

## Chapter

# Ureteropelvic Junction Obstruction: Robot-Assisted Pyeloplasty

*Pietro Diana, Paolo Casale, Alberto Rosario Saita,  
Giovanni Lughezzani and Nicolomaria Buffi*

## Abstract

The standard treatment of ureteropelvic junction obstruction (UPJO) is represented by the Anderson-Hynes dismembered pyeloplasty, even if different approaches, both surgical and endoscopic, have been described. Robot-assisted pyeloplasty (RP) is a feasible and safe approach. The indications for the robotic approach remain the same as those for the laparoscopic or open pyeloplasty. Every patient with symptomatic UPJO, or with decreasing renal function in the presence of UPJO, should undergo RP. The transperitoneal, retroperitoneal, and transmesocolic approaches are described focusing on advantages and disadvantages of each approach. Robot-assisted pyeloplasty has excellent success rates for relief of obstruction and very low peri- and post-operative morbidity. The robotic surgical technique maintains the advantages of laparoscopic surgery providing a more precise manipulation and visualization, and a faster learning curve. Comparative studies are reported to confront the different techniques. Secondary minimally invasive pyeloplasty is obviously a more challenging procedure due to the fibrosis and the adhesions formed after the previous surgery. Newer techniques and indications such as the employment of buccal mucosal graft, the single port approach, and indocyanine green injection are described. Tips and tricks to keep in mind during this kind of procedure are listed in order to report our experience in this setting.

**Keywords:** ureteropelvic junction obstruction, robot-assisted pyeloplasty, robotic surgery

## 1. Introduction

The standard treatment of ureteropelvic junction obstruction (UPJO) is represented by the Anderson-Hynes dismembered pyeloplasty, even if different approaches, both surgical and endoscopic, have been described.

The Anderson-Hynes dismembered pyeloplasty was first described in 1993 by Schuessler et al. [1], and the laparoscopic approach has become the gold standard in alternative to the open approach as the long-term outcomes are comparable between the two techniques with success rates from 90 to >95% [2–5]. However, laparoscopic

pyeloplasty, both through a transperitoneal and a retroperitoneal approach, remains a challenging procedure and it requires high proficiency in laparoscopic skills especially due to the reconstructive part. In fact, even in large series of referral centers, the operative time remains extensive.

The robot-assisted laparoscopic approach overcomes the limits of conventional laparoscopy thanks to the three-dimensional vision, increased tools dexterity, and greater precision. Therefore, considering the reconstruction skills needed for intracorporeal suturing, dismembered pyeloplasty most benefits from the robotic assistance.

Robotic pyeloplasty (RP) using the Da Vinci (Intuitive Surgical, Inc., Sunnyvale, CA, USA) system has been first described by Gettman et al. in 2002 [6], reporting perioperative outcomes of 9 patients treated with robotic transperitoneal pyeloplasty for UPJO.

### 1.1 Indications to robotic dismembered pyeloplasty

The indications for the robotic approach remain the same as those for the laparoscopic or open pyeloplasty. Every patient with symptomatic UPJO, or with decreasing renal function in the presence of UPJO, should undergo RP. Additionally, patients that failed primary treatment, the robotic approach could be considered.

The diagnostic workout mirrors the one for the open and laparoscopic approach. The patients should undergo diuretic MAG4 renogram and CT scan to evaluate the anatomy, such as the presence of a crossing vessel and the eventual presence of renal calculi to plan the surgical strategy accordingly.

## 2. Surgical strategies

### 2.1 Transperitoneal approach for robot-assisted pyeloplasty

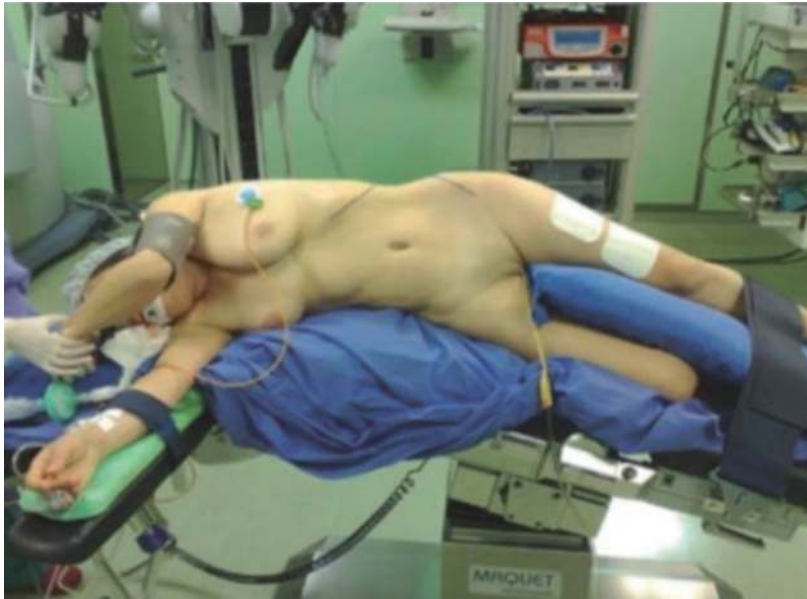#### 2.1.1 Operating room setup

The patient is placed at a 60° full flank position exposing upward the affected side. The two arms are placed on an arm board and alongside the patient's flank, respectively. Both legs are fully extended and the upper one is abducted with one or two pillows placed in between. Extension of the operating table is performed breaking the patient's flank midway between the iliac crest and the costal margin to obtain a broader operating field (**Figure 1**).

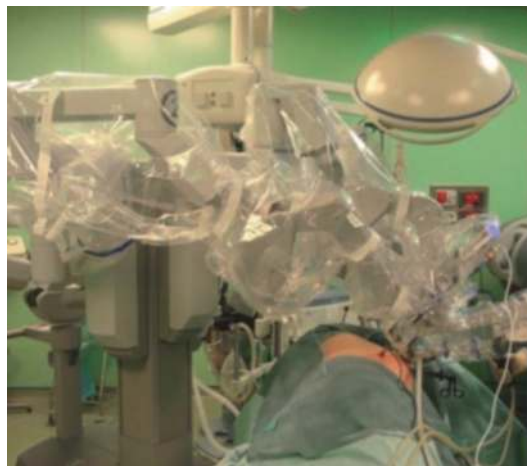The OR setup can be seen in **Figure 2**. Anesthesia takes position at the head of the patient. The robotic cart is coming from the patient's back.

#### 2.1.2 Robotic ports

The optic trocar is placed at the level of the umbilicus, for esthetic reasons, or on pararectal line for obese patients always at the umbilical level. Trocars of 12 or 8 mm are used for the Si and Xi DaVinci system, respectively. Either a 30° or a 0° camera is employed depending on the operator preference. The two operative robotic ports are positioned at the midpoint between the anterior superior iliac spine and the umbilicus and on the pararectal line at least 1 cm below the costal arch. The 5-mm assistant port is placed cranially in respect to the camera port at the midpoint between the umbilicus and the xiphoid process (**Figure 3**).



**Figure 1.**  
*Patient's position for transperitoneal robotic pyeloplasty.*

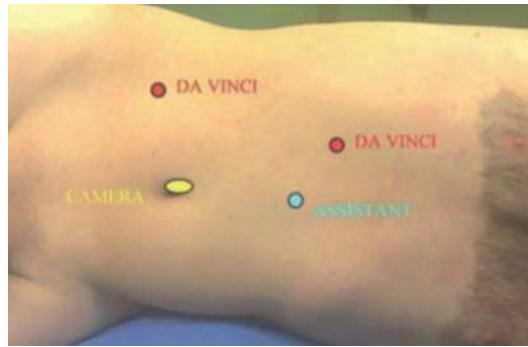


**Figure 2.**  
*Operating theater setup for transperitoneal robotic pyeloplasty.*

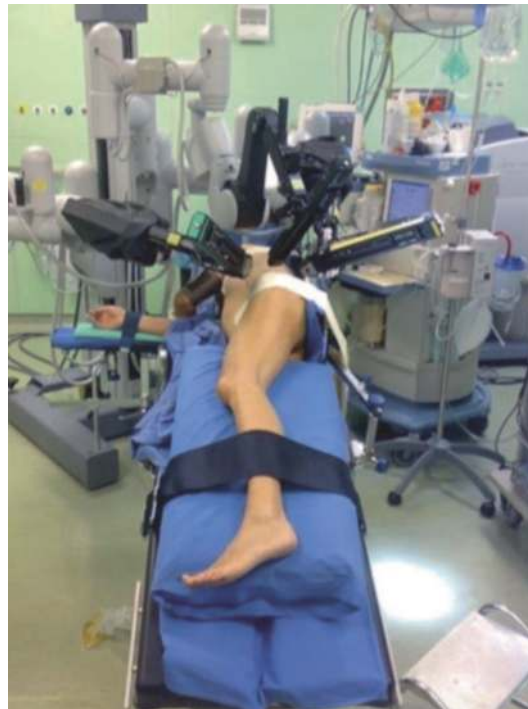### *2.1.3 Procedure step-by-step*

After the medialization of the colon, on the right side, the overlying Gerota's fascia is incised, while on the right side, the white line of Toldt is incised and the left colon is mobilized medially. Despite the side, the target structures (the ureter, the dilated renal pelvis, and eventually the aberrant crossing vessels) are exposed. The ureter can be visualized by following the psoas muscle medially starting from the lower pole of the kidney. Any crossing vessels are identified and preserved. The UPJ is fully mobilized using both blunt and sharp dissection. Bipolar fenestrated forceps and monopolar scissors are employed in this phase.

When the UPJ is isolated and the obstruction is identified, section of the ureter is performed. In case of a severe dilation of the pelvis, the redundant portion should be excised. The presence of renal calculi in the renal pelvis implies its removal with the employment of a flexible cystoscope. The ureter is then spatulated



**Figure 3.**  
*Port placement for transperitoneal robotic pyeloplasty.*



**Figure 4.**  
*Patient's position for retroperitoneal robotic pyeloplasty.*

longitudinally up to the visualization of healthy tissue; the pyeloplasty is then performed according to the Anderson-Hynes technique. Two 4-0 Vicryl running sutures are preferred for the anastomosis, one for the posterior and the other for the anterior plate using a robotic needle driver.

In the case of a crossing vessel, a dismembered pyeloplasty is performed with anterior transposition of the ureteral anastomosis in respect to the blood vessels.

## 2.2 Retroperitoneal approach for robot-assisted pyeloplasty

### 2.2.1 Operating room setup

As seen in **Figure 4**, the patient is placed in a full flank position with the operating table extended to maximize the operating field. The robotic system is placed in order to enter the arms anteriorly of 25–30° in respect to the head of the patient.

### 2.2.2 Robotic ports

A retroperitoneal access is performed at the level of the tip of the 12th rib. A Balloon expander or other cost-effective alternatives (such as a finger of sterile gloves tied to a trocar and filled with saline water) [7] are used to create a working space in the retroperitoneal fat. The two operative ports are positioned at the crossover of the 12th rib and the erector spinae muscle and at the level of the anterior axillary line 6–8 cm cranially to the iliac crest, respectively. A 5-mm trocar for the assistant is positioned along the erector spinae muscle, cranially to the iliac crest (**Figure 5**).

### 2.2.3 Procedure step-by-step

The Gerota's fascia is excised and the UPJ is exposed. The plasty mirrors the transperitoneal approach.

## 2.3 Transperitoneal versus retroperitoneal access

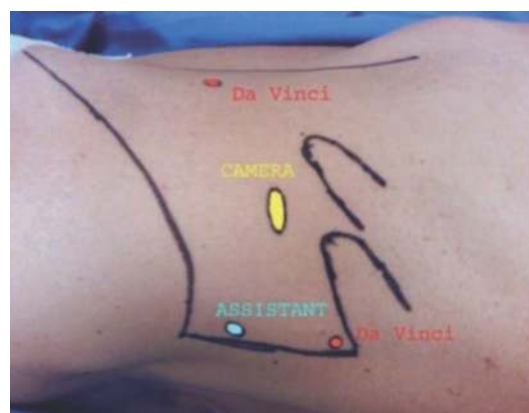Cestari et al. [5] reported outcomes of 36 and 19 patients who underwent retroperitoneal and transperitoneal robotic pyeloplasty, respectively. They stated that either the transperitoneal or retroperitoneal approach is feasible and safe, comparable in terms of operative time, estimated blood loss, and postoperative complications. No cases of conversion were reported.

Regarding the transperitoneal approach, given the wider working space, it is usually preferred in case of a wide renal pelvis (>6 cm), presence of pelvic calculi, crossing vessels, renal malformations (i.e., horseshoe kidney), or pelvic kidney.

The advantage of the retroperitoneal access comprehends a direct exposure of the UPJ without the opening of the peritoneal cavity and minimizing intraperitoneal organs injury. However, the lack of familiar anatomical reference structures and a narrow operative space are limitations of this approach. Additionally, using a retroperitoneal access gives the possibility to manage conservatively urinary fistulas, since urine will remain in the retroperitoneal cavity.

## 2.4 Transmesocolic approach for the left robot-assisted pyeloplasty

Gupta et al. reported in 2009 the transmesocolic access for the left UPJO [8] through an incision of the mesocolon. This approach allows the operator to access directly the left renal pelvis and UPJ without mobilizing the descending colon.



**Figure 5.**  
*Port placement for retroperitoneal robotic pyeloplasty.*

The best candidates for this approach are young thin patients, with a large renal pelvis. In the case of renal calculi or either previous or present history of a complicated ureteropelvic junction obstruction, a transperitoneal approach might be the access of choice.

The transmesocolic approach brings advantages such as a shorter mean operative time and hospital stay, and a faster bowel peristalsis recovery as described in the literature [9, 10].

## **2.5 Ureteral stenting in robot-assisted pyeloplasty**

A ureteral stent is necessary to protect the anastomosis from high renal intrapelvic pressure. Therefore, a ureteral stent is usually placed during the procedure either in a retrograde or antegrade fashion.

Retrograde stent placement is performed in the operating room before the procedure. A retrograde pyelogram during the double J position can exclude any other ureteric abnormalities. However, it is more time-consuming as the patient is before proceeding with the surgery; moreover, stenting results in the collapse of the renal pelvis, making the identification of the UPJ stricture more difficult.

Antegrade stenting consists in putting the ureteral double-J stent during the pyeloplasty. In this way, the collapse of the renal pelvis is avoided. Usually, a hydrophilic guidewire and a 5-Fr ureteral catheter are inserted through the 5-mm trocar after suturing the posterior aspect of the anastomosis. The guidewire and the catheter are pushed within the ureter with a robotic grasper or a needle driver down to the bladder. Then, the ureteral catheter is removed and the double-J stent is placed onto the guidewire. After the stent placement, the anterior aspect of the anastomosis is completed. This technique is safe, feasible and time-saving [11]. Disadvantage consists in the blind placement of the stent. Correct stent placement can be assured by fluoroscopy or an abdominal X-Ray; another technique has been reported by Rodrigues et al. [12] using methylene blue to fill the bladder and its appearance through the stent holes as an indicator of correct positioning.

Gaitonde et al. [13] used a cystoscopically placed ureteropelvic junction occlusion catheter positioned along with a marked Foley urethral catheter to display the distance required to accurately position the lower coil of the stent into the bladder. The Foley and the occlusion balloon are prepared and after pyelotomy, the balloon is deflated, and the occlusion catheter is withdrawn into the proximal ureter. After completing the posterior aspect of the anastomosis, a guidewire is inserted through the catheter and grasped at the kidney pelvis. The occlusion catheter is then removed and the stent pushed along the guidewire up to the renal pelvis. The distal end of the stent pusher was advanced until the calibrated mark of the Foley catheter appears to ensure the correct positioning of the distal coil in the bladder.

Fiori et al. reported flexible pneumocystoscopy as safe and feasible in placing a retrograde ureteral stent in the setting of laparoscopic pyeloplasty. In this way, the patient can be placed directly on the flank position and the reconstruction can proceed [14].

Studies comparing retrograde versus an antegrade stenting approach have been done. For all the studies, the setting is the laparoscopic pyeloplasty. Antegrade stenting is quicker; however, retrograde stenting appears to ensure a higher success rate in correct stent placement [15–18]. Stentless pyeloplasty has also been reported; however, very few and conflicting reports evaluate the safety and the efficacy of a stentless approach [19–21].

## 2.6 Postoperative management

Patient's mobilization and feeding can start postoperative day 1. The bladder catheter is usually removed on postoperative day 2 and the drain the following day if the output is less than 50–70 mL; patients are discharged on the same day.

Stent removal occurs after 4 weeks postoperatively. On the same occasion, urinalysis, urine culture, and abdominal ultrasound can be prescribed in order to assess the short-term operative outcome.

Patients are then evaluated at 6 and 12 months with urinalysis, urine culture, MAG3 renogram, and URO-CT scan.

## 3. Surgical outcomes

Robot-assisted pyeloplasty has excellent success rates for relief of obstruction and very low peri- and post-operative morbidity. The robotic surgical technique maintains the advantages of laparoscopic surgery, providing a more precise manipulation and visualization and a faster learning curve.

Several methods and variables may be adopted to define resolution of the obstruction including radiology and nuclear medicine tests (renogram, intravenous pyelogram, or ultrasound), symptom resolution, and laboratory analysis.

Ultrasound can lead to an incorrect interpretation of obstruction resolution as the persistent residual hydronephrosis can be seen for months or longer after the procedure.

Renal scintigraphy is widely recognized as the best noninvasive imaging modality to define the obstruction and it is employed in the evaluation of the postoperative outcomes.

The first experience with robot-assisted Anderson-Hynes pyeloplasty was published by Getmann et al. in 2002 [6]. The authors reported outcomes of 9 consecutive patients treated with transperitoneal robotic pyeloplasty. No surgical conversion was reported and 1 patient underwent an open surgery in the second place because of a urinary fistula. Favorable outcome for all patients was reported at 4 months follow-up.

Patel published a 50-patient series reaching 100% of success rate. Operative success was defined by a negative MAG3 renography. The authors stated that this technique offers short-term efficacy and a very low rate of complications, with a quick learning curve [22].

Mufarrij et al. reported a multi-institutional series of 140 patients, with 29 months follow-up, including both primary and secondary UPJO. The success rate reached the 96% of the cases and recurrence was reported in six cases. Complication rate was 7.1% and, postoperatively, double-J stent migration was the most common complication. As for minor complications, fever was the most frequently described [23].

Schwentner et al. published in 2007. A large series of 92 patients, 80 with primary obstruction and 12 with secondary ones, were described. The follow-up reached up to 40 months and the success rate was 96%. In the secondary obstruction, the arm failure rate after RP was slightly higher [24].

The optimal results of the robotic procedure were confirmed in another multi-institutional large series of 169 patients, both primary and secondary obstructions being taken into account. The success rate reached 97.6% with 39 months follow-up. The mean estimated blood loss (EBL) was around 50 mL and the complication rate was 6.6% [25].

Authors	Number of patients	Transperitoneal vs. retroperitoneal approach	Operative time (min)	Conversion rate (%)	Complication rate (%)	Hospital stay (days)	Follow-up (months)
Patel [22]	50	Transperitoneal	122	0	32	1.1	11.7
Olsen et al. [30]	67	Retroperitoneal	146	1.5	17.9	2	12.1
Schwentner et al. [24]	92	Transperitoneal	108	0	NA	4.6	39.1
Mufarrrij et al. [23]	140	Transperitoneal	217	0	10	2.1	29
Guptal et al. [31]	86	Transperitoneal	121	2.3	9.3	2.5	13.6
Minnillo et al. [28]	155	Transperitoneal	198.5	0	11	1.95	31.7
Etafy et al. [32]	61	Transperitoneal	335	0	11.4	2	18
Sivaraman et al. [25]	168	Transperitoneal	134.9	0	6.6	1.5	39
Buffi et al. [33]	145	Both	120	2.8	8.3	4.7	24

**Table 1.** Comparative studies (more than 50 patients)



Cestari et al. reported that both the retro- and transperitoneal RPs were safe and these were the feasible procedures with a low morbidity rate with an overall success rate of 96% [5].

Overall, the outcomes of the procedure have been defined as excellent and reproducible [22, 25, 26], with durable results [24].

The success rate reported [27] is high (81–100%), with reintervention rates between 0 and 13.1%. Operative times are more variable, ranging from 105 to 335 min. They concluded RP to be a safe procedure with a reproducible high rate of successful outcomes, low conversion rates (0–4.8%), complication rates (2–17.9%), and a limited EBL.

Outcomes of RP in the pediatric population have been largely described in the literature. Minnillo et al. published the largest series, assessing 155 pediatric patients undergoing RP; a success rate of 96% with a 3% of failure rate was reported [28].

A recent meta-analysis of comparative studies in the pediatric population showed no difference in success rate between robotic and conventional laparoscopic pyeloplasty [29] with an overall success rate of 99.3% and 96.9%, respectively, with no significant difference between the two approaches. Complication and reoperation rates were comparable between the two approaches. The length of hospitalization was significantly shorter for the robotic group (**Table 1**).

A recent multi-institutional study [34] reported 407 pediatric cases treated with robotic pyeloplasty and found a complication rate of 13.8%. No high-grade complications were reported (Clavien Dindo IV or V).

### **3.1 Comparative studies**

Autorino et al. published a meta-analysis that demonstrates no statistically significant difference in terms of success and complication rates between minimally invasive and open approach in the adult population; however, the minimally invasive approaches provides a shorter hospital stay compared to open surgery [27].

Basatac et al. [35] confirmed the significant decrease in the length of hospital stay, estimated blood loss, earlier drainage removal, and the decrease of the need for painkillers. In terms of success rates, intraoperative complications, and conversions, no significant differences were found.

Basatac et al. described a shorter time for robotic surgery although considering exclusively the console time. Hanske et al. [36], when evaluating a large number of patients undergoing minimally invasive versus open, reports a statistically significant difference in the percentage of patients requiring prolonged operation time (<236 min): 29.6% for minimally invasive pyeloplasty versus 15.3% for open pyeloplasty.

## **4. Role of robotic approach in the management of recurrent ureteropelvic junction obstruction**

The robotic approach is feasible, safe, and effective for treating recurrent obstruction [33]. Secondary minimally invasive pyeloplasty is obviously a more challenging procedure due to the fibrosis and the adhesions formed after the previous surgery. The precise movements with the robotic assistance and the amplified vision provide higher precision, thus, a bloodless dissection and a higher quality of the suture above all in complex patients.

RP in the treatment of secondary obstructions in pediatric series is reported with data from small series of patients. No comparative prospective studies were ever reported.

Thom et al. found that nine secondary robotic procedures done at their center required longer operative time with an increased blood loss and failure rate (22%) [37]. Atug et al. show data from 7 patients undergoing redo RP. The outcomes were compared with data from a series of 37 patients that underwent RP for primary ureteropelvic junction obstruction. Mean operative time was 60 min longer in the secondary RP group. However, EBL, hospital stay, and overall success were comparable [38].

Hemal et al. described the outcomes of 9 patients (mean age: 16.4 year) treated for secondary UPJO after failure of a previous open pyeloplasty and additionally failed endoscopic pyelotomy. All patients were treated robotically and reported clinical resolution of symptoms and no sign of residual obstruction at postoperative renal scan [39].

Data from a series of 20 patients treated for secondary obstruction were published. Redo RP resulted successful in 94% of cases and the procedure was reported as feasible and safe [40].

Another series of 16 pediatric patients affected by secondary ureteropelvic junction obstruction is reported by Lindgren et al. [41]. These patients underwent redo RP following prior intervention, in specific, 12 underwent previous open surgeries and 4 RP. Redo RP and redo robotic ureterocalicostomy were performed in 13 and 3 patients, respectively. Overall resolution of symptoms was 100%, and radiographic test resolution or improvement was reported in 88% of cases. None of the patients needed further surgical treatment at an intermediate-term follow-up.

## 5. Single-site robot-assisted pyeloplasty

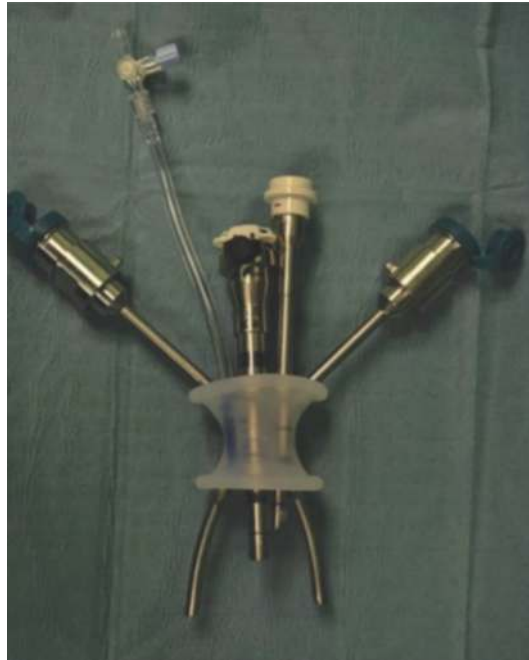
The treatment of UPJO is frequently performed in young patients. Thus, besides the resolution of the obstruction, the cosmetic result represents a crucial point in this population. Laparoendoscopic single site (LESS) pyeloplasty has been thought to reach this kind of goal [41, 42].

LESS is a complex approach, particularly due to suturing, even for urologists with an extended experience. This is due to the loss of instrument triangulation and instrument clashing and to the reduced visibility and maneuverability associated with the coaxial orientation of instruments and of the laparoscope. The robotic technology minimizes the limitations associated with laparoendoscopic single site.

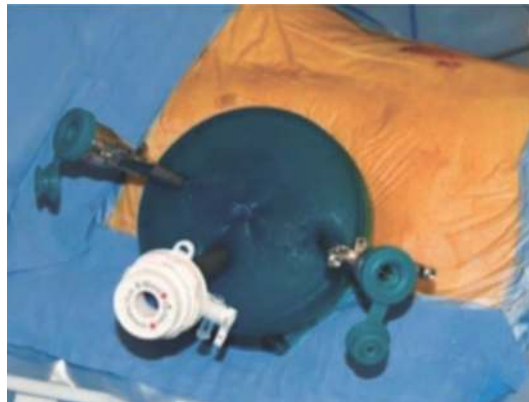Robotic laparoendoscopic single site (R-LESS) pyeloplasty technique is performed with the use of a 2.5 cm umbilical incision. Through this the single site port is inserted and the robot arms are connected (**Figure 6**) [43]. The GelPort system, introduced by a 3–5 cm umbilical incision, has also been employed to perform robotic LESS pyeloplasty [44] (**Figure 7**).

Data from a multicenter series of 30 cases reported the feasibility and safety of R-LESS pyeloplasty in highly selected patients. Only 2 patients were converted into a classic laparoscopic or robot-assisted approach. In three cases, an additional 3 mm trocar was needed. Success rate, at 13 months follow up, was comparable to rates reported in conventional robotic studies.

Exclusion criteria for this approach are a body mass index (BMI)  $>30 \text{ kg/m}^2$ , previous surgical procedure, an extremely dilated kidney pelvis (i.e., pelvis diameter  $> 6 \text{ cm}$ ), complicated ureteropelvic junction obstruction with calculi, pelvic kidney, and horseshoe kidney [45, 46].



**Figure 6.**  
*Da Vinci single site.*



**Figure 7.**  
*The GelPort system.*

R-LESS pyeloplasty is considered as a feasible and reproducible procedure in selected cases offering shorter hospitalization. Real advantages compared to the standard robot-assisted pyeloplasty are still to be shown in terms of operative outcome.

## **6. Buccal mucosal graft in pyeloplasty**

Management of recurrent UPJO has lower success rate compared to primary treatment. Redo pyeloplasty can be challenging due to scar tissue and fibrosis that lead to larger resections to find healthy and well-vascularized tissue for reanastomosis. Buccal mucosal grafts (BMG), already in use for ureteral reconstruction, have been proposed in UPJO refractory to surgery and endoscopic treatment [47].

The procedure consists in identifying the UPJO and dissecting longitudinally the anterior aspect of the stenosis. The incision is carried 1 cm proximally and distally to the stricture to ensure exposure of healthy tissue. 8-Fr double-J ureteral stents is placed robotically without the use of fluoroscopy. Single buccal graft is then harvested from the right inner cheek avoiding to compromise the Stensen ducts. The graft is placed as an anterior anastomotic onlay, over the ureteral and UPJ defect, with two 4-0 Vicryl sutures in a running fashion. The repair and entire surgical fields are wrapped in omentum after confirming the anastomoses are watertight with retrograde filling of the urinary collecting systems with methylene blue.

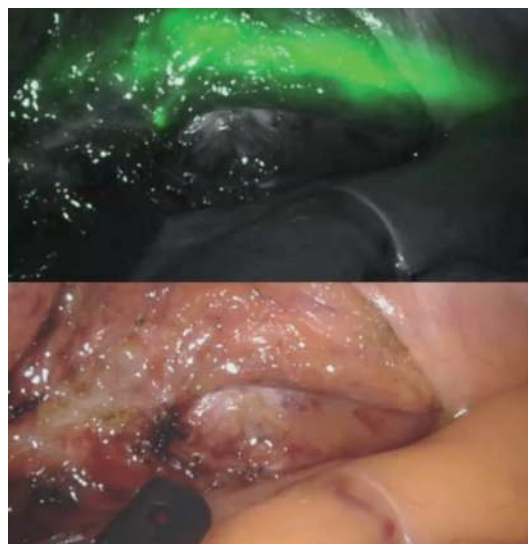
Although a handful of cases have been reported, it is a feasible and safe technique in both a pediatric and adult population. In the two studies, 3 and 2 patients were reported and a complete resolution of symptoms with a stable or improved ultrasound was seen at a median follow-up of 10 and 7 months, respectively. No postoperative complications were reported [48, 49].

## 7. The role of indocyanine green in redo pyeloplasty

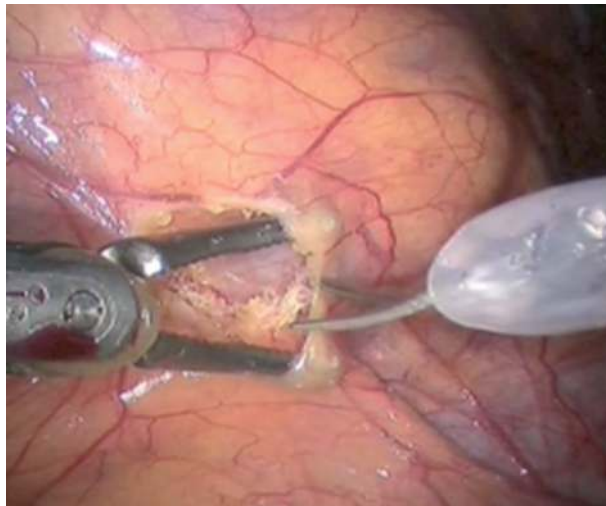The use of intraureteral injection indocyanine green (ICG) dye and subsequent visualization under near infra-red fluorescence (NIRF) has been used to facilitate robotic ureteral identification and reconstruction by aiding in rapid and accurate identification of the stricture margins. This can be particularly useful in case of recurrent UPJ interventions since the presence of fibrotic tissue may be a challenge to the surgeon [50, 51].

The procedure consists in inserting a 6-Fr ureteral catheter into the diseased ureter and 10 ml of ICG is injected retrogradely into the lumen, above and below the level of stenosis, and NIRF is used to guide our dissection; healthy tissue appears bright green and fibrotic, less perfused tissue, since it loses its transparency, appears darker giving precise localization of the proximal and distal stricture margins (**Figure 8**). Step-by-step procedure is shown in **Figures 9–15**.

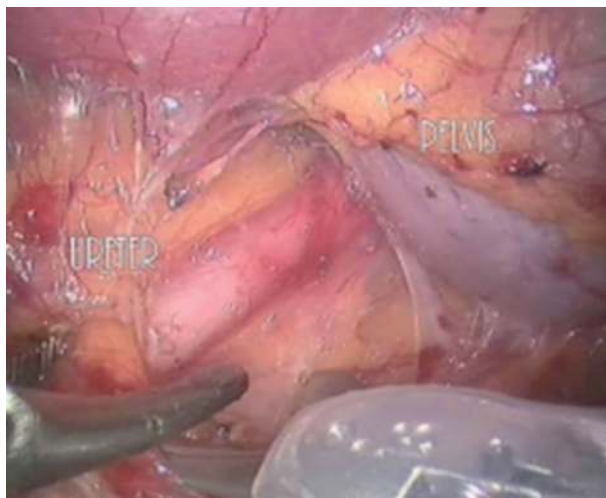
Several series were published proving that the intraureteral injection of ICG is reproducible, safe, easy to perform, and involves minimal additional costs. All cases were clinically and radiographically successful, and no patient has required a repeat operation for stricture recurrence [50].



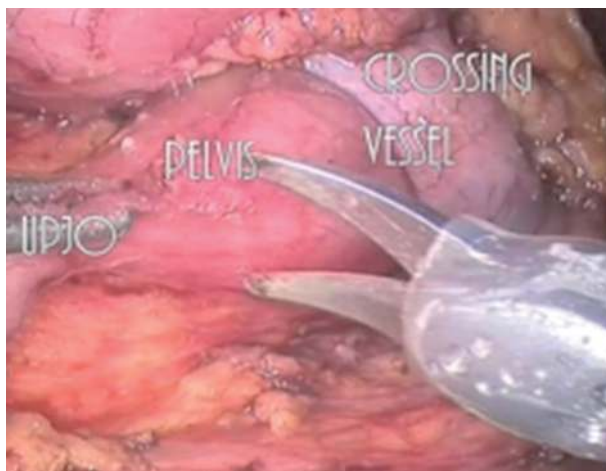
**Figure 8.**  
*Intraureteral injection of indocyanine green in a redo pyeloplasty.*



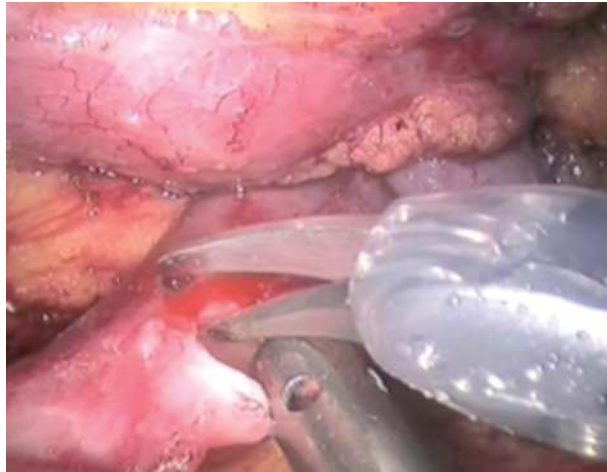
**Figure 9.**  
*Peritoneal incision.*



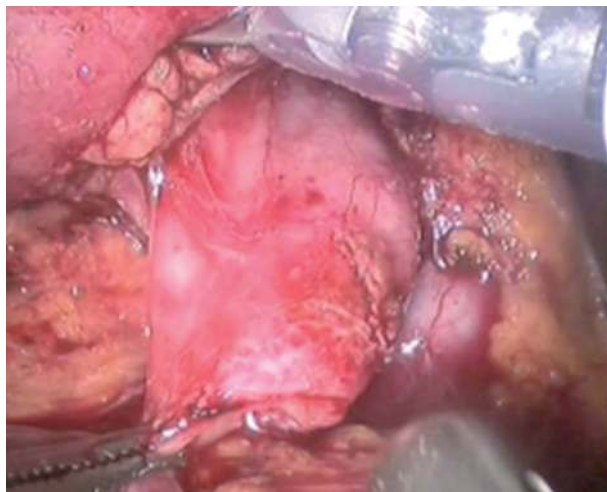
**Figure 10.**  
*Structures isolation.*



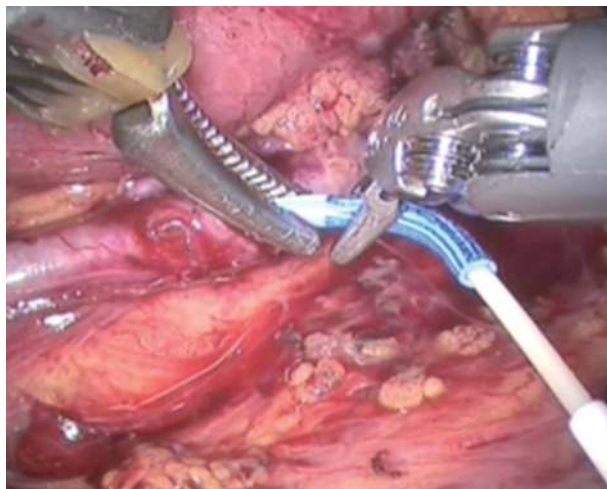
**Figure 11.**  
*Exposure of structures.*



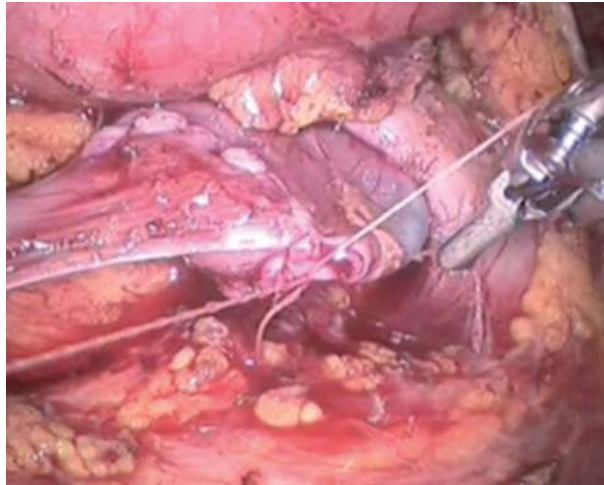
**Figure 12.**  
*Ureteral Incision.*



**Figure 13.**  
*Decrossing of the renal pelvis.*



**Figure 14.**  
*Anterograde ureteral stenting.*



**Figure 15.**  
*Anastomosis.*

## 8. Tips and tricks to approach robot-assisted pyeloplasty

Here, the steps where we think it is most important not to underestimate are described.

First of all particular attention should be given to the ports placement; although, it could sound trivial if you have a wrong port positioning the surgery might result challenging and the failure rate and risk of complications increase. During the diagnostic workout, a CT scan is performed not only to check for the presence of renal stones and a crossing vessel but also to understand the anatomy and the relationship of the kidney with the renal pelvis. The kidney can be ectopic, also called pelvic, and this would change the trocars placement. UPJO incidence reaches up to 22–37% of ectopic kidneys [52]. The camera port is still placed at the umbilicus level. The two operative robotic ports are positioned on the homolateral side as affected kidney 8 cm apart laterally on the same line as the camera and the 5-mm assistant port is positioned at the distal third on the line between the superior anterior iliac crest and the umbilicus.

Ureteral isolation is also fundamental for reducing the peri-operative risks and to better manage the ureter during the reconstruction phase. Several are the challenging scenarios where the importance of the ureteral isolation cannot be overstated. In the redo pyeloplasty, the fibrotic tissue makes both the identification and the handling of the structures more difficult and the risk of failure might increase if the ureter is not well isolated; as said the use of intraureteral ICG can help during this phase. Other scenarios can be encountered in the case of extra-rotated kidneys and intrarenal pelvis where the structures can be hidden and, in these cases, a partial isolation of the kidney and marker stitches can be placed to better expose the structures and a larger surgical field.

It is important not to underestimate the presence of calculi in the renal pelvis. In these cases, a flexible cystoscope can be inserted through one of the robotic trocars and consequently inserted into the renal pelvis through a small incision previously performed. This is important as it allows stone extraction or even lithotripsy avoiding spilling of water into the peritoneal cavity.

Finally, the ureteropelvic anastomosis is one of the most crucial phases of this kind of surgery as it is fundamental to have a continent anastomosis to avoid urinary fistulas, but it is also important not to have an over tight suturing that would create again a stricture of the junction. Barbed sutures are advised as the barbs on its surface penetrate inside the tissue and lock them into place enabling the surgeon to adjust the tightness of the anastomosis.

## Author details

Pietro Diana<sup>1,2</sup>, Paolo Casale<sup>1</sup>, Alberto Rosario Saita<sup>1,2</sup>, Giovanni Lughezzani<sup>1,2</sup> and Nicolomaria Buffi<sup>1,2\*</sup>

1 Department of Urology, Humanitas Clinical and Research Institute, Rozzano, Italy

2 Humanitas University, Pieve Emanuele, Italy

\*Address all correspondence to: buffi.nicolomaria@gmail.com

## IntechOpen

---

© 2020 The Author(s). Licensee IntechOpen. This chapter is distributed under the terms of the Creative Commons Attribution License (<http://creativecommons.org/licenses/by/3.0>), which permits unrestricted use, distribution, and reproduction in any medium, provided the original work is properly cited. 



## References

- [1] Schuessler WW, Grune MT, Tecuanhuey LV, et al. Laparoscopic dismembered pyeloplasty. *The Journal of Urology*. 1993;**150**:1795
- [2] Brooks JD, Kavoussi LR, Preminger GM, Schessler WW. Comparison of open and endourological approaches to the obstructed uretero-pelvic junction. *Urology*. 1995;**46**:791-795
- [3] Bauer JJ, Bishoff JT, Moore RG, Chen RN, Iverson AJ, Kavoussi LR. Laparoscopic versus open pyeloplasty: Assessment of objective and subjective out-come. *The Journal of Urology*. 1999;**162**:692-695
- [4] Klingler HC, Remzi M, Janetschek G, Kratzik C, Marberger MJ. Comparison of open versus laparoscopic pyeloplasty techniques in treatment of ureteropelvic junction obstruction. *European Urology*. 2003;**44**:340-345
- [5] Cestari A, Buffi NM, Lista G, et al. Retroperitoneal and transperitoneal robot-assisted pyeloplasty in adults: Techniques and results. *European Urology*. 2010;**58**:711-718
- [6] Gettman MT, Neururer R, Bartsch G, Peschel R. Anderson-Hynes dismembered pyeloplasty performed using the da Vinci robotic system. *Urology*. 2002;**60**:509-513
- [7] Cestari A, Guazzoni G, Naspro R, et al. Original dissecting balloon for retroperitoneal laparoscopy: Cost-effective alternative to commercially available device. *Journal of Endourology*. 2007;**21**:714-717
- [8] Gupta NP, Mukherjee S, Nayyar R, Hemal AK, Kumar R. Transmesocolic robot-assisted pyeloplasty: Single center experience. *Journal of Endourology*. 2009;**23**:945-948
- [9] Porpiglia F, Billia M, Volpe A, Morra I, Scarpa RM. Transperitoneal left laparoscopic pyeloplasty with transmesocolic access to the pelvi-ureteric junction: Technique description and results with a minimum follow-up of 1 year. *BJU International*. 2008;**101**:1024-1028
- [10] Shadpour P, Nayyeri RK, Daneshvar R, Salimi H, Radfar H. Prospective clinical trial to compare standard colon-reflecting with transmesocolic laparoscopic pyeloplasty. *BJU International*. 2012;**110**:1814-1818
- [11] Minervini A, Siena G, Masieri L, Lapini A, Serni S, Carini M. Antegrade stenting in laparoscopic pyeloplasty: Feasibility of the technique and time required for stent insertion. *Surgical Endoscopy*. 2009;**23**:1831-1834
- [12] Rodrigues H, Rodrigues P, Ruela M, Bernabé A, Buogo G. Dismembered laparoscopic pyeloplasty with antegrade placement of ureteral stent: Simplification of the technique. *International Brazilian Journal of Urology*. 2002;**28**:439-444
- [13] Gaitonde K, Roesel G, Donovan J. Novel technique of retrograde ureteral stenting during laparoscopic pyeloplasty. *Journal of Endourology*. 2008;**22**:1199-1202
- [14] Fiori C, Morra I, Di Stasio A, Grande S, Scarpa RM, Porpiglia F. Flexible pneumocystoscopy for double J stenting during laparoscopic and robot assisted pyeloplasty: Our experience. *International Journal of Urology*. 2010;**17**:192-194
- [15] Mandhani A, Goel S, Bhandari M. Is antegrade stenting superior to retrograde stenting in laparoscopic pyeloplasty? *The Journal of Urology*. 2004;**171**:1440-1442

- [16] Chandrasekharam VV. Is retrograde stenting more reliable than antegrade stenting for pyeloplasty in infants and children? *Urology*. 2005;**66**:1301-1304
- [17] Arumainayagam N, Minervini A, Davenport K, et al. Antegrade versus retrograde stenting in laparoscopic pyeloplasty. *Journal of Endourology*. 2008;**22**:671-674
- [18] El-Feel AS, Abdel-Hakim MA, Abouel-Fettouh HI, Abdel-Hakim AM. Antegrade ureteral stenting during laparoscopic dismembered pyeloplasty: Intraoperative findings and long-term outcome. *Journal of Endourology*. 2010;**24**:551-555
- [19] Shalhav AL, Mikhail AA, Orvieto MA, Gofrit ON, Gerber GS, Zorn KC. Adult stentless laparoscopic pyeloplasty. *Journal of the Society of Laparoendoscopic Surgeons*. 2007;**11**:8-13
- [20] Bilen CY, Bayazit Y, Güdelo lu A, Abat D, Inci K, Doran S. Laparoscopic pyeloplasty in adults: Stented versus stentless. *Journal of Endourology*. 2011;**25**:645-650
- [21] Sethi AS, Regan SM, Sundaram CP. Robot-assisted laparoscopic pyeloplasty with and without a ureteral stent. *Journal of Endourology*. 2011;**25**:239-243
- [22] Patel V. Robotic-assisted laparoscopic dismembered pyeloplasty. *Urology*. 2005;**66**:45-49
- [23] Mufarrij PW, Woods M, Shah OD, et al. Robotic dismembered pyeloplasty: A 6-year, multi- institutional experience. *The Journal of Urology*. 2008;**180**:1391-1396
- [24] Schwentner C, Pelzer A, Neururer R, et al. Robotic Anderson-Hynes pyeloplasty: 5-year experience of one Centre. *BJU International*. 2007;**100**:880-885
- [25] Sivaraman A, Leveillee RJ, Patel MB, et al. Robot- assisted laparoscopic dismembered pyeloplasty for ureteropelvic junction obstruction: A multi-institutional experience. *Urology*. 2012;**79**:351-355
- [26] Gupta NP, Nayyar R, Hemal AK, Mukherjee S, Kumar R, Dogra PN. Outcome analysis of robotic pyeloplasty: A large single-Centre experience. *BJU International*. 2010;**105**:980-983
- [27] Autorino R, Eden C, El-Ghoneimi A, et al. Robot-assisted and laparoscopic repair of ureteropelvic junction obstruction: A systematic review and metanalysis. *European Urology*. 2014;**65**:430-452
- [28] Minnillo BJ, Cruz JA, Sayao RH, et al. Long-term experience and outcomes of robotic assisted laparoscopic pyeloplasty in children and young adults. *The Journal of Urology*. 2011;**185**:1455-1460
- [29] Cundy TP, Harling L, Hughes-Hallett A, et al. Meta-analysis of robot-assisted vs conventional laparoscopic and open pyeloplasty in children: Robot- assisted vs laparoscopic and open pyeloplasty in children. *BJU International*. 2014;**114**:582-594
- [30] Olsen LH, Rawashdeh YF, Jorgensen TM. Pediatric robot assisted retroperitoneoscopic pyeloplasty: A 5-year experience. *Journal of Urology*. 2007;**178**(5):2137-2141
- [31] Gupta NP, Nayyar R, Hemal AK, et al. Outcome analysis of robotic pyeloplasty: A large single-centre experience. *BJU International*. 2010;**105**(7):980-983. DOI: 10.1111/j.1464-410X.2009.08983
- [32] Etafy M, Pick D, Said S, et al. Robotic pyeloplasty: The University of California-Irvine experience. *Journal of Urology*. 2011;**185**(6):2196-2200. DOI: 10.1016/j.juro.2011.02.054

- [33] Buffi NM, Lughezzani G, Hurle R, et al. Robot-assisted surgery for benign ureteral strictures: Experience and outcomes from four tertiary care institutions. *European Urology*. 2017;**71**:945-951
- [34] Dangle PP, Akhavan A, Odeleye M, et al. Ninety-day perioperative complications of pediatric robotic urological surgery: A multi-institutional study. *Journal of Pediatric Urology*. 2016;**12**(102):e1-e102
- [35] Basatac C, Boylu U, Öno FF, Gümüs E. Comparison of surgical and functional outcomes of open, laparoscopic and robotic pyeloplasty for the treatment of ureteropelvic junction obstruction. *Turkish Journal of Urology*. 2014;**40**(1):24-30
- [36] Hanske J, Sanchez A, et al. Comparison of 30-day perioperative outcomes in adults undergoing open versus minimally invasive pyeloplasty for uretero-pelvic junction obstruction: Analysis of 593 patients in a prospective national database. *World Journal of Urology*. 2015;**33**(12):2107-2113
- [37] Mei H, Pu J, Yang C, Zhang H, Zheng L, Tong Q. Laparoscopic versus open pyeloplasty for ureteropelvic junction obstruction in children: A systematic review and meta-analysis. *Journal of Endourology*. 2011;**25**:727-736
- [38] Thom MR, Haseebuddin M, Roytman TM, Benway BM, Bhayani SB, Figenshau RS. Robot-assisted pyeloplasty: Outcomes for primary and secondary repairs, a single institution experience. *International Braz J Urol*. 2012;**38**:77-83
- [39] Atug F, Burgess SV, Castle EP, Thomas R. Role of robotics in the management of secondary ureteropelvic junction obstruction. *International Journal of Clinical Practice*. 2006;**60**:9-11
- [40] Hemal AK, Mishra S, Mukharjee S, Suryavanshi M. Robot assisted laparoscopic pyeloplasty in patients of ureteropelvic junction obstruction with previously failed open surgical repair. *International Journal of Urology*. 2008;**15**:744-746
- [41] Lindgren BW, Hagerty J, Meyer T, Cheng EY. Robot-assisted laparoscopic reoperative repair for failed pyeloplasty in children: A safe and highly effective treatment option. *The Journal of Urology*. 2012;**188**:932-937
- [42] Niver BE, Agalliu I, Bareket R, Mufarrij P, Shah O, Stifelman MD. Analysis of robotic-assisted laparoscopic pyeloplasty for primary versus secondary repair in 119 consecutive cases. *Urology*. 2012;**79**:689-694
- [43] Desai MM, Berger AK, Brandina R, et al. Laparoendoscopic single-site surgery: Initial hundred patients. *Urology*. 2009;**74**:805-812
- [44] White WM, Haber GP, Goel RK, Crouzet S, Stein RJ, Kaouk JH. Single port urologic surgery: Single center experience with the first 100 cases. *Urology*. 2009;**74**:801-804
- [45] Cestari A, Buffi NM, Lista G, et al. Feasibility and preliminary clinical outcomes of robotic laparoendoscopic single-site (R-LESS) pyeloplasty using a new single-port platform. *European Urology*. 2012;**62**(1):175-179
- [46] Buffi NM, Lughezzani G, Fossati N, et al. Robot-assisted, single-site, dismembered pyeloplasty for ureteropelvic junction obstruction with the new da Vinci platform: A stage 2a study. *European Urology*. 2015;**67**:151-156
- [47] Zhao LC, Weinberg AC, Lee Z, et al. Robotic ureteral reconstruction using buccal mucosa grafts: A multi-institutional experience. *European Urology*. 2018;**73**:419-426

[48] Ahn JJ, Shapiro ME, Ellison JS, et al. Pediatric robot-assisted redo pyeloplasty with buccal mucosa graft: A novel technique. *Urology*. 2017;**101**:56-59

[49] Zampini AM, Nelson R, Haijing Zhang JJ, et al. Robotic salvage pyeloplasty with buccal mucosal onlay graft: Video demonstration of technique and outcomes. *Urology*. 2017;**110**:253-256

[50] Lee Z, Moore B, Giusto L, Eun DD. Use of indocyanine green during robot-assisted ureteral reconstructions. *European Urology*. 2015;**67**:291-298

[51] Diana P, Lughezzani G, Maffei D, et al. Intraureteral indocyanine green in robot-assisted re-do pyeloplasty for recurrent ureteropelvic junction obstruction. *European Urology Supplements*. 2019;**18**:e2730. DOI: 10.1016/S1569-9056(19)32827-1

[52] Cinman NM, Okeke Z, Smith ADJ. Pelvic kidney: Associated diseases and treatment. *Endourology*. 2007;**21**:836-842