

Sentinel lymph node biopsy using indigocyanine green fluorescence in uterine cancer

Looser G-L., Welter J., Sell W., Lorenz K., Fehr M.K.

Gynecology and Gynecological Oncology, Cantonal Hospitals Frauenfeld and Münsterlingen, Switzerland

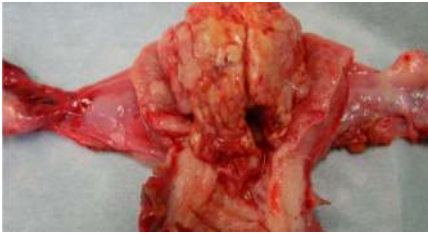

Fig. 1: Endometrioid endometrial cancer, G3, FIGO IB

Introduction

In endometrial cancer, societies such as the Society of Gynecological Oncology and National Comprehensive Cancer Network recommend sentinel lymph node biopsy using indigocyanine green (ICG-SLNB) as a reasonable staging strategy. According to a meta-analysis, ICG as a tracer injected into the cervix yields higher detection rates than other tracers or other injection sites. Compared to standard systematic lymphadenectomy (LND), ICG-SLNB has lower morbidity, allows detection of lymph nodes in atypical locations, such as the presacral and parametrial areas, and allows for microstaging of lymph nodes assessed by systemic lymphadenectomy.

Material and Methods

We did a retrospective analysis of 45 patients who had ICG-SLNB for uterine cancer using conventional laparoscopy or robotic surgery from 2012 to 2019. ICG was injected into the cervix, 1ml subepithelial and 1ml into the stroma at both 3 and 9 o'clock. Two different optical systems were used: Karl Storz Opal-1 NIR/ICG (n=10) and Novadaq Pinpoint (n=35). Pathological ultrastaging was done by sampling the SLN at 2mm intervals with additional cytokeratin staining. Number of technical failures, detected sentinel nodes and their location was assessed. Technical failures were defined as no lymph node staining or only unilateral pelvic staining. We also compared sites of lymph node metastasis using ICG-SLNB to 10 endometrial cancer patients having metastatic lymph nodes assessed by systematic lymphadenectomy.

Results

A total of 353 lymph nodes were detected, of which 22 (6%) were metastatic. Six percent of SLN were found in atypical locations. Seven women (16%) had SLN in atypical locations (3 in parametrium only and 4 in the presacral only).

Anatomic site of SLN	Number SLN	Number of metastatic SLN
Obturator fossa	141 (40%)	16
External iliac vessels	87 (25%)	3
Common iliac vessels	50 (14%)	1
Paraortic	54 (15%)	2
Parametrial	9 (3%)	0
Presacral	12 (3%)	0

	Pinpoint (n=35 patients)	Opal-1 (n=10 patients)	p-value
Technical failures	4 (11%)	3 (30%)	0.17
Median number of SLN detected per patient (range)	11 (2-18)	2.5 (1-6)	0.002

Site of metastasis	Pelvis only	Paraaortal only	Pelvic and Paraaortal
ICG-SLNB (n=6 patients)	4	0	2
Systematic lymphonodectomy (LND) (n=4 patients)	2	0	2

Discussion

The imaging device has an impact on the number of sentinel nodes detected and the technical failure rate. Sixteen percent of patients had SLN in atypical locations, however none had metastatic disease. The pattern of nodal spread was similar in both ICG-SLNB and systematic LND, which is reassuring.

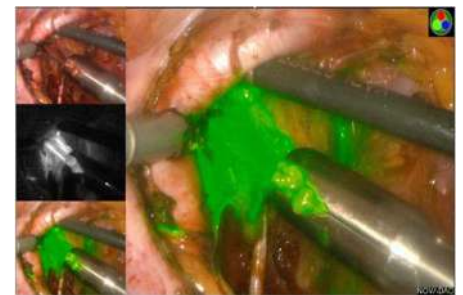


Fig. 2: ICG-staining of lymphatic conglomerate in the obturator fossa

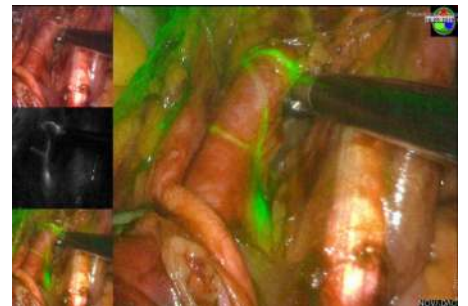


Fig. 3: ICG-staining of lymphatic vessels around the common iliac vessels

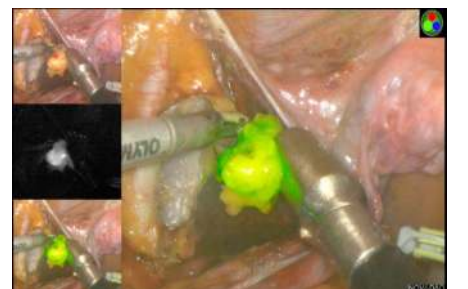

Fig. 4: Excellent discrimination between fatty tissue und lymph nodes in the parametrium