

---

# Challenges in the Surgical Treatment of Rectal Prolapse

---

Renato Pietroletti

Additional information is available at the end of the chapter

<http://dx.doi.org/10.5772/intechopen.78059>

---

## Abstract

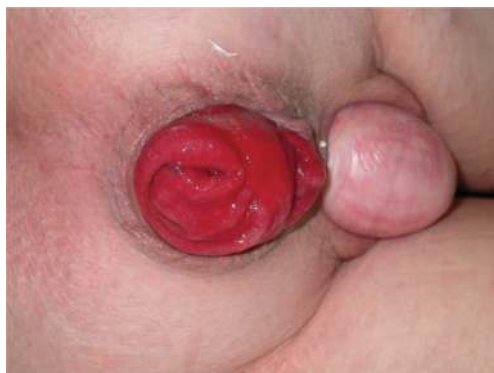The approach to a patient with overt rectal prolapse remains controversial since the choice of the most appropriate technical option may be a difficult task. The different approaches are based upon patients' age, comorbidities, sex, size of prolapse, associated incontinence, constipation, and urinary and genital disturbances. However, analysis of the literature failed to detect a significant evidence favoring one among the large number of those different surgical techniques proposed for the treatment of rectal prolapse. In fact, many randomized prospective controlled trials, comparing perineal and abdominal operations, rectopexy alone, resection alone and/or resection plus rectopexy could not find significant differences in terms of morbidity, mortality, improvement of incontinence or constipation, quality of life and recurrence. Therefore, without a clear-cut support by the literature, a pragmatic approach is necessary, applying common sense, experience and considering the availability of resources as well. Nevertheless, we may expect that definitive answers to many open questions about surgery of rectal prolapse may come from larger studies and longer follow-up.

**Keywords:** rectal prolapse, surgery, abdominal, perineal, procedure

---

## 1. Introduction

The complete prolapse of the rectum is a true intussusception of the viscus outside of the anus, through the sphincters. Aged multiparous women are mainly affected, even if earlier observations reported a significant incidence in nulliparous or psychiatric patients [1, 2]. In males, the rectal prolapse tends to appear in younger patients, but in any patient, a history of chronic constipation and excessive straining is reported. Some anatomical abnormalities represent predisposing factors of rectal prolapse and many other are a consequence of the prolapse itself [3]. Abnormally lax attachments of the rectum to the sacrum and to lateral pelvic walls, a deep



**Figure 1.** Complete prolapse of the rectum involving also mid-anterior compartments.

peritoneal pouch between rectum and vagina or bladder are invariably observed. Consequently, the long-standing stretching in pelvic structures will result in other associated abnormalities which affect also the anterior and middle compartments, depicting the so called “tetralogy of fall-out syndrome” (**Figure 1**). Genital prolapse, urinary incontinence, perineal descent, levator diastasis, patulous anus and finally pudendal nerve stretch with consequent neuropathy and anal sphincter weakness are frequently observed, either alone or in combination. The attempts to explain the etiology of rectal prolapse generated several different theories, all looking at one or more of the observed anatomical defects as the main abnormalities predisposing to rectal prolapse and thus proposing a specific surgical treatment. A typical example is represented by the theory of the sliding hernia by Moscovitz [4], who proposed the suturing of the deep pouch of Douglas as a targeted surgical therapy. Instead, the cineradiographic studies of Broden and Snelleman [5] identified the cause of rectal prolapse in a complete recto-rectal intussusception. In those patients complaining of chronic constipation (the vast majority), this symptom may be accompanied by impaired intestinal transit time, dolichocolon, redundant sigmoid colon or a true sigmoidocele. The latter one can be also the cause of a severe obstructed defecation. All these mentioned conditions may complicate and worsen the clinical picture of a complete rectal prolapse and must be taken into consideration, in planning surgical treatment.

Overt rectal prolapse is a disabling and embarrassing condition since the quality of life of the patient is marred by symptoms such as mucus discharge, true incontinence, bleeding, obstructed defecation and although rarely, pain. Not to mention the occurrence of complications such as massive bleeding, ischemia or incarcerated prolapse all requiring emergency abdominal surgery leading almost invariably to intestinal stoma.

## 2. Prolapse in children

Regardless of sex, rectal prolapse is reported rarely in children older than 3 years of age and is uncommon in western countries. The rectal prolapse in children is mostly due to either excessive straining at defecation or because of an acute respiratory disease [6] such as pertussis. Usually,

	Patients (no.)	Results (%)
Sclerosing injection	414	83–100
Anal encirclement	40	97–100
Presacral packing	100	100
Linear cauterization	73	97
Rectopexy	8	100

**Table 1.** Treatment results of rectal prolapse in children, data from the literature.

it is represented by a simple prolapse of rectal mucosa and conservative treatment has a great percentage of success, as soon as the children grow. In case of failure, different procedures could be indicated, the simplest one being represented by injection sclerotherapy. However, if surgical treatment is needed, we can rely upon a great number of different operations, similarly to an adult patient. **Table 1** summarizes different treatments and results in pediatric patients.

### 3. Complete rectal prolapse in adult

Kairaluoma [7] estimated the annual prevalence of rectal prolapse in the adult population in about 2.5/100.000 affecting more commonly women than men [8]. Childbirth, straining at stool, anatomical abnormalities and progressive laxity of rectal attachments, also related to menopausal, hormonal changes can represent etiologic factors and account for the increasing frequency of complete rectal prolapse observed with age progression in females. In males, on the contrary, the peak of incidence is around 30–40 years of age. As said earlier, following the cine-radiographic studies of Broden and Snelleman, the anatomical defect causing complete prolapse of the rectum is represented by a true recto-rectal intussusception. Among the other anatomical abnormalities, the observation of a deep peritoneal pouch, supporting early pathogenetic hypothesis of complete rectal prolapse being as a sliding hernia, is a complementary defect. Instead, this anatomical abnormality together with the pelvic floor deficiency, the genital descent and urinary disturbances, all represent a consequence of the continuous straining of the rectum. Therefore, apart from the occurrence of prolapse, not rarely the patient complains of many other symptoms of pelvic floor failure, the main one being fecal incontinence. Interestingly, continence improvement after surgical treatment of rectal prolapse is reported in up to 77% of the cases in the experience of various authors. [1–3, 8]

From the clinical point of view, the most common complaint is related to the presence of the prolapse itself, sometime reported as feeling of a balloon or a foreign body in the perineum. Tenesmus, mucous discharge, or true fecal incontinence, together with symptoms of obstructed defecation, almost invariably complete the clinical picture. If the prolapse is not appearing spontaneously, the patient must be asked to strain, either in the left lateral or in the squatting position. Alternatively, we could ask the patient to take a picture of the prolapse at its maximal descendent by himself using a smartphone. The author says that a lot of patients already found this method of reporting of such symptoms of friendly use (**Figure 2**).



**Figure 2.** Self-reporting by a patient herself of rectal procidentia at maximum extent, with photograph.

As far as physical examination is concerned, a full thickness rectal prolapse will appear as a cylinder of bowel with its concentric, symmetric folds. Conversely, a simple mucosal prolapse appears with its irregular, mainly radiated mucosal folds. To confirm the diagnosis of full thickness rectal procidentia, it is mandatory to palpate accurately the prolapse; this is to be done with the thumb inserted in the lumen of the prolapsed bowel and the first and second fingers on the external aspect, firmly grasping the bowel wall. In this way, the double thickness of the prolapsing bowel is easily recognizable. At the same time, by means of gentle pressure, the rectum can be squeezed back and repositioned inside the pelvis.

Before surgical treatment is planned, a complete diagnostic screening is needed and should be addressed to investigate continence, colon and rectum imaging, associated organs prolapse. In patients with a reasonably long life expectancy, it is mandatory the control of any co-existing functional bowel disorder, since a complete anatomical cure of the prolapse is not to be counter-balanced by a poor quality of life, related to bad bowel function.

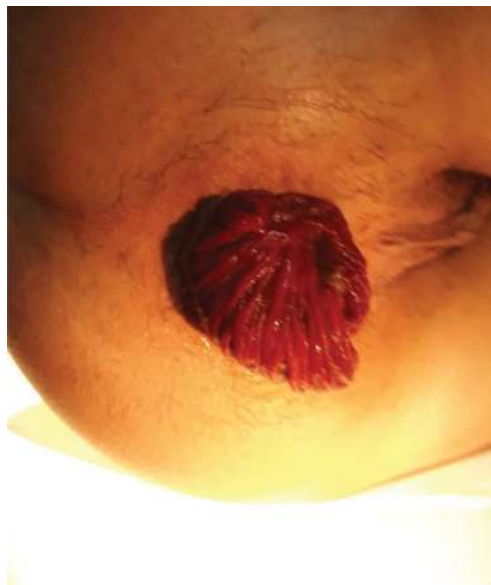Colonoscopy is invariably needed to exclude other diseases also in view of patients' age. Anorectal manometry, although with its limitations, can be useful particularly when coupled with trans anal ultrasound, the latter aimed to detect sphincter lesions especially in a multiparous woman. In addition, one of the recently developed continence questionnaire with a scoring system can be of utmost importance for grading incontinence and for follow-up purposes [9, 10].

As for imaging studies, contrast enema may depict the redundant sigmoid colon and a multi-contrast proctography may detect the associated abnormalities of the pelvic floor. In this respect, pelvic MRI or MRI defecography [11] may replace, in expert hands, conventional

radiographic studies, detecting at the same time the involvement of pelvic organs other than rectum [12] However, conventional multicontrast defecography appears superior in diagnosing rectocele or enterocele [13]. Radiographic transit time studies might be indicated in case of severe, longstanding constipation, in order to rule out delayed transit of the whole colon with consequent implications of surgical treatment.

The correlation between rectal prolapse and chronic psychiatric diseases has been often reported [1–3]. In recent years, such association became even more evident although ill-understood; autism [14] and other forms of behavioral abnormalities are often observed in rectal prolapse, contributing to poor outcome in case of surgical treatment [15, 16]. In addition, an emerging behavioral abnormality such as anorexia nervosa is found to be not rarely complicated by rectal prolapse [17]. All the spectrum of eating disorders, when coupled with laxative abuse, rectal purging, forced defecation and excessive straining may lead to overt rectal prolapse [18, 19]. Such aspects deserve a particular attention and they need to be fully evaluated before surgery is planned.

Finally, a few considerations are due to the complete prolapse of an ileal pouch. In the large experience of the Cleveland Clinic, pouch prolapse after ileo-anal procedure has been reported in 0.3% of the patients [20]. Since pouch surgery is becoming more and more popular, we might expect a rise in its incidence. **Figure 3** shows a complete prolapse of a pouch, in a patient after total proctocolectomy for complications of Hirschsprung disease. Treatment of this condition may be challenging and preferably conducted by means of abdominal, mesh pouch-pecty, however not rarely ending in pouch loss and permanent stoma [20, 21].



**Figure 3.** Complete prolapse of an ileal pouch.

## 4. Principles of surgical treatment

The history of the surgical treatment of rectal prolapse is rich of several, different surgical techniques, all proposed with the aim of eliminating the anatomical defect which was believed to be the main responsible for the prolapse. According to Kuijpers [22], the literature reports a list of authors who proposed to treat the prolapse by means of different techniques; encircling the anus, or plicate or resect the prolapse, or to suspend and/or fix it or to wrap with foreign material.

Such wide variability of surgical approach may be related to the leading theory born in the mind of the surgeon about the pathogenesis of the prolapse; the strong believe in a specific anatomical defect of pelvic floor as the main responsible of the rectal prolapse, represented the milestone suggesting the development of targeted operations, each focused on that anatomical abnormality. In addition, different categories of patients were encountered in clinical practice as far as age, sex, associated illnesses is concerned. They need a personalized treatment, especially in terms of low morbidity/mortality and less invasive procedures for an aged and risky patient. In recent times however, the full understanding of rectal prolapse pathophysiology has eliminated the debate around several, obsolete surgical procedures, practically abandoned. Nonetheless, still some controversial issues exist on a handful of operations commonly performed, referring in particular to the choice of abdominal versus perineal approach. In the vast majority of cases, we are approaching complete rectal prolapse in a geriatric patient with associated illnesses, not rarely in the ASA status III or IV; only a small amount of individuals is represented by a young patient, in good physical conditions. In addition, we should take into account that the various anatomical defects accompanying (not causing!) rectal prolapse need to be treated anyway, possibly at the same time; last but not least, we must pay attention to all the associated symptoms (fecal incontinence, constipation, urinary incontinence, sexual disturbances), planning treatment and adequate follow-up in an “holistic” approach.

We may conclude that the ideal surgical treatment for correction of the rectal prolapse should be mini-invasive, with low morbidity, almost nihil mortality and a reasonable percentage of recurrence.

Due to the clinical characteristics of majority of the patients, as mentioned earlier, it is not surprising that perineal procedures have been developed and became quite popular with respect to more invasive abdominal operations. Therefore, the choice is debated between abdominal approach and perineal procedure taking into consideration factors other than age and performance status of the patient.

## 5. Perineal operations

The simplest contentive treatment of the rectal prolapse was represented by a suture encircling the anus. The original procedure was that one proposed by Tiersch (**Figure 4**), encircling the anus with a wire. Other modifications of the original technique involved the use of different material such as silicone, mesh, silastic rings or Angelchik prosthesis. Results are poor

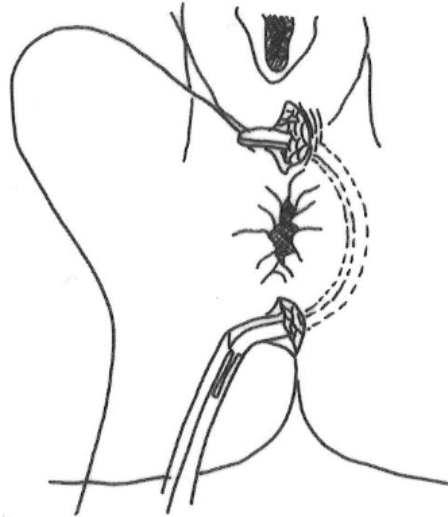


Figure 4. The anal encirclement procedure according to Tiersch.

and complications are frequent therefore these methods have been abandoned and herein are reported for completeness.

Edmonde Delorme, a French military surgeon, described the procedure of prolapse mucosectomy and plication of rectal wall [23]. The procedure is not invasive and becomes quite popular especially in Europe with good result in terms of morbidity, mortality and recurrence (Table 2).

Deaths are rarely reported, postoperative morbidity is represented mainly by bleeding, anal stricture may be observed as late sequelae. Recurrence varies between 5 and 26% with a mean value of 12–15%. Interestingly, adding a pelvic floor repair to Delorme's operation improves results in terms of continence and recurrence [24]. Our policy is to perform posterior levatorplasty routinely after a Delorme's procedure [25] with the aim of restoring a correct anorectal angle [26], increasing the height of the anal canal. This sort of anatomical restoration contributes to improve continence and reduces recurrence in our experience. In a recent study by Youssef [27], patients with rectal prolapse were randomly assigned to Delorme's operation or Delorme plus levatorplasty. The author reported improved continence and less recurrence in the group treated with levatorplasty respect to Delorme alone, thus confirming the rationale of levatorplasty as a fundamental tool in improving clinical results of Delorme's. This is confirmed in a retrospective, long-term follow-up study showing 9.9% actuarial incidence

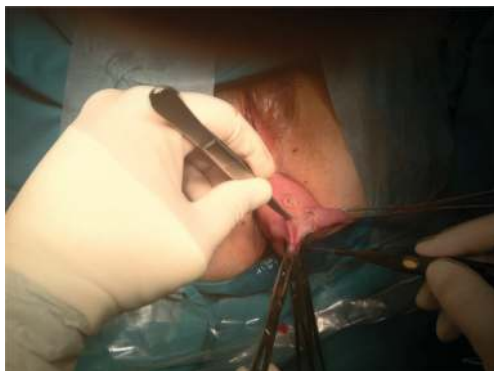No. of pts.	Mortality (%)	Recurrence (%)
414	0–1.2	5–26

Table 2. Results of Delorme's operation: cumulative data from the literature.

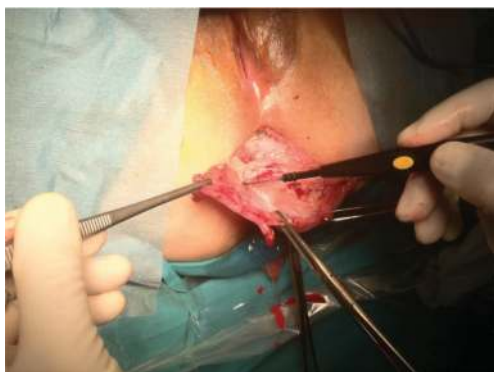of prolapse recurrence. The absence of levatorplasty and the presence of constipation represented the risk factors [28].

The operation is carried out in lithotomy position, either in spinal or even local anesthesia. After infiltration of prolapsed rectum submucosa with diluted adrenaline (1:250,000 w/v) or epinephrine, the mucosa is stripped off starting 1 cm away from the dentate line, to the apex of the prolapse. Accurate hemostasis of rectal wall is achieved by diathermy. Following this, the rectal wall is plicated similarly to a concertina, by means of six to eight (The author prefers eight) longitudinal sutures taking four to five bites of rectal wall and then tied. The plicated prolapse is repositioned and the operation is terminated by suturing proximal rectal mucosa to the dentate line. As stated earlier, the posterior levatorplasty completes the procedure. The procedure is outlined in **Figures 5–10**.

This operation represents the ideal surgical treatment for those patients unfit for other more invasive procedures. Even if recurrence rate is not negligible, the operation is repeatable with a high chance of success [29] (**Table 3**).

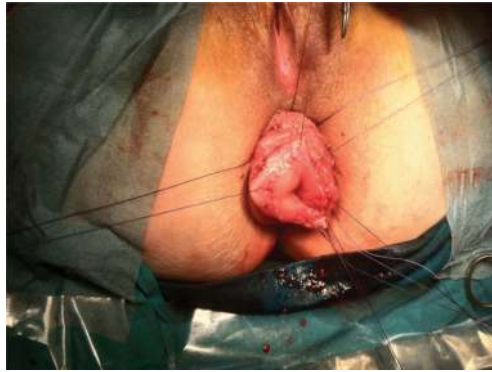

**Figure 5.** Mucosectomy of the rectal prolapse.

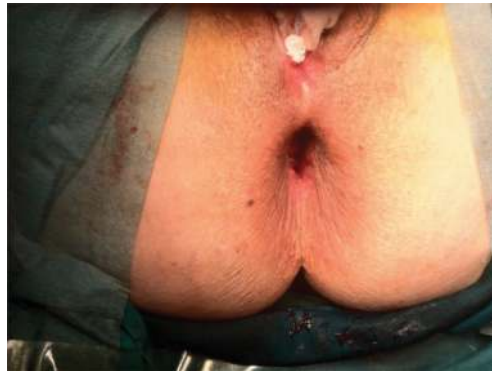

**Figure 6.** Mucosectomy is carried out by diathermy with careful hemostasis.

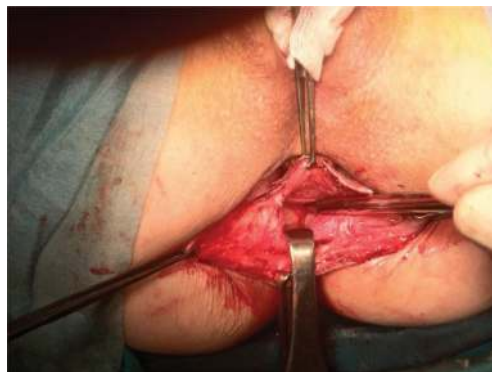



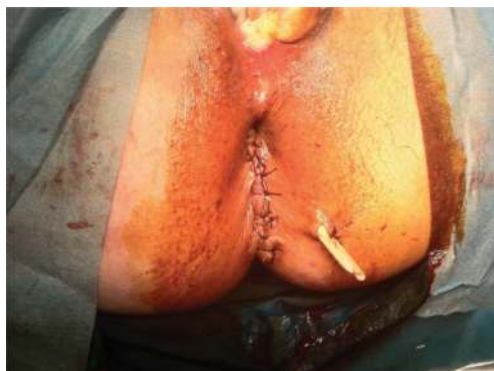**Figure 7.** Plication of the prolapse with longitudinal sutures.



**Figure 8.** Patulous anus at the end of the procedure.



**Figure 9.** The two branches of levator muscles are identified for levatorplasty.



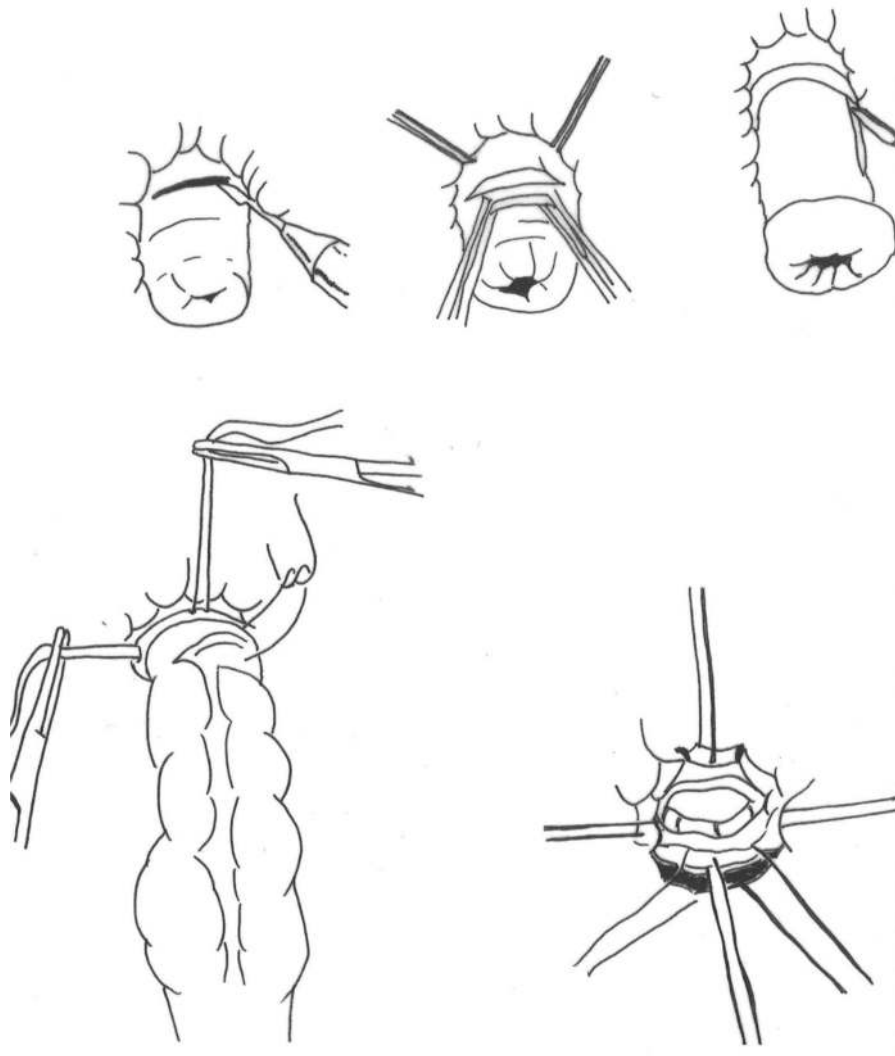
**Figure 10.** Posterior levatorplasty restores correct ano-rectal angle.

		Mortality	Morbidity	Recurrence	Improved continence	Comments
No. of pts	▪ 62					3 males
Median age	78 years (27–92)					1 pouch prolapse
Delorme	▪ 46 ▪Associated levatorplasty in 26	0	1*	3	28*	* Minor bleeding ** 26 delorme + levatorplasty
Resection rectopexy	12	0	2^	0	12	^ Sub-occlusion
Rectopexy	1	0	0	1	0	
Total	59 operated pts.°	0	3	4	40	° 2 pts. and 1 pouch prolapse operated elsewhere

**Table 3.** Surgery of complete rectal prolapse—author's personal experience.

Perineal rectosigmoidectomy was firstly described by Altemeier [2]. The procedure combines different advantages but also shows some weak points. In first place, the prolapsed rectum is excised, the deep peritoneal pouch is shortened and closed and finally, pelvic floor muscles can be repaired. It is therefore attractive to achieve such an extensive anatomical correction by means of a perineal operation, in a patient considered unfit for major abdominal surgery. Coming to the weak points however, recurrence is still a problem with its incidence varying from 3–43% [3, 8]. Moreover, incontinence may persist due to the loss of reservoir function following rectal resection. The operation can be performed in lithotomy or jack-knife positions, in spinal or preferably under general anesthesia with complete muscle relaxation. The rectal prolapse is attracted outside of the anus and a full thickness cut is made transversely at the level of the dentate line. The sigmoid colon is delivered through the incised peritoneum of the deep pouch of Douglas, the sigmoid

vessels in the mesentery ligated and divided and then the proximal section of the prolapse is accomplished. At this time, the muscle fibers of the levator ani become evident anteriorly and may be plicated. Subsequently, the posterior aspect of the prolapse is approached and having divided the rectal wall, the mesorectum and puborectal sling become apparent. At this stage, plication of the puborectal muscle can be easily performed and after ligation of mesorectal vessels the prolapsed rectum with distal sigmoid colon is removed. The anastomosis between the resected proximal sigmoid and the dentate line is performed with interrupted sutures. Technical principles are depicted in **Figure 11**.



**Figure 11.** The Altemeier procedure depicted through the main stages.

No. of pts.	Mortality (%)	Recurrence (%)
738	0–6	0–50

**Table 4.** Results of Altemeier operation: cumulative data from literature.

In the case of Altemeier procedure too, in the experience of various authors, the pelvic floor repair improves the results of the operation either in terms of continence and recurrence rate [30, 31]. Modifications of the original technique include the use of mechanical circular stapler for the coloanal anastomosis, and the fashioning of a colonic pouch [8, 32]. In addition, pouch proctosigmoidectomy too showed to be superior to conventional Altemeier operation in terms of functional results (**Table 4**).

Pelvic floor repair alone and perineal rectopexy have to be mentioned among the perineal procedures employed for the treatment of rectal prolapse. However, they have been completely abandoned since their results showed to be very disappointing [8].

## 6. Abdominal procedures

Whenever possible (i.e. young, fit patients) an abdominal procedure should be preferred for treating rectal prolapse, in view of overall better results. The abdominal approach allows to treat the main defect simultaneously with other anatomical abnormalities. In fact, full mobilization of the rectum and fixation to the sacrum leaving lateral ligaments, thus preserving rectal innervation, guarantees from further intussusception. In addition, a deep peritoneal pouch can be repaired together with levator diastasis and should colonic resection be indicated, it may be easily accomplished via a laparotomic/laparoscopic approach. Not to mention the possibility of treating uterine or vaginal prolapse, bladder descent or anomalies of urethrovesical angle. Finally, the abdominal approach does not preclude the possibility of combining a perineal operation when needed; for instance, in presence of a large rectocele or vaginal prolapse a colpoperineorrhaphy or rectocele repair are easily approached from below.

All the abdominal procedures carry a slightly higher morbidity and mortality with respect to perineal operations, thus selection criteria are of utmost importance, considering the benign nature of the disease. In a propensity matched cohort of patients with comparable surgical risk status, no differences were found in terms of morbidity and mortality between perineal and abdominal operations [33], thus the progresses in anesthesiology, surgical techniques and technology and postoperative care make abdominal approach rather safe even in risky patients [34, 35].

### 6.1. Abdominal rectopexy

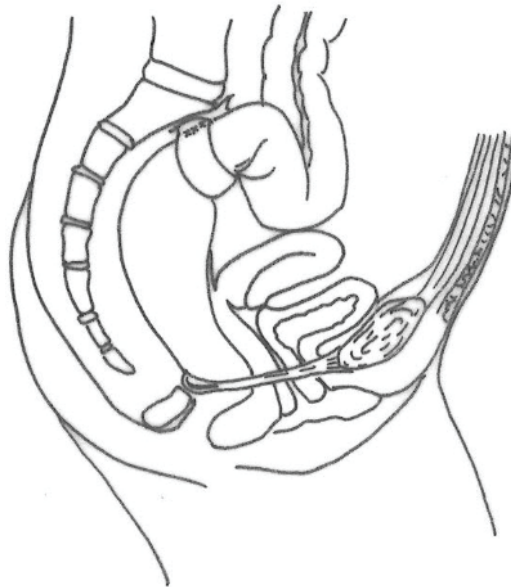
To date, little doubt exists in considering abdominal rectopexy as the gold standard in treating rectal prolapse in view of the very low (less than 2%) recurrence rate. The debate is rather moved on to the method of fixation (absorbable/non-absorbable suture, mesh of foreign material), the position of the mesh on the rectum (anterior, posterior), the fixation of the mesh (posterior or lateral) and finally whether or not a colonic resection should be performed.

The earlier method of anterior rectopexy was that one developed by Ripstein [36] who attached the rectum after full mobilization, to the promontory of the sacrum by means of a sling of foreign material passing anteriorly (**Figure 12**), with the aim of fixing the rectum by a dense fibrous reaction. Not surprisingly the consequent scar tissue encircling the rectum was responsible for the development of stricture and obstructive complications (7–17%) and/or intractable constipation in up to 43% of the cases [3, 8]. Interestingly, Scaglia [37] reported a far low incidence of postoperative constipation when preserving lateral ligaments during rectal mobilization. As said earlier, leaving the rectal innervation untouched, by means of careful preservation of lateral attachments, guarantees a normal rectal sensation and therefore risks of postoperative constipation can be minimized.

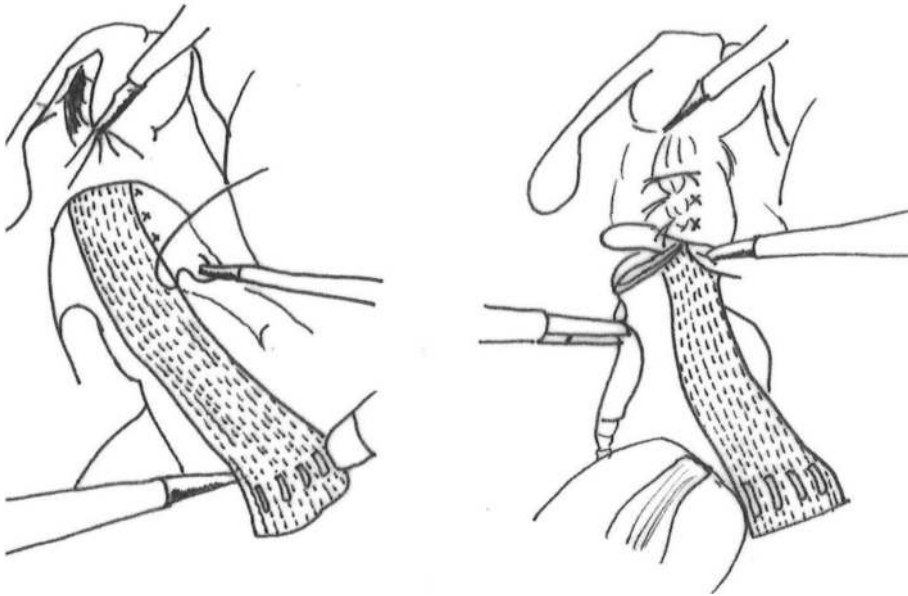
Recently D'hoore [38] developed a new method of anterior rectopexy which seems to obviate the troubles of the Ripstein rectopexy. The rectum is mobilized and the dissection is deepened anteriorly. A mesh is then sutured to the anterior rectal wall and tractioned up in order to be fixed to the promontorium of the sacrum. Closure of the peritoneum completes the procedure (**Figure 13**). Results of this interesting type of anterior rectopexy, performed laparoscopically in the vast majority of the cases, or even with the help of robotic surgery are reported in **Table 5** and are quite encouraging [39, 40].

However also in this case, similarly to other comparative studies, results from a randomized protocol comparing laparoscopic, ventral mesh recto-pxy and Delorme's operation, failed to obtain significantly better results of one procedure over the other [41].

Some technical aspects are emerging from the literature and deserve consideration; in a female patient, the deep anterior dissection of the rectum from the vagina does not carry particular risks.



**Figure 12.** The Ripstein procedure, with the prosthesis anchoring the rectum anteriorly.



**Figure 13.** Laparoscopic suturing of the mesh on the anterior face of the rectum; peritoneization concludes the procedure.

n. of patients	251
Mean age	68 years
Follow-up	19–42 months
Mortality	0%
Morbidity	0–23.5%
Recurrence	2–5.8%
Improvement of incontinence	>80%
Improvement of constipation	>80%

**Table 5.** Cumulative data from literature of results in laparoscopic ventral mesh rectopexy (LVR).

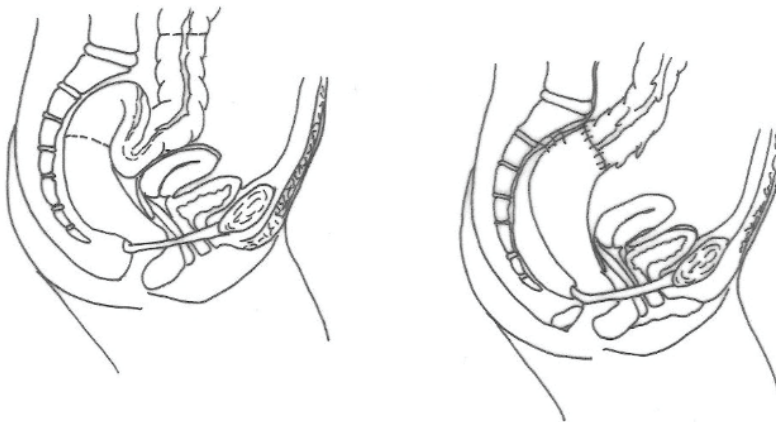
In a male however, the deep anterior dissection of the rectum from seminal vesicles and prostate may be more challenging and even if it seems to be safe in terms of incidence of postoperative complications such as sexual disturbances (impotence, retrograde ejaculation) [42], unwilling problems in a young patient, reoperation rate has been reported to be not negligible [43], with 33% further surgery either due to persistent or recurrent prolapse. Other concerns may arise as far as mesh use in rectal surgery and in fact a new type of postoperative morbidity has been observed in case of ventral mesh rectopexy, that is mesh erosion. Evans reported 2% mesh erosion treated by mesh removal [44]. Borie also treated by means of mesh removal, the 7 patients complaining of mesh erosion out of 149 treated with laparoscopic ventral mesh rectopexy [45]. He found no worsening of functional symptoms. In conclusion, although of limited incidence and good prognosis, mesh erosion is a problem to be dealt with in case of laparoscopic ventral mesh rectopexy.

## 6.2. Resection and rectopexy

Resection alone gained a certain popularity, especially in the USA [46, 47] but the debate must be addressed to two main aspects, strictly correlated: in first place, it seems that in order to obtain adequate cure and low recurrence rate, the colon resection has to be wide, such as true anterior resection of the rectum with all the well-known technical difficulties not rarely encountered in such a demolitive operation (blood supply after ligation of inferior mesenteric artery, full mobilization of splenic flexure). This originates consequently, serious concerns about morbidity and mortality due to anastomotic and general complications; 3.5% mortality and 50% rate of septic complications are thrilling enough to move the majority of surgeons to a safer operation other than anterior resection, when a resective procedure is indicated.

Resection-rectopexy is also known as the Frykman-Goldberg [48] operation and is a sigmoid resection with sutured rectopexy to the sacrum (**Figure 14**).

There are strong evidences that this operation may be a very good choice for a young, fit patient [49]. In fact, it cures the prolapse with a very low recurrence, does not worsen incontinence, improves constipation, and allows the correction of other pelvic floor anomalies at the same time (**Table 6**).



**Figure 14.** Sigmoid resection and sutured rectopexy according to the standard technique.

n. of patients	360
Mortality	0.8–2%
Morbidity	0–23%
Recurrence	0–9%
Improvement of incontinence	>85%
Improvement of constipation	>90%

**Table 6.** Cumulative data from literature of results in resection-rectopexy.



Since constipation, either in term of its persistency or “de novo” occurrence represents a major concern, leading to bad quality of life and probably being responsible for recurrence of prolapse, it is obviously attractive the idea of eliminating such problem with a safe resection such as a sigmoidectomy combined with rectopexy. A large amount of data from literature are now supporting the evidence that rectopexy alone might be responsible for severe post-operative constipation.

## 7. Choice of the best surgical option

Given so many variables in patient’s selection, the best surgical option is still a case by case choice, highly dependent on surgeon’s discretion and experience. In general, if the prolapse is short, not more than 4–5 cm up to 6–7 cm, the choice of a perineal operation is reasonable. Whereas in case of large prolapse measuring 10–15 cm it seems advisable an abdominal approach, preferably resection rectopexy. Unfortunately, if we search in the literature for supporting evidence, we cannot obtain conclusive data. In fact, in the last 20 years, two Cochrane systematic reviews were unable to draw any significant conclusion comparing different surgical techniques for the treatment of complete rectal prolapse [50, 51]. The final comment of the authors was that quality of papers was low, number of patients was inadequate and several methodologic bias were present. In a well-designed multicenter trial, the PROSPER trial, Senapati [52] tried to give answers to many open questions of surgical treatment of complete rectal prolapse. 340 patients were randomized to abdominal or perineal operation and subsequently each group further randomized to rectopexy alone or resection-rectopexy and Delorme’s or Altemeier procedures. Quite surprisingly, no differences were found among all the compared operations; incidence of recurrence was similar between abdominal and perineal operations and even between Delorme and Altemeier and rectopexy versus resection/rectopexy. Also in all the other parameters investigated (morbidity, mortality, incontinence, constipation, quality of life), no operation showed to be superior to the others.

Another interesting contribution, come from an international survey by Formjine and Wexner [53]; surgeons from Europe and the USA were asked, by means of a detailed questionnaire, to indicate the preferred choice for rectal prolapse treatment. 391 surgeons from 50 different countries answered and results showed a sort of geographic dichotomy. In case of a high-risk patient the preferred approach was perineal for the majority of surgeons with a little prevalence of Delorme’s operation in Europe with respect to the USA where Altemeier operation is more popular. As far as young patients are concerned, the different approach resulted quite sharp, with the USA more favorable for resection rectopexy and Europeans devoted to the newly developed ventral mesh rectopexy. This difference may be explained with the recent limitations of FDA for the use of prosthetic material in pelvic surgery, particularly in urogynecologic use. Quite interestingly a similar duality is observed also for internal rectal prolapse causing obstructed defecation. When operation is indicated, resection rectopexy is the choice of American surgeons, whereas in Europe the stapled transanal rectal resection (S.T.A.R.R. and Tran-S.T.A.R.R.) is favored. Also in this case, the recommendation concerning the risk of potentially severe complications of the two mentioned procedures, particularly in nonspecialist settings, prompted a prudent approach among American surgeons [54, 55].



## 8. Recurrent prolapse

The same principles applied for the treatment of complete rectal prolapse, can be employed for successful treatment of recurrences. Dedicated surgeons have to be familiar with the approach to recurrent rectal prolapse since its incidence is not negligible, especially when a perineal operation is performed. Unfortunately, data from the literature do not give substantial support to the surgeon [56]. However, recent studies seem to indicate that resection rectopexy results in less than 10% recurrence rate [57], the progress in intra and postoperative care make resection rectopexy safe even in high-risk patients and we must consider that the literature reports a nearly 100% success for the treatment of recurrent prolapse [58]. But then, how can we select the right operation in case of recurrent rectal prolapse? The high chances of success of surgical treatment for recurrent rectal prolapse make us hypothesize that changing of surgical strategy, could address more properly to the right operation, perhaps that one probably indicated at the beginning. However, in case of recurrence, the adoption of the same operation previously performed is not to be disregarded. At the start, an intelligent question to ask to ourselves is related to the blood supply of the remaining bowel. In fact, all those patients who have undergone resection anastomosis may develop ischemia in case of a secondary resection. A good option in case of re-do operation for recurrent prolapse, especially if the length of the prolapsed bowel is no more than 4–5 cm and in presence of a risky patient can be the Delorme's plication. This operation in fact leaves untouched the main arterial flow to the rectum. However, if a suture rectopexy was the former choice, this can be repeated and better accompanied by a sigmoid resection. Steele [59] found in a very large study, that abdominal operations are associated with the lowest incidence of re-recurrence, when treating recurrent rectal prolapse and therefore this should be a preferred choice whenever possible. As a matter of fact, considering the benign nature of the disease, re-do abdominal surgery might be demanding both for the surgeon and the patient. Thus, we may conclude that an abdominal operation has to be considered in case of recurrence if previous operation was fixation rectopexy; if this is the case resection rectopexy is advisable. The same approach is to be considered if recurrent prolapse is more than 5–7 cm and the previous operation was a Delorme. On the contrary, if a repeated Delorme is not successful a third plication procedure can be safely repeated and probably, at this stage, the rectum is shortened enough to be suspended by its vascular pedicle. Obviously, in case of a repeated Delorme operation, it seems wise to add posterior levatorplasty.

## 9. Conclusions

Treatment of complete rectal prolapse remains a surgical dilemma. The complex picture of a full-thickness rectal prolapse needs to be approached in specialized centers, with the adequate case-load of patients. This means that surgical experience and a good amount of common sense are mandatory in order to plan a tailored surgical strategy. The right choice of the most appropriate operation must take into account all the associated anatomical modifications of pelvic floor. Chronic straining at defecation and/or constipation are invariably present in patients with rectal prolapse and thus every effort is to be addressed in investigating such symptoms and treat them. That's why preoperative investigations must be performed with the aim of detecting delayed intestinal transit, voiding disturbances,

sexual troubles, mid compartment anomalies, fecal incontinence, nonrelaxing puborectal muscle. We must take into account that the persistence of a malfunctioning of the bowel will lead to failure of prolapse surgery and poor quality of life. On the other hand, once rectal prolapse is corrected, undertreatment of urogenital anomalies will lead to worsening of their symptoms. For old, risky patients, Delorme operation seems a straightforward approach coupled with posterior levatorplasty with the aim of reducing recurrence and improving continence. Recently, Cavazzoni [60], in a very preliminary study, proposed the implant of Gatekeeper prosthesis after Delorme operation with the aim of improving continence. Those patients with better physical performance are managed preferably by means of an abdominal operation also performed laparoscopically. Many surgeons are adopting laparoscopic, anterior mesh rectopexy, especially in Europe, whereas resection rectopexy remains popular in the USA. The first procedure faces the criticism of mesh erosion and high reoperation rate, especially in male patients, whereas the latter represents a gold standard in terms of low incidence of recurrence and good functional results. In addition, we should consider that due to the improvement of anesthesiology and patient's postoperative care, the standard sigmoid resection with sutured rectopexy can be proposed reasonably also in the older patient. In future, the wider diffusion of robotic surgery [61] may lead to the increasing use of such mini-invasive surgical technique also in abdominal surgery for complete rectal prolapse, with the aim of improving further the results.

## Author details

Renato Pietroletti<sup>1,2\*</sup>

\*Address all correspondence to: [renato.pietroletti@cc.univaq.it](mailto:renato.pietroletti@cc.univaq.it)

1 Department of Clinical and Biotechnological Sciences, University of L'Aquila, AQ, Italy

2 Unit of Surgical Coloproctology, Hospital Val Vibrata, Sant'Omero, TE, Italy

## References

- [1] Goligher JC. Surgery of the Anus, Rectum and Colon. 5th ed. London: Bailliere-Tindall; 1984
- [2] Altemeier WA, Cuthbertson WR, Schowengerdt C, Hunt J. Nineteen years experience with the one stage perineal repair of rectal prolapse. *Annals of Surgery*. 1971;**173**:993-1006
- [3] Keighley MRB, Williams NS. Rectal Prolapse in Surgery of the Anus, Rectum and Colon. 2nd ed. London: WB Saunders; 2007. pp. 794-842
- [4] Moscovitz AV. The pathogenesis, anatomy and cure of prolapse of the rectum. *Surgery, Gynecology & Obstetrics*. 1912;**15**:7-21
- [5] Broden B, Snelleman B. Procidentia of the rectum studied with cineradiography: A contribution to the discussion of causative mechanism. *Diseases of the Colon and Rectum*. 1968;**11**:330-347

- [6] Greenberg DP, Von Konig CH, Heining U. Health burden of pertussis in infant and children. *Pediatric Infectious Disease Journal*. 2005;**24**(suppl 5):S49-S43
- [7] Kairaluoma MV, Kellokumpu IH. Epidemiologic aspects of complete rectal prolapse. *Scandinavian Journal of Surgery*. 2005;**94**(3):207-210
- [8] Mills S. Rectal prolapse. In: Beck DE, Roberts PL, Saclarides TJ, Senagore AJ, Stamos MJ, Wexner SD, editors. *The ASCRS Textbook of Colon and Rectal Surgery*. 2nd ed. New York: Springer; 2011. pp. 549-563
- [9] Jorge JM, Wexner SD. Etiology and management of fecal incontinence. *Diseases of the Colon and Rectum*. 1993;**36**:77-97
- [10] Rockwood TH, Church JM, Fleshman JW, Kane RL, Mavrantonis C, Thorson AG, Wexner SD, Bliss D, Lowry AC. Fecal incontinence quality of life scale: Quality of life instrument for patients with fecal incontinence. *Diseases of the Colon and Rectum*. 2000;**43**(1):9-16
- [11] Piloni V, Tosi P, Vernelli M. MR-defecography in obstructed defecation syndrome (ODS): Technique diagnostic criteria and grading. *Techniques in Coloproctology*. 2013 Oct;**17**(5):501-510. DOI: 10.1007/s10151-013-0993-z Epub 2013 Apr 5
- [12] Lalwani N, Moshiri M, Lee JH, Bhargava P, Dighe MK. Magnetic resonance imaging of pelvic floor dysfunction. *Radiologic Clinics of North America*. 2013;**51**:1127-1139
- [13] van Iersel JJ, Formijne Jonkers HA, Verheijen PM, Broeders IA, Heggelman BG, Sreetharan V, Fütterer JJ, Somers I, van der Leest M, Consten EC. Comparison of dynamic magnetic resonance defaecography with rectal contrast and conventional defaecography for posterior pelvic floor compartment prolapse. *Colorectal Disease*. 2017 Jan;**19**(1):O46-O53. DOI: 10.1111/codi.13563
- [14] Van Heest R, Jones S, Giacomantonio M. Rectal prolapse in autistic children. *Journal of Pediatric Surgery*. 2004 Apr;**39**(4):643-644
- [15] Hill SR, Ehrlich PF, Felt B, Dore-Stites D, Erickson K, Teitelbaum DH. Rectal prolapse in older children associated with behavioral and psychiatric disorders. *Pediatric Surgery International*. 2015;**31**(8):719-724. DOI: 10.1007/s00383-015-3733-9
- [16] Marceau C, Parc Y, Debroux E, Tiret E, Parc R. Complete rectal prolapse in young patients: Psychiatric disease a risk factor of poor outcome. *Colorectal Disease* 2005 Jul;**7**(4):360-365
- [17] Dreznik Z, Vishne TH, Kristt D, Alper D, Ramadan E. Rectal prolapse: A possibly underrecognized complication of anorexia nervosa amenable to surgical correction. *International Journal of Psychiatry in Medicine*. 2001;**31**(3):347-352
- [18] Guerdjikova AI, O'Melia A, Riffe K, Palumbo T, McElroy SL. Bulimia nervosa presenting as rectal purging and rectal prolapse: Case report and literature review. *The International Journal of Eating Disorders*. 2012 Apr;**45**(3):456-459. DOI: 10.1002/eat.20959. Epub 2011 Aug 31. Review
- [19] Mitchell N, Norris ML. Rectal prolapse associated with anorexia nervosa: a case report and review of the literature. *Journal of Eating Disorders*. 2013 Oct 10;**1**:39. DOI: 10.1186/2050-2974-1-39. eCollection 2013

- [20] Joyce MR, Fazio VW, Hull TT, Church J, Kiran RP, Mor I, Lian L, Shen B, Remzi FH. Ileal pouch prolapse: Prevalence, management, and outcomes. *Journal of Gastrointestinal Surgery*. 2010 Jun;**14**(6):993-997. DOI: 10.1007/s11605-010-1194-y
- [21] Changchien EM, Griffin JA, Murday ME, Bossart PW. Mesh pouch pexy in the management of J-pouch prolapse. *Diseases of the Colon and Rectum*. 2015 Apr;**58**(4):e46-e48. DOI: 10.1097/DCR.0000000000000337
- [22] Kuijpers JHC. Treatment of complete rectal prolapse: To narrow, to wrap, to suspend, to fix, to encircle, to plicate or to resect? *World Journal of Surgery*. 1992 Sep-Oct;**16**(5):826-830
- [23] Delorme E. Sur le traitement des prolapses du rectum totaux par l'escission de la muqueuse rectale ou rectocolique. *Bulletin et Mémoires de la Société des Chirurgiens de Paris*. 1900;**26**:499-518
- [24] Lechaux JP, Lechaux D, Perez M. Results of Delorme's procedure for rectal prolapse: Advantages of a modified technique. *Diseases of the Colon and Rectum*. 1995;**38**:301-307
- [25] Pietroletti R, Cianca G, Maggi G, Leardi S, Simi M. Trattamento chirurgico del prolasso del retto: interventi per via perineale. In: *Proceedings of the 98° Congress of Societa' Italiana di Chirurgia*; 13-18 October 1996; Rome Pozzi. pp. 397-411
- [26] Kuijpers JHC, de Morree H. Towards a selection of the most appropriate procedure in the treatment of complete rectal prolapse. *Diseases of the Colon and Rectum*. 1988;**31**:355-357
- [27] Youssef M, Thabet W, El Nakeeb A, Magdy A, Alla EA, El Nabeey MA, Fouda El Y, Omar W, Farid M. Comparative study between Delorme operation with or without post-anal repair and levatorplasty in treatment of complete rectal prolapse. *International Journal of Surgery*. 2013;**11**(1):52-58. DOI: 10.1016/j.ijssu.2012.11.011
- [28] Placer C, Enriquez-Navascués JM, Timoteo A, Elorza G, Borda N, Gallego L, Saralegui Y. Delorme's procedure for complete rectal prolapse: A study of recurrence patterns in the long term. *Surgery Research and Practice*. 2015;**2015**:920154. DOI: 10.1155/2015/920154
- [29] Tobin SA, Scott IHK. Delorme operation for rectal prolapse. *The British Journal of Surgery*. 1994;**81**:1681-1684
- [30] Friedmann R, Mugga-Sullam M, Freund HR. Experience with the one stage perineal repair of rectal prolapse. *Diseases of the Colon and Rectum*. 1983;**26**:789-791
- [31] Ramanujam PS, Venkatesh KS, Fiets MJ. Perineal excision of rectal procidentia in elderly, high-risk patients. *Diseases of the Colon and Rectum*. 1994;**37**:1027-1039
- [32] Yoshioka K, Ogunbiyi OA, Keighley MRB. Pouch perineal recto-sigmodectomy gives better functional results than conventional recto-sigmoidectomy in elderly patients with rectal prolapse. *The British Journal of Surgery*. 1998;**85**:1525-1526
- [33] Mustain WC, Davenport DL, Parcels JP, Vargas HD, Hourigan JS. Abdominal versus perineal approach for treatment of rectal prolapse: comparable safety in a propensity-matched cohort. *The American Surgeon*. 2013;**79**(7):686-692

- [34] Laubert T, Bader FG, Kleemann M, Esnaashari H, Bouchard R, Hildebrand P, Schlöricke E, Bruch HP, Roblick UJ. Outcome analysis of elderly patients undergoing laparoscopic resection rectopexy for rectal prolapse. *International Journal of Colorectal Disease*. 2012 Jun;**27**(6):789-795. DOI: 10.1007/s00384-011-1395-1
- [35] Clark CE 3rd, Jupiter DC, Thomas JS, Papaconstantinou HT. Rectal prolapse in the elderly: trends in surgical management and outcomes from the American College of Surgeons National Surgical Quality Improvement Program database. *Journal of the American College of Surgeons*. 2012;**215**(5):709-714. DOI: 10.1016/j.jamcollsurg.2012.07.004
- [36] Ripstein CB. Procidentia: Definitive corrective surgery. *Diseases of the Colon and Rectum*. 1972;**15**:334-336
- [37] Scaglia M, Fasth S, Hallgren T, Nordgren S, Oresland T, Hultén L. Abdominal rectopexy for rectal prolapse. Influence of surgical technique on functional outcome. *Diseases of the Colon & Rectum*. 1994 Aug;**37**(8):805-813
- [38] D'Hoore A, Penninckx F. Laparoscopic ventral recto (colpo) pexy for rectal prolapse: Surgical technique and outcome for 109 patients. *Surgical Endoscopy*. 2006 Dec;**20**(12):1919-1923
- [39] Faucheron JL, Trilling B, Girard E, Sage PY, Barbois S, Reche F. Anterior rectopexy for full-thickness rectal prolapse: Technical and functional results. *World Journal of Gastroenterology*. 2015 Apr 28;**21**(16):5049-5055. DOI: 10.3748/wjg.v21.i16.5049
- [40] Faucheron JL, Trilling B, Barbois S, Sage PY, Waroquet PA, Reche F. Day case robotic ventral rectopexy compared with day case laparoscopic ventral rectopexy: A prospective study. *Techniques in Coloproctology*. 2016 Oct;**20**(10):695-700. DOI: 10.1007/s10151-016-1518-3. Epub 2016 Aug 17
- [41] Emile SH, Elfeki HA, Youssef M, Farid M, Wexner SD. Abdominal rectopexy for the treatment of internal rectal prolapse: A systematic review and meta-analysis. *Colorectal Disease*. 2017 Jan;**19**(1):O13-O24. DOI: 10.1111/codi.13574
- [42] Owais AE, Sumrien H, Mabey K, McCarthy K, Greenslade GL, Dixon AR. Laparoscopic ventral mesh rectopexy in male patients with internal or external rectal prolapse. *Colorectal Disease*. 2014 Dec;**16**(12):995-1000. DOI: 10.1111/codi.12763
- [43] Rautio T, Mäkelä-Kaikkonen J, Vaarala M, Kairaluoma M, Kössi J, Carpelan-Holmström M, Salmenkylä S, Ohtonen P, Mäkelä J. Laparoscopic ventral rectopexy in male patients with external rectal prolapse is associated with a high reoperation rate. *Techniques in Coloproctology*. 2016 Oct;**20**(10):715-720. DOI: 10.1007/s10151-016-1528-1 Epub 2016 Sep 19
- [44] Evans C, Stevenson AR, Sileri P, Mercer-Jones MA, Dixon AR, Cunningham C, Jones OM, Lindsey I. A multicenter collaboration to assess the safety of laparoscopic ventral Rectopexy. *Diseases of the Colon and Rectum*. 2015 Aug;**58**(8):799-807. DOI: 10.1097/DCR.0000000000000402

- [45] Borie F, Coste T, Bigourdan JM, Guillon F. Incidence and surgical treatment of synthetic mesh-related infectious complications after laparoscopic ventral rectopexy. *Techniques in Coloproctology*. 2016 Nov;**20**(11):759-765
- [46] Thauerkauf FJ, Bears OH, Hill JR. Rectal prolapse causation and surgical management. *Annals of Surgery*. 1970;**171**:819-835
- [47] Schlinkert RT, Beart RW Jr, Wolff BG, Pemberton JH. Anterior resection for complete rectal prolapse. *Diseases of the Colon and Rectum*. 1985 Jun;**28**(6):409-412
- [48] Frykman H, Goldberg S. The surgical management of rectal procidentia. *Surgery, Gynecology & Obstetrics*. 1969;**129**:1225-1230
- [49] Ashari LH, Lumley JW, Stevenson AR, Stitz RW. Laparoscopically-assisted resection rectopexy for rectal prolapse: Ten years' experience. *Diseases of the Colon and Rectum*. 2005 May;**48**(5):982-987
- [50] Tou S, Brown SR, Nelson RL. Surgery for complete (full-thickness) rectal prolapse in adults. *Cochrane Database of Systematic Reviews*. 2015 Nov 24;**11**:CD001758. DOI: 10.1002/14651858.CD001758.pub3
- [51] Tou S, Brown SR, Malik AI, Nelson RL. Surgery for complete rectal prolapse in adults. *Cochrane Database of Systematic Reviews*. 2008 Oct 8;**4**:CD001758. DOI: 10.1002/14651858.CD001758.pub2. Update in: *Cochrane Database Syst Rev*. 2015;**11**:CD001758
- [52] Senapati A, Gray RG, Middleton LJ, Harding J, Hills RK, Armitage NC, Buckley L, Northover JM, PROSPER Collaborative Group. PROSPER: A randomised comparison of surgical treatments for rectal prolapse. *Colorectal Disease*. 2013 Jul;**15**(7):858-868. DOI: 10.1111/codi.12177
- [53] Formijne Jonkers HA, Draaisma WA, Wexner SD, Broeders IA, Bemelman WA, Lindsey I, Consten EC. Evaluation and surgical treatment of rectal prolapse: an international survey. *Colorectal Disease*. 2013 Jan;**15**(1):115-119. DOI: 10.1111/j.1463-1318.2012.03135
- [54] Dodi G, Pietroletti R, Milito G, Binda G, Pescatori M. Bleeding, incontinence, pain and constipation after STARR transanal double stapling rectotomy for obstructed defecation. *Techniques in Coloproctology*. 2003 Oct;**7**(3):148-153
- [55] Ravo B, Amato A, Bianco V, Boccasanta P, Bottini C, Carriero A, Milito G, Dodi G, Mascagni D, Orsini S, Pietroletti R, Ripetti V, Tagariello GB. Complications after stapled hemorrhoidectomy: Can they be prevented? *Techniques in Coloproctology*. 2002 Sep;**6**(2):83-88
- [56] Hotouras A, Ribas Y, Zakeri S, Bhan C, Wexner SD, Chan CL, Murphy JA. Systematic review of the literature on the surgical management of recurrent rectal prolapse. *Colorectal Disease*. 2015 Aug;**17**(8):657-664. DOI: 10.1111/codi.12946
- [57] Hool GR, Hull TL, Fazio VW. Surgical treatment of recurrent complete rectal prolapse: A thirty-year experience. *Diseases of the Colon and Rectum*. 1997 Mar;**40**(3):270-272

- [58] Pikarsky AJ, Joo JS, Wexner SD, Weiss EG, Noguera JJ, Agachan F, Iroatulam A. Recurrent rectal prolapse: what is the next good option? *Diseases of the Colon and Rectum*. 2000 Sep;**43**(9):1273-1276
- [59] Steele SR, Goetz LH, Minami S, Madoff RD, Mellgren AF, Parker SC. Management of recurrent rectal prolapse: Surgical approach influences outcome. *Diseases of the Colon and Rectum* 2006;**49**(4):440-445
- [60] Cavazzoni E, Rosati E, Zavagno V, Graziosi L, Donini A. Simultaneous Delorme's procedure and inter-sphincteric prosthetic implant for the treatment of rectal prolapse and faecal incontinence: Preliminary experience and literature review. *International Journal of Surgery*. 2015 Feb;**14**:45-48. DOI: 10.1016/j.ijssu.2014.12.031
- [61] Germain A, Perrenot C, Scherrer ML, Ayav C, Brunaud L, Ayav A, Bresler L. Long-term outcome of robotic-assisted laparoscopic rectopexy for full-thickness rectal prolapse in elderly patients. *Colorectal Disease*. 2014 Mar;**16**(3):198-202. DOI: 10.1111/codi.12513

