

---

# Applications of Anorectal Ultrasound in Anorectal Disorders

---

Kasaya Tantiphlachiva

Additional information is available at the end of the chapter

<http://dx.doi.org/10.5772/intechopen.78326>

---

## Abstract

Endoanal ultrasound (EAUS) and endorectal ultrasound (ERUS) have been introduced to clinical use since the 1980s. The techniques have been used to assess various anorectal disorders and conditions, including anorectal abscess and fistula, fecal incontinence, anorectal tumor, anorectal pain and occasionally evaluation of adjacent pelvic pathology. Information acquired includes anatomical location of disease, extent of disease, involvement of anal sphincter by disease and the status of anal sphincter. This information is valuable for treatment planning, prevention of disease recurrence, prevention and/or correction of sphincter defect and follow-up evaluation. The technique is cheap, simple, well tolerated, and repeatable with acceptable accuracy. Although the interpretation is operator-dependent, technology has developed to improved image quality such as 3D-reconstruction, peroxide-enhanced technique and volume render mode. This chapter reviews the current application of anorectal ultrasound in the common anorectal disorders.

**Keywords:** endoanal ultrasound, endorectal ultrasound, transanal ultrasound, transrectal ultrasound, anorectal disorder

---

## 1. Introduction

Endoanorectal ultrasound (EARUS) was first described in 1956 by Wild and Reid but was not popularized due to technological limitations [1]. Law and Bartram, in 1989, had described the technique of endoanal ultrasound (EAUS) using 2D-plastic-coned probe [1, 2] and correlated the image with histological findings of the anal canal [1]. Early use of endoectal ultrasound (ERUS) is mostly by urologist to demonstrate bladder, prostate and seminal vesicle. Pahlman et al. [3] had used rectal ultrasound for preoperative staging of rectal tumor. Konishi et al. [4],

Anorectal disorders	EAUS*	ERUS**
Anorectal sepsis: abscess/fistula	✓	=
Fecal incontinence	✓	-
Anal sphincter injury	✓	-
Anorectal pain/pelvic pain	✓	✓
Anal cancer	✓	✓
Rectal cancer	-	✓
Pelvic pathology: retrorectal/gynecological/prostate	-	✓

\*EAUS: endoanal ultrasound.  
\*\*ERUS: endorectal ultrasound.

**Table 1.** Anorectal disorder which endoanal and endorectal ultrasound can be used.

had used ERUS to assess the depth of rectal tumor invasion in order to select the patient for local excision. However, the resolution was limited by the machine frequency [4]. After sequential developments, EARUS has become an important part of the assessment for various anorectal conditions, both benign and malignant. The operator may be a radiologist, gastroenterologist or surgeon [5].


Currently, sonography for viewing anorectal region can be performed transanally, transvaginally or transperineally [6]. Here, the focus is on the transanal technique. It is well tolerated by most patients, needs minimal preparation, no radiation exposure and can be performed in the office setting [5] and in both genders. **Table 1** categorizes anorectal disorders that could be assessed by EARUS.

## 2. Equipment, technique and normal anatomy


Anal canal is defined functionally from the proximal aspect of the internal anal sphincter (IAS)/levator ani muscle above down to the anal verge below [7]. This area is surrounded by IAS and external anal sphincter (EAS) [7] which persistently contract. Thus, the probe is usually in close contact with the wall of the anal canal. However, in the rectum above, the water-filled balloon is used as a conduction media from the transducer to the rectal wall.

The examining position can be left lateral decubitus, lithotomy or prone jackknife position [8]. Bowel preparation or sedation is not required except in the presence of fecal impaction or severe anorectal pain, respectively. After careful digital rectal examination, the probe is lubricated and gently inserted into the anal canal. Standard orientation is that the anterior part of the patient is at 12 o'clock, posterior part at 6 o'clock, right side at 9 o'clock, and left side at 3 o'clock [8]. If it is a two-dimensional probe, the examiner should manually advance and withdraw the probe to demonstrate each anatomical level. If it is a three-dimensional probe, the examiner should hold the probe steadily in the middle of the anal canal while the image is acquired. The three planes of analysis are (1) the deeper plane: at the upper level of anal canal where the typical hyperechoic U-shaped sling of the puborectalis muscle is seen

(2) the intermediate plane: at the middle level of anal canal where the hypoechoic IAS, the perineal body and the transverse perineal muscle are seen and EAS forms a complete ring  
(3) the superficial plane: at the lower level of the anal canal where IAS has terminated and only hyperechoic subcutaneous part of the EAS is seen [2, 9]. **Figure 1** demonstrates normal endoanal ultrasonographic views of the anal canal at each level.



**Figure 1.** Normal endoanal ultrasonographic views of anal canal at three levels—left: in female and right: in male.



**Figure 2.** Endorectal ultrasonographic view of rectal wall (five layers).

Endorectal ultrasound (ERUS) views the rectal wall as alternating five hyper- and hypo-echoic layers (**Figure 2**). From the lumen outward, the innermost white (hyperechoic) layer represents the interface between the balloon and rectal mucosa. The inner dark (hypoechoic) layer represents the mucosa and muscularis mucosae. The middle white (hyperechoic) layer represents the submucosa. The outer dark (hypoechoic) layer represents the muscularis propria. The outer white (hyperechoic) layer represents the interface between the muscularis propria and perirectal fat/serosa [10, 11]. These rings should be smooth, homogenous and complete.

### 3. Application of endoanorectal ultrasound

#### 3.1. Endoanal ultrasound in anorectal abscess and fistula

Most anorectal sepsis are caused by the infection of the anal gland which normally drains into anal crypts, known as cryptoglandular theory [12]. In the acute phase, the suppuration loculated in the potential space around the anus: *perianal* (or subanodermal), *intersphincteric*, *ischioanal* (or ischioanal) and *supralelevator abscesses* [13, 14]. In the chronic phase, the suppuration takes a course between and through anal sphincter muscles to find the exit in the perianal skin. The most commonly used classification of the anorectal fistula is Park's classification [12, 15]: *intersphincteric fistula* (primary tract courses in the intersphincteric space down to the skin), *transsphincteric fistula* (primary tract traverses the EAS to enter the ischioanal fossa before exit at the skin), *suprasphincteric* (primary tract courses up within the intersphincteric plane above and over the puborectalis muscle before coursing back into ischioanal fossa downwards to the exit at the skin), *extrasphincteric fistula* (primary tract traverses levator ani to course through the ischioanal space without relation with IAS and EAS) [15]. Another additional subtype courses in the submucosa without traversing IAS or EAS is called *subcutaneous fistula* [15]. Perianal sepsis that arises from noncryptoglandular causes, such as Crohn's disease, tuberculosis, rectovaginal fistula, traumatic injury or in patients after previous anorectal surgery, may have more complex courses of the fistula and related abscess.

Preoperative imaging aims to reduce the risk of postoperative recurrences and fecal incontinence [16]. Endoanal ultrasound (EAUS) is a safe and reliable technique for the assessment of perianal sepsis [17]. With three-dimensional technology (3D-EAUS), the accuracy in identifying primary fistula type, internal opening, secondary tract and adjacent abscesses was improved from a two-dimensional view (2D-EAUS) [18]. Fistula and abscess are hypoechoic tracts or lesion within the anal wall [19]. From meta-analysis of the early studies, sensitivity and specificity for fistula detection of EAUS versus MRI were 87 versus 87% and 43 versus 69%, respectively [20]. In the identification of internal opening, sensitivity of EAUS versus MRI was 88–91% versus 19–97% and specificity of 41–100% versus 71–100% [20].

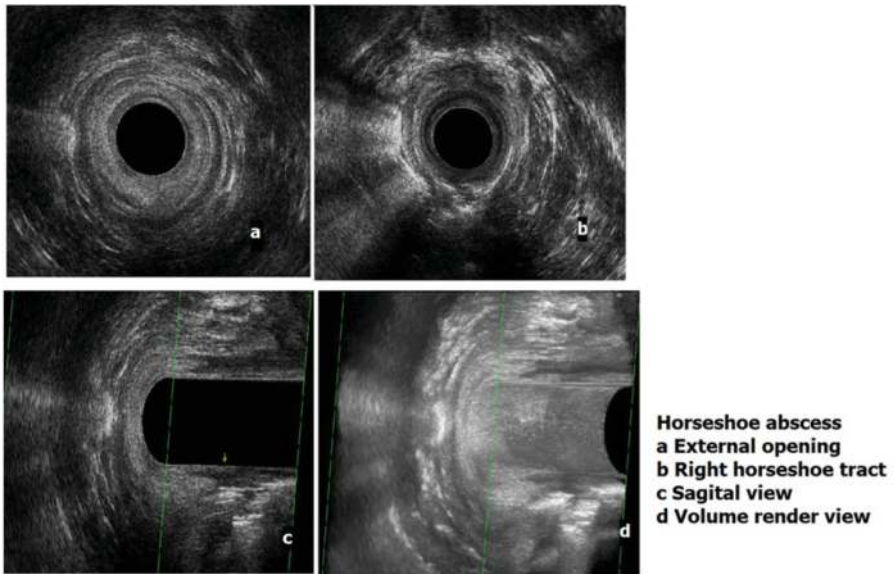
Injection of hydrogen peroxide into the external opening of the fistula has significantly improved the visualization of the fistula tract [16] as it would form into small air bubbles which show as bright hyperechoic (white) tracts [16]. The technique provided better detection of internal opening, fistula level, secondary tract and chronic fistula cavity [21, 22]. Addition of image-enhanced technology as volume rendering to the 3D-EAUS further improved the accuracy of preoperative fistula study [23, 24]. **Figure 3a** is an example of EAUS in demonstrating the horseshoe fistula using the 3D technique, hydrogen peroxide injection and volume render mode. **Figure 3b** compares the 3D-EAUS view with the rendered view of postanal space abscess.

The accuracy of EAUS in evaluation of the recurrent anorectal fistula did not significantly decrease compared to primary anorectal fistula [25]. Another useful information for planning the fistula operation, obtained during EAUS, is whether there is any anal sphincter defect(s) [25].

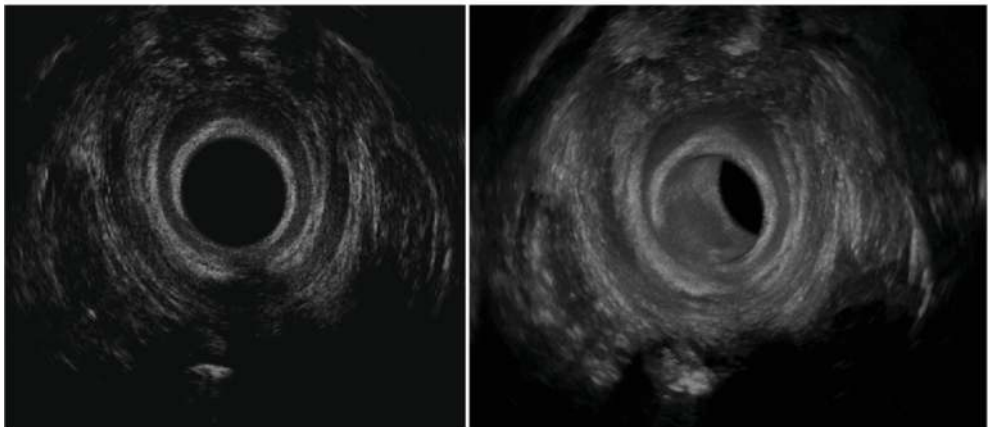
In Crohn-related anorectal fistula, there was no significant difference between 3D-EAUS versus MRI in detection of anorectal fistula: sensitivity, 98 versus 91%; specificity, 100 versus 100% and accuracy, 98 versus 92% [26]. While 3D-EAUS was preferable in the detection of the intersphincteric fistula, MRI was preferable in evaluation of suprasphincteric and extrasphincteric fistula [26]. EAUS technique is simple, inexpensive and well tolerated by the patient [27] and more available than MRI [28]. Thus, it is recommended as a modality for assessment of patients with occult anorectal abscess, complex anal fistula or perianal Crohn's disease [28, 29].

### 3.2. Endoanal ultrasound in fecal incontinence and anal sphincter injury

Fecal incontinence (FI) is a disturbing condition that greatly impacts the patient's quality of life. The anatomical causes are anal sphincter disruption or atrophy which could occur as a result of vaginal delivery, surgery, trauma or aging. EAUS is a gold standard and has an established role in defining anal sphincter anatomy and defect in the assessment of patients with FI [30–32]. Information from EAUS includes EAS/IAS/puborectalis muscle integrity, length and thickness. A comparison to the normative value may explain the possible cause(s) of incontinence [33, 34]. FI was found to be associated with anal sphincter length and thickness rather than volume [33]. IAS defect appears as a discontinuity of the hypoechoic band or localized thinning. There was a significant correlation between decreased maximal resting anal sphincter pressure and decreased IAS thickness or presence of IAS defect [35]. EAS defect appears as a discontinuity in the hyperechoic band of EAS. EAS defect or thinning was



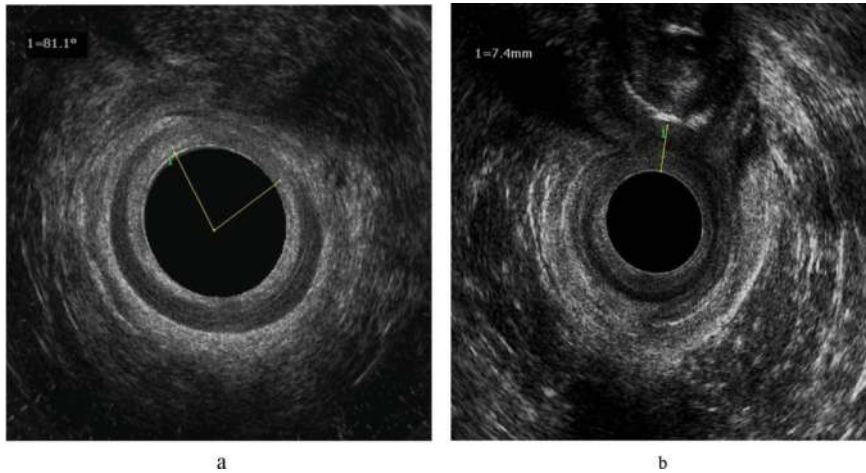
a



b

**Figure 3.** a. Endoanal ultrasound view of the right horseshoe fistula. b. 3D-EAUS view with the rendered view of postanal space abscess.

significantly correlated with maximal squeeze pressure [36]. In females, perineal body thickness measurement should be performed. The thickness of 10 mm or less is considered abnormal [37]. **Figure 4a** shows the EAUS view of anterior anal sphincter defect (most commonly found in obstetric injury) and **Figure 4b** demonstrates the perineal body measurement by



**Figure 4.** a. Endoanal ultrasound view of anterior anal sphincter defect; IAS defect seen as the discontinuity of the hypochoic (dark) ring and EAS defect seen as the discontinuity of the hyperechoic (white) ring. b. Perineal body measurement; the hyperechoic shadow is the examiner's index finger that presses against the patient's posterior vaginal wall.

inserting the examiner's index finger into the patient's vagina and gently pressing on the posterior wall. Compared to MRI, 3D-EAUS can also be used to detect EAS atrophy and defects [38]. By MRI, EAS atrophy is defined as diffuse thinning of EAS or diffuse replacement of EAS by fat [38]. By EAUS, EAS atrophy is defined by the visibility of the outer interface between EAS border and subadventitial fat, reflection pattern and length [38]. The atrophic EAS could not be clearly differentiated from the subadventitial fat, has a hyperechogenic reflection, and is short [38].

In the patient who has sustained anorectal and perineal trauma, a thorough assessment of anorectal anatomy and function should be performed after the patient recovers and regains the ability to go to the toilet [39]. The preferred anorectal imaging is EAUS as the sensitivity for evaluation of anal sphincter defect is nearly 100%, better identification of IAS injury than MRI, less time-consuming and less expensive than MRI [39]. Together with the information from anorectal manometry and pudendal terminal motor latency test, a definitive treatment can be planned [30, 39].

### 3.3. Endoanal ultrasound in the assessment of anorectal dysfunction

3D-EAUS can be used to evaluate patients with obstructed defecation by steps of scan described by Murad-Regadas, called "echodefecography" [40]. Using this technique, anismus, anorectocele and rectal intussusception can be identified with moderate to high agreement with defecography [40]. Recent studies showed that echocardiography alone [41] or in combination with transvaginal and transperineal ultrasound is an effective and useful non-invasive test in evaluation of the patients with pelvic floor dysfunction including obstructed defecation and pelvic organ prolapse [42, 43].

### 3.4. Endorectal ultrasound in rectal cancer

Evaluation of rectal tumor is essential for planning the treatment. Carcinoma is seen as a hypoechoic lesion disrupting or penetrating through the rectal wall layers [11]. Villous adenoma can be classified as **uT0** lesion which does not penetrate the submucosa [11]. In situ, carcinoma (pTis) could not be differentiated from the benign adenoma using the ultrasound imaging alone [11]. A **uT1** tumor invades the submucosal layer and may be divided into uT1-slight, if only slight irregularity of the submucosa is seen, and uT1-massive, if massive irregularity of the submucosa is seen. A **uT2** tumor invades the outer hypoechoic muscular layer but with intact perirectal fat interface. A **uT3** tumor infiltrates the submucosal layer and presents as irregularity of the outer hyperechoic layer. A **uT4** tumor invades the adjacent organs such as bladder, uterus, cervix, vagina, prostate and seminal vesicles. Perirectal lymph nodes that are likely involved by the malignant cells are greater than 5 mm in size, have mixed echogenicity, irregular margins and are spherical rather than ovoid or flat [11]. **Figure 5a** demonstrates ERUS view of villous adenoma which shows no invasion of the hyperechoic middle submucosal layer. **Figure 5b** and **c** shows uT1 and uT3N1 lesions, respectively. This preoperative locoregional staging information can be used in treatment planning, whether local excision, oncologic resection or preoperative chemoradiotherapy would be appropriate.

In grossly benign rectal adenoma planning for local removal, additional ERUS may detect up to 81% of focal invasive carcinoma [44]. If the routine use of ERUS for biopsy-negative rectal adenomas is applied, the false-negative rate would be decreased from 24 to 5% and would allow better operative planning [44]. The accuracy of uT0 was 87% [45]. For other T-stages, the accuracy of preoperative uT staging is 94, 77 and 83% for T2, T3, T4, respectively [46]. From meta-analysis and a recent study [47, 48], the sensitivity and specificity for each T stages are as follows:

Sensitivity: 96, 88, 81, 96 and 95% for T0, T1, T2, T3 and T4, respectively.

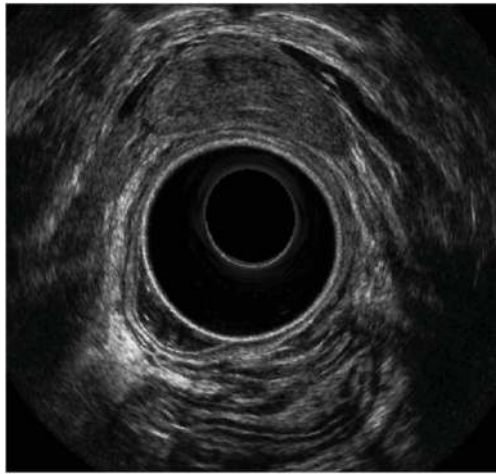
Specificity: 87, 93, 96, 91 and 98% for T0, T1, T2, T3 and T4, respectively.

The concern of ERUS is that the overstaging of 18% and understaging of 13% has been reported [45]. With three-dimensional ERUS (3D-ERUS), the examiner can evaluate the arbitrary planes from any direction [49]. This improves the sensitivity, specificity and accuracy of the test [50]. For example, the sensitivity for detection of T4 is up to 100% and the specificity for T1 was 97% [50]. The total overstaging and understaging were reduced to 4.5 and 6.8%, respectively [50].

For lymph node staging, the accuracy of ERUS had been reported from 68 to 79% [45, 51]. Sensitivity and specificity were between 71 and 80% and 63 and 79%, respectively [52]. With 3D-ERUS, the accuracy improved up to 85–96% [53, 54]. Recent meta-analysis, including both 2D- and 3D-techniques, reveals sensitivity and specificity of 95 and 80%, respectively [55]. The diagnostic accuracy of ERUS for N-stage is comparable to CT and MRI [56]. Nothing is reliable in the evaluation of lymph node metastasis.

ERUS has substantial agreement with MRI and surgical pathology in predicting the radial tumor-mesorectal margin [56, 57]. From the available data, a combination of ERUS and MRI is recommended for pretreatment assessment of rectal cancer [58–60]. For postneoadjuvant chemoradiotherapy (CRT) evaluation, the accuracy to assess complete tumor response of

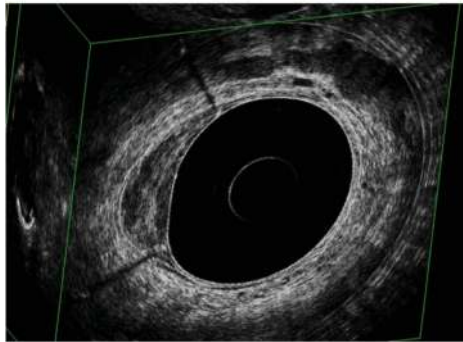




**Villous adenoma**

Expansion of inner hypoechoic layer (musosa) with intact middle hyperechoic layer

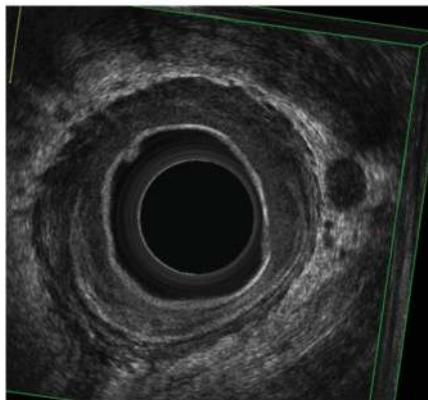
a



**uT1 cancer**

Submucosa (middle hyperechoic layer) is invaded but the muscularis propia (outer hypoechoic layer) is still intact

b



**uT3N1 cancer**

Perirectal fat (outer hyperechoic layer) infiltration (breaching) is seen with enlarged round hypoechoic lymph node

c

Figure 5. a. Villous adenoma, b. uT1 rectal cancer, and c. uT3N1 lesions.

ERUS, MRI and CT was 82, 75 and 83%, respectively [61]. The accuracy to detect T4 tumors with invasion to the circumferential margin was 94 and 88% for ERUS and MRI, respectively [61]. The accuracy for lymph node restaging was 72, 72 and 65% for ERUS, MRI and CT, respectively [61]. These are considered low and with no clinical relevance [61]. However, ERUS, if sequentially performed before, during and at 6–8 weeks after CRT, may predict therapeutic efficacy for locally advanced rectal cancer [62].

### 3.5. Endoanal-endorectal ultrasound for anal cancer

EAUS/ERUS evaluation of anal carcinoma has not been included in the major clinical guidelines [63, 64]. However, the technique is inexpensive, safe, well tolerated and repeatable for assessment of local disease [65]. EAUS staging of anal carcinoma had been proposed using the depth of invasion (**Table 2**) [65]. However, this is not correlated with the size criteria of tumor-node-metastasis (TNM) staging [66]. The exception is for T4 that the involvement of pelvic organ can be assessed. For lymph node evaluation, ERUS should be added to visualize the perirectal lymph node and any suspected lymph node should be considered as metastatic [67].

Following chemoradiotherapy, EAUS can be repeated to determine the response and used for surveillance. Although it is difficult to differentiate between post radiation change (edema, fibrosis) and tumor, tumors tend to be more hypoechogenic than scar (more mixed echogenic) [63]. It has been suggested that EAUS should not be performed within 45 days after the last radiotherapy but should be delayed until 16–20 weeks [63]. Serial examination and addition of color doppler to determine vascularity may increase the specificity in detecting local recurrence [65]. In some institutes, EAUS may be used to guide brachytherapy for anal cancer [64].

### 3.6. Endoanal ultrasound in anorectal pain

Endoanal ultrasound can be used in patients with chronic proctalgia to look for the possible causes, that is, chronic anorectal sepsis, IAS hypertrophy and anal sphincter defect [68, 69].

EAUS* stage	Definition
uT1	Involvement of the mucosa and submucosa without infiltration of the IAS <sup>§</sup>
uT2	Involvement of the IAS <sup>§</sup> with sparing of the EAS <sup>§§</sup>
uT3	Involvement of the EAS <sup>§§</sup>
uT4	Involvement of a pelvic organ
N0	No suspicious perirectal lymph nodes
N+	Perirectal lymph nodes suspicious for metastasis

\*EAUS: endoanal ultrasound.

§IAS: internal anal sphincter.

§§EAS: external anal sphincter.

**Table 2.** Endoanal ultrasound staging for anal carcinoma.

Recent EAUS study found that paradoxical anal sphincter puborectalis muscle (PR) contraction during straining and increased PR thickness is more common in these patients than normal subjects [70]. This information is useful for the management plan.

### 3.7. Other usage

EAUS and ERUS have been used to evaluate the pathologic process around the anorectal area such as bladder lesion, ovarian tumor and retrorectal tumor [71, 72]. However, it has not been popularized and is usually used as an adjunct to other imaging modality [73].

### 3.8. Personal experience

Our institute, King Chulalongkorn Memorial Hospital, is a tertiary center with a colorectal surgery fellowship program. We have adopted endoanal ultrasound in our practice since 2008. By that time, the 2D-technology was used, and we had compared the data from 2D-EAUS (with selective use of peroxide enhancement) with the data from examination under anesthesia (EUA) by our most experienced surgeon, Rojanasakul A. For acute anorectal abscess, fistula-in-ano and recurrent fistula, EAUS and EUA had 67, 91 and 100% agreement in identification of internal openings, respectively (Poster presentation in the 71st colon and rectal surgery: current principles and practice 2008, Minneapolis, MN). The results are comparable to the early 2D-EAUS report [21, 74, 75]. Later, the 3D-technology was launched. We had established the normative values of the anal sphincter anatomical component [34]. The mean IAS and EAS thickness in male versus female were  $1.7\pm 0.4$  versus  $1.8\pm 0.3$  mm and  $8.1\pm 1.3$  versus  $6.9\pm 0.9$  mm, respectively [34]. The mean anal canal length in male and female was 38.6 and 34.0 mm, respectively [34]. These findings were comparable with the previous study [34, 76]. We have used intraoperative EAUS in acute anorectal abscess to guide drainage, preoperative assessment of fistula-in-ano, assessment of anal sphincter defect in patients with fecal incontinence or anal sphincter injury. ERUS has been used for assessment of rectal tumor which clinically suitable for surgery and advanced rectal cancer (preoperative staging, follow-up). Additionally, MRI is selectively used in complex cases that need further information for the multidisciplinary team and academic discussion. In our experience, EAUS and ERUS are effective, informative, inexpensive and readily available technologies for colorectal surgeons.

## 4. Conclusion

Endoanal-endorectal ultrasound is a useful tool for assessment of various anorectal disorders. In a static view, the anal sphincter complex can be evaluated for integrity, thickness and length as well as local staging of anorectal cancer. In a dynamic view, anorectal dysfunction and structural defects related to pelvic floor disorder can be appreciated. The technique is noninvasive, well tolerated, inexpensive and widely available. The main drawback is that the interpretation depends largely on the experience of the operator.

## Acknowledgements

I would like to thank and give accreditation to Professor Dr. Arun Rojanasakul for his leadership, mentorship, inventorship and contribution to the field of colorectal surgery; Professor Chucheeep Sahakitrungrueng and Assistant Professor Jirawat Pattanaarun, my teachers, for their professional teaching and introduction to anorectal ultrasound.

## Conflict of interest

No conflict of interest

## Author details

Kasaya Tantiphlachiva

Address all correspondence to: kasaya.tan@gmail.com

Department of Surgery, Faculty of Medicine, Chulalongkorn University, Bangkok, Thailand

## References

- [1] Law PJ, Bartram CI. Anal endosonography: Technique and normal anatomy. *Gastrointestinal Radiology*. 1989;**14**:349-353
- [2] Abdool Z, Sultan AH, Tharka R. Ultrasound imaging of the anal sphincter complex: A review. *The British Journal of Radiology*. 2012;**85**:865-875
- [3] Pählman L, Adalsteinsson B, Glimelius B, Lindgren PG, Scheibenpflug L. Ultrasound in preoperative staging of rectal tumours. *Acta Radiol Diagn (Stockh)*. 1984;**25**:489-494
- [4] Konishi F, Muto T, Takahashi H, Itoh K, Kanazawa K, Morioka Y. Transrectal ultrasonography for the assessment of invasion of rectal carcinoma. *Diseases of the Colon and Rectum*. 1985;**28**:889-894
- [5] Schaffzin DM, Wong WD. Surgeon-performed ultrasound: Endorectal ultrasound. *Surgical Clinics of North America*. 2004;**84**:1127-1149
- [6] Berton F, Gola G, Wilson SR. Sonography of benign conditions of the anal canal: An update. *AJR*. 2007;**189**:765-773
- [7] Solan P, Davis B. Anorectal anatomy and imaging techniques. *Gastroenterology Clinics of North America*. 2013;**42**:701-712
- [8] Mihmanli I, Kantarci F, Dogra VS. Endoanorectal ultrasonography. *Ultrasound Quarterly*. 2011;**27**:87-104

- [9] Reginelli A, Mandato Y, Cavaliere C, Pizza NL, Russo A, Cappabianca S, et al. Three-dimensional anal endosonography in depicting anal-canal anatomy. *La Radiologia Medica*. 2012;**117**:759-771
- [10] Nasserri Y, Langenfeld SJ. Imaging for colorectal cancer. *Surgical Clinics of North America*. 2017;**97**:503-513
- [11] Santoro GA. Preoperative staging of rectal cancer: Role of 3D endorectal ultrasonography. *Acta Chirurgica Iugoslavica*. 2012;**59**:57-61
- [12] Parks AG, Gordon PH, Hardcastle JD. A classification of fistula-in-ano. *The British Journal of Surgery*. 1976;**63**:1-12
- [13] Visscher AP, Felt-Bersma RJ. Endoanal ultrasound in perianal fistulae and abscesses. *Ultrasound Quarterly*. 2015;**31**:130-137
- [14] Ommer A, Herold A, Berg E, Furst A, Sailer M, Schiedeck T. German S3 guideline: Anal abscess. *International Journal of Colorectal Disease*. 2012;**27**:831-837
- [15] Sun MR, Smith MP, Kane RA. Current techniques in imaging of fistula in ano: Three-dimensional endoanal ultrasound and magnetic resonance imaging. *Seminars in Ultrasound, CT and MRI*. 2008;**29**:454-471
- [16] Felt-Bersma RJ. Endoanal ultrasound in perianal fistulas and abscess. *Digestive and Liver Disease*. 2006;**38**:537-543
- [17] Brilliantino A, Iacobellis F, Di Sarno G, D'Aniello F, Izzo D, Paladino F, et al. Role of three-dimensional endoanal ultrasound (3D-EAUS) in the preoperative assessment of perianal sepsis. *International Journal of Colorectal Disease*. 2015;**30**:535-542
- [18] Garces-Albir M, Garcia-Botello SA, Espi A, Pla-Marti V, Martin-Arevalo J, Moro-Valdezate D, et al. Three-dimensional endoanal ultrasound for diagnosis of perianal fistulas: Reliable and objective technique. *World J Gastrointest Surg*. 2015;**8**:513-520
- [19] Kim MJ. Transrectal ultrasonography of anorectal disease: Advantages and disadvantages. *Ultrasonography*. 2015;**34**:19-31
- [20] Siddiqui MR, Ashrafian H, Tozer P, Daulatzai N, Burling D, Hart A, et al. A diagnostic accuracy meta-analysis of endoanal ultrasound and MRI for perianal fistula assessment. *Diseases of the Colon and Rectum*. 2012;**55**:576-585
- [21] Navarro-Luna A, Garcia-Domingo MI, Rius-Marcias J, Marco-Molina C. Ultrasound study of anal fistulas with hydrogen peroxide enhancement. *Diseases of the Colon and Rectum*. 2004;**47**:108-114
- [22] Kim Y, Park YJ. Three-dimensional endoanal ultrasonographic assessment of an anal fistula with and without H<sub>2</sub>O<sub>2</sub> enhancement. *World Journal of Gastroenterology*. 2009;**15**:4810-4815
- [23] Santoro GA, Fortling B. The advantages of volume rendering in three-dimensional endosonography of the anorectum. *Diseases of the Colon and Rectum*. 2006;**50**:359-368

- [24] Sudol-Szopinska I, Kolodziejczak M, Szopinski TR. The accuracy of a postprocessing technique- volume render mode- in three-dimensional endoanal ultrasonography of anal abscess and fistulas. *Diseases of the Colon and Rectum*. 2011;**54**:238-244
- [25] Emile SH, Magdy A, Youssef M, Thabet W, Abdelnaby M, Omar W, et al. Utility of endoanal ultrasonography in assessment of primary and recurrent anal fistulas and for detection of associated anal sphincter defects. *Journal of Gastrointestinal Surgery*. 2017;**21**:1879-1887
- [26] Alabiso ME, Iasiello F, Pellino G, Iacomino A, Roberto L, Pinto A, et al. 3D-EAUS and MRI in the activity of anal fistulas in Crohn's disease. *Gastroenterology Research and Practice*. 2016;**2016**:1895694. DOI: 10.1155/2016/1895694. Epub 2015 Dec 27
- [27] Gravante G, Gordano P. The role of three-dimensional endoluminal ultrasound imaging in the evaluation of anorectal diseases: A review. *Surgical Endoscopy*. 2008;**22**:1570-1578
- [28] Ommer A, Herold A, Berg E, Fürst A, Post S, Ruppert R, et al. German S3 guidelines: Anal abscess and fistula (second revised version). *Langenbeck's Archives of Surgery*. 2017;**402**:191-201
- [29] Vogel JD, Johnson EK, Morris AM, Paquette IM, Saclarides TJ, Feingold DL, et al. Clinical practice guideline for the management of anorectal abscess, fistula-in-ano, and rectovaginal fistula. *Diseases of the Colon and Rectum*. 2016;**59**:1117-1133
- [30] Albuquerque A. Endoanal ultrasonography in fecal incontinence: current and future perspectives. *World Journal of Gastrointestinal Endoscopy*. 2015;**7**:575-581
- [31] Italian Society of Colorectal Surgery (SICCR), Pucciani F, Altomare DF, Dodi G, Falletto E, Frasson A, et al. Diagnosis and treatment of faecal incontinence: consensus statement of the Italian Society of Colorectal Surgery and the Italian Association of Hospital Gastroenterologists. *Digestive and Liver Disease*. 2015;**47**:628-645
- [32] Paquette IM, Varma MG, Kaiser AM, Steele SR, Rafferty JF. The American Society of Colon and Rectal Surgeons' clinical practice guideline for the treatment of fecal incontinence. *Diseases of the Colon and Rectum*. 2015;**58**:623-636
- [33] West RL, Felt-Bersma RJ, Hansen BE, Schoten WR, Kuipers EJ. Volume measurements of the anal sphincter complex in healthy controls and fecal-incontinent patients with three-dimensional reconstruction of endoanal ultrasonography images. *Diseases of the Colon and Rectum*. 2005;**48**:540-548
- [34] Tantiplachiva K, Sahakitrungruang C, Pattanaarun J, Rojanasakul A. Normative anatomy of the anal sphincter detected with 3D-endoanal ultrasonography. *Asian Biomed*. 2013;**7**:865-871
- [35] Parangama C, Anu E, Sukria N. Endoanal ultrasound assessment of sphincter defects and thinning-correlation with anal manometry. *Arab Journal of Gastroenterology*. 2014;**15**:27-31
- [36] Titi MA, Jenkins JT, Urie A, Molloy RG. Correlation between anal manometry and endo-sonography in female with faecal incontinence. *Colorectal Disease*. 2007;**10**:131-137

- [37] Oberwalder M, Thaler K, Baig MK, Dinnewitzer A, Efron J, Weiss EG, et al. Anal ultrasound and endosonographic measurement of perineal body thickness, a new evaluation for fecal incontinence in females. *Surgical Endoscopy*. 2004;**18**(4):650
- [38] Cazemier M, Terra MP, Stoker J, de Lange-de Klerk ES, Boeckxstaens GE, Mulder CJ, et al. Atrophy and defects detection of the external anal sphincter: comparison between three-dimensional anal endosonography and endoanal magnetic resonance imaging. *Diseases of the Colon and Rectum* 2006;**49**:20-27
- [39] Jeganathan AN, Cannon JW, Bleier JI. Anal and perineal injuries. *Clinics in Colon and Rectal Surgery*. 2018;**31**:24-29
- [40] Murad-Regadas SM, Regadas FS, Rodrigues LV, Silva FR, Soares FA, Escalante RD. A novel three-dimensional dynamic anorectal ultrasonography technique (echodefecography) to assess obstructed defecation, a comparison with defecography. *Surgical Endoscopy*. 2008;**22**:974-979
- [41] Regadas FS, Haas EM, Abbas MA, Marcio Jorge J, Habr-Gama A, Sands D, et al. Prospective multicenter trial comparing echodefecography with defecography in the assessment of anorectal dysfunction in patients with obstructed defecation. *Diseases of the Colon and Rectum*. 2011;**54**:686-692
- [42] Bruscianno L, Limongelli P, Pescatori M, Napolitano V, Gagliardi G, Maffettone V, et al. Ultrasonographic patterns in patients with obstructed defaecation. 2007;**22**:969-977
- [43] de la Portilla F, Rubio Manzanares Dorado M, Pino Di'az V, Vazquez Monchul JM, Palacios C, Di'az Pavo'n JM, et al. The role of tridimensional dynamic ultrasound for pelvic floor evaluation. *Cirugía Española* 2015;**93**:530-535
- [44] Worrell S, Horvath K, Blakemore T, Flum D. Endorectal ultrasound detection of focal carcinoma within rectal adenomas. *American Journal of Surgery*. 2004;**187**:625-629
- [45] Garcia-Aguilar J, Pollack J, Lee S-K, Hernandez de Ana E, Mellgren A, Wong WD, et al. Accuracy of endorectal ultrasonography in preoperative staging of rectal tumors. *Diseases of the Colon and Rectum*. 2002;**45**:10-15
- [46] Xu D, Ju HX, Qian CW, Jiang F. The value of TRUS in the staging of rectal carcinoma before and after radiotherapy and comparison with the staging postoperative pathology. *Clinical Radiology*. 2014;**69**:481-484
- [47] Puli SR, Bechtold ML, Reddy JB, Choudhary A, Antillon MR, Brugge WR. How good is endoscopic ultrasound in differentiating various T stages of rectal cancer? Meta-analysis and systematic review. *Annals of Surgical Oncology*. 2009;**16**:254-265
- [48] Surace A, Ferrarese A, Marola S, Borello A, Cumbo J, Rivelli M, et al. Endorectal ultrasound in the diagnosis of rectal cancer: Accuracy and criticisms. *International Journal of Surgery*. 2014;**12**(Suppl. 2):S99-S102
- [49] Hunerbein M. Endorectal ultrasound in rectal cancer. *Colorectal Disease*. 2003;**5**:402-405
- [50] Jun-hong R, Fa-jin G, Wei-de D, Xiu-jie H, Na M. Study of endorectal ultrasonography in the staging of rectal cancer. *Chinese Medical Journal*. 2012;**125**:3740-3743

- [51] Glaser F, Schlag P, Herfarth C. Endorectal ultrasonography for the assessment of invasion of rectal tumours and lymph node involvement. *The British Journal of Surgery*. 1990;**77**:883-887
- [52] Puli SR, Reddy JB, Bechtold ML, Choudhary A, Antillon MR, Brugge WR. Accuracy of endoscopic ultrasound to diagnose nodal invasion by rectal cancer: A meta-analysis and systematic review. *Annals of Surgical Oncology*. 2009;**16**:1255-1265
- [53] Kim JC, Kim HC, Yu CS, Han KR, Kim JR, Lee KH, et al. Efficacy of 3-dimensional endorectal ultrasonography compared with conventional ultrasonography and computed tomography in preoperative rectal cancer staging. *American Journal of Surgery*. 2006;**192**:89-97
- [54] Santoro GA, D'Elia A, Battistella G, Di Falco G. The use of a dedicated rectosigmoidoscope for ultrasound staging of tumours of the upper and middle third of the rectum. *Colorectal Disease*. 2007;**9**:61-66
- [55] Zhou Y, Shao W, Lu W. Diagnostic value of endorectal ultrasonography for rectal carcinoma: A meta-analysis. *Journal of Cancer Research and Therapeutics*. 2014;**10**(Suppl): 319-322
- [56] Phang PT, Gollub MJ, Loh BD, Nash GM, Temple LK, Paty PB, et al. Accuracy of endorectal ultrasound for measurement of the closest predicted radial mesorectal margin for rectal cancer. *Diseases of the Colon and Rectum*. 2012;**55**:59-64
- [57] Tsai C, Hague C, Xiong W, Raval M, Karimuddin A, Brown C, et al. Evaluation of endorectal ultrasound (ERUS) and MRI for prediction of circumferential resection margin (CRM) for rectal cancer. *American Journal of Surgery*. 2017;**213**:936-942
- [58] Gérard JP, André T, Bibeau F, Conroy T, Legoux JL, Portier G, et al. Rectal cancer: French Intergroup clinical practice guidelines for diagnosis, treatments and follow-up (SNFGE, FFCD, GERCOR, UNICANCER, SFCD, SFED, SFRO). *Digestive and Liver Disease*. 2017;**49**:359-367
- [59] Arezzo A, Bianco F, Agresta F, Coco C, Faletti R, Krivocapic Z, et al. Practice parameters for early rectal cancer management: Italian Society of Colorectal Surgery (Società Italiana di Chirurgia ColoRettale; SICCR) guidelines. *Techniques in Coloproctology*. 2015;**19**:587-593
- [60] Eberhardt SC, Carter S, Casalino DD, Merrick G, Frank SJ, Gottschalk AR, et al. ACR Appropriateness Criteria® Pretreatment Staging of Colorectal Cancer. *Journal of the American College of Radiology*. 2013;**10**:83-92
- [61] De Jong EA, ten Berge JC, Dwarkasing RS, Rijkers AP, van Eijck CH. The accuracy of MRI, endorectal ultrasonography, and computed tomography in predicting the response of locally advanced rectal cancer after preoperative therapy: A metaanalysis. *Surgery* 2016; **159**:688-699
- [62] Li N, Dou L, Zhang Y, Jin J Wang G, Xiao Q, et al. Use of sequential endorectal US to predict the tumor response of preoperative chemoradiotherapy in rectal cancer. *Gastrointestinal Endoscopy*. 2017;**85**:669-674



- [63] Martellucci J. Endoanal ultrasound for anal cancer follow up. *International Journal of Colorectal Disease*. 2011;**26**:679-680
- [64] Granata V, Fusco R, Reginelli A, Roberto L, Granata F, Rega D, et al. Radiological assessment of anal cancer: An overview and update. *Infectious Agents and Cancer*. 2016;**11**:52. eCollection 2016
- [65] Parikh J, Shaw A, Grant LA, Schizas AM, Datta V, Williams AB, et al. Anal carcinomas: the role of endoanal ultrasound and magnetic resonance imaging in staging, response evaluation and follow-up. *European Radiology*. 2011;**21**:776-785
- [66] NCCN Clinical Practice Guidelines in Oncology on Anal Carcinoma, Version 2.2017. Available from: <http://www.nccn.org>
- [67] Jacopo M. Endoanal ultrasound for anal cancer staging. *International Journal of Colorectal Disease*. 2011;**26**:385-386
- [68] Beer-Gabel M, Carter D, Venturero M, Zmora O, Zbar AP. Ultrasonographic assessment of patients referred with chronic anal pain to tertiary referral centre. *Techniques in Coloproctology*. 2010;**14**:107-112
- [69] Garcia-Montes MJ, Arguelles-Arias F, Jimenez-Contreras S, Sanchez-Gey S, Pellicer-Bautista F, Herrerias-Gutierrez JM. Should anorectal ultrasonography be included as a diagnostic tool for chronic anal pain? *Revista Española de Enfermedades Digestivas*. 2010;**102**:7-14
- [70] Xue YH, Ding SQ, Ding YJ, Pan LQ. Role of three-dimensional endoanal ultrasound in assessing the anal sphincter morphology of female patients with chronic proctalgia. *World Journal of Gastroenterology*. 2017;**23**:3900-3906
- [71] Schaarschmidt K, Willital GH. Intraanal ultrasound: A new air in the diagnosis of pelvic process and their relation to the sphincter complex. *Journal of Pediatric Surgery*. 1992;**27**:604-608
- [72] Hutton KA, Benson EA. Case report: Tailgut cyst-assessment with transrectal ultrasound. *Clinical Radiology*. 1992;**45**:288-289
- [73] Zoller S, Joos A, Dinter D, Back W, Horisberger K, Post S, et al. Retrorectal tumors: Excision by transanal endoscopic microsurgery. *Revista Española de Enfermedades Digestivas*. 2007;**99**:547-530
- [74] Cataldo PA, Senagore A, Luchtefeld MA. Intrarectal ultrasound in the evaluation of perirectal abscesses. *Diseases of the Colon and Rectum*. 1993;**36**:554-558
- [75] Moscowitz I, Baig MK, Noguera JJ, Ovalioglu E, Weiss EG, Singh JJ, et al. Accuracy of hydrogen peroxide enhanced endoanal ultrasonography in assessment of the internal opening of an anal fistula complex. *Techniques in Coloproctology*. 2003;**7**:133-137
- [76] Knowles AM, Knowles CH, Scott SM, Lunniss PJ. Effects of age and gender on three-dimensional endoanal ultrasonography measurements: Development of normal ranges. *Techniques in Coloproctology*. 2008;**12**:323-329

