

Chapter

Minimally Invasive Approach in Surgery for Congenital Heart Disease

*Massimo A. Padalino, Demetrio G. Pittarello,
Vladimiro L. Vida and Giovanni Stellin*

Abstract

Surgery for congenital heart disease (CHD) has changed considerably during the last decade. Improved surgical results in patients with simple CHD and new interventional cardiology procedures have stimulated the surgeon to adopt minimally invasive techniques to reduce the patient's surgical insult and obtain good functional and cosmetic results. As a consequence, new surgical techniques and specialized equipment for minimally invasive cardiac surgery (MICS) procedures have been developed and refined in recent years. The improving surgical outcomes in patients with CHD, the significant advances in surgical instrumentation and perfusion technology, and the broad utilization of new catheter-based interventional procedures to repair simple CHD have triggered surgeons' interest to adopt and innovate minimally invasive approaches for CHD repair, so as to reduce patient's surgical trauma and improve functional and cosmetic results while maintaining a high standard of clinical outcomes and possibly shortening hospitalization times. This article reports on our updated full experience and institutional protocols with MICS in children and adults with CHD.

Keywords: congenital heart defects, minimally invasive, surgery, long-term outcomes, cost-effective

1. Introduction

Ever since the first intracardiac repair of an atrial septal defect (ASD) by Lewis and Varco in 1954 [1], congenital heart surgery has continued to evolve, to become a widely available treatment modality with excellent results. Simple defects like an ASD can now be repaired with almost no mortality and morbidity. In the meantime, interventional cardiology has developed significantly effective transcatheter procedures to perform therapeutic closure of simple defects as well as relieving valvar and vascular obstructions. These catheter-based repairs as an alternative to the surgical gold standard have become popular thanks to its minimally invasive appeal and excellent cosmetic outcome. However, sometimes results may be suboptimal [2, 3], and they may also have severe postoperative complications leading to death [4]. However, these procedures are equally well accepted because they are claimed to be "noninvasive." Despite the current advancement of surgical and catheter-based techniques having been pursued for the patient's benefit, as physicians and surgeon,

we have to remember that our goal is to accomplish the optimal repair that ensures a healthy survival, a safe technique, and the best quality of life, either physical or psychological.

There are several surgical approaches that have been proposed as an alternative to the standard sternotomy [5] which have been introduced to reduce the invasiveness of surgery while ensuring the perfect repair. In addition, since a sternal scar, however small, continues to be at a disadvantage because of it attracting a stigma of being a cardiac patient or because of sociocultural issues, other alternatives must be explored. These have included a small incision with a full sternotomy [6], a partial sternotomy or mini-sternotomy [7, 8], a right axillary [9] or anterolateral [10, 11], as well as a posterior thoracotomy [12–14]. However, as more experience was gained, the complete anterolateral thoracotomy (in spite of being once considered superior to a sternotomy) has been less utilized because of reports of thoracic cage deformity (caused by rib deformation and atrophy of severed pectoral muscles) and asymmetric development of breasts when used prepubescently [15]. Utilization of a mini-anterolateral thoracotomy and an appropriate location of the incision away from the nipple area have been reported by our group to avoid these complications in the long term [16, 17].

Thus, the improving surgical outcomes in patients with CHD, the significant advances in surgical instrumentation and perfusion technology, and the broad utilization of new catheter-based interventional procedures to repair simple CHD have triggered surgeons' interest to adopt and innovate minimally invasive approaches for CHD repair, so as to reduce the patient's surgical trauma and improve functional and cosmetic results while maintaining a high standard of clinical outcomes and possibly shortening hospitalization times.

We present our current experience with MICS in patients with CHD, according to our institutional policy.

2. The Padova minimally invasive congenital cardiac surgery protocol

Since the early 1990s, we have continuously adopted a minimally invasive approach to the surgical closure of simple CHD which has evolved through the years to a systematic protocol of MICS for all patients with simple and moderately severe CHD, which includes:

- Routine perioperative transesophageal 2D-echo monitoring (TEE); in small infants weighing less than 4 kg, we have used epicardial 2D echocardiography.
- Postoperative pain control.
- “FastTrack” management (extubation within 3 hours of mechanical ventilation).
- Early discharge from the intensive care unit (ICU).
- Early discharge home (within 4–5 days from the operation) [16].

The surgical approach has always been chosen according to the patient's age, gender, and specific patient's request, balancing safety and effectiveness of the operation and patient's satisfaction after the operation (according to the “gender-differentiated minimally invasive surgery” protocol [7]). For example, a right anterior mini-thoracotomy (RAMT) is less visible in adult females when the incision is within the submammary sulcus. An axillary lateral mini-thoracotomy (RALMT) is

currently offered to both male and females whose weight is higher than 10 kg, for repair of simple CHD such as ASD, partial anomalous pulmonary venous drainage (PAPVD), discrete subaortic stenosis (SAS), membranous ventricular septal defect (VSD), and partial atrioventricular septal defects (p-AVSD). On the contrary, some kind of a mini-sternotomy (MS), meant as limited to the body of the sternum, is offered mostly to infants and children, weighing less than 10 kg, in order to repair lesions other than ASD, such as large VSD with significant left to right shunt in 3–6-month-old infants. In fact, according to our experience, this approach with the help of an appropriate retractor (Bookwalker retractor, Codman Surgical instruments, GS Medical Ltd., Dublin) can guarantee an excellent exposure of the great vessels when other maneuvers are required (i.e., aortic cross-clamping, pulmonary valvotomy, closure of patent ductus arteriosus (PDA)). In addition to these approaches, a right posterior mini-thoracotomy (RPMT) has occasionally been offered as a surgical option in older children and young females, to approach the aortic valve, SAS repair, and VSD closure. Also, from June 2006, as a refinement of our minimally invasive protocol, we have routinely employed peripheral cannulation (usually through right groin vessels) for the cardiopulmonary bypass in patients with simple CHD and a bodyweight superior to 15 kg.

Last, as part of our minimally invasive armamentarium, a video-assisted thoracoscopic surgery (VATS) has also been widely utilized since 1994, for the correction of simple CHD as PDA and vascular rings. However, after the introduction of percutaneous closure of restrictive PDA, we have drastically reduced this practice.

2.1 Transesophageal echocardiography

Routine TEE imaging is helpful in the surgical repair of CHD in children. Performance of TEE in these patients submitted to MICS represents a great contributor to the overall excellence in outcome for CHD. The TEE that has been used intraoperatively since the 1980s [17, 18] is a mainstay of monitoring during simple and complex pediatric cardiovascular surgery [19, 20], especially in MICS, since it provides dynamic control and intraoperative anatomical information but also:

- Allows the surgeon to review the anatomical findings preoperatively.
- Can diagnose myocardial performance.
- Provides an evaluation of postsurgical results and can show residual shunts or other surgical problems that can be addressed during the same operative time (avoiding repeat surgery and its associated costs [21, 22]).
- Allows evaluation of effective de-airing after MICS procedure, enhancing patient's safety in regard to air embolism-related problems.

It has been especially valuable in the operating room where it is used preoperatively to confirm or modify anatomical diagnoses which have been established by TTE and angiography and also identifies possible additional pathologic conditions to delineate anatomy and structural details that may have remained ill-defined by transthoracic imaging [23–25]. The technological advancements, particularly the use of small probe sizes, have significantly improved patient safety and success of cardiac surgery in infants and children [26–33].

The probe is usually inserted by the anesthesiologist, after induction of general anesthesia, and it is used for all the time of operation with a Philips Sonos IE33 echocardiography machines (Philips, Andover, MA) equipped with pulsed,

continuous wave, color Doppler, and 3D capabilities. In patients >20 kg, we have been using an adult probe (xMatrix probe: X7-2t; 3D matrix array probe; 2–7 MHz; Philips, Andover, MA) with 2500 elements per transducer and, on the contrary, in pediatric patients (whose weight is between 4.0 and 20.0 kg), a pediatric probe (Mini Multi probe: S7-3t; 3–7 MHz; Philips, Andover, MA) with 64 elements per transducer and dimensions of 10.7 mm (tip width) and 8.0 mm (tip height).

These clinical benefits, a growing number of highly skilled operators, and improvements in technology have led to the rapid adoption of TEE monitoring in pediatric cardiac surgery with remarkable advances in the management of patients with congenital heart disease in this particular setting.

2.2 Anesthesia care

In recent years, “FastTrack” management (FTM), in the perioperative care of patients with CHD, with early tracheal extubation after cardiac surgery, has become increasingly popular [34–37] especially in MICS, with the delivery of cost-efficient care considered as an additional variable when measuring and comparing surgical outcomes [37, 38].

Potential advantages were previously described [38]:

1. Reduced incidence of airway irritation and ventilator-associated complications (i.e., accidental extubation, laryngotracheal trauma, pulmonary hypertensive crisis during endotracheal tube suctioning, mucous plugging of endotracheal tubes, barotraumas secondary to positive airway pressure ventilation, and ventilator-associated pulmonary infections and atelectasis)
2. Reduced parental stress
3. Reduced requirements of sedation and potential associated hemodynamic compromise
4. More rapid patient mobilization
5. Earlier ICU discharge
6. Decreased length of hospital stay
7. Reduced costs (ventilator-associated and length of ICU/hospital stay)

In this context, anesthesia should not be managed by a strict protocol. A general institutional approach for children who are candidates to FastTrack extubation consisted of induction of anesthesia with thiopental 5 mg/kg, fentanyl 3 mcg/kg, and rocuronium 0.9 mg/kg. During surgery and cardiopulmonary bypass (CPB), anesthesia is maintained with remifentanyl 0.5–1 mcg/kg/min and propofol 3–5 mg/kg. Muscle relaxants are given again before CPB at 0.15 mg/kg. The patient is monitored as routine (ECG, pulse oximetry, invasive arterial pressure, central venous pressure, diuresis, temperature, and somatic and cerebral near-infrared spectroscopy (NIRS)). Shortly before the end of the surgery, remifentanyl is discontinued, and intravenous morphine (0.1–0.2 mg/kg) or fentanyl (1–2 mcg/kg) is administered. When surgery is over, according to FTM protocol, the neuromuscular block is reversed by the intravenous administration of atropine, 0.01 mg/kg, and neostigmine, 0.05 mg/kg. Immediate post-extubation analgesia or sedation in children includes a single administration of rectal paracetamol (40–50 mg/kg),

a bolus of morphine 0.05 mg/kg iv or fentanyl 0.5–1 mcg/kg iv, and/or midazolam 0.05–1 mg/kg iv, with repeated boluses as needed.

For the first 24 postoperative hours, morphine is given by continuous iv in most patients. Pain scores and vital signs are recorded by the bedside nurse, on an hourly basis throughout the day, or, when appropriate, by the parents or even by the child, if it is old enough to report his/her pain scores on a 0–10 pain scale. Supplemental analgesia is administered if required, according to the recorded pain scores.

Despite this program, extubation in the OR after pediatric cardiac surgery is to be meditated. In order to migrate to a routine practice of early extubation, it is necessary that surgeons, anesthesiologists, intensivists, perfusionists, and nurses have the same mindset and cooperate to achieve this goal and the final decision. Extubation, either in the operating room or in the ICU, is usually decided based on clinical evaluation and also considering some operative parameters such as bypass and aortic cross-clamp times, the complexity of surgery, requirement of high dosage inotropic support, hemodynamic stability, and occurrence of persistent bleeding. Operating room extubation is usually not performed if there are signs of airway compromise, hemodynamic instability requiring bolus delivery of vasopressors, cardiac rhythm instability, excessive bleeding, or core temperature < 35°C.

In patients submitted to VATS, postoperative pain is significant, especially early after surgery [39, 40], and higher than sternotomy. For these reasons, there has been an increased interest in the use of paravertebral block (PVB). The intercostal nerves are relatively devoid of covering fascia as they traverse the paravertebral space, making it an ideal location for local anesthetic blockade [41]. The PVB technique includes the use of ultrasound [42] with a linear probe at high frequency in pediatric patient with weight > 15 kg, alternatively, which can be performed by a single injection at the level of paravertebral space intraoperatively under direct vision by the surgeon [43] or anesthesiologists prior to chest closure [44]. The single-shot multilevel PVB with ropivacaine 0.5% has a place in these procedures (max 0.4 ml/kg at the fifth intercostal space), with analgesic benefits seen in the first few hours, and can reduce long-term adverse pain outcomes.

In this kind of patients, a change in the attitude of surgeons, anesthesiologists, perfusionists, and nurses, combined with appropriate anesthetic and surgical techniques, permitted better results and outcomes.

2.3 Cardiopulmonary bypass and operative strategies

According to our minimally invasive surgical protocol [45], a direct aortic and bicaval cannulation is usually employed in patients with a body weight of less than 10 kg. Since 2006, in larger patients, we have routinely used a peripheral arterial and venous cannulation [46–48] for establishing the cardiopulmonary bypass (CPB). This is achieved by percutaneous cannulation of the superior vena cava (SVC) followed by surgical isolation and cannulation of the femoral vessels (**Figure 1**).

The SVC peripheral cannulation is usually performed by a trained anesthesiologist with experience with patients with CHD, using 2D transesophageal echo (TEE) guidance (**Figure 2**), after 100 U/kg of heparin has been systemically administered [46]. The internal jugular vein is punctured and dilated, and then an SVC (Medtronic Biomedicus 96,570 Next Gen, MN, USA) is inserted and positioned under TEE monitoring, about 1 cm above the SVC-right atrial junction. Currently, we reserve this approach to DVAPP, in which the presence of pulmonary veins in the SVC may complicate the traditional SVC cannulation through a small incision. In all other cases, as experience has increased, we have recently moved to a direct SVC cannulation with a right angle metal tipped venous cannula (Medtronic DLP single

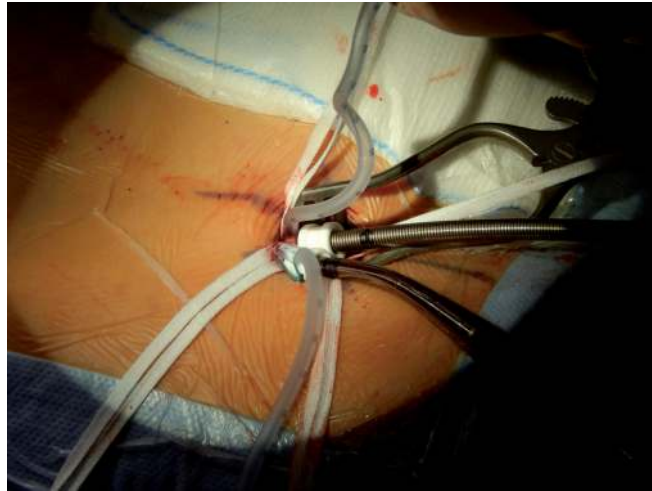

Figure 1.
Exposure of the femoral artery and vein is obtained by means of a transversal skin incision (2 cm in length) along with the groin folder (bikini incision).

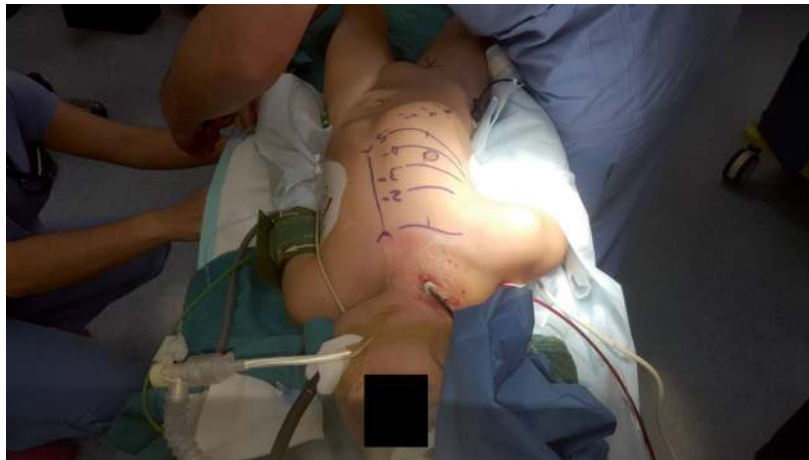

Figure 2.
Percutaneous cannulation of the internal jugular vein utilizing a venous cannula (bio-Medicus Medtronic, USA), inserted using standard echo-guided modified Seldinger technique.

stage venous) through a usual 5.0 Prolene purse string on the right atrium or in the SVC when approach is through an ALT, where SVC is very well exposed (**Figure 3**).

A 2 cm incision is employed at the inguinal fold (**Figure 1**) for exposing the femoral artery and vein. After full systemic heparinization has been achieved (with activated clotting time (ACT) > 400 s), direct arterial cannulation is usually accomplished with a femoral arterial cannula with introducer (Medtronic Biomedicus 96,570 NextGen MN, USA). Venous cannulation (Medtronic Biomedicus 96,670 NextGen MN, USA femoral venous cannula) is then performed using the Seldinger technique under TEE guidance that can clearly show the guide in the right atrium.

In children weighing less than 15 kg, the femoral artery may be too small for safe cannulation; for this reason, we prefer central cannulation in the ascending aorta, utilizing a FEM FLEX arterial cannula, fixed with double 4.0 Ticron purse string. This mixed cannulation approach has allowed us to extend MICS to children as small as 10 kg.

When femoral arterial cannulation is performed, we routinely monitor both lower extremities by NIRS, with sensors positioned on the anterior side of the thigh,

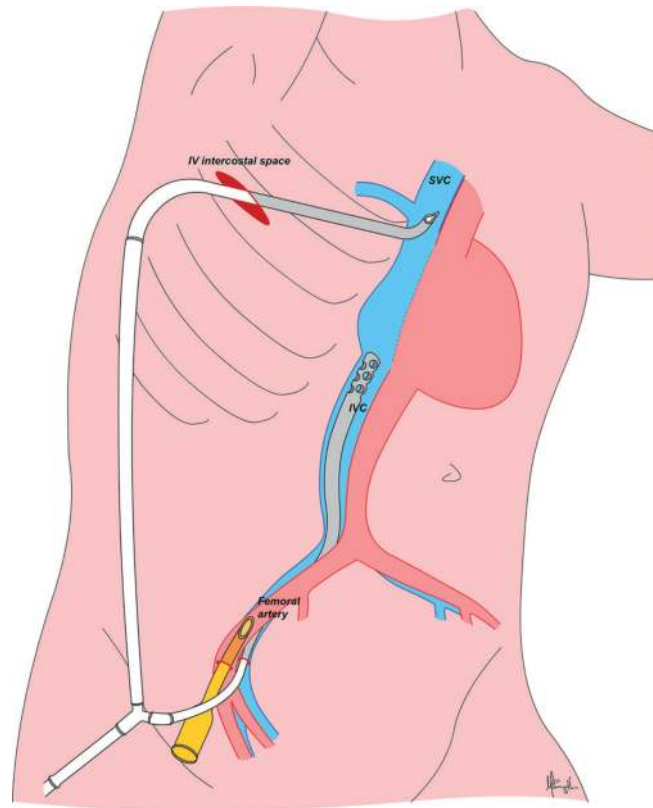


Figure 3.
Diagram showing direct superior vena cava cannulation through the RALMT, with a right angle metal tipped venous cannula.

so as to check for any oxygen saturation variations in the cannulated leg during the extracorporeal perfusion [48].

Assisted venous drainage (with a maximum vacuum of 50 mmHg) is adopted to minimize the size of tubing and venous cannulas (that are usually one to two under the estimated size for a patient's body surface area [BSA]). Once the cardiopulmonary bypass is started, mild hypothermia (rectal temperature of 34–35°C) is reached [45].

At full flow, once the venae cavae are snared, ventricular fibrillation is induced by an epicardial electrode and cable connected to a fibrillator (Fi 20 M, Stockert, Livanova Group, Munich, Germany) in all patients requiring a RAMT. On the contrary, when a MS or RPMT is used, a conventional aortic cross-clamping with cold hematic cardioplegia may be employed as an alternative.

At the end of the intracardiac repair, an accurate de-airing of the left cardiac sections is performed under transesophageal 2D-echocardiographic monitoring, on Trendelenburg position. The de-airing is obtained by filling the left cardiac chambers with saline solution before declamping or defibrillating. Sustained blow ventilation is always performed by the anesthesiologist to clear the left atrial chamber from residual air bubbles. During induced ventricular fibrillation time, it is essential to avoid blood suction inside the left cardiac sections.

After surgical repair is completed and the intracardiac de-airing is completed, the induced fibrillation is discontinued. An intravenous lidocaine bolus of 1 mg/kg is given, and the heart is promptly defibrillated by external direct current shock (3–5 J/kg) when sinus rhythm is not naturally restored. In patients requiring aortic cross-clamping, a further de-bubbling is achieved through the cardioplegia needle by continuous suction, before and after clamp removal.

At the end of CPB, systemic heparinization is reverted, and the femoral cannulas are then removed. After chest closure, the SVC cannula is removed by the anesthesiologist. As a routine, the femoral vessel patency is checked by 2D-echo and Doppler, before discharge.

After completion of the procedure, decannulation and hemostasis are performed. The opened pericardium is partially approximated with interrupted stitches; this is suggested to avoid rare but potentially lethal complications such as cardiac herniation [49]. A subperiosteal epidural catheter is placed in the posterior intercostal groove created extrapleurally for bupivacaine infusion. A thorax drain is inserted and the thorax closed in layers.

3. Minimally invasive surgical approaches

3.1 Mini-sternotomy

As previously described [45], a 4-cm skin incision in the midline of the chest, with its superior margin at or approximately 1–2 cm below the nipple level, is employed (**Figure 4**). The sternum is longitudinally divided in its lower third, up to its body and retracted to expose the great vessels. When central cannulation is employed, the inferior vena cava cannula is passed through a separate 5-mm skin incision (which is later utilized for the chest drainage insertion).

The MS approach is usually used for surgical repair of simple CHD lesions as ASD, VSD, PAPVD, and p-AVSD in infants and children. Whenever the child is older than 5 years, the sternal bone is more rigid, and the simple MS may not allow a safe exposure of ascending aorta. For this reason, we usually utilize a T-incision (**Figure 5**) which consists in an extension of the midline sternal incision about 5–10 mm laterally (right and left) at the level of the third intercostal space, without reaching the external border of the sternal body and the mammary artery. This incision can be safely performed with an oscillatory saw. The application of a reverse T mini-sternotomy has also been applied to young adults for aortic valve repair or replacement, with or without associated ascending aorta vascular graft replacement. The right pleura is routinely opened, and the pericardium is incised laterally down to 1 cm from the right phrenic nerve to create a sort of pericardial window, to avoid possible cardiac tamponade in case of severe postoperative pericardial effusion.

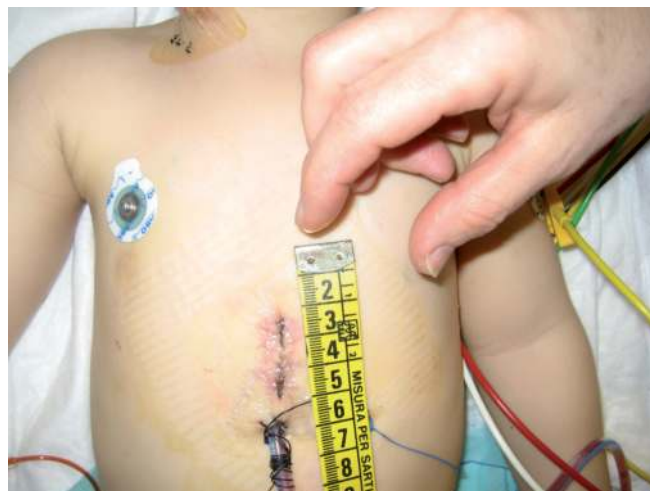


Figure 4. Mini-sternotomy approach: The cutaneous incision (3–5 cm long) is done below the line between the two nipples.

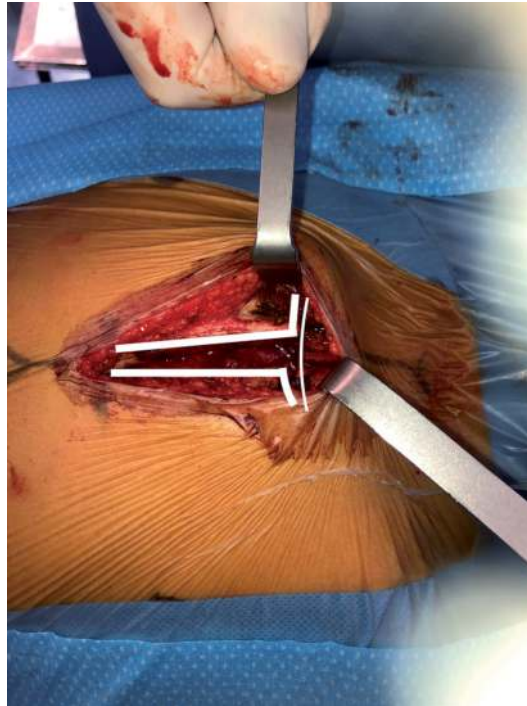


Figure 5.
T-sternal incision mini-sternotomy (T-MT) is useful in older children to expose the great vessels adequately.

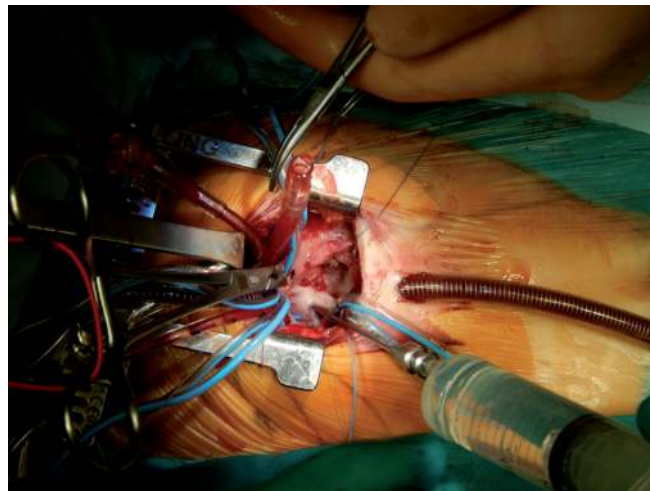


Figure 6.
Right anterior mini-thoracotomy approach.

3.2 Right anterior mini-thoracotomy

We use this technique mainly in female patients (some children but mostly teenagers and adults) for ostium secundum type ASD closure, as an alternative to an MS. In RAMT, a 4-cm semilunar incision in the sulcus of the right breast is entering the chest in the fourth intercostal space (**Figure 6**). In the prepuberty age, the incision is kept very low under the right nipple (at about 5–8 cm away from the nipple area [7, 16]), particularly in female patients, to avoid any possible future interference with breast development [45]. Subcutaneous fat and mammary gland are gently dissected from the fascia up to the fourth intercostal space, where the chest cavity is entered. The incision of the intercostal space is approximately 1 cm longer

than the skin incision at each side. A video-assisted optical technology using a 5 mm 0° optical scope, which is inserted through a separate 5 mm incision, in the fourth intercostal space, may be helpful to implement the surgical vision [45], but with increased experience we have realized that this aid is rarely necessary for infants and children. In patients >15 kg who undergo peripheral cannulation, the SVC is usually occluded with a cross-clamp that is inserted through a separate lateral 5-mm incision that is later utilized for inserting chest drainage.

3.3 Right posterior mini-thoracotomy

In our hands, this approach has been ideal for treating discrete SAS, PAPVD, and sinus venosus ASD. This technique was introduced for simple CHD since 2001. After the original description by Metras and Kreitmann in 1999 [14] for repairing simple CHD, we have modified it from a classic wide right posterior thoracotomy to a mini-thoracotomy, the RPMT (**Figure 7**). Currently, a 4-cm subscapular incision is employed for entering the chest in the fourth intercostal space [45]. This technique has been mainly used in female patients (under specific patient's request). Through this surgical approach, the aorta can be easily visualized and cross-clamped, and aortic valve area can be exposed.

3.4 Right axillary lateral mini-thoracotomy

The right axillary lateral mini-thoracotomy is currently out the approach of choice since it can be safely and efficiently employed for repair of various types of moderately severe CHD, similar to standard surgical procedures, either in adults or in children as small as 10 kg. A right axillary incision provides the best direct plane of vision to the atrial septum, AV valves, and the membranous ventricular septum (**Figure 8**). On the contrary, we do not suggest this approach for conal septal defects or pulmonary valve procedures, since the right ventricular outflow tract is not accessible to expose, and there is the potential risk of a suboptimal repair and postoperative residual defects or complications. Also, the axillary area is one of the least muscularly covered parts of the thoracic cage, allowing for less invasive trans-thoracic access to the heart. Last, the subaxillary location of the scar, being far away from the breast and being naturally covered by a resting arm, provides an excellent cosmetic result, either in female or in male patients. At the beginning of our experience, we primarily employed this approach to close ostium secundum type ASD. As

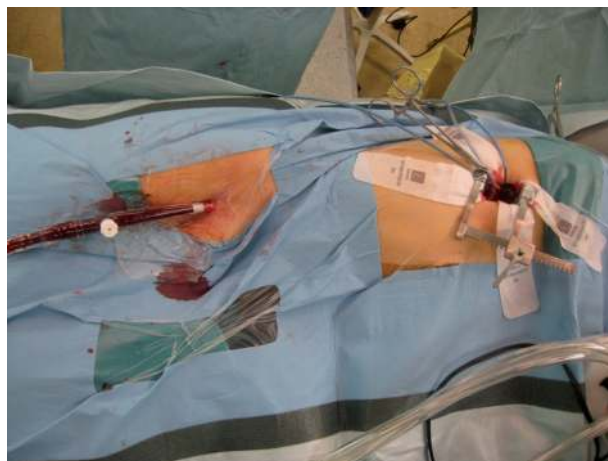


Figure 7.
Right axillary lateral mini-thoracotomy approach.

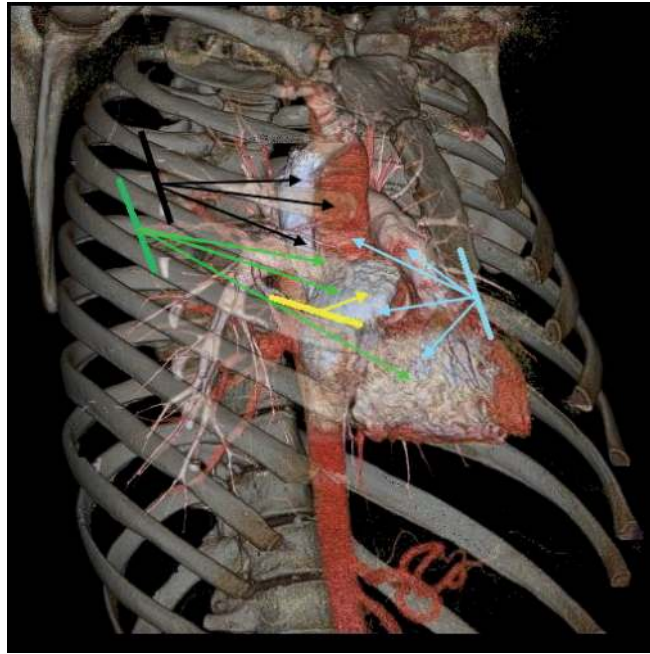


Figure 8.

Minimal invasive approaches and cardiac structure exposure. Angio-CT scan 3D reconstruction in a control patient (right oblique anterior view) showing different minimally invasive surgical chest approaches and their relationship with the cardiac structures and their related capability of exposing them adequately: (A) mini-sternotomy (light blue) shows atrial and ventricular septa and the great vessels. (B) Right anterior mini-thoracotomy (yellow) shows atrial septum; (C) right axillary lateral mini-thoracotomy to perform various procedures on the superior vena cava and aorta through III intercostal space (black) and on the atrial or membranous ventricular septa through the IV intercostal space (green).

we gained experience and confidence about exposure of various parts of the heart, application of this approach has been extended to the correction of other CHD, such as PAPVC of right-sided pulmonary veins (including performance of the Warden procedure—SVC reinsertion onto the RA appendage), the scimitar vein syndrome (off pump relocation of the anomalous vein to the left atrium), partial AVSD, SAS, and restrictive peri-membranous/subaortic VSD.

The patient is placed in a left lateral decubitus, with slightly backward reclining position. The lower torso and pelvic region are placed in a 45-degree position to allow access to the inguinal region (**Figure 9**). Marked anterior and median axillary lines and the appropriate intercostal space are used as guiding parameters for the proper axillary incision. In fact, a third intercostal space may be better for DVAPP repair, since it allows a perfect exposure of the entire SVC area to the innominate vein, while a fourth or fifth intercostal space is better indicated for ASD or VSD or mitral valve exposure. An oblique incision is performed in the right axilla from the median to the anterior line, not extending the latter one. The skin is undermined to be able to slide to the desired operative field. The latissimus dorsi is mobilized free of its fascial attachments, and the digitations of serratus anterior overlying the intercostal space are identified and split. The thoracotomy is performed with a subperiosteal entry through the superior margin of the rib. The pericardium is opened 2 cm anterior to the phrenic nerve. Placing stay sutures along both the margins of the pericardium should be placed so as to expose the field as much as possible. Sometimes, the institution of CPB through inguinal cannulation and deflation of the lungs are necessary to achieve adequate exposure of the heart. In patients older than 15 years or weighing more than 25 kg, a selective bronchial intubation is feasible and highly recommended so as to deflate the right lung and keep the left lung inflated during the procedure (whose inflated volume can push

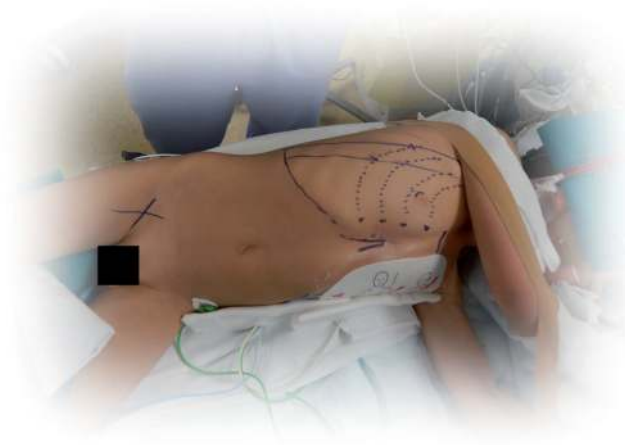

Figure 9.

Operative position of the patient undergoing a RALMT; the patient is rotated in left lateral decubitus, and the proposed incision lines are shown.

up the heart and allow for a better exposure of the surgical field). This is especially true in adults with big chest or overweight patients.

3.5 Left posterior extrapleural mini-thoracotomy (LPEMT)

As we have previously reported [45], a left posterior extrapleural mini-thoracotomy may be used for PDA closure [50] as an alternative to VATS closure, according to surgeon's preferences and especially in children with a body weight greater than 3 kg. On a right lateral decubitus position and through a limited left subscapular skin incision (usually 2–3 cm) and total muscle-sparing technique, the superficial thoracic fascia muscularis is incised [50]. The parietal pleura is carefully detached from the thoracic wall with blunt dissection. A triple ligation closes the PDA. The left lung then is re-expanded for preventing air entrapment within the extrapleural space, and the chest is usually closed without the use of chest drainage. This is a straightforward technique that is preferred in patients with a bodyweight of less than 20 kg carrying low postoperative complications when compared with the transpleural approach [50]. This LPEMT procedure with no need for intensive care and hospitalization of only 24 hours has been reported to be cost-effective [50] when compared to traditional transpleural approach, which requires a more extended hospitalization, or to percutaneous procedures, in which the costs of a single or multiple coils, or an Amplatzer device, make costs increase stellarly. In conclusion, the minimally invasive skin and muscle splitting LPEMT technique is a safe and effective procedure, more cosmetic and significantly less expensive than other standard procedures (surgical or percutaneous, respectively).

3.6 Video-assisted thoracoscopy

Video-assisted thoracoscopy has been widely utilized in over 200 patients for PDA closure, before the broad application of percutaneous PDA occlusion. Nowadays, its application is drastically reduced but may be an alternative for infants and children less than 10 kg (or under specific patient's request) [51] and for relieving respiratory/digestive compression caused by vascular rings. Technically, we have described previously this procedure [45]: the patient is put on the right

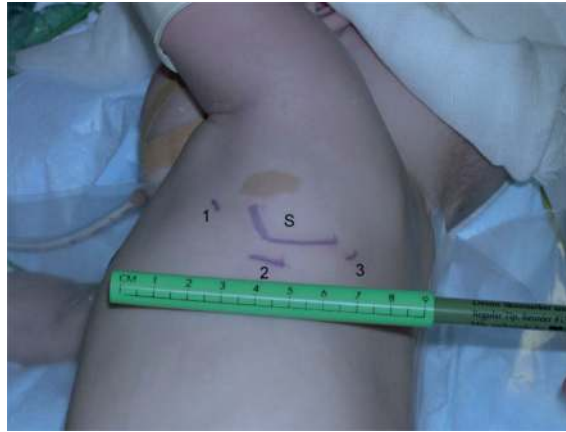

Figure 10.

Patent ductus arteriosus VATS closure. On right decubitus, three mini-incisions are done along with the fourth intercostal space: Two 5-mm long incisions (1 and 3) for the introduction of the surgical instruments in the chest and one 10-mm incision below the tip of the scapula, for the optical camera probe.

lateral decubitus position; three incisions are made around the left scapula (2 of 5 mm and 1 of 10 mm, **Figure 10**). After lung retraction and dissection of the surrounding anatomical structures, a single titanium clip 10 mm long is squeezed tight on the aortic junction of the duct. The complete closure of the duct is routinely assessed in the operating room through cross-sectional and color Doppler echocardiographic imaging, which can be performed with transesophageal or transthoracic echocardiography. In the case of residual shunting, a second clip may be applied. Patients are usually extubated in the operating room and discharged the following day. However, VATS equipment is not everywhere available because of cost considerations.

4. Our 22 years of surgical experience

From 1996 to 2018, we have treated with MICS techniques 976 patients affected by CHD (M/F 387/589). Overall, the median age at repair was 5 years (interquartile range 1.7–11 years). The most common CHD was ASD secundum type in 557 patients (57%), while the remaining were affected by other anomalies (VSD, p-AVSD, PAPVD, SAS). In particular, a large VSD patch closure was performed by MS in 145 infants <1 year of age (14.8%). Minimally invasive access was a midline MS in 452 patients (median age 2, IQR 0.5–5 years), RAMT in 356 (median age 9, IQR 4–20 years), and a RALMT in 168 (median age 9, IQR 6–14 years).

All patients required CPB, and peripheral cannulation was used in 191 patients (19.5%); it is of note that almost all patients undergoing RALMT underwent peripheral cannulation (96%). Induced ventricular fibrillation was used in 598 patients (61.3%), while aortic cross-clamping was employed in the remaining, with a median cross-clamping time of 16 min (IQR 9–25).

There were no early and late deaths at operation. Minor postoperative complications occurred in 110 patients (11.2%), being 39 (35.6%) post-pericardiotomy syndrome. Median intensive care unit stay was 1 day (IQR 1–2), and all patients were discharged home after a median stay of 5 days (IQR 4–6). All clinical preoperative, operative, and postoperative data divided by minimally invasive approach are described in detail in **Table 1**.

<i>Variable</i>	MS	RAMT	RALMT	p-value
<i>(Patients)</i>	(452)	(356)	(168)	
Malc*	245 (56)	52 (15)	90 (54)	<0.0001
ASD II*	138 (31)	337 (95)	82 (49)	<0.0001
VSD < 1 aa*	145 (32)	-	-	<0.0001
Other CHD*	169 (37)	19 (5.3)	86 (51)	<0.0001
Age at operation (years)**	2 (0.5-5)	9 (4-20)	9 (6-14)	<0.0001
Age > 18 aa at operation*	6 (1.3)	94 (26)	34 (20)	<0.0001
Weight at operation (kg)**	11 (6-18)	27 (17-52)	30 (19-52)	<0.0001
Peripheral cannulation*	17 (3.8)	103 (29)	161 (96)	<0.0001
CPB time (min)**	70 (43-96)	35 (27-50)	47 (32-71)	<0.0001
ACC*	292 (65)	12 (3.4)	77 (46)	<0.0001
ACC time (min)**	48 (36-60)	37 (32-51)	40 (34-55)	<0.0001
IFV*	161 (36)	344 (97)	93 (55)	<0.0001
IFV time (min)**	14 (9-21)	16 (11-25)	17 (13-25)	<0.0001
ICU stay (days)**	2 (1-2)	1 (1-1)	1 (1-1)	<0.0001
ICU stay > 2 days*	66 (15)	2 (0.6)	2 (1.2)	<0.0001
Total Hospital stay (days)**	5 (4-7)	5 (5-6)	4 (3-5)	<0.0001
Postoperative complications*	71 (16)	18 (5)	21 (13)	<0.0001
Post-pericardiotomy syndrome*	27 (6)	10 (2.8)	2 (1.2)	0.009
Blood transfusion*	208 (46)	37 (10)	3 (1.8)	<0.0001

* number of patients and percentage (%); ** median and interquartile range (IQR).

ACC, aortic Cross Clamping; ASD II, atrial septal defect secundum type; CHD, congenital heart disease; CPB, cardio-pulmonary bypass; ICU, intensive care unit; IVF, induced ventricular fibrillation; MS: mini-sternotomy; RALMT, right axillary mini-thoracotomy; RAMT: right anterior mini-thoracotomy; VSD, ventricular septal defect.

Table 1.

Clinical preoperative, operative and postoperative data by minimally invasive approach (n = 976) since 1996.

5. Discussion

Recent technological advances have enabled treatment for a wide range of CHD, with excellent early and late results. As a consequence, both children and adults with CHD can now expect better outcomes. In the last decade, however, surgical techniques have also centered around the reduction of trauma and postoperative recovery time and even improvement of cosmetic results. A standard median sternotomy has been the conventional approach for correction of congenital cardiac defects for many years, but it often yields to unsatisfactory esthetic results [6, 7, 52]. Unsightly midline scars arouse displeasure and psychological distress, especially in young female patients. Minimally invasive cardiac surgery can offer real value to the patients, be it cosmetic, psychological (no scar in the front), biological (less bleeding, less pain, less sternum deformity without division of the manubrium), or even sociocultural (as in some Middle Eastern countries, in which a frontal scar in female patients is considered as a doom). However, these techniques have had particular application in congenital cardiac surgery when compared with adults.

It is true that MICS in this context is mostly about minimally invasive incisions, while real minimally invasive procedures which avoid utilization of cardiopulmonary bypass are under evaluation nowadays. For the surgical approach, CPB-assisted operations with minimal thoracotomies or “hybrid procedures” have been described.

Nowadays, ASD can usually be closed by an interventional cardiologist, unless morphological features are unfavorable. This can be called a true minimally invasive method since no incision and, mostly, no CPB is involved in the procedure. It is, in fact, CPB that is more invasive since it can trigger the so-called systemic inflammatory syndrome, which is proportional to the CPB time and inversely proportional to BSA [50]. Any other attempt is rather “minimal access” surgery. However, surgery does not require X-ray exposure and allows complete repair using biological or physiological materials such as autologous or heterologous pericardium. On the contrary, current transcatheter procedures require prolonged X-ray exposure [51], and septal defect closure devices are made of a rigid metal material that is bound to stay inside the heart forever: is this going to be safe forever? Some authors have reported late device dislocation and higher risk late reoperation [5]: is this acceptable for ASD?

On the other side, Butera et al. [2] reported that ASD closure by percutaneous approach has a significantly lower rate of either total or major early post-procedural complications than surgery. However, costs remain high, and financial issues are a matter of concern in many countries with public health system. During the last few years, with increasing experience, we have observed a significant reduction in the operative times without increased risk, when compared with conventional surgery [16]. The median cost for treatment of ASDs was 7275 euros (IQR 6975-7515 euros). According to scatterplot analysis, we showed a progressive reduction of hospital costs over time ($P = 0.009$) (**Figure 11**).

In the light of our results, we are now extending our minimally invasive approaches to CHD which are more complex than ASD. Besides, the safety of the peripheral CPB convinced us to employ it progressively to lower body weight patients. We believe that soon, due to the miniaturization of surgical instruments, cannulas, and tubing systems, we will spread the use of minimally invasive surgery with peripheral CPB in even smaller children.

Since many years, it has been our institutional policy to promote a gender-differentiated minimally invasive approach for patients with CHD [52]. This has proven to be safe, and it offers excellent clinical results comparable to classic more invasive methods. In addition, in our experience, we have demonstrated a 95% patient satisfaction after RAMT, with no evidence of scoliosis, restriction to shoulder movement, breast development, or lactation problems at follow-up [15]. The only complication we could outline in our female patients with mini-thoracotomy (MT) was a temporary trivial neuro-sensorial deficit at the mammary area that disappeared in all within 6 months after surgery. In addition to the benefit of a limited cutaneous incision, a careful and gentle muscle plane dissection and reconstruction is certainly related to the high quality of our results. It is highly advisable that the MT incision be located very low in the submammary area, usually at least 4–5 cm under the right nipple and away from any possibility of future breast development.

The RALMT has been added relatively recently in our minimally invasive surgical armamentarium [45], and it has rapidly gained affidability as it has proven to be an effective and safe approach to correct patients with PAPVD from the right lung (which is even easier to identify from this approach). Also, it allows excellent visualization of the aortic root when needed (i.e., aortic cross-clamping or access to the aortic valve or sub-valvar area).

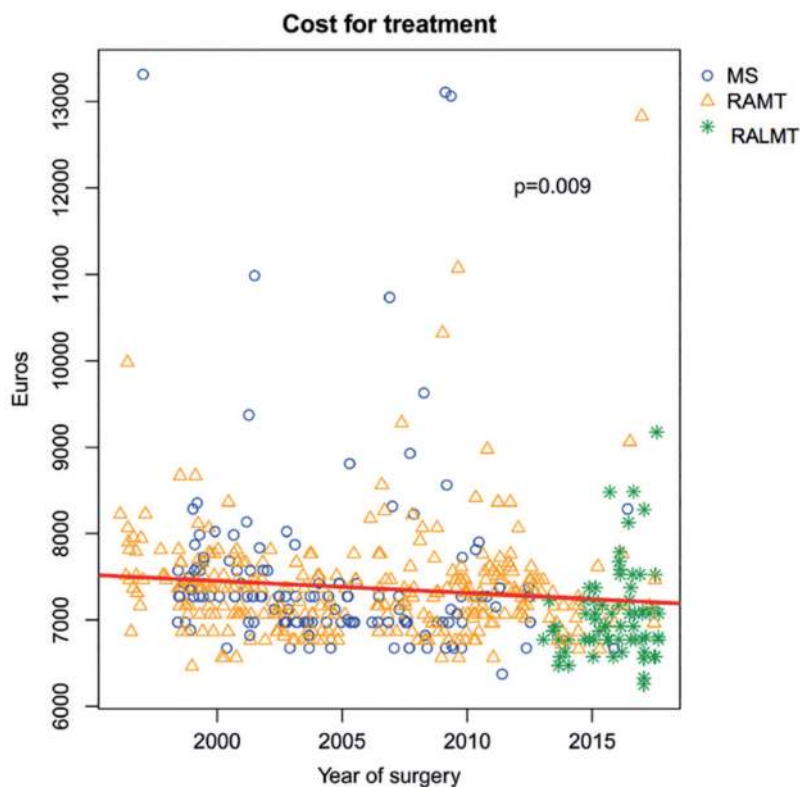


Figure 11.

Scatterplot showing the variation of the overall cost of treatment for surgical ostium secundum atrial septal defect closure, by year of surgery. MS, mini-sternotomy; RAMT, right anterior mini-thoracotomy; RALMT, right lateral mini-thoracotomy (modified from Vida et al. [16]).

In our two decades of experience, induced ventricular fibrillation has been a safe and reproducible technique, which we have always associated with mild systemic protective hypothermia [7, 25, 26]. It avoids cumbersome cross-clamping and consequently allows smaller access especially in RAMT or RALMT approaches. Nonetheless, we are also aware that a cross-clamping through RAMT can also be used when needed [28]. With the recent introduction of the RALMT, which exposes the ascending aorta much better, aortic cross-clamping can be quickly done employing a Novare Straight Cygnus Aortic Cross Clamp in adults or even with conventional Chitwood clamps in children.

Intraoperative TEE echocardiographic monitoring is of paramount importance in such limited surgical exposure since it can ensure a total de-airing of the left chambers together with a complete assessment of the surgical correction and detection of possible residual lesions. Furthermore, the utilization of Trendelenburg position as a default position during open heart surgery on induced FV is a new safety strategy to prevent a cerebral air embolism.

The use of a peripheral CPB has been shown to be a safe and excellent option in selected patients [18, 19], since it permits minimal surgical incisions, consequently reducing the patient's surgical trauma. As mentioned above, the NIRS monitoring of the blood perfusion to the lower extremities in patients with peripheral CPB is a useful tool to control blood flow perfusion variations to the lower extremities during CPB time. It is of notice that we were never required to convert peripheral to central CPB because of issues with lower limb blood flow. However, critical NIRS levels (<30%) has been reached in patients with a bodyweight of less than 15 kg for a maximum period of 30 min, which has entirely normalized after arterial

decannulation as did the postoperative myoglobin and creatine phosphokinase levels (within 12 hours). Last, we needed to patch repair the femoral artery only in five patients among all. However, as we shifted to the subaxillary (muscle sparse) approach, we have switched to central aortic cannulation utilizing the same arterial cannula (Medtronic Bio-Medicus NextGen MN, USA), to avoid residual stenosis in borderline femoral arteries (in children < than 15 kg).

6. Conclusions

Minimally invasive cardiac surgery for CHD consists in the minimization of surgical access with consequent reduction of surgical trauma, reduced postoperative pain, and a more prompt recovery that can permit a decrease in hospital stays and costs. Despite minimal incisions, in our hands, these techniques have allowed optimal repair which is comparable to the conventional surgery ones in terms of safety, with an additional better cosmetic result and a better-perceived quality of the treatment by the patients, especially female, with less psychological discomfort caused by the more traditional sternal scars. The technological advancement (such as vacuum-assisted venous drainage, new retracting systems, and the use of peripheral cannulation for CPB) has permitted further miniaturization of our incisions without increasing patients' morbidity and, on the contrary, improving results and patients' satisfaction. The recent lateralization of surgical access has added another benefit contributing to an increase in the types of CHD we can treat, with no additional risk. Nowadays, MICS for CHD continues to evolve and expand with growing technology and surgeon experience. It is safe and effective for various types of CHD, and it does not appear to result in significant differences in short-term and long-term survival and freedom from adverse events when compared with the more traditional midline sternotomy approaches. It seems to result in faster recovery to healthy routine life, reducing the length of hospital stay and better satisfaction among patients. As this compares favorably with percutaneous techniques, MICS for CHD is now to be considered the gold standard for surgical repair of simple and moderately severe CHD which are not amenable or borderline for transcatheter repair.

Acknowledgements

We acknowledge Mr. Nicola Paccagnella (Department of Cardiac, Thoracic, Vascular Sciences and Public Health, University of Padova Medical School, Italy) for the artwork. We had no fundings.

Conflict of interest

The authors declare no conflict of interest.

Acronyms

CHD	congenital heart disease
LPEMT	left posterior extrapleuric mini-thoracotomy
MICS	minimally invasive cardiac surgery
MS	midline mini-sternotomy

RAMT	right anterior mini-thoracotomy
RALMT	right axillary lateral mini-thoracotomy
RPMT	right posterior mini-thoracotomy


Author details

Massimo A. Padalino*, Demetrio G. Pittarello, Vladimiro L. Vida
and Giovanni Stellin

Department of Cardiac, Thoracic, Vascular Sciences and Public Health, University
of Padova Medical School, Italy

*Address all correspondence to: massimo.padalino@unipd.it

IntechOpen

© 2020 The Author(s). Licensee IntechOpen. This chapter is distributed under the terms
of the Creative Commons Attribution License ([http://creativecommons.org/licenses/
by/3.0](http://creativecommons.org/licenses/by/3.0)), which permits unrestricted use, distribution, and reproduction in any medium,
provided the original work is properly cited. 

References

- [1] Lewis FJ, Varco RL, Taufic M. Repair of atrial septal defects in man under direct vision with the aid of hypothermia. *Surgery*. 1954;**36**:538-556
- [2] Butera G, De Rosa G, Chessa M, Rosti L, Negura DG, Luciane P, et al. Transcatheter closure of atrial septal defect in young children: Results and follow-up. *Journal of the American College of Cardiology*. 2003;**42**:241-245
- [3] Thomson JD, Aburawi EH, Watterson KG, Van Doorn C, Gibbs JL. Surgical and transcatheter (Amplatzer) closure of atrial septal defects: A prospective comparison of results and cost. *Heart*. 2002;**87**:466-469
- [4] Sarris GE, Kirvassilis G, Zavaropoulos P, Belli E, Berggren H, Carrel T, et al. Surgery for complications of transcatheter closure of atrial septal defects: A multi-institutional study from the European congenital heart surgeons association. *European Journal of Cardio-Thoracic Surgery*. 2010;**37**:1285-1290
- [5] del Nido PJ. Minimal incision congenital cardiac surgery. *Seminars in Thoracic and Cardiovascular Surgery*. 2007;**19**:319-324
- [6] Cremer JT, Boning A, Anssar MB, Kim PY, Pethig K, Harringer W, et al. Different approaches for minimally invasive closure of atrial septal defects. *The Annals of Thoracic Surgery*. 1999;**67**:1648-1652
- [7] Nicholson IA, Bichell DP, Bacha EA, del Nido PJ. Minimal sternotomy approach for congenital heart operations. *The Annals of Thoracic Surgery*. 2001;**71**:469-472
- [8] Kadner A, Dodge-Khatami A, Dave H, Knirsch W, Bettex D, Pretre R. Closure of restrictive ventricular septal defects through a right axillary thoracotomy. *The Heart Surgery Forum*. 2006;**9**:E836-E839
- [9] Mishaly D, Ghosh P, Preisman S. Minimally invasive congenital cardiac surgery through right anterior minithoracotomy approach. *The Annals of Thoracic Surgery*. 2008;**85**:831-835
- [10] Grinda JM, Folliguet TA, Dervanian P, Mace L, Legault B, Neveux JY. Right anterolateral thoracotomy for repair of atrial septal defect. *The Annals of Thoracic Surgery*. 1996;**62**:175-178
- [11] Yoshimura N, Yamaguchi M, Oshima Y, Oka S, Ootaki Y, Yoshida M. Repair of atrial septal defect through a right posterolateral thoracotomy: A cosmetic approach for female patients. *The Annals of Thoracic Surgery*. 2001;**72**:2103-2105
- [12] Houyel L, Petit J, Planche C, Sousa-Uva M, Roussin R, Belli E, et al. Right postero-lateral thoracotomy for open heart surgery in infants and children. Indications and results. *Archives des Maladies du Coeur et des Vaisseaux*. 1999;**92**:641-646
- [13] Metras D, Kreitmann B. Correction of cardiac defects through a right thoracotomy in children. *The Journal of Thoracic and Cardiovascular Surgery*. 1999;**117**:1040-1042
- [14] Bleiziffer S, Schreiber C, Burgkart R, Regenfelder F, Kostolny M, Libera P, et al. The influence of right anterolateral thoracotomy in prepubescent female patients on late breast development and on the incidence of scoliosis. *The Journal of Thoracic and Cardiovascular Surgery*. 2004;**127**:1474-1480
- [15] Vida VL, Tessari C, Fabozzo A, Padalino MA, Barzon E, Zucchetta F, et al. The evolution of the right

anterolateral thoracotomy technique for correction of atrial septal defects: Cosmetic and functional results in prepubescent patients. *The Annals of Thoracic Surgery*. 2013;**95**:242-247

[16] Vida VL, Zanotto L, Zanotto L, Tessari C, Padalino MA, Zanella F, et al. Minimally invasive surgery for atrial septal defects: A 20-year experience at a single centre. *Interactive Cardiovascular and Thoracic Surgery*. 2019;**28**:961-967. DOI: 10.1093/icvts/ivz017

[17] Matsumoto M, Oka Y, Strom J, Frishman W, Kadish A, Becker RM, et al. Application of transesophageal echocardiography to continuous intraoperative monitoring of left ventricular performance. *The American Journal of Cardiology*. 1980;**46**:95-105

[18] Shanewise JS, Cheung AT, Aronson S, Stewart WJ, Weiss RL, Mark JB, et al. ASE/SCA guidelines for performing a comprehensive intraoperative multiplane transesophageal echocardiography examination: Recommendations of the American Society of Echocardiography Council for intraoperative echocardiography and the Society of Cardiovascular Anesthesiologists Task Force for certification in perioperative transesophageal echocardiography. *Journal of the American Society of Echocardiography*. 1999;**12**:884-900

[19] Stokes JW. Transoesophageal echocardiography in routine cardiac surgery. *The Medical Journal of Australia*. 2005;**182**:93-94

[20] Ayres NA, Miller-Hance W, Fyfe DA, Stevenson JG, Sahn DJ, Young LT, et al. Indications and guidelines for performance of transesophageal echocardiography in the patient with pediatric acquired or congenital heart disease: Report from the task force of the Pediatric Council of the American Society of echocardiography.

Journal of the American Society of Echocardiography. 2005;**18**:91-98

[21] Sheil ML, Baines DB. Intraoperative transoesophageal echocardiography for paediatric cardiac surgery-an audit of 200 cases. *Anaesthesia and Intensive Care*. 1999;**27**:591-595

[22] Fanshawe M, Ellis C, Habib S, Konstadt SN, Reich DL. A retrospective analysis of the costs and benefits related to alterations in cardiac surgery from routine intraoperative transesophageal echocardiography. *Anesthésie et Analgésie*. 2002;**95**:824-827

[23] Ramamoorthy C, Lynn AM, Stevenson JG. Pro: Transesophageal echocardiography should be routinely used during pediatric open cardiac surgery. *Journal of Cardiothoracic and Vascular Anesthesia*. 1999;**13**:629-631

[24] Kamra K, Russell I, Miller-Hance WC. Role of transesophageal echocardiography in the management of pediatric patients with congenital heart disease. *Pediatric Anesthesia*. 2011;**21**:479-493

[25] Jijeh AMZ, Omran AS, Najm HK, Abu-Sulaiman RM. Role of intraoperative transesophageal echocardiography in pediatric cardiac surgery. *Journal of the Saudi Heart Association*. 2016;**28**:89-94

[26] Muhiudeen IA, Roberson DA, Silverman NH, Haas GS, Turley K, Cahalan MK. Intraoperative echocardiography for evaluation of congenital heart defects in infants and children. *Anesthesiology*. 1992;**76**:165-172

[27] Scohy TV, Matte G, van Neer PL, van der Steen AF, McGhie J, Bogers A, et al. A new transesophageal probe for newborns. *Ultrasound in Medicine & Biology*. 2009;**35**:1686-1689

[28] Scohy TV, Gommers D, Schepp MN, Gommers D, Schepp MN, McGhie J,

- et al. Image quality using a micromultiplane transesophageal echocardiographic probe in older children during cardiac surgery. *European Journal of Anaesthesiology*. 2009;**26**:445-447
- [29] Ma XJ, Huang GY, Liang XC, Chen ZG, Jia B, Li X, et al. Transoesophageal echocardiography in monitoring, guiding, and evaluating surgical repair of congenital cardiac malformations in children. *Cardiology in the Young*. 2007;**17**:301-306
- [30] Balmer C, Barron D, Wright JG, de Giovanni JV, Miller P, Dhillon R, et al. Experience with intraoperative ultrasound in paediatric cardiac surgery. *Cardiology in the Young*. 2006;**16**:455-462
- [31] Aronson LA. Trans-nasal placement of biplane transesophageal echocardiography probe intraoperatively in an adolescent with congenital heart disease. *Anesthesia and Analgesia*. 2003;**97**:1617-1619
- [32] Rice MJ, McDonald RW, Li X, Shen I, Ungerleider RM, Sahn DJ. New technology and methodologies for intraoperative, perioperative, and intraprocedural monitoring of surgical and catheter interventions for congenital heart disease. *Echocardiography*. 2002;**19**:725-734
- [33] Bruce CJ, O'Leary P, Hagler DJ, Seward JB, Cabalka AK. Miniaturized transesophageal echocardiography in newborn infants. *Journal of the American Society of Echocardiography*. 2002;**15**:791-797
- [34] Lake CL. Fast-tracking in paediatric cardiac anesthesia: An update. *Annals of Cardiac Anaesthesia*. 2002;**5**:203-206
- [35] Laussen P, Roth S. Fast tracking: Efficiently and safely moving patients through the intensive care unit. *Progress in Pediatric Cardiology*. 2003;**18**:149-158
- [36] Metin K, Celik M, Oto O. Fast-track anesthesia in cardiac surgery for noncomplex congenital cardiac anomalies. *Pediatrics and Neonatology*. 2005;**5**:2
- [37] Mittnacht AJC, Thanjan M, Srivastava S, Joashi U, Bodian C, Hossain S, et al. Extubation in the operating room after congenital heart surgery in children. *The Journal of Thoracic and Cardiovascular Surgery*. 2008;**136**:88-93
- [38] Demetrio P, Shafer K. Anesthesia for minimally invasive cardiac surgery. In: Vida V, Stellin G, editors. *Fundamentals of Congenital Minimally Invasive Cardiac Surgery*. USA: Elsevier; 2018
- [39] Vogt A, Stieger DS, Theurillat C, Curatolo M. Single-injection thoracic paravertebral block for postoperative pain treatment after thoracoscopic surgery. *British Journal of Anaesthesia*. 2005;**95**:816-821
- [40] Nagahiro I, Andou A, Aoe M, Sano Y, Date H, Shimizu N. Pulmonary function, postoperative pain, and serum cytokine level after lobectomy: A comparison of VATS and conventional procedure. *The Annals of Thoracic Surgery*. 2001;**72**:362-365
- [41] Karmakar MK. Thoracic paravertebral block. *Anesthesiology*. 2001;**95**:771-780
- [42] Jamieson BD, Mariano ER. Thoracic and lumbar paravertebral blocks for outpatient lithotripsy. *Journal of Clinical Anesthesia*. 2007;**19**:149-151
- [43] Sabanathan S, Smith PJ, Pradhan GN, Hashimi H, Eng JB, Mearns AJ. Continuous intercostal nerve block for pain relief after thoracotomy. *The Annals of Thoracic Surgery*. 1988;**46**:425-426
- [44] Myles PS, Bain C. Underutilization of paravertebral block in thoracic

surgery. *Journal of Cardiothoracic and Vascular Anesthesia*. 2006;**20**:635-638

[45] Vida VL, Padalino MA, Motta R, Stellin G. Minimally invasive surgical options in pediatric heart surgery. *Expert Review of Cardiovascular Therapy*. 2011;**9**(6):763-769. DOI: 10.1586/erc.11.69. Review

[46] Vida VL, Tiberio I, Gallo M, Guariento A, Suti E, Pittarello D, et al. Percutaneous internal jugular venous cannulation for extracorporeal circulation during minimally invasive technique in children with congenital heart disease: Operative technique and results. *Minerva Pediatrica*. 2016;**68**:341-347

[47] Vida VL, Tessari C, Putzu A, Tiberio I, Guariento A, Gallo M, et al. The peripheral cannulation technique in minimally invasive congenital cardiac surgery. *The International Journal of Artificial Organs*. 2016;**39**:300-303. DOI: 10.5301/ijao.5000505

[48] Vida VL, Padalino MA, Boccuzzo G, Stellin G. Near-infrared spectroscopy for monitoring leg perfusion during minimally invasive surgery for patients with congenital heart defects. *The Journal of Thoracic and Cardiovascular Surgery*. 2012;**143**:756-757

[49] Speggorin S, Padalino MA, Vida VL, Bonato R, Stellin G. Cardiac herniation. After minimally invasive cardiac surgery: An unusual potentially lethal complication. *Circulation*. 2009;**120**: 2509-2510

[50] Leon-Wyss J, Vida VL, Veras O, Vides I, Gaitan G, O'Connell M, et al. Modified extrapleural ligation of patent ductus arteriosus: A convenient surgical approach in a developing country. *The Annals of Thoracic Surgery*. 2005;**79**:632-635

[51] Vida VL, Rubino M, Bottio T, Padalino MA, Milanese O, Pittarello D,

et al. Thoracoscopic closure of the patent arterial duct. *Cardiology in the Young*. 2004;**14**:164-167

[52] Vida VL, Padalino MA, Boccuzzo G, Veshti AA, Speggorin S, Falasco G, et al. Minimally invasive operation for congenital heart disease: A sex-differentiated approach. *The Journal of Thoracic and Cardiovascular Surgery*. 2009;**138**:933-936