

---

# Epiduroscopy (Epidural Endoscopy)

---

Havva Sayhan and Serbulent Gokhan Beyaz

Additional information is available at the end of the chapter

<http://dx.doi.org/10.5772/62918>

---

## Abstract

Epiduroscopy is a relatively new technique used in the evaluation and treatment of low back pain via advancements in optical fiber technology. As a minimally invasive endoscopic technique, it allows for direct endoscopic imaging of the epidural space and helps the patients for the pain management who having post-lumbar surgery syndrome (PLSS) and other cases of low back pain and radiculopathy. An advanced understanding of the anatomy of epidural space and adjacent structures are also essential for positive and successful clinical outcomes. The use of epiduroscopy in the pain clinic is performed as a day procedure, and the patient is awake and can communicate with the doctor. During an epiduroscopy, thin tubes with a bright light and tiny fiberoptic camera at the end are inserted through the sacral hiatus into the epidural space around the dura and guided up toward the affected site. Anterior epiduroscopy and epiduroscopic laser neural decompression (ELND) have been recently introduced in treating herniated disc decompressions, and chronic low back pain and radicular pain, respectively. The most common complications of epiduroscopic approach are the pain in the intervention point, dural puncture, and headache.

**Keywords:** epiduroscopy, anterior epiduroscopy, epiduroscopic laser discectomy, post-lumbar surgery syndrome (PLSS), low back pain, chronic pain, epidural space

---

## 1. Introduction

Epiduroscopy, also known as spinal endoscopy, which is directly visualize the epidural space with a percutaneously minimal invasive inserted fiberoptic scope. Epiduroscopy is a relatively new diagnostic and therapeutic technique developed in the [1] performed to treat the low back pain, specifically radicular pain in which the epidural space is directly visualized on a video monitor. The development of epiduroscopy is connected to the integration of fiberoptic technology with computer-enhanced imaging for viewing the central nervous system that

---

is miniaturized enough to be inserted into the epidural space. The fiber-optic visualization would be easy and safe to apply in medical practice and has made a major contribution to advances in pain medicine. In this way, the epidural space can be identified for the cause of pain and other neurological signs by distinguishing the anatomic structures and pathological structures.

Epiduroscopy involves looking inside the epidural space that contains nerves who are pain generators inside of the spinal column that connect the spinal cord to the rest of the body. An epiduroscopy involves insertion of a tiny fiber-optic camera attached to a catheter into the epidural space through a small incision in the sacral hiatus near the tail bone. The areas of concern can then be visualized by guided up towards the affected nerve roots. Afterward, the adhesions can be cut away and local anesthetic and steroid solutions can be injected.

The increased attention has been paid to epiduroscopy to deliver accurate diagnosis and treatment for chronic pain. Recently, as a result of these efforts, epiduroscopically assisted laser therapy has been reported for multiple lesions such as discectomy [2]. Epiduroscopy is expected to provide successful outcomes in the diagnosis and treatment of intractable low back and leg pain where even epidural steroid injection is not efficacious for pain relief and pain recurs after operation.

## 2. History of epiduroscopy

Epiduroscopy was considered a method to study the spinal anatomy, and then improvements allowed its employment as therapeutic approach in the diagnosis and treatment of pain. Clinicians have been working with various types of endoscopes for over 80 years, with varying degrees of success.

In the 1930s, Burman started the first study on epiduroscopy and reported direct visualization of the spinal canal with arthroscopic equipment to examine the anatomy of the vertebral column that were removed intact from human cadavers [3].

The first use of the instrument on patients did by Stern in 1936 for the direct observation of the posterior roots for rhizotomies and for the treatment of spastic conditions.

Later, Pool developed this system which did not have any recording and imaging system and applied the technique clinically on over 400 patients. He could diagnose conditions such as neuritis, herniated disc, neoplasms, adhesions, and venous congestion [4].

Afterward, researchers focused on visualizing the spinal canal, however, there was no further remarkable progress on endoscopy in the literature until the late 1950s.

The key breakthrough for clinical application of this technology is the development of the first flexible endoscope in 1958 by Hirschowitz et al. [5] that gave rise to enormous advances in diagnostics and therapy.

In the late 1960s and early 1970s, the Japanese researcher Ooi and Morisaki [6] developed an instrument for intradural and extradural examinations that combined a flexible light source with rigid optics. The fiber-optic light source technology protected the tissues from heat injury, since the fibers absorb infrared rays and reflect visible rays.

In 1991, Saberski and Kitahata [7] considered clinical use of these devices for the placement into the epidural space as a diagnostic tool where the caudal approach to the epidural space offer advantage over the paramedian lumbar approach. The authors reported that the caudal approach facilitated correct catheter positioning for administration of epidural steroid for the treatment of radiculopathy.

In 1993, Leu et al. [8] used endoscopies for therapeutic intervention in addition to diagnostics, and performed peridural and intraductal endoscopies in patients.

Schutze et al. [9] conducted the first video-optic examinations of the lumbar epidural space in chronic patients with a flexible catheter-secured epiduroscopic unit.

Epiduroscopy received approval through the United States Food and Drug Administration (FDA) in 1996 for visualization of the epidural space.

Recently, minimal invasive and microsurgical techniques such as epiduroscopic laser discectomy have been introduced and used for chronic low back pain and post-lumbar surgery syndrome (PLSS) which was called before as false back surgery syndrome (FBSS). Considering the ongoing development trends in the area of microsystems technology, epidural endoscopy has an increasing significance of invasive intervention in pain medicine.

### **3. Indications and contraindications**

The pain physician's major responsibilities involve treating unexplained pain symptoms and effective pain management. It can be difficult to classify and treat chronic spinal pain syndromes.

Therefore, the conformity between clinical examination, imaging results, diagnostic blocks, and epiduroscopy is the backbone to ascertain the cause of pain and to establish a diagnosis in clinical decision.

Epiduroscopy has the advantage of visually identified structures in the epidural space such as hyperemia, changes in vascularity, fibrosis and adhesions, lateral recess stenosis, disk herniation, and ligamentum flavum hypertrophy. Relative clinical indications for epiduroscopy consist in diagnostic and therapeutic of pain syndromes.

The main indication for epiduroscopy used to be for diagnosis of the sources of pain. Recently, therapeutic is the main indication of the epiduroscopy due to the ability to the treatment of these sites with accuracy. Diagnostically, use of the procedure provides a better view of pathological and anatomical structures and circumstances. Obviously, success of treatment depends on the underlying pathology. Therefore, success or failure of treatment can be used as a measure of the validity of diagnostic parameters obtained through epiduroscopy [10, 12, 13].

As a therapeutic technique, epiduroscopy includes procedures such as direct application of pharmacologic therapy, lysis of scar tissue, adhesions, catheter placement, implantation of

stimulation electrodes under direct vision (radio frequency therapy, spinal cord stimulation) and discectomy. Additionally, conscious sedation in patients is administered in order to provide response to stimulated pain-generating areas. Further, epiduroscopy has the potential not only to reduce the incidence of surgery but also to the treatment of post-lumbar surgery syndrome.

Radiculopathy associated with any of the following signs or symptoms is also an indication for epiduroscopy: failed response to epidural steroid injections, filling defects caused by adhesions, post-laminectomy failed back syndrome, and failed conservative back therapy.

The following indications were defined by the consensus committee of the foundation of World Initiative on Spinal Endoscopy (WISE) in 2006 [11]:

To improve diagnosis:

- Diagnosis of clinically relevant epidural pathology, if pain can be attributed to epidural space (spinal canal) structures based on current history, physical examination and supportive present-day laboratory investigations
- Biopsy for histopathological and/or histochemical analysis
- Provocative stimulatory tests (e.g., electrical, light, mechanical)

To provide treatment:

- Irrigation
- Direct application of therapeutic agent
- Direct lysis of adhesions/scar tissue with physical or chemical agents (e.g., mechanical, pharmacological, laser, radio frequency)

As a supportive tool:

- Placing catheter systems (epidural, spinal)
- Implanting stimulation electrodes (spinal cord stimulation)
- As an adjunct in minimally invasive surgery
- Retrieval of foreign bodies
- (Potentially) for post-operative assessment

Contraindications for epiduroscopy

There is a need for confidence in diagnostic to consider contraindications for epiduroscopy, and in particular of the need to differentiate between low back pain of non-spinal origin, such as cognitive affective disorder, and low back pain of psychological origin, for example, compensation psychosis.

The contraindications for epiduroscopy correspond to those for epidural regional anesthesia techniques. The contraindications for regional anesthesia can be listed as skin infections in the

area of a cut, hemorrhagic diathesis, anticoagulant therapy, exacerbation of intercurrent illness, flu-like conditions, high cardio-vascular risks, etc.

The contraindications were defined by the consensus committee of the foundation of World Initiative on Spinal Endoscopy (WISE) in 2006 as absolute and relative [11].

The absolute contraindications are stated as follows: psychiatric diseases that potentially interfere with informed consent and/or perception of pain, retinal disease, increased risk for or the presence of elevated intracranial pressure, manifest bowel and bladder, dysfunction and sensory disturbances in S2-S4 area, cerebrovascular disease, advanced systemic diseases, septic or dystrophic skin lesions in the sacral areas (anal fistule, sacral osteomyelitis, etc.), meningeal cysts, meningocele, meningomyelocele, severe respiratory insufficiency (COPD), known allergy for drugs used in the procedure, instable angina, malignancy.

Relative contraindications are as follows: psychiatric diseases that potentially interfere with informed consent and/or perception of pain, inability to lie in a prone position for more than 60 min, severe respiratory insufficiency (COPD), drug or alcohol abuse, etc. [12, 11, 13, 10]

#### **4. Anatomy of epidural space**

The main application of epiduroscopy is in relation to the management and treatment of chronic radicular pain. The detailed anatomy of the epidural space and its surrounding bony and ligamentous structures is of great importance for clinicians who perform epiduroscopy. A clear understanding of the relevant anatomy and contents of the space is essential to perform epiduroscopy safely. Epiduroscopic screening with high video-optic quality is enabling displaying of the corresponding morphological structures and visual understanding of this region.

The epidural space is formed between the dural sheath and the spinal canal that extends from the foramen magnum of the skull to the sacral hiatus in combination with the sacrococcygeal ligament. It is bounded superiorly by the fusion of the spinal and periosteal layers of the dura mater at the foramen magnum, and inferiorly by the sacrococcygeal membrane. The epidural space contains the dural sac, the anterior and posterior spinal nerve roots, the extradural venous plexus, spinal arteries, lymphatics, filum terminale and fatty tissue. The anterior and posterior spinal nerve roots are within the dural sac. The dural sac generally ends at the level of the S2 vertebral body and its continuation known as the filum terminale [14].

Anterior or posterior approach to the lumbar epidural space must be used in epiduroscopy. Although posterior epiduroscopy can theoretically be performed at any level of the spinal column and through the sacral hiatus, the anterior epiduroscopy must be via caudal approach. Anterior epiduroscopy is the most recent longitudinal approach to the entire lumbar epidural space and provides a significant improvement in the treatment of low-back and leg pain [15].

The sacrum is a wedge-shaped triangular bone at the base of the spinal column that forms from the naturally fused five sacral vertebrae. The sacrum is held in place between the two iliac bones, articulating superiorly with the fifth lumbar vertebra and caudad with the coccyx.

The lamina of the lowest segment of the sacrum is incomplete; therefore, there is a gap which is called the sacral hiatus in the anatomical structure. There are two bony projections that are called the sacral cornua, and the sacrococcygeal ligament which covers this U-shaped space posteriorly. Both of these structures are represent important clinical landmarks when needles are placed into the caudal canal. Penetration of the sacrococcygeal ligament provides direct access to the epidural space of the sacral canal. A superiorly continuation of the sacral canal is the lumbar spinal canal.

Since the spinal cord ends near the level of the second lumbar vertebra, this canal does not carry the spinal cord but contains the epidural venous plexus and is filled with fat, which is subject to an age-related increase in density [16]. Most of these vessels are intensified in the anterior portion of the canal. The advancement of needles or catheters cephalad into the sacral canal can lead to trauma of both the dural sac and epidural vessels.

The epidural space contains prominent amount of epidural fat that distributes along the canal in a predictable pattern allows injected fluid to diffuse through the epidural space and have impact on nerve roots by the absorption of drugs. The fat in the epidural space is soft which surrounds dura mater and protects the neural structures, and facilitates the movement of the dural sac [21].

The spinal dura mater is a strong connective tissue membrane surrounding the cerebral spinal fluid, the spinal cord, the anterior and posterior nerve roots, and spinal ganglia. It extends from the foramen magnum to the sacrum. The dura is being separated by the epidural space so is not attached to the vertebrae. Microscopic view of the dura mater consists of white fibrous and elastic tissues arranged in longitudinal bands or flattened lamellae. Characteristics of dura mater seen on epiduroscopic images are convex, tubular, and grey-white with blood vessels on the surface, giving the appearance of a road map. In epiduroscopy, a fiber-optic endoscope inserted into the sacral hiatus advanced upward into the epidural space. When the epiduroscope advanced in the sacral canal the exact position of dural sac must be ensured via image guidance to prevent dural sac injury because the dural sac terminates at S2 level.

The epidural space contains arteries and veins supplying the spinal cord. The epidural arteries are relatively small and pass through the intervertebral foramina to supply adjacent vertebrae and ligaments. The arteries are located in the lateral epidural space hence not threatened by an advancing needle or epiduroscope. Inside, the spinal canal there is a network of large and valveless veins running along the entire length of the vertebral column. The epidural veins predominantly lie in the anterior epidural space and interconnected one to another to form a venous plexus and ultimately drain into the azygous system of veins. The vertebral plexuses with the veins of bones of the vertebral column form Batson's plexus. The intervertebral veins are responsible for the communication between the vertebral venous plexuses which run through the intervertebral foramina. In the lumbosacral part of the vertebral column, the ventral venous plexus is generally larger than the dorsal plexus. The vertebral venous plexus is subject to distension in case of increased intrathoracic or intra-abdominal pressure because of ascites, pregnancy, large tumors. Thus the venous plexus is thought to be involved in a trauma during epiduroscope placement in the epidural space and increases the risk. [17, 18, 19].

The arteries appear on epiduroscopic images as a thin red thread with pale opaque insulation while veins cannot be detectable, and pulsatile flow can be seen [20].

The epidural space communicates with the paravertebral spaces via the intervertebral foramina where major site of action for an epidural located to nerve roots. The nerve supply of the epidural space is via branch from the sinu-vertebral nerves that originate from the rami communicantes. The nerve roots lie in the posterolateral part of the epidural space where they enter and exit the vertebral column at each level in a specific pattern. Nerve roots seen on epiduroscopic images as grey-white tube shape with a vessel running longitudinally down the centre [20, 18].

The lymphatics of the epidural space are present in the region of the dural nerve roots whereas they are absent in the nerve root itself and remove foreign materials from the subarachnoid and epidural spaces [21].

## 5. Pathological findings of epiduroscopy

Epiduroscopy is the most recent, complete, and effective technique to approach the spine through minimal invasive access means for treating persistent low-back pain.

Spinal pain and radicular pain syndromes are both characterized by pathological and anatomical changes in the epidural space and diagnosed via epiduroscopy such as arachnoiditis, fibrosis, stenosis, nerve root compression.

The epidural space lies between the dura mater and the walls of the vertebral canal, containing fat and small blood vessels. The space is located just outside the dural sac which surrounds the spinal nerve roots and is filled with cerebrospinal fluid.

Epiduroscopic view under traditional white-light endoscopy can give us a better understanding of the pathology. Dura mater appears as either a blue-gray or gray-white exterior with small blood vessels on its surface, epidural fat appears usually yellowish in color, globular, and glistening with small blood vessel on or in it, nerve roots are white tinged with yellow tube shape with a vessel running longitudinally down the center, ligamentum flavum seen as a white and concave tube without vessels.

### 5.1. Fibrosis

The formation of scar tissue near the nerve root spontaneously or after spine surgery thought to be the potential cause of the pain or radicular symptoms. If it binds the lumbar nerve root with fibrous adhesions that also called epidural fibrosis. Epidural fibrosis also may restrict the flow of medication to the nerve roots and limiting the effectiveness of epidural injections since mechanical deformation of spinal nerve roots and dorsal root ganglions. If the patient suffers from continued or recurrent pain directly after spine surgery epiduroscopic diagnostic imaging technique can often pinpoint the responsible pathology of pain. It was shown that possibility of experience to recurrent radicular pain with an extensive epidural scar is more

than less extensive one, and the correlation is statistically significant [22]. None the less a correlation between the degree of epidural fibrosis and the intensity of post-surgical pain was also reported [23, 24]. Epidural fibrosis is diagnosed not only in patients who have had low back surgery but also who have anatomical abnormalities such as stenosis, instabilities and herniated discs without surgery. There are many patients who having pathology with no pain therefore establishing a cause and effect relationship between pathology and pain is low [25]. In the endoscopic image, epidural fibroses appear clear white and are generally avascular.

## 5.2. Adhesions

Epidural adhesions most commonly occurs as a complication of spinal surgery that are related to inflammatory reactions and result in the entrapment of nerves within dense scar tissue. Beside this can also develop following disc herniation or infection without prior surgery taking place. Morphological changes in the supporting structures of the spine have been identified primarily in the form of epidural adhesions. They limit the pain-free movement and function of structures in the intervertebral foramen and the bony vertebral canal, and prevent direct application of medications to the affected disc and nerve root. Epidural adhesions may or may not involve in the generation of pain therefore should be considered carefully [26, 53]. Adhesions or adhesive areas are easily visible fibrous bands of tissue with epiduroscopy that appear clear to white and often bizarre. Epiduroscopy is used to break down adhesions by infusion of a small amount of saline through the catheter with careful and gentle movement of the catheter.

## 5.3. Chronic inflammatory processes

The visual function of epiduroscopy can be used to identify chronic inflammatory processes in the epidural space such as epiduritis and radiculitis. Chronic inflammatory condition increases levels of inflammatory mediators at the affected site and results increased pain.

## 5.4. Radiculitis

Radiculitis is pain that originates from direct pressure on the nerve roots because of inflammation or other irritation of a nerve root at its connection to the spinal column. Disc herniation, osteophytes, thickening of surrounding ligaments, spinal stenosis, damaged intervertebral discs, degeneration of the spine, spondylolisthesis, or scoliosis could be one of the many causes of radiculitis.

Radiculitis symptoms start with radiating pain along the nerve path and usually accompanied with sensations of numbness, tingling, pins, and needles. The other incorporating symptoms of muscle weakness and loss of reflexes also present as the condition progresses. A variety of symptoms of radiculitis can be felt anywhere in the body depending on the location of the affected disc, and nerve root because each area of the body is controlled by nerves exit the spinal column in pairs. For example, cervical nerve root can cause pain and other symptoms through the arms, hands, and fingers, lumbar nerve root can radiate through the leg and into the foot and prompting leg pain and foot pain.



### **5.5. Epiduritis**

Epiduritis is an acute or chronic inflammatory process of epidural structures in the epidural space and on the outer surface of the dura mater of the spinal cord. Epiduroscopically it is characterized with cardinal symptoms such as swelling, redness, and a positive pain provocation test.

### **5.6. Arachnoiditis**

The arachnoid mater is the middle one of the three protective membranes of the central nervous system that surrounds the brain and spinal cord. Inflammation of the arachnoid is called arachnoiditis that subdural processes take place on the caudal fibers and the nerve root sheaths, and characterized by severe burning pain, stinging, numbness, and neurological problems. In the case of arachnoiditis and perineural nerve sheath fibrosis, the spinal dura mater appears thickened and the tissue appeared to have increased vascularization. Arachnoiditis is a complex neuropathic pain disorder with a complex etiology that affects the nerves connecting to the lower back and legs. Adhesive arachnoiditis is most commonly present with associated epidural fibrosis whereas epidural fibrosis can occur alone. Arachnoiditis is most frequently seen in patients who have undergone multiple surgical procedures.

### **5.7. Xanthosis**

Xanthosis is a yellowish degeneration with yellowish pigmentation which could be observed in the spinal epidural space in the literature by Heavner et al. [27]. This epiduroscopy finding in the peridural tissue adjacent to blood vessels at the left L5-S1 intervertebral foramen associated with radiculopathy. They administered treatment with the same equipment and gained satisfactory reduction in the radicular pain with the treatment outcome. Thus, called as a novo epiduroscopy finding.

### **5.8. Ligamentum flavum hypertrophy**

Hypertrophy of the ligamentum flavum is a pathologic condition due to fibrosis and scar tissue formation that contribute to cord compression radiculopathy. Hypertrophy of the ligamentum flavum can be rarely encountered in the lumbar region however more common in cervical and thoracic regions. Hypertrophy of the ligamentum flavum is usually involved in the pathogenesis of spinal stenosis which can cause loss of disc height, reduce the diameter of the spinal canal and compress the dural sac and nerve roots. A multilevel detailed examination of the epidural space is now possible with epiduroscopy and directly observation of hypertrophied ligamentum flavum can be satisfactorily achieved [28, 29].

### **5.9. Cysts in the spinal canal**

The patients may suffer from recurrent pain and/or troublesome new symptoms such as failed back surgery syndrome after surgical treatment. Some cyst types may also be present in the different levels of the spinal canal such as synovial cyst of a lumbar facet joint, often cause spinal compression and radicular pain. Even if these cysts can be visualized in epiduroscopic

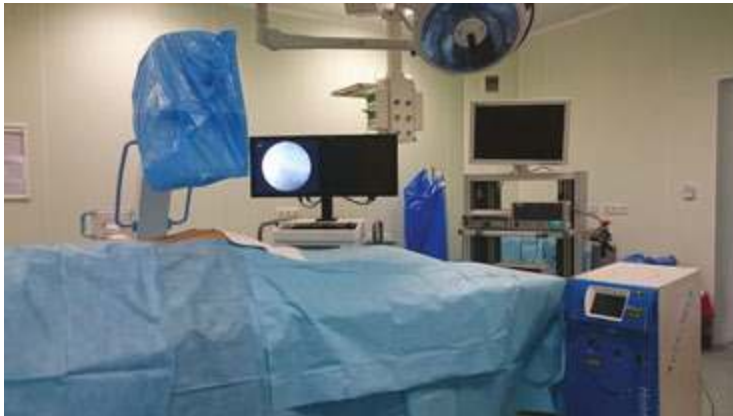imaging, due to the packed up anatomy and the inflamed cyst being not easily identified from adjacent structures confirmation of the diagnosis with fluoroscopy, MRI or CT may be necessary to assess the contents of spinal canal [30]. Minimally invasive technique such as cyst rupture by epiduroscopy has the potential for fenestration of cyst either post-operative or not.

Jin et al. successfully removed a lumbar facet joint cyst at L4/5 level by epiduroscopy. Epiduroscopy usage as a support to diagnose and therapy of the cyst that results compression on the radicular nerve would be favorably an alternative technique over conventional surgery in the future [31].

## 6. Technique of epiduroscopy

Before the epiduroscopy process, the patient's history should be reviewed as expeditiously as possible and a comprehensive physical exam should be carried out. Detailed preoperative knowledge of the patient's neurological assessment is necessary to recognize the post-operative neurological complications. The specialized nerve tests such as EMG, NCV and SSEP to investigate the functioning of the nervous system, and imaging studies like CT scans or MRI scans should be completed in the preoperative setting. The skeletal structures of the sacrum, the level of termination and position of the bottom of the dural sac particularly on T2-weighted MRI, the evaluation of the anterior and posterior epidural spaces should be performed previously.

Epidural bleeding during epiduroscopy constitute extremely rare, however, taking conventional precautions to prevent is substantial. NSAIDs use should be stopped 24 h before and aspirin should be stopped 3–4 days before procedure in the perioperative period. It is also generally recommended to stop any oral anticoagulant before open surgery. In addition to complete blood count (CBC) that also called hemogram, an evaluation of basic coagulation



**Figure 1.** Optimum design of the operating room at which the epiduroscopy takes place.

parameters should be ordered for prothrombin time (PT) with a partial thromboplastin time (PTT), and the international normalized ratio (INR) calculation based on results of PT to monitor individuals in the perioperative period. The operating room is equipped with a fluoroscopy table, C-armed scopy device, holmium laser, light source, and imaging device (Figures 1–3).

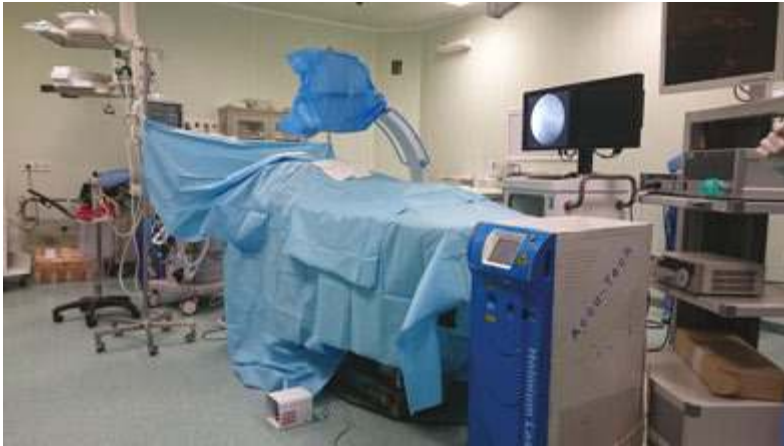

Figure 2. Anesthesia device in front of the operating table.

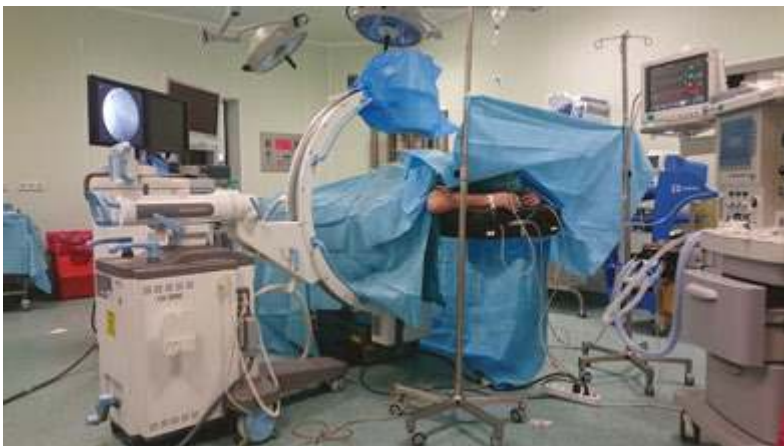
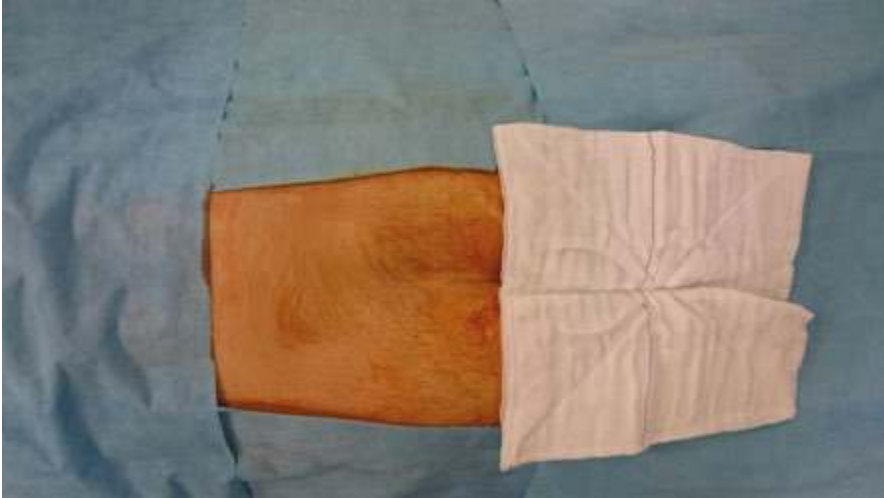
Figure 3. C-armed scope and video monitoring system to the right of operating table, Holmium laser device and tradle close to applicator.

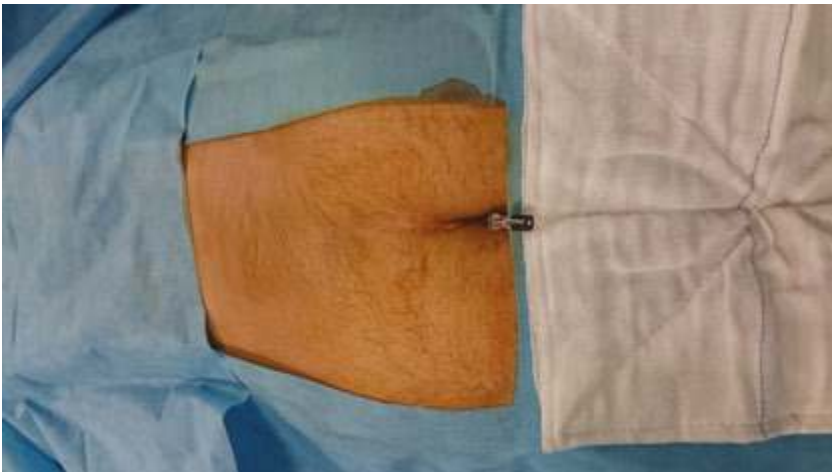
Perioperative antibiotic prophylaxis therapy in general administration of ceftriaxone 1 g intravenously should be given within 1 h before epiduroscopy. The patient is admitted to the

operation room and placed in the prone position on the fluoroscopy table with a pillow under the abdomen to correct the lumbar lordosis.

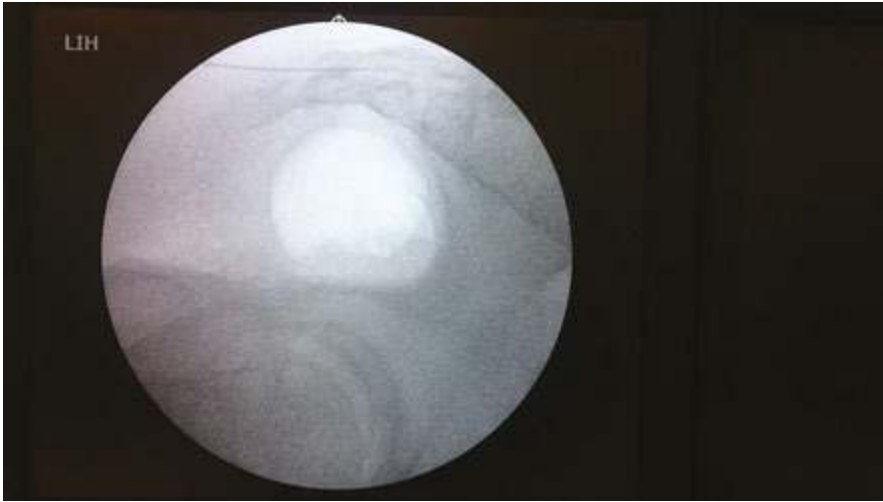


**Figure 4.** After setting aseptic conditions, sterile dressing gets covered over procedure area.

The practice of aseptic technique is maintained and patient and fluoroscopy are covered the sterile dressing (**Figure 4**). Intravenous 2 mg midazolam and 50 mcg fentanyl is administered for performing the procedure under conscious sedation.

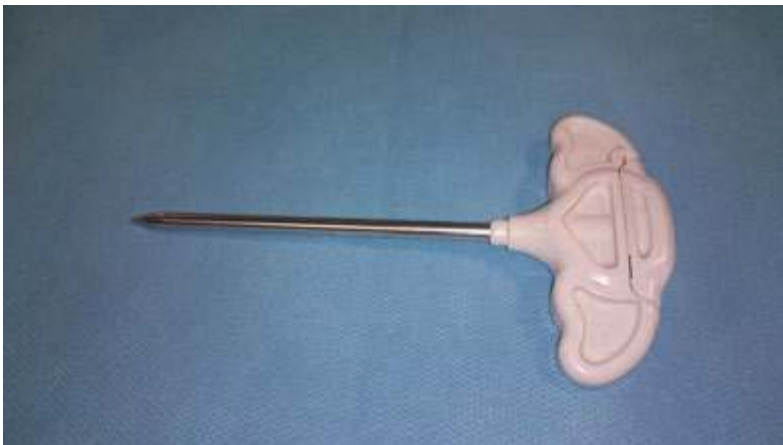

**Figure 5.** Insertion of 22G spinal needle passing through sacral hiatus.



**Figure 6.** Fluoroscopy image of 22G spinal needle after passing through sacral hiatus.

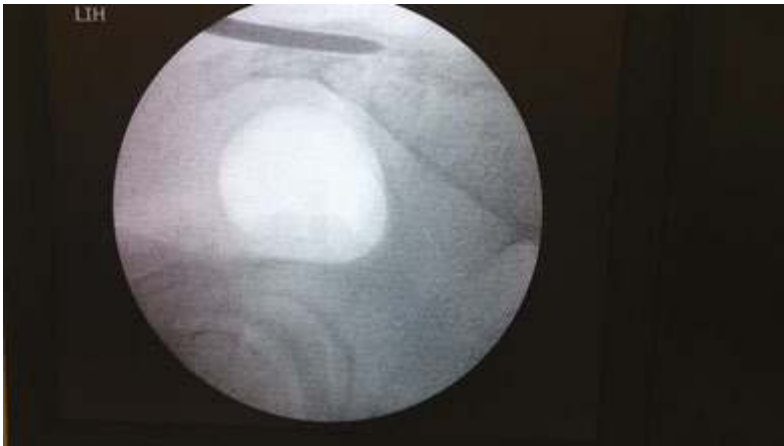
Under C-arm (fluoroscope) lateral image guidance, intradermal, and subdermal infiltration of local anesthetic is injected by a 22G spinal needle, then 8–10 mL 1% lidocaine injection is administered to epidural space by passing through the sacral hiatus (**Figures 5 and 6**). This will greatly reduce the abnormal pain and pressure feeling of patient during advancing the trocar through the narrow caudal canal, will prevent in vivo motion in patient and there will be no need to increase the sedation of prone-positioned patient so that facilitates ease of application for clinician.



**Figure 7.** 4.2 mm outer diameter and 3.5 mm inner diameter ranged trocar.



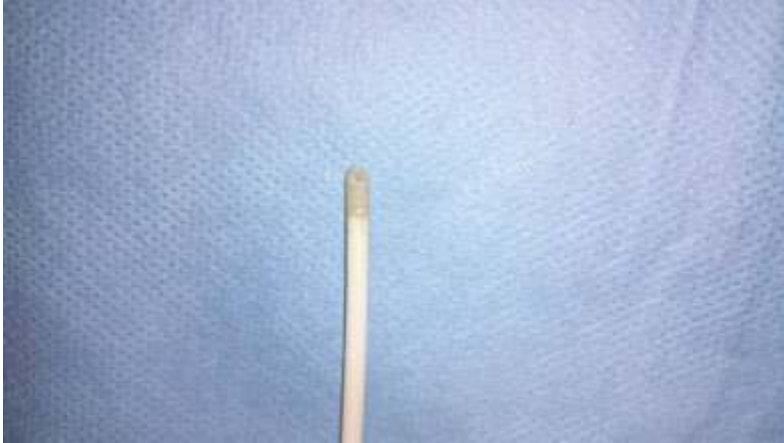**Figure 8.** Image of trocar after its stilette is removed.



**Figure 9.** The lateral fluoroscopic image of trocar in the caudal epidural space after passing through sacral hiatus.

Lateral intradermal and subdermal incision of 0.5 cm is made in the skin with No. 11 sharp disposable scalpel where 22G spinal needle introduced. If you notice some bleeding from the incision simply apply firm pressure to the area with surgical gauze. The trocar is, outer diameter 4.2 mm and inner diameter 3.5 mm, and then advanced through sacral hiatus at the skin incision point with C-armed scopy guidance (**Figures 7–9**). There is a slight loss of resistance as the trocar enters the caudal canal. Repeat antero-posterior (AP) images will be taken during the trocar advancement and will assure that the trocar direction does not stray from midline. AP image confirmation of proper placement of the trocar in the mid-line of sacral foramina will verify its position within the same line of pubic symphysis. The C-armed scopy

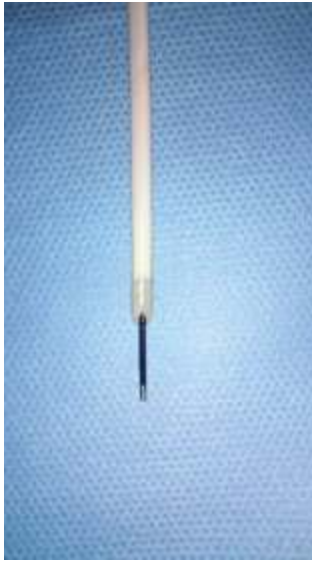is rotated in a lateral direction once trocar is held on the posterior to dural sac, where termination and position of the bottom of the dural sac was determined previously on MRI, and the central stylet of the trocar is pulled out.



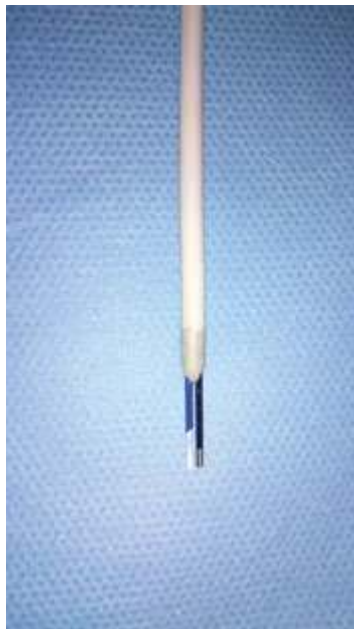**Figure 10.** Image of epiduroscope catheter tip.

Spinaut-V® epiduroscopy catheter is 33 cm in length and outer diameter 3.2 mm in width. The catheter has two working channels in 1.2 mm diameter where one is maintained on the top and the other is at the bottom of device. (**Figure 10**). The top canal is for using a high resolution fiber optic camera, and the bottom canal is for using a laser probe or biopsy forceps that can ablate a herniated disc or epidural scar tissue (**Figures 11** and **12**). The device has an ergonomic design for handling the epiduroscope. There is a controller gear on both sides of catheter to steer the catheter in 2-way directions (right or left). There is a dual port on the back of controller gear look like a dual exhaust. (**Figure 13**). On the left input, the canal allows insertion of camera and physiological saline solution administration at the same time to give a clear view of the inside of the epidural space during the procedure (**Figure 14**). Extension tubing for extension line is connected to the left input and attached to physiological saline bag 150 mL via a 3-way stop-cock. A 20-mL injector is also connected to the 3-way stop-cock. Physiological saline solution is injected either by exerting a light pressure on the injector or slow infusion. In the right input; there is a tube outlet that allows suction of blood or other given solutions. Non-ionic radio-opaque material is preferred to be administered through the right canal because it is highly dense and can stick to camera that results blurred image. This happens more frequently when it is administered through left canal. Additionally; injecting physiological saline along with radio-opaque material will pull away the material away from the camera. The best way of avoiding the blurred image and obtaining good visualization of the epidural space is passing camera through the epiduroscope after application of the initial epidurography.





**Figure 11.** Camera and laser probe from superior and lateral taken from epiduroscope catheter tip.

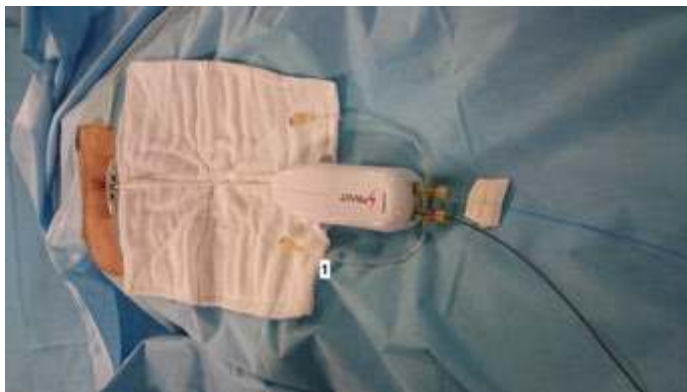

**Figure 12.** Laser probe and camera are superposed in the upper shooting.





**Figure 13.** Fiberoptic camera advances from the left input (1), laser probe advances from the right input (2).

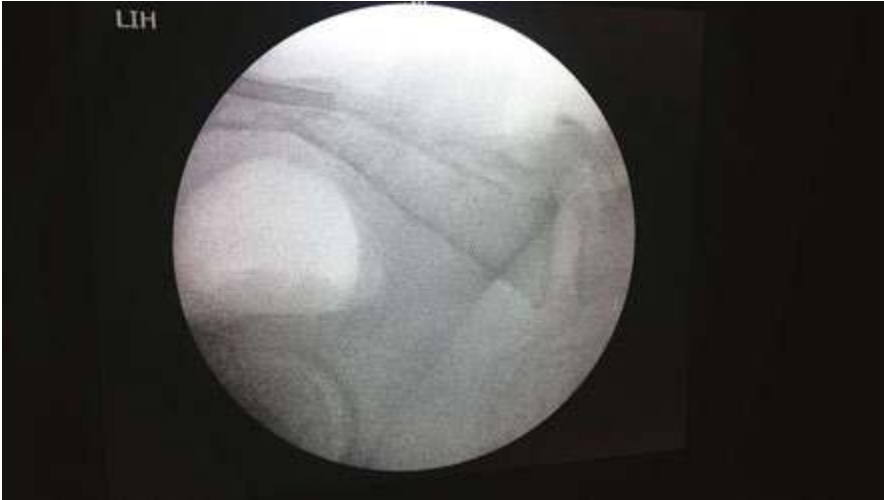

**Figure 14.** Physiologic saline line (1).

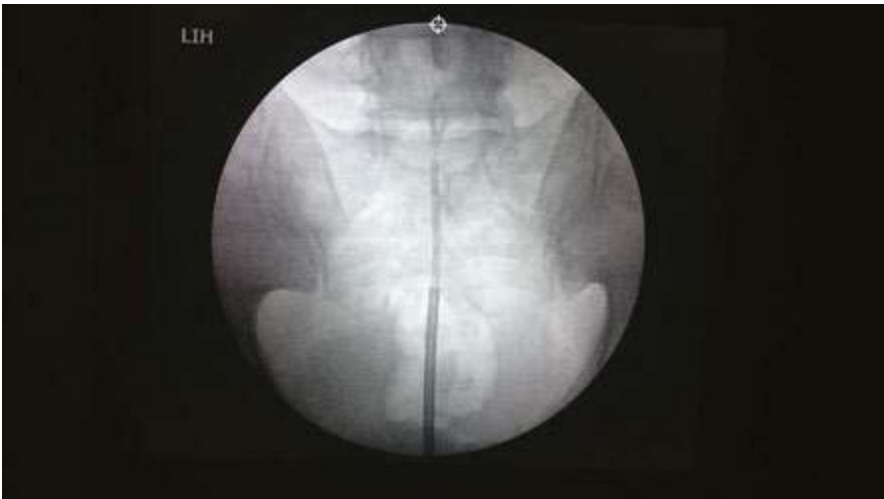In the case of access to posterior epidural space, epiduroscopy is passed through the trocar and advanced to S1 vertebra level with guidance of C-armed scopy. After the epiduroscopy is placed, 10 mL of radio-opaque material is injected for epidurography. The monitoring of epidural space is started after re-evaluating the clinical condition of patient, MRI, and epidurography results.

The epiduroscope is rotated 90° laterally to gain access into the anterior epidural space and advanced through trocar under the guidance of C-armed scopy lateral imaging. While attempting to introduce epiduroscopy into the anterior epidural space rotating the scope too much may lead folding of the catheter tip, an abrupt turn of epiduroscope to the left or right

that cause sensation of pain may lead patient movement and induce loss of the position of the patient. Following the access into the anterior epidural space, epiduroscope is returned to original neutral position.

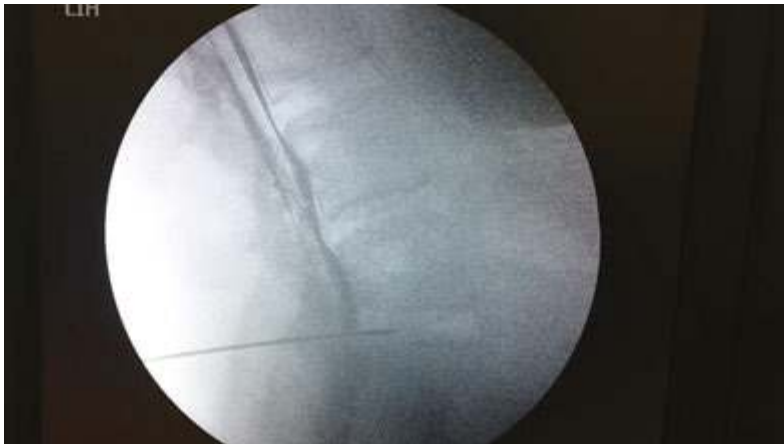

**Figure 15.** The lateral fluroscopic image of epiduroscope tip at S1 level.

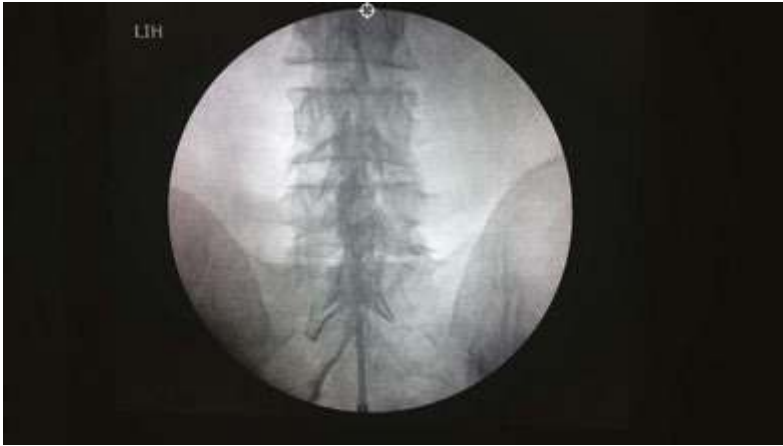

**Figure 16.** The AP fluroscopic image of epiduroscope tip at S1 level.

Once epiduroscope inserted into the anterior epidural space, the tip of the epiduroscope is introduced to the level of S1 (**Figures 15 and 16**). Initial epidurography is done at the same time to detect disc herniation or obstruction level, and compared to MRI and clinical findings. The bulging at targeted disc level is easily seen due to obstruction to the flow of the injected radio-opaque material towards to cephal. By use of the AP fluoroscopy position, the end-plates of targeted levels are straightened. The fiberoptic camera with light is connected to epiduroscope under sterile conditions and advanced through the left input until the epiduroscopic end point. The camera that the light source system controlled and white balanced prior to procedure to assure accurate tissue color is turned on. Injection of physiological saline through the catheter placed into the epidural space would keep distend the epidural space and keep clear the camera for a good view. The piston of physiological saline containing injector is slightly pushed (0.15–0.20 mL/s). The amount of given hydration must be tightly monitored. The fiberoptic camera shouldnot get pass the end point of epiduroscope because the vision from the camera is designed to fit the opening of epiduroscope to point upwards. This way we obtain a crescent shaped edge beneath the monitorized view and use this as a kind of compass. Keeping the crescent edge at the bottom part of the image allows us proper orientation in the anterior epidural canal. While in the anterior epidural canal, as we get the crescent at the bottom the dura will be appear at the upper side of the image on the screen. As we are able to monitor both dura and lumbar disk at the same time, laser probe that is introduced into respective input canal does not harm the dura and placed in the targeted disk.



**Figure 17.** The lateral fluoroscopic image of upward passing of radio-opac material through anterior and posterior openings.



**Figure 18.** The final AP epidurography.

Before the termination of procedure, a final epidurography is performed to assess the efficiency of epiduroscopy (**Figures 17 and 18**). If the patient did not diagnosed with diabetes mellitus and the dura was not perforated, 80 mg of methyl prednisolone and 10–15 mg of bupivacaine in 5 mL total volume would be injected and the trocar along with the epiduroscopy catheter is removed.

When the procedure is over, a single suture for skin closure is applied and wound dressing is completed. The patient is admitted to post-op care unit and evaluated. If no abnormality is observed the patient is discharged to the ward. The patient is immobilized for 3–4 h. Especially in patients with disc herniation is advised to use steel corset while mobilizing. The pain in the intervention point and headache are the most common complications of an epidural procedure. To manage this, intravenous hydration treatment and intravenous 1 gr of paracetamol are sufficient. If there is no problem in their general clinic condition, patients can be discharged at same day or can be admitted to the ward for one night then discharged the day after the procedure with antibiotics and NSAIDs prescription. Because of the administration of steroids to epidural region, 7–10 days of salt-free diet is reasonable. Perineal care is advised cleaning of the perineum from dorsal to front without contacting the intervention point after defecation/urination is advised. Patients are permitted to take their first shower 1–2 days after the epiduroscopy

## 7. Therapeutic anterior epiduroscopy

Epiduroscopy has been introduced as a new technique for treatment of chronic low back pain (LBP) syndromes or herniated disks. The clinical effectiveness and cost-effectiveness of

epiduroscopy have been described in multiple prospective and retrospective studies although the underlying mechanisms have not been fully investigated.

The procedures used for determination of the pathology in chronic low back pain often have difficulty in making an accurate diagnosis. However, epidural endoscope allows visualization of the epidural space to potentially identify the reason of LBP, therefore, to address these problems attention has been drawn to epiduroscopy as a tool for an accurate diagnosis. In addition to more accurate diagnosis, usage as a therapy of any adhesion or inflammation, compression on the radicular nerve therein, and inject medications into the lesions.

### **7.1. Epiduroscopic laser discectomy**

Disc decompression is typically performed both surgically and non-surgically to reduce pressure on the nerve root by removing disc nucleus while preserving disc strength with a high success rate, [1, 2] and low complication rate [32, 33].

Technological innovations in the treatment of disc decompressions has improved the ability to treat pathology effectively through anterior epiduroscopy that requires only local anesthetic and conscious sedation (leading to reduced risk of accidental nerve damage), overcomes the possible complications of surgery and general anesthesia.

Recently, epiduroscopic laser neural decompression (ELND) as another minimal invasive technique have been introduced for chronic low back pain and radicular pain that cannot be solved by other non-invasive conservative treatments, including the epidural steroid injection [34]. In spite of surgery is often considered as the next step in treating continuous chronic low back pain, it has potential risks of post-lumbar surgery syndrome that is difficult to manage. The incidence of post-lumbar surgery syndrome after back surgery ranges from 5 to 50% [35].

Laser is a source of monochromatic, coherent and unidirectional light that used in many fields of medicine with diagnostic and therapeutic purposes. Disc and neural decompression, rechanneling stenoses caused by adhesions are examples of the use of laser and expands the range of possibilities for epiduroscopy. Researches involving lasers have been conducted on the usefulness of epiduroscope for the patients with the post-lumbar surgery syndrome. Epiduroscopic laser application allows treatment of low back pain and radicular pain caused by herniated lumbar disc, adhesions or fibrosis in the epidural space depending on the particular pathological and anatomical circumstances [36, 37].

In the treatment of patients with chronic refractory low back pain a two working channel system of video guided catheter and subsequent application of an optical laser fiber is established. As with the existing epiduroscopic adhesiolysis, epiduroscopic laser neural decompression (ELND) also provides non-invasiveness, short operating time, elimination of the risks of general anesthesia, communication with the patient during the procedure, and short recovery time. ELND offers a variety of additional benefits that direct treatment of the origin of pathology by reducing the volume of the herniated disc in the affected area, direct removal of severely adhered areas with the laser, no occurrence of laser-related oedema or adhesions.

However, an excellent visual control is compulsory for the use of laser where the endoscope with the flexible tip makes possible advancement fine navigation of the relatively rigid laser fiber. Further visual control has to assured and saline infusion has to be started prior to the laser activation.

Because of the risks of heat damage to the nerve roots induced by laser disc decompression, treatment of adhesions near the nerve root should be avoided. Epiduroscopic laser neural decompression can easily remove painful adhesions in the area of the nerve root that cannot mobilized by mechanical movement of the tip of the epiduroscope.

If motor nerve paralysis occurs due to thermal damage of nerve roots during the laser treatment as a complication, the procedure must be aborted immediately. Other complications those need particular caution have been reported as local sensory impairment, fiber breakage, and discitis during the laser procedure [38].

## 8. Complications

In spite of epiduroscopy is a safe technique as a minimal invasive procedure to reduce post-operative complications, the rates of complications will increase commensurate with its increasing usage.

Complications arising during epiduroscopy therapy are mainly reported as headache, cervicodynia, convulsions, dura tear, neurologic damage, visual impairment, infection, general back complaints, vomiting, meningitis, radicular radiating pain, bladder, dizziness, hypoacusia, and rectal disorders.

According to the literature, complications related to epiduroscopy are generally caused by puncture trauma, accidental dural injury, puncture of an epidural blood vessel or epidural bleeding, changes in the epidural pressure caused by saline infusion [39, 40, 42, 45, 49, 50]. The knowledge on the complications and accidental symptoms, using proper epiduroscopic equipment and ensuring optimal vision accompanied with sufficient experience in using the epiduroscopic technique can help prevention from complications.

Post-dural puncture headache are reported relatively frequently during epiduroscopy when attempting to carry out placement of the epiduroscopic catheter or from accidental perforation of the dura as a result of perforation of the spinal dura mater and attributed to a rapid loss of cerebrospinal fluid.

The dural perforation is not a serious complication unless the accidental dural perforation is not recognized and is not responded to, otherwise, spontaneous closure of the perforated site has also observed. Epidural blood patches are reliable in order to treat the patients' headache due to dural perforation during epiduroscopy within a short time [41, 43, 44, 47, 48].

It is reported by Gill and Heavner [51] that a sudden increase in epidural pressure due to the epidural infusion causes compression of the optic nerve and compression of the vessels that results to a rupture and in turn to retinal haemorrhage.

Another clinically relevant complication described by Mizuno et al. [46] in which encephalopathy and rhabdomyolysis was induced by the administration of the contrast agent iotrolan during epiduroscopy.

Our experience has also shown that the amount of liquids delivered to the spinal canal should be calculated precisely during implementation of the epiduroscopy procedure, and infusion rate of drug or radiopaque substances should be at a low speed to avoid complications. When saline fluid was infused too quickly this led to hypertension, decreased oxygen saturation, respiratory arrest, and loss of consciousness where epiduroscopy was immediately terminated [52].

The incidence of complications is inversely proportional to professional skills of practitioner and the number of years of experience. It should be bear in mind, there are risks associated with medical procedures in the spinal region, even when it is performed properly and conscientiously.

## Author details

Havva Sayhan and Serbulent Gokhan Beyaz\*

\*Address all correspondence to: [sgbeyaz@gmail.com](mailto:sgbeyaz@gmail.com)

Faculty of Medicine, Sakarya University, Sakarya, Turkey

## References

- [1] Heavner J, Chokhavatia S, Kizelshteyn G. Percutaneous evaluation of the epidural and subarachnoid space with a flexible fiberscope. *Reg Anesth.* 1991;15(1):85.
- [2] Richter EO, Abramova MV, Cantu F, DeAndres J, Lierz P, Manchiaro PL, Van Buyten JP, Kim JD, Jang JH, Jung GH, Kim JY, Jang S, Salgado H, Salgado P, Alo KM. Anterior epiduroscopic neural decompression: eight-center experience in 154 patients. *Eur J Pain Suppl.* 2011;5(2):401–407.
- [3] Burman M. Myeloscapy or the direct visualisation of the spinal canal and its contents. *J Bone Joint Surg.* 1931;13:695–696.
- [4] Pool J. Myeloscapy: intraspinal endoscopy. *Surgery.* 1942;11:169–182.
- [5] Hirschowitz BI, Curtiss LE, Peters CW, Pollard HM. Demonstration of a new gastro-scope, the fiberscope. *Gastroenterology.* 1958;35(1):discussion 51–3.
- [6] Ooi Y, Morisaki N. Intrathecal lumbar endoscope. *Clin Orthop Surg (Japan).* 1969;4:295–297.

- [7] Saberski LR, Kitahata LM. Direct visualization of the lumbosacral epidural space through the sacral hiatus. *Anesth Analg*. 1995;80:839–840.
- [8] Leu HF, Hauser RK, Schreiber A. Lumbar percutaneous endoscopic interbody fusion. *Clin Orthop Relat Res*. 1997;337:58–63.
- [9] Schutze G, Kurtse G, Grol O, Enns E. Endoscopic method for the diagnosis and treatment of spinal pain syndromes. *Anesteziol Reanimatol*. 1996;4:62–64.
- [10] Ruetten S, Meyer O, Godolias G. Endoscopic surgery of the lumbar epidural space (epiduroscopy): results of therapeutic intervention in 93 patients. *Minim Invasive Neurosurg*. 2003;46(1):1–4.
- [11] Beltrutti D, Groen GJ, Lloyd Saberski L, Kiesling AS, Schutze G, Weber G. Epiduroscopy Consensus Decision March, 2006. In: World Initiative on Spinal Endoscopy (WISE) Consensus Conference; 3–4 March; Graz (Austria). Austria, 2006.
- [12] Avellanal M, Reganon GD, Orts A, Montero LG, Ares JA. Epiduroscopy: Complications and troubleshooting. *Tech Reg Anesth Pain Manage*. 2014;1(8):35–39.
- [13] Bosscher HA, Heavner JE. Lumbosacral epiduroscopy findings predict treatment outcome. *Pain Pract*. 2014;14(6):506–14.
- [14] Westbrook JL. Anatomy of the epidural space. *Anaesth Intensive Care Med*. 2012;13(11):551–554.
- [15] Richter E, Abramova M, Mussell J. Current trends in minimally invasive spinal surgery. *J Neurosurg Rev*. 2011;1(1):1–13.
- [16] Schütze G. *Epiduroscopy Spinal Endoscopy*. 1st ed. Heidelberg: Springer Medizin Verlag; 2008. 156 p.
- [17] Ellis H. The anatomy of the epidural space. *Anaesth Intensive Care Med*. 2009;10(11): 533–35.
- [18] Brockway M. Focus on: central neural blockade anatomy of the epidural space. *Curr Anaesth Crit Care*. 1999;10:118–122.
- [19] Richardson J, Groen GJ. Applied epidural anatomy continuing education in anaesthesia. *Contin Educ Anaesth Crit Care Pain* 2005;5(3): 98–100
- [20] Lee PB, Kim SO, Kim YC. Epiduroscopic Adhesiolysis. In: Kim DH, editor. *Minimally Invasive Percutaneous Spinal Techniques*. 1st ed. Elsevier; 2011.
- [21] Ogan SF. Anatomy and Clinical Importance of the Epidural Space. In: Ogan SF, editor. *Epidural Analgesia—Current Views and Approaches*. 1st ed. Croatia: Intech; 2012. pp. 1–13.
- [22] Maroon JC, Abala A, Bost J. Association between peridural scar and persistent low back pain after lumbar discectomy. *Neurol Res*. 1999;21 (1):S43–620.



- [23] Almeida DB, Prandini MN, Awamura Y, Vitola ML, Simião MP, Milano JB, Bordignon KC, Ache MP, Ramina R. Outcome following lumbar disc surgery: the role of fibrosis. *Acta Neurochir.* 2008;150(11):1167–1176.
- [24] Rönnberg K, Lind B, Zoega B, Göthlin GG, Halldin K, Gellerstedt M, Brisby H. Peridural scar and its relation to clinical outcome: a randomised study on surgically treated lumbar disc herniation patients. *Eur Spine J.* 2008;17(12):1714–1720.
- [25] Jarvik JG, Deyo RA. Diagnostic evaluation of low back pain with emphasis on imaging. *Ann Intern Med.* 2002;137(7):586–597.
- [26] Quintero G, Hugo V, Pachano C, Francisco E. Preventing adhesions in obstetric and gynecologic surgical procedures. *Rev Obstet Gynecol.* 2009;2(1):38–45.
- [27] Heavner JE, Bosscher H, Dunn D, Lehman T. Xanthosis in the spinal epidural space an epiduroscopy finding. *Pain Practice.* 2004;4(1):39–41.
- [28] Sairyo K, Biyani A, Goel VK, Leaman DW, Booth R Jr, Thomas J, Ebraheim NA, Cowgill IA, Mohan SE. Lumbar ligamentum flavum hypertrophy is due to accumulation of inflammation-related scar tissue. *Spine (Phila Pa 1976).* 2007;32(11):E340–7.
- [29] Krasuski P, Poniecka AW, Gal E, Walid A, Truonga A, Harte AML. Epiduroscopy: review of technique and results. *Pain Clin.* 2001;13(1):71–76.
- [30] Jin HS, Bae JY, In CB, Choi EJ, Lee PB, Oct FS. Epiduroscopic removal of a lumbar facet joint cyst. *Korean J Pain.* 2015;28(4):275–279.
- [31] Hoshino Y, Sumitani M, Kusakabe Y, Sato K, Tomioka T, Ogawa M, Sekiyama H, Yamada Y. Successful treatment of spinal canal cystic lesion with the epiduroscopy: a case report. *J Jpn Soc Pain Clin.* 2012;19 (2):98–102.
- [32] Alò KM, Wright RE, Sutcliffe J, Brandt SA. Percutaneous lumbar discectomy: one-year follow-up in an initial cohort of 50 consecutive patients with chronic radicular pain. *Pain Pract.* 2005;5(2):116–123.
- [33] Carragee EJ, Han MY, Yang B, Kim DH, Kraemer H, Billys J. Activity restrictions after posterior lumbar discectomy: a prospective study of outcomes in 152 cases with no postoperative restrictions. *Spine.* 1999;24(22):2346–2351.
- [34] Jo DH, Yang HJ. The survey of the patient received the epiduroscopic laser neural decompression. *Korean J Pain.* 2013;26:27–31.
- [35] Takeshima N, Miyakawa H, Okuda K, Hattori S, Hagiwara S, Takatani J, Noguchi T. Evaluation of the therapeutic results of epiduroscopic adhesiolysis for failed back surgery syndrome. *Br J Anaesth.* 2009;102:400–407.
- [36] Ruetten S, Meyer O, Godolias G. Epiduroscopic diagnosis and treatment of epidural adhesions in chronic back pain syndrome of patients with previous surgical treatment: first results of 31 interventions. *Z Orthop Ihre Grenzgeb.* 2002;140(2):171–175.

- [37] Hayek SM, Helm S, Benyamin RM, Singh V, Bryce DA, Smith HS. Effectiveness of spinal endoscopic adhesiolysis in post lumbar surgery syndrome: a systematic review. *Pain Phys.* 2009;12(2):419–435.
- [38] Ahn JS. Laser decompression. *J Korean Soc Spine Surg.* 2000;7:318–321.
- [39] Racz GB, Heavner JE, Trescot A. Percutaneous lysis of epidural adhesions—Evidence for safety and efficacy. *Pain Pract.* 2008;8(4):277–286.
- [40] Talu GK, Erdine S. Complications of epidural neuroplasty: a retrospective evaluation. *Neuromodulation.* 2003;6(4):237–247.
- [41] Perkins WJ, David DH, Huntoon MA, Horlocker TT. A retained Racz catheter fragment after epidural neurolysis: implications during magnetic resonance imaging. *Anesth Analg.* 2003;96(6):1717–1719.
- [42] Richter H. Is the so-called epidural neuroplasty (Racz catheter) a harmless procedure? In: *Neurochirurgie DGF*, ed. Deutsche Gesellschaft Fur Neurochirurgie. Strasbourg, Germany: Deutsche Gesellschaft fur Neurochirurgie; 2005.
- [43] Wagner KJ, Sprenger T, Pecho C, Kochs EF, Tölle TR, Berthele A, Gerdesmeyer L. Risks and complications of epidural neurolysis—a review with case report. *Anesthesiol Intensmed Notfallmed Schmerzther.* 2006;41(4):213–222.
- [44] Moschos MM, Rouvas A, Papaspirou A, Apostolopoulos M. Acute visual loss and intraocular hemorrhages associated with endoscopic spinal surgery. *Clin Ophthalmol.* 2008;2(4):937–939.
- [45] Heavner J, Wyatt DE, Bosscher H. Lumbosacral epiduroscopy complicated by intravascular injection. *Anesthesiology.* 2007;107(2):347–350.
- [46] Mizuno J, Gauss T, Suzuki M, Hayashida M, Arita H, Hanaoka K. Encephalopathy and rhabdomyolysis induced by iotrolan during epiduroscopy. *Can J Anaesth.* 2007;54(1):49–53.
- [47] Komiya K, Igarashi T, Suzuki H, Hirabayashi Y, Waechter J, Seo N. In vitro study of patient's and physician's radiation exposure in the performance of epiduroscopy. *Reg Anesth Pain Med.* 2008;33(2):98–101.
- [48] Heavner JE, Bosscher H. Epiduroscopy and radiation exposure. *Reg Anesth Pain Med.* 2009;34(1):79.
- [49] Avellanala M, Diaz-Reganona G, Ortsa A, Gonzalez-Monteroa L, Aresc JA. Epiduroscopy complications and troubleshooting. *Techniques in Regional Anesthesia and Pain Management.* 2014;18(1–2):35–39.
- [50] Kallewaard JW, Vanelderden P, Richardson J, Van Zundert J, Heavner J, Groen GJ. Epiduroscopy for patients with lumbosacral radicular pain. *Pain Pract.* 2014;14(4):365–77.

- [51] Brian Gill J, Heavner JE. Visual impairment following epidural fluid injections and epiduroscopy: a review. *Pain Med.* 2005;6(5):367–374.
- [52] Beyaz SG. Seizures and transient neurological deficits during epiduroscopy in a patient with failed back surgery syndrome. *Pain Med.* 2015;16(4):825–827.
- [53] Manchikanti L, Boswel MV, Singh V, Pampati V, Damron KS, Beyer CD. Prevalence of facet joint pain in chronic spinal pain of cervical, thoracic, and lumbar regions. *BMC Musculoskelet Disord.* 2004;5(15)
- [54] Belozer M, Wang G. Epidural adhesiolysis for the treatment of back pain. *Health Technol Assess.* 2004;5:1–19.

