

# An Unusual Case of sudden Complete Urinary Incontinence 20 Days after Pelvic Floor Surgery and Tension-Free Vaginal Tape

Haemmerle B., Schmid S., Keller N.  
 Gynaecology and Obstetrics, Grabs, Switzerland

## Problem statement

Tension-free midurethral synthetic slings are a minimal invasive treatment of stress urinary incontinence. If urinary incontinence occurs in combination with pelvic floor disorder, a combined treatment must be considered. We describe a case of sudden complete urinary incontinence 20 days after pelvic floor surgery and mid-urethral sling operation.

## Methods and Results

An 81-year-old woman presented herself with disturbing stress urinary incontinence and symptomatic pelvic organ prolapse in our outpatient clinic. In the past her stress urinary incontinence was treated with an incontinence ring pessary until the pelvic organ prolapse increased and the pessary dislocated. 30 years before she had had an abdominal hysterectomy and presumably a colposuspension. During the examination a further pelvic floor disorder comprising of vaginal vault prolapse, cystocele, enterocele, distal rectocele and anterior rectocele with stool-outlet-obstruction was diagnosed. In a urodynamic study the stress urinary incontinence could be confirmed. To repair the symptomatic pelvic floor disorder the patient required an anterior and posterior colporrhaphy, vaginal repair of enterocele and anterior rectocele. Additionally a tension-free midurethral sling (retropubic tension-free vaginal tape, TVT) was implanted because of stress urinary incontinence. Seven days after the operation the patient restarted taking acetylsalicylic acid (100mg) because of cardiac indication. After an uneventful first follow-up examination 14 days after the surgery with sonographic correct position of the TVT, the patient reported 20 days later with suddenly occurred complete urinary incontinence. The clinical and sonographic examinations showed a new haematoma of the vaginal vault and the anterior vaginal wall with consequent dislocation of the TVT. Four months later the haematoma had slightly become smaller and the urinary incontinence had improved.

## Conclusion

The occurrence of vaginal vault haematoma 20 days after pelvic floor repair is unusual even in combination with the intake of acetylsalicylic acid. The volume of the haematoma caused the dislocation of the TVT, which resulted in complete urinary incontinence. But when the haematoma absorbed, the incontinence improved. Once the TVT dislocated by haematoma, it might not be correctly placed anymore after its absorption. If there is still some incontinence after the entire absorption of the haematoma, the placement of a new TVT could be considered.

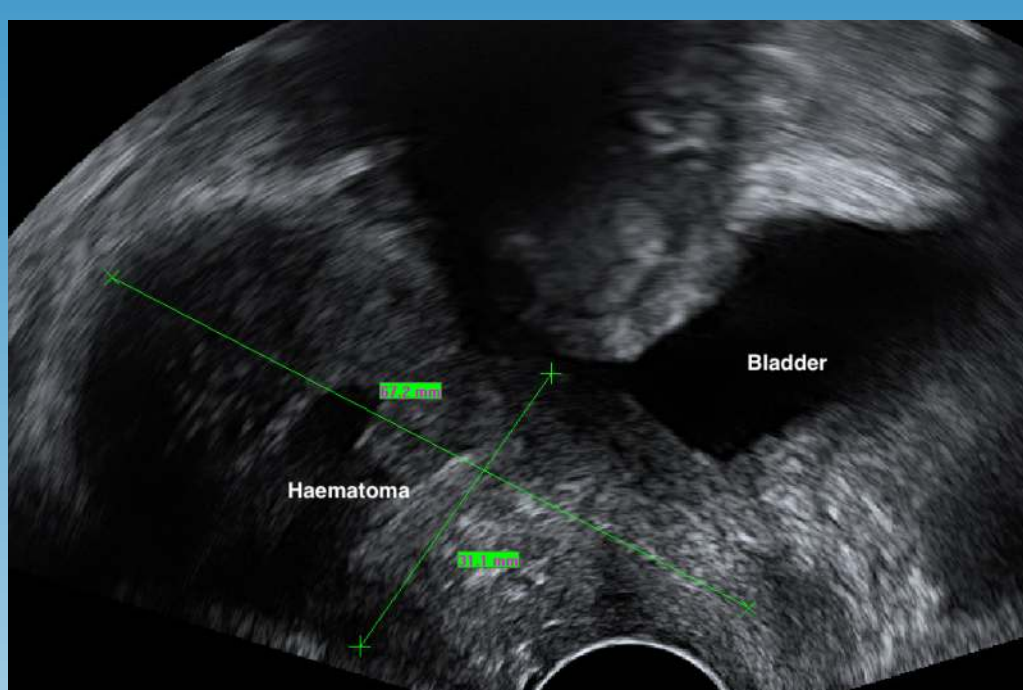


Fig. 1: Haematoma 20 days after surgery

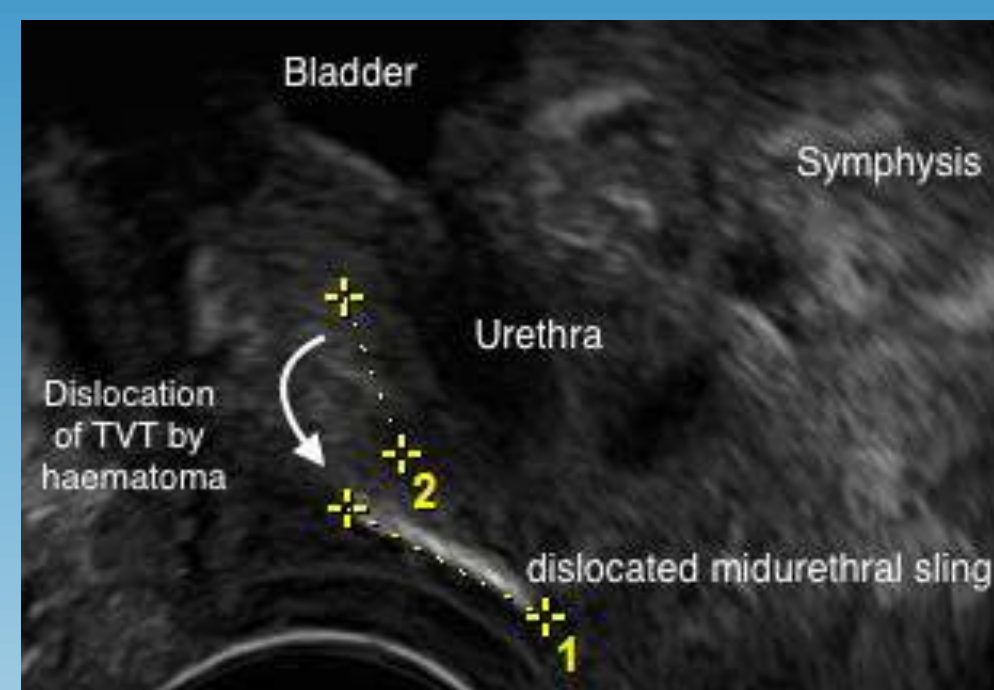


Fig. 2: Dislocated TVT after absorption of the haematoma

1. Balachandran A., Curtiss N., Duckett J. The management of massive haematomas after insertion of retropubic mid-urethral slings. *Int Urogynecol J.* 2015; 26: 1449 - 1452.
2. May L., Jha S., Abdi S. Management of massive retropubic haematoma post-TVT. *Int Urogynecol J.* 2016; 27: 1279 – 1280.
3. Piskytlova P. Complications tension.free vaginal tape surgery. *Ceska Gynekol.* 2017; 82: 243-251.