

# Diagnosis of Congenital Diaphragmatic Hernia (CDH)

Kotis Alexandros, Tsikouris Panagiotis, Lisgos Philip,  
Dellaporta Irini, Georganas Marios, Ikonomidou Ioanna,  
Tsiopanou Eleni and Karatapanis Stylianos  
*General Hospital of Rhodes  
Greece*

## 1. Introduction

Congenital diaphragmatic hernia (CDH) is a congenital malformation (birth defect) of the diaphragm. The most common type of CDH is a Bochdalek hernia; other types include Morgagni's hernia, diaphragm eventration and central tendon defects of the diaphragm. Malformation of the diaphragm allows the abdominal organs to push into the chest thereby impeding proper lungformation. CDH is a life-threatening pathology in infants, and a major cause of death due to two complications: pulmonary hypoplasia and pulmonary hypertension. The frequency of CHD is approximately 1/3000 births. The survival rate for infants with hernias of the foramen of Bochdalek varies from institution to institution; but overall, it has remained at about 50% for nearly half a century, despite advances in neonatal intensive care, anesthesia, and surgery. CDH is believed to result from incomplete fusion of the pleuroperitoneal membrane, and passage of the abdominal contents into the chest. A chest x-ray can confirm the diagnosis if bowel gas is visible above the diaphragm accompanied by a mediastinal shift. CDH can also be found in older children (5-30% of CHD)(32) presenting with acute distress or GI symptoms, in most cases due to an episode of infection with involvement of the residual lung and airways (B streptococcus pneumonia) or posttraumatic involvement. This paper aims to evaluate the appearance of congenital diaphragmatic hernia (CDH) by diagnostic imaging methods. Anterior CHD through the foramen of Morgagni (90% right sided) is less common (1-5%) and is usually asymptomatic(31). Prenatal US and/or prenatal MRI already detects the hernia in utero in most cases(28). The intrathoracic space restriction results in ipsilateral lung hypoplasia. The associated pulmonary hypertension makes it very difficult to provide adequate oxygenation. Restoring the intrathoracic space and achieving pulmonary expansion are the main goals of surgery.

## 2. Diagnosis and testing

Congenital diaphragmatic hernia can be detected prenatally by an ultrasound examination performed during the second trimester in most affected infants. Clinical examination of the newborn with CDH often reveals a scaphoid abdomen (since the abdominal contents can be

in the thorax), diminished breath sounds ipsilateral to the side of the hernia, and displacement of the heart sounds contralateral to the hernia. A chest x-ray can confirm the diagnosis if bowel gas is visible above the diaphragm accompanied by a mediastinal shift.

## 2.1

Diaphragmatic anomalies indirectly involve the gastrointestinal system by allowing herniation or displacement of abdominal contents into the thorax, thereby distorting normal anatomic relationships. The following diaphragmatic anomalies have been detected by antenatal sonography: posterolateral (Bochdalek) hernias, anterolateral (Morgagni) hernias, and diaphragmatic eventrations. Posterolateral diaphragmatic hernias are the most common and form as a result of incomplete fusion of the pneumoperitoneal membrane during embryogenesis. Occurring more frequently on the left than the right, they are typically associated with herniation of abdominal viscera such as stomach, spleen, and small bowel into the left hemithorax. Right-sided defects tend to involve the liver and gallbladder, so they may be more difficult to diagnose due to similarities in echogenicity of fetal lung and liver(27). Sonographic findings commonly identified in conjunction with posterolateral diaphragmatic hernias include cystic or solid intrathoracic masses corresponding to abdominal organs, mediastinal shift, smaller than expected abdominal circumference, and failure to identify a fluid filled stomach in the left upper quadrant(25,26,27). Polyhydramnios is frequent and pleural effusions or ascites are occasionally seen. Paradoxical movement of the abdominal contents on the side of the hernia has been described during fetal respiratory efforts. Positive identification of intrathoracic bowel loops is possible when peristalsis is observed during real time evaluation. In the absence of this specific finding, documentation of a very low abdominal circumference or lack of gastric visualization is strongly suggestive of diaphragmatic hernia if seen in conjunction with unilateral thoracic mass lesions. Other fetal intrathoracic masses such as cystic adenomatoid malformation, pulmonary sequestration, and bronchogenic cyst should also be considered in the differential diagnosis. Although it is possible to overdiagnose diaphragmatic hernias on oblique scans that demonstrate thoracic and abdominal contents in the same plane, if care is taken to obtain a true cross section of the chest, this pitfall can be avoided. Even when peristalsis of intrathoracic bowel loops is observed, a definitive diagnosis of diaphragmatic hernia may not be possible because the sonographic findings associated with diaphragmatic eventration may be almost identical with those seen with hernias. In a recent series of diaphragmatic anomalies, detected antenatally, the only finding distinguishing a case of diaphragmatic eventration was a normal abdominal circumference. Although diaphragmatic hernias are usually accompanied by severe respiratory complications related to pulmonary hypoplasia, pulmonary function tends to be much better in infants with unilateral diaphragmatic eventration. Anteromedial (Morgagni) hernias form as a result of maldevelopment of the septum transversum in the retrosternal area. They are often associated with a defect in the pericardium, allowing abdominal contents to herniate into the pericardial sac. Antenatal sonography may reveal pericardial effusion and an anteriorly located intrathoracic mass in cases of anteromedial diaphragmatic hernia.(24)

Congenital abnormalities of the diaphragm range from total agenesis, an extreme life threatening condition with herniation of abdominal contents into the thorax, to that of a rare

accessory hemidiaphragm that describes an almost vertical course through the chest, along the course of the major fissure, radiographically mimicking upper lobe disease or collapse, particularly on the left side(36). Eventrations (localized congenital weaknesses or absence of the musculature of the central portion of the diaphragm) usually manifest themselves as smooth convex mounds interrupting the gentle curvature of the diaphragm normally seen on chest radiographs. This most commonly presents in childhood on the right side, whereas that found in adults has a left-sided predominance. With eventration a curious tilting of the liver may be seen during the course of CT examination, where the anterior portion of that organ occupies a higher position than its posterior half. Both fluoroscopy and ultrasound may be used to evaluate the motion of the diaphragm in this condition. Very little or no inferior movement is seen on inspiration. The most common organ herniating through the hemidiaphragm is the stomach (36). The less common of the diaphragmatic hernias are those through the foramen of Morgagni anteromedially. These occur predominantly on the right and usually contain omentum; however, liver and colon are occasionally present within them. Herniation through an incompletely closed posterolateral pleuroperitoneal membrane (the foramen of Bochdalek) is usually on the left side. These are common in infants and may contain retroperitoneal fat, spleen, kidney or even large bowel. Congenital diaphragmatic hernia may be diagnosed prenatally using ultrasound, when the abdominal organs may be visualized within the fetal thorax, even displacing the mediastinum. In the newborn, respiratory distress, a scaphoid abdomen, and air-filled loops of bowel in one side of the chest usually suggest the diagnosis. In the case of bilateral anteromedial defects of the diaphragm, a characteristic picture of a three tiered snowman, with elevation of the heart and thymus by herniation of abdominal structures through a single midline opening, is usually seen(36).

The large diaphragmatic hernias that compromise lung growth are posterolateral in position and are caused by defective closure of the pleuroperitoneal canal. The remnant of this canal in the normally developed diaphragm is the foramen of Bochdalek. Typically, infants with congenital diaphragmatic hernias are severely distressed at birth, and because the abdomen contains fewer contents than normal, it appears scaphoid. Radiographically, the abdominal contents, which may include stomach, bowel, spleen and liver, can be identified within the thorax. Approximately 85% of congenital hernias are left sided(33). Rarely multicystic lesions such as cystic adenomatoid malformation may be considered in the differential diagnosis. In this situation fluoroscopy has been advocated in order to visualize intestinal peristalsis, but barium studies are not required. The ipsilateral lung is the more severely hypoplastic, but because of mediastinal shift, a lesser degree of contralateral hypoplasia is also present. The aerated ipsilateral lung may be visible preoperatively in the apex of the hemithorax, but the true degree of growth arrest can be appreciated only postoperatively when the tiny lung, tethered by the hilum, is outlined by a large pneumothorax. Contralateral hypoplasia is not as obvious, although more severe involvement may be indirectly indicated by the presence of pneumothorax caused by overdistention of underdeveloped alveoli. For this reason, the complication of contralateral pneumothorax signifies a poor prognosis(34).

The diaphragmatic hernia affects the lung primarily by interference with airway generation. Following unsuccessful operation, alveoli multiply at a normal rate and increase in size in an attempt to obtain normal lung volume. However airways are unable to multiply postnatally and there are also fewer pulmonary vessels. As it always increases in volume,

the overdistended alveoli of the persistently hypoplastic lung result in a hyperlucent, emphysematous appearance, particularly of the lower lobe(35).

## 2.2

There is a high incidence of anomalies associated with each of the diaphragmatic lesions discussed here. These include chromosomal anomalies and gastrointestinal, genitourinary and cardiovascular defects. Identification of a diaphragmatic anomaly should prompt careful sonographic evaluation of the fetus for concomitant abnormalities as well as consideration of chromosomal analysis. In the absence of other lethal lesions, antenatal sonographic detection of diaphragmatic defects requires delivery to be performed at a tertiary care center appropriately equipped to manage the affected newborn, thus maximizing the infant's chance of survival.

## 2.3

Clinical examination is seldom revealing of a diagnosis, although a large rupture may mimic cardiac tamponade. The chest radiograph in the erect position may be the most diagnostic clue. Elevation of the hemidiaphragm, hemothorax, and bowel loops in the chest may lead one to perform upper and/or lower GI tract barium examinations, ultrasound, CT, angiography of the celiac axis, liver and lung scans, or even administration of contrast through a chest tube with a search for its appearance in the abdomen(36). CXR or ultrasound scan will confirm the diagnosis in a neonate who has not previously been diagnosed. Arterial blood gas measurements are required for pH, PaCO<sub>2</sub> and PaO<sub>2</sub>. With persistent pulmonary hypertension with right-to-left ductal shunting, the PaO<sub>2</sub> may be higher from a pre-ductal (right-hand) sampling site. Blood samples must be monitored for electrolytes, calcium and glucose. Ultrasound of the heart and urinary system may be required to assess for other abnormalities. Cranial ultrasonography will highlight neural abnormalities such as hydrocephalus and neural tube defects. Chromosomal analysis may be indicated.(22).

## 2.4

Additionally air-fluid loops of bowel in a congenital diaphragmatic hernia can resemble the multiple cysts of cystic adenomatoid malformation. An important clue to the correct diagnosis of diaphragmatic hernia is the absence or paucity of gas-filled bowel loops within the abdomen. Congenital diaphragmatic hernias most often occur through the foramen of Bochdalek, which lies posteriorly and medially in each hemidiaphragm. Left-sided hernias are more common and more frequently involve bowel herniation. Solid abdominal viscera are more likely to herniate into the chest through right-sided hernias. Hernias through the foramen of Morgagni, which lies anteriorly, are less common and usually are less severe. Infants with large diaphragmatic hernias usually present with severe respiratory distress immediately after birth. Compression of the ipsilateral lung in utero causes it to be hypoplastic and often the contralateral lung is also small. The patients are profoundly hypoxic and a persistent fetal circulation caused by hypoxia-induced pulmonary hypertension usually further compromises the infant's condition. Even with early diagnosis and surgery, the mortality of this condition remains high. ECMO has improved the survival

of some patients by circumventing the problem of pulmonary hypertension and the right-to-left shunting of blood away from the lungs. Congenital diaphragmatic hernia may be minimally symptomatic at birth and can present later in life(20).

Poor outcomes have been connected with pneumothorax (reflecting lung hypoplasia) and a right-sided defect, whereas favorable features include the presence of aerated ipsilateral lung and aeration in the contralateral lung of more than 50%.

Congenital diaphragmatic hernia (CDH) is a major surgical emergency in newborns and the key to survival lies in prompt diagnosis and treatment.

From many imaging studies Aspelund et al concluded that prenatal LHR  $> 0.85$  predicts survival for infants with isolated left-sided CDH without compromising discrimination of survivors from non-survivors. The diagnostic utility of LHR may be confounded by gestational age at measurement. Stringent LHR threshold may minimize false-negative attribution and improve utility of this measurement as predictor of survival. Kozakiewitz et al concluded that congenital diaphragmatic hernia (CDH) in most cases presents immediately or within hours after birth with signs of respiratory failure: dyspnea, tachypnea, and cyanosis. Kline-farh et al concluded that with further research with prenatal US and fetal MRI and the development of innovative medical and surgical therapies, the morbidity and mortality of children with congenital diaphragmatic hernias can be significantly reduced. Cruz-Martinez et al concluded that Intrapulmonary artery Doppler evaluation helps to refine the prediction of survival after FETO in fetuses with severe CDH and that the minimum number of scans required for an inexperienced trainee to become competent in examining the LHR is on average 70. Cannie M et al concluded that there is a significant relationship between Apparent Diffusion Coefficient (low) and Apparent Diffusion Coefficient (high) values and gestational age in normal fetal lungs. This relationship is most probably explained by developmental changes during the last three stages of lung development, which involve intense peripheral growth of airways and vessels as well as maturation. In CDH, measurement of ADC (low) might be useful as a predictor of postnatal outcome that is independent of lung volume. Gorincour G, et al concluded that normal fetal lung signal intensity curves can be obtained. Lungs at risk of hypoplasia presented significant alterations of signal ratios. The prognostic value of such results requires additional postnatal clinical follow-up. Kilian et al concluded that among fetuses with left-sided CDH, assessment of pulmonary hypoplasia based on MRI relative fetal lung volume and MRI relative lung-to-head ratio is excellent in prediction of neonatal survival and ECMO requirement. The prognostic accuracy is slightly better than that of sonographic relative lung-to-head ratio. Among fetuses with right-sided CDH, the prognostic value of all parameters is lower than those among fetuses with left-sided defects. Jani J, et al concluded that in the assessment of fetuses with CDH, MRI-based o/e Total Fetal Lung Volume is useful in the prediction of postnatal survival

Siegel MJ, et al in a study with seven patients with left-sided congenital diaphragmatic hernias at ages of 2-20 months are reported and five are described in detail. Radiographic findings were classic in one patient, but simulated inflammatory chest disease in two patients, gastric volvulus in three patients, and a pneumothorax in one patient. These misleading appearances if not recognized can lead to incorrect radiographic interpretation and in some cases inappropriate treatment. Reither M. concluded that the most common

causes of respiratory distress in the newborn and the frequently rapidly changing pulmonary pattern in the follow up studies are presented. Various degrees of the hyaline membrane disease and bronchopulmonary dysplasia are demonstrated as well as the different changes of the pulmonary pattern in controlled and assisted ventilation, recurrent atelectasis, dystelectasis, emphysema, pneumothorax and pneumomediastinum. Chest film follow up series are demonstrated. The differential diagnosis includes pulmonary aspiration syndrome, the neonatal pneumonia and emergency cases in pediatric surgery. Hubbard AM et al demonstrated that in these fetuses, MR imaging proved important by clearly demonstrating herniation of fetal liver into the chest, thereby changing family counseling and prenatal care. Levin D. et al concluded that although oligohydramnios subjectively degrades image resolution, sonography still reveals important fetal anatomic landmarks. Major anomalies can be detected on sonography even when the pregnancy has less than the normal amount of amniotic fluid. Strouse PJ et al concluded that Congenital abnormalities of the umbilical venous system are rare. A case of fatal right congenital diaphragmatic hernia (CDH) in association with an anomalous umbilical vein bypassing the liver and directly entering the right atrium is presented. The ductus venosus was absent. Although much of the liver was within the right hemithorax, radiographs showed an apparently normal umbilical venous catheter (UVC) course, suggesting a normally positioned liver and mitigating against the diagnosis of CDH. Aberrant umbilical drainage, yielding a falsely normal appearing UVC course, may delay the diagnosis of CDH. Perez CG, demonstrated that Ultrasonographic examination of the fetal abdomen is an integral part in all routine fetal sonograms and can provide significant information about the status and prognosis of the fetus. Although many types of fetal anomalies can be identified (i.e., gastroschisis, omphalocele, or congenital diaphragmatic hernia), there are several sonographic findings that are not clearly anomalous, but may be associated with poor fetal outcome. Echogenic fetal bowel, small or absent fetal stomach and fetal intra-abdominal calcifications all fall into this category. This article reviews the recent literature as it relates to these topics, including suggestions regarding the need for further action, and the types of further actions that are available to help identify abnormal fetuses and prevent unnecessary and/or invasive testing of normal ones. Urban BA, concluded that Helical CT amniography is an efficient means for evaluation of congenital diaphragmatic hernia. Accurate diagnosis was made in all three patients. Hubbard AM, et al concluded that MR imaging is a valuable adjunct to US for prenatal diagnosis of fetal chest masses. The need for immediate postnatal diagnosis has been de-emphasized, but the demand for precision and efficiency in preoperative cross-sectional imaging, monitoring progress and complications of treatment, and assistance with nutritional support has increased (Schwartz DS, et al.). Five cases with congenital diaphragmatic hernia all demonstrated fetal breathing activity by thoracic wall movement (Fox HE et al). In four of the fetuses, perinasal fluid flow was seen by the Doppler technique. The fetus with no demonstrated perinasal flow during breathing movements died in the early neonatal period and had pulmonary hypoplasia. Observation of the fetal breathing-related nasal and oropharyngeal fluid flow in cases of antenatally diagnosed congenital diaphragmatic hernia provides a rationale to hypothesize that the absence of this phenomenon is a useful marker for prenatal prediction of pulmonary hypoplasia. Guibaud L et al concluded that Sonography is highly accurate for prenatal diagnosis of CDH. Sonography also assists the prognostication of postnatal outcome in isolated CDH by allowing quantification of the contralateral lung area on a four-chamber view.

Knox E, et al demonstrated that in CDH, LHR and the presence of liver in the fetal thorax may be a useful predictive indicator of perinatal survival. Future usage of developing techniques needs careful evaluation prior to usage to guide therapy. Mullassery D, et al demonstrated that Liver herniation is associated with poorer prognosis in fetal CDH. Grading liver herniation or using it as part of a panel of markers may enhance the value of liver herniation as a prognostic test in fetal CDH. Bağlaj M, et al concluded that Chest radiography following passage of a nasogastric tube and contrast studies of the gastrointestinal tract seem to be the most useful investigations for the diagnosis of left CDH. For patients with right CDH, owing to the high probability of liver herniation, a chest radiograph with liver scintigraphy or CT seems to be the best diagnostic option. Coleman BG, et al demonstrated that Fetal therapy is a rapidly evolving specialty, which is being practiced at several centers in this country. Sonography is an integral part of this specialty practice and has been used extensively in the diagnosis of some congenital anomalies that have debilitating or lethal consequences for the fetus. Technologic improvements in both sonography and magnetic resonance imaging have assisted tremendously in the many advances herein reported in the diagnosis and treatment of the above-described 4 congenital anomalies. Coakley FV. Et al showed that prenatal MRI has been shown to positively and incrementally influence management in a substantial proportion of patients being considered for fetal intervention. Despite these findings, precise indications for prenatal MRI in the setting of fetal surgery are not yet established, because both prenatal MRI and fetal surgery are relatively new techniques that remain in evolution. Fox HE, et al showed that all studies show that there is a clear association between most of these markers and pulmonary hypoplasia. However, these markers have not been studied together in a large number of cases, and comparisons between each of the markers is unknown

### **3. Imaging studies**

#### **Radiography**

##### **3.1**

In the neonatal and infantile periods, the importance of obtaining a chest radiograph at the first sign of distress cannot be overstated. This image usually permits an accurate diagnosis, alternatively sometimes plain abdominal radiography is also needed for a precise diagnosis. Typically, no bowel gas is evident in the abdomen. A chest x-ray can confirm the diagnosis if bowel gas is visible above the diaphragm accompanied by a mediastinal shift. Congenital diaphragmatic hernia can be detected prenatally by an ultrasound examination performed during the second trimester in most affected infants

##### **3.2**

In patients presenting in the neonatal and infantile periods, the classic radiographic appearance of congenital diaphragmatic hernia is one in which the left hemithorax is filled with loops of bowel, the mediastinum is shifted to the right, and the abdomen is relatively devoid of gas. In some cases, a few loops of intestine can be seen in the abdomen, but more often only the stomach remains visible within the abdomen. Interestingly, the stomach may be in an abnormal location, often more central than one would expect. The abnormal

positioning of the stomach may be helpful in differentiating congenital diaphragmatic hernia from those few cases of congenital cystic adenomatoid malformation (CCAM) in which the cysts are large enough to mimic the air-filled intestinal loops. In CCAM of the lungs, the stomach and bowel are normal in position and appearance.

### 3.3

If the chest radiograph is obtained before any air has entered the herniated bowel, diagnosing this condition with accuracy may be difficult. Similar difficulties arise when the liver alone is in the right hemithorax. In either case, the involved hemithorax is partially or totally opacified, and the mediastinal structures are shifted to the other side. In this circumstance, a large pleural fluid collection or mass may be present; however, in most such cases, air soon enters the intestine, and this finding establishes the diagnosis. In other cases, the condition may be diagnosed by noting abnormal intrathoracic positioning of a nasogastric tube.

### 3.4

Placement of an orogastric tube prior to the study helps decompress the stomach and helps determine whether the tube is positioned above or below the diaphragm.

### 3.5

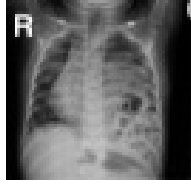
Typical findings in a left-sided posterolateral congenital diaphragmatic hernia include air-filled or fluid-filled loops of the bowel in the left hemithorax and shift of the cardiac silhouette to the right. Examine the chest radiograph for evidence of pneumothorax. The incidence of associated cardiac anomalies is high (approximately 25%); therefore, cardiac ultrasonography is needed shortly after birth. Cardiac defects may be relatively minor (atrial septal defect) or life-threatening (transposition of great vessels, hypoplastic left heart, aortic coarctation). In addition, echocardiography is helpful in assessing myocardial function and determining whether the left ventricular mass is significantly decreased(18,19). Unusual findings on plain radiography include a contralateral pneumothorax, contralateral collapse/consolidation, fluid in the chest, and the absence of a contralateral aerated lung. If herniation occurs on the right, the intestine and liver or the liver alone may fill the right hemithorax. If the liver is in the chest, its normal silhouette is not generally seen in the abdomen.

## 4. Morgagni hernias

### 4.1

Classically, Morgagni hernias appear as unilateral, mediastinal, and basal masses containing a variety of abdominal organs, including air-filled loops of intestine. Occasionally, these hernias may be bilateral, and in rare cases, they may produce significant respiratory distress. Large anterior-central diaphragmatic hernias may produce elevation of the cardiac silhouette and bilateral bulges to either side of the lower mediastinum. Often, these herniations occur into the pericardial cavity. When this occurs, serious cardio respiratory compromise can result.



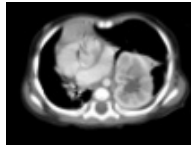


A 4 month old baby boy with congenital diaphragmatic hernia.

## 5. Computed tomography

### 5.1

In adults with congenital diaphragmatic hernia, previously undiagnosed Bochdalek hernias are most frequently identified when patients undergo computed tomography (CT) scanning for reasons that appear to be unrelated to the hernia. These Bochdalek hernias usually contain retroperitoneal fat or a kidney. Some authors believe that, with the routine use of thin-section CT scanning on modern imaging equipment, the prevalence and characteristics of late-presenting Bochdalek hernia can be more accurately estimated. However, small Bochdalek defects may occur in as many as 6% of older adults. Additionally, there was marked improvement over conventional CT amniography in embryos with helical CT amniography. Data are obtained immediately after localization with a low-dose topogram that eliminates the need for real-time sonographic guidance(21).



A 4 month old baby boy with congenital diaphragmatic hernia.

## 6. Magnetic resonance imaging

### 6.1

Regarding the prenatal magnetic resonance imaging (MRI) evaluation of congenital diaphragmatic hernia, advances in this modality provide high-quality images of the intrathoracic organs. MRIs can clearly depict diaphragmatic discontinuity, a fetal compressed lung, and connecting bowel segments between the abdomen and chest. MRI can accurately depict congenital diaphragmatic hernia and permits an easy diagnosis. MRI findings can be used to differentiate this condition from other chest masses, and MRI is superior to ultrasonography in demonstrating the position of the fetal liver above or below the diaphragm. Fetal MRI is increasingly being used to confirm the diagnosis of CDH, as well as to better define the internal anatomy [Hedrick et al 2004]. Calculation of lung volumes using fast spin-echo MRI appears to provide good prognosis about the degree of pulmonary hypoplasia and subsequent fetal outcome and seems likely to replace the LHR derived from ultrasound examination for this purpose [Gorincour et al 2005](17). Ultrafast fetal MRI – an imaging technique advanced at CHOP that checks the position of the abdominal organs, especially the liver, and measures protrusion into the chest. Ultrafast

fetal MRI is used to better define the severity of CDH, exclude associated anomalies and estimate fetal lung volume as a prognostic indicator. We recommend fetal MRI two times during gestation. The first MRI is obtained during the initial evaluation in order to demonstrate the anatomic defect and determine whether or not the liver is herniated, which may be difficult to determine with ultrasound alone. Fetal MRI is useful in excluding other associated abnormalities in the chest, abdomen and brain. Magnetic Resonance Imaging (MRI) testing can assist in these efforts as well. Sometimes CDH does not appear through ultrasound images, and a diagnosis is made after the child has been born. There are a few centers where a Fetal Therapeutic or CDH team might both evaluate a baby prior to birth, and discuss treatment options with the parents of the child. Fetal MRI is increasingly being used to confirm the diagnosis of CDH, as well as to better define the internal anatomy [Hedrick et al 2004]. Calculation of lung volumes using fast spin-echo MRI appears to provide good prognosis about the degree of pulmonary hypoplasia and subsequent fetal outcome and seems likely to replace the LHR derived from ultrasound examination for this purpose [Gorincour et al 2005].

When CDH is found on routine prenatal ultrasound examination, both a high-resolution ultrasound examination and fetal MRI to determine the presence of additional structural anomalies are indicated. Chromosome analysis of fetal cells obtained by amniocentesis should be considered in all cases while CGH should strongly be considered when CDH is present in conjunction with additional anomalies.

All fetuses with CDH should be evaluated for the presence of syndromes and/or additional major malformations given that they so commonly coexist and significantly affect the prognosis. Involvement of a medical geneticist in the evaluation of these families can be helpful. The measurement of either the expected/observed LHR or the lung volume by fetal MRI have been useful to predict outcome; however, since the predictive value of these measurements varies from center to center, results must be interpreted with caution.

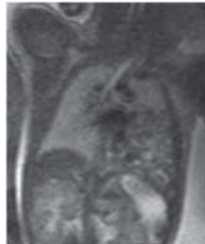

Fig. 1. 34-week fetus with left-sided congenital diaphragmatic hernia.

## 7. Ultrasonography

### 7.1

In prenatal life, ultrasonography has a high sensitivity in the detection of congenital diaphragmatic hernia. Bowel loops may appear to undergo peristalsis in the chest. The definite ultrasonographic diagnosis of fetal congenital diaphragmatic hernia lies on the visualization of abdominal organs in the chest; the ultrasonographic hallmark of this condition is a fluid-filled mass just behind the left atrium and ventricle in the lower thorax,

as seen on a transverse view. In patients presenting in the prenatal period, ultrasonographic features indicative of congenital diaphragmatic hernia include polyhydramnios, an absent or intrathoracic stomach bubble, a mediastinal and cardiac shift away from the side of the herniation, a small fetal abdominal circumference, the absence of the stomach in the abdomen, and, rarely, fetal hydrops. In a right-sided hernia, the right lobe of the liver alone may be herniated, or associated hydrothorax and ascites may be observed. Pregnant women carrying a fetus with congenital diaphragmatic hernia are often referred for ultrasonography first because of suspected polyhydramnios. **Color flow Doppler** can be used to: Demonstrate abnormal positioning of the umbilical and portal veins, which are indicative of liver herniation; Identify right-sided hernias, which can be difficult to detect on ultrasound examination because of the similar echogenicity of lung and liver(16). As with other birth defects, most congenital diaphragmatic hernias (CDHs) are typically discovered by routine ultrasound at 16 to 18 weeks gestation. Families referred to The Children's Hospital of Philadelphia's Center for Fetal Diagnosis and Treatment undergo a comprehensive, one-day evaluation that includes: High-definition level II ultrasound – to assess the defect and to determine the fetus' lung-to-head circumference ratio (LHR), a measure that can help predict the severity of lung problems associated with CDH. Many infants are now diagnosed in utero by Ultrasound imaging testing often identifies CDH before the child is born. Further ultrasound testing, once the fetus has been diagnosed with CDH, can help to determine the severity of the disorder and any additional problems that may be present. Chest x-Ray in CHD is frequently abnormal but not always diagnostic. A "bubbly" hemithorax with obliteration of the costophrenic sinus, deviation of the mediastinum to the contralateral side, abnormal position of the nasogastric tube, and an airless abdomen are the most common findings on chest and abdominal X-ray(28,29). Sometimes differential diagnosis with aerated congenital cystic adenomatoid malformation (CCAM) is equivocal. In these cases US can help in further diagnosis: the presence of mobile gastrointestinal structures and spleen, in severe cases parts of the liver confirms the hernia(28,29,30). Diaphragmatic eventration is usually the result of congenital paralysis, aplasia, or atrophy of the diaphragmatic muscle, and is seen on chest X-ray as an abnormally elevated diaphragm, partly or totally(31). Left-sided eventrations are more likely to be complete. The severity of presentation depends on the location and whether it involves a complete leaflet(31). Rarely, diaphragmatic eventration is bilateral and can lead to respiratory distress in infants, especially when associated with infection.

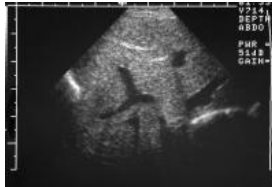Ultrasound examination. The majority of infants with CDH are now diagnosed prenatally by ultrasound examination, which demonstrates herniated viscera with or without liver in the fetal thorax, absence of the normal position of the stomach bubble below the diaphragm, and mediastinal shift [Steger et al 2003, Tonks et al 2004]. Although not specific for CDH, polyhydramnios is often detected [Witters et al 2001]. Calculation of the lung-to-head ratio (LHR) may be of prognostic value; however, centers have reported mixed results in the utility of this measure for predicting fetal outcome [Lipshutz et al 1997, Laudy et al 2003, Heling et al 2005]. Specifically, the "size" of the right lung is compared to the head circumference; a high ratio (>1.4) indicates good lung size and predicts a good outcome; a low ratio (variously cited as <1.0 or <0.6) indicates small lung size and predicts a poor outcome [Lipshutz et al 1997, Laudy et al 2003]. Some of the limitations of use of the LHR for predicting outcome:

- Inter-observer variability in determining the LHR is considerable.
- An indeterminate ratio between 1.0 and 1.4 is found in most fetuses.
- Prognostic accuracy is reduced for the following: right-sided CDH, additional birth defects, and/or diagnosis before 24 weeks gestation or after 26 weeks gestation.

Note: Gestational age is expressed as menstrual weeks calculated either from the first day of the last normal menstrual period or by ultrasound measurements.

Color flow Doppler can be used to:

- Demonstrate abnormal positioning of the umbilical and portal veins, which are indicative of liver herniation;
- Identify right-sided hernias, which can be difficult to detect on ultrasound examination because of the similar echogenicity of lung and liver.



Ultrasonogram of a right-sided congenital diaphragmatic hernia shows the liver herniating through the defect.

## 8. References

- [1] Saifuddin A, Arthur RJ. Congenital diaphragmatic hernia--a review of pre- and postoperative chest radiology. *Clin Radiol.* Feb 1993;47(2):104-10.
- [2] Gale ME. Bochdalek hernia: prevalence and CT characteristics. *Radiology.* Aug 1985;156(2):449-52.
- [3] Mullins ME, Stein J, Saini SS, Mueller PR. Prevalence of incidental Bochdalek's hernia in a large adult population. *AJR Am J Roentgenol.* Aug 2001;177(2):363-6.
- [4] Reed JO, Lang EF. Diaphragmatic hernia in infancy. *Am J Roentgenol Radium TherNucl Med.* Sep 1959;82:437-49.
- [5] Mitanchez D. [Antenatal treatment of congenital diaphragmatic hernia: An update.]. *Arch Pediatr.* Jun 27 2008;
- [6] Pelizzo G, Lembo MA, Franchella A. Gastric volvulus associated with congenital diaphragmatic hernia, wandering spleen, and intrathoracic left kidney: CT findings. *Abdom Imaging.* May-Jun 2001;26(3):306-8.
- [7] Swischuk LE. *Imaging of the Newborn, Infant and Young Child. 4th ed.* Lippincott Williams & Wilkins;1997:68-72, 398-99, 412-23.
- [8] Tibboel D, Gaag AV. Etiologic and genetic factors in congenital diaphragmatic hernia. *ClinPerinatol.* Dec 1996;23(4):689-99.
- [9] Wilcox DT, Irish MS, Holm BA, Glick PL. Prenatal diagnosis of congenital diaphragmatic hernia with predictors of mortality. *ClinPerinatol.* Dec 1996;23(4):701-9.
- [10] Cannie M, Jani J, De Keyzer F, Van Kerkhove F, Meersschaert J, Lewi L, et al. Magnetic resonance imaging of the fetal lung: a pictorial essay. *EurRadiol.* Jul 2008;18(7):1364-74.

- [11] Shin SM, Mulligan SA, Baxley WA, HO KJ. Bochdalek Hernia of Diaphragm in the Adult: Diagnosis by Computed Tomography. *Chest* 1987;92:1098-1101
- [12] Diaphragmatic Rupture Due to Blunt Trauma: Sensitivity of Plain Chest Radiographs. *AJR* 1991;156:51-57
- [13] Sergio G Golombek MD, FAAP *Perinatology* (2002) 22, 242-246 DOI: 10.1038/sj/jp/7210701 The History of Congenital Diaphragmatic Hernia from 1850s to the Present.
- [14] Keith A. On the origin and nature of hernia. *Br J Surg* 1924; 11: 455..
- [15] Prenatal prediction of neonatal morbidity in survivors with congenital diaphragmatic hernia: a multicenter study. *Ultrasound Obstet Gynecol.* 2008 Oct 9. PMID: 18844275
- [16] Masturzo B, Kalache KD, Cockell A, Pierro A, Rodeck CH. Prenatal diagnosis of an ectopic intrathoracic kidney in right-sided congenital diaphragmatic hernia using color Doppler ultrasonography. *Ultrasound Obstet Gynecol.* 2001;18:173-4. [PubMed: 11530002]
- [17] Gorincour G, Bouvenot J, Mourot MG, Sonigo P, Chaumoitre K, Garel C, Guibaud L, Rypens F, Avni F, Cassart M, Maugey-Laulom B, Bourliere-Najean B, Brunelle F, Durand C, Eurin D. Prenatal prognosis of congenital diaphragmatic hernia using magnetic resonance imaging measurement of fetal lung volume. *Ultrasound Obstet Gynecol.* 2005;26:738-44. [PubMed: 16273597]
- [18] Gross RE. Congenital hernia of the diaphragm. *Am J Dis Child.* 1946;71:579-592.
- [19] Areechon W, Reid L. Hypoplasia of the lung associated with congenital diaphragmatic hernia. *Br Med J.* 1963;i:230-3.
- [20] Brant WE: Pulmonary cavities. In Brant WE, Helms CA (eds): *Fundamentals of Diagnostic Radiology* 2<sup>nd</sup> ed. Baltimore, Lippincott Williams & Wilkins 2007 pp 1240-41
- [21] Kelly DR, Grant EG, Zeman RK, Choyke PL, Bolan JC, Warsof SL. In utero diagnosis of congenital diaphragmatic hernia by CT amniography *J Comput Assist Tomogr* 1986;10:500-502
- [22] Doyle NM, Lally KP; The CDH Study Group and advances in the clinical care of the patient with congenital diaphragmatic hernia. *Semin Perinatol.* 2004 Jun;28(3):174-84.
- [23] *Thomas C. Weiss* - Published: 2009-01-28
- [24] Comstock CH: The antenatal diagnosis of diaphragmatic anomalies, *J Ultrasound Med* 5:391, 1986
- [25] Barss VA, Benacerraf BR, Frigoletto FD: Antenatal sonographic diagnosis of fetal gastrointestinal malformations. *Pediatrics* 76:445, 1985
- [26] Benacerraf BR, Greene MF: Congenital diaphragmatic hernia: US diagnosis prior to 22 weeks gestation. *Radiology* 158:809, 1986
- [27] Chinn DH, Filly RA, Callen PW, et al: Congenital diaphragmatic hernia diagnosed prenatally by ultrasound *Radiology* 148:119, 1983
- [28] Gibson AT, Steiner GM (1997) Imaging of the neonatal chest. *Clin Radiol* 52:172-186
- [29] Alford BA, McIlhenny J, Jones JE, Sutton CL, Silen M, Rodgers BM, McKinney CD (1993) Asymmetric radiographic findings in the pediatric chest: approach to early diagnosis. *Radiographics* 13:77-93
- [30] Rencken I, Patton WL, Brasch RC (1998) Airway obstruction in pediatric patients. *Radiol Clin North Am* 36:175-187

- [31] Singh S, Behnde MS, Kinnane GM, (2001) Delayed presentations of congenital diaphragmatic hernia. *PediatrEmerg Care* 17:269-271
- [32] Schafermeyer R(1993) *Pediatric trauma. Emerg Med Clin North Am* 11:187-251
- [33] Bonham Carter RE, Waterston DJ, Aberdeen E: Hernia and eventration of the diaphragm in childhood. *Lancet* 1:656,1962
- [34] Fliegel CP, Kaufmann HJ; Problems caused my pneumothorax in congenital diaphragmatic hernia. *Ann Radiol* 15;159,1972
- [35] Berdon WE, Baker DH, Amoury R: The role of pulmonary hyoplasia in the prognosis of newborn infants with diaphragmatic hernia and eventration *AJR* 103:413,1968
- [36] Putman CH and Ravin C. *Textbook of diagnostic Imaging 2<sup>nd</sup> EdsCh 41Chest Wall and hemidiaphragm* 1994
- [37] Lipshutz GS, Albanese CT, Feldstein VA, Jennings RW, Housley HT, Beech R, Farrell JA, Harrison MR. Prospective analysis of lung-to-head ratio predicts survival for patients with prenatally diagnosed congenital diaphragmatic hernia. *J Pediatr Surg.* 1997;32:1634–6. [PubMed: 9396544]
- [38] Laudy JA, Van Gucht M, Van Dooren MF, Wladimiroff JW, Tibboel D. Congenital diaphragmatic hernia: an evaluation of the prognostic value of the lung-to-head ratio and other prenatal parameters. *PrenatDiagn.* 2003;23:634–9. [PubMed: 12913869]
- [39] Stege G, Fenton A, Jaffray B. Nihilism in the 1990s: the true mortality of congenital diaphragmatic hernia. *Pediatrics.* 2003;112:532–5. [PubMed: 12949279]
- [40] Tonks A, Wyldes M, Somerset DA, Dent K, Abhyankar A, Bagchi I, Lander A, Roberts E, Kilby MD. Congenital malformations of the diaphragm: findings of the West Midlands Congenital Anomaly Register 1995 to 2000. *PrenatDiagn.* 2004;24:596–604. [PubMed: 15305345]
- [41] Witters I, Legius E, Moerman P, Deprest J, Van Schoubroeck D, Timmerman D, Van Assche FA, Fryns JP. Associated malformations and chromosomal anomalies in 42 cases of prenatally diagnosed diaphragmatic hernia. *Am J Med Genet.* 2001;103:278–82. [PubMed: 11746006]
- [42] Heling KS, Wauer RR, Hammer H, Bollmann R, Chaoui R. Reliability of the lung-to-head ratio in predicting outcome and neonatal ventilation parameters in fetuses with congenital diaphragmatic hernia. *Ultrasound Obstet Gynecol.* 2005;25:112–8. [PubMed: 15660446]
- [43] Hedrick HL, Crombleholme TM, Flake AW, Nance ML, von Allmen D, Howell LJ, Johnson MP, Wilson RD, Adzick NS. Right congenital diaphragmatic hernia: Prenatal assessment and outcome. *J Pediatr Surg.* 2004;39:319–23. [PubMed:15017545]
- [44] Gorincour G, Bouvenot J, Mourot MG, Sonigo P, Chaumoitre K, Garel C, Guibaud L, Rypens F, Avni F, Cassart M, Maugey-Laulom B, Bourliere-Najean B, Brunelle F, Durand C, Eurin D. Prenatal prognosis of congenital diaphragmatic hernia using magnetic resonance imaging measurement of fetal lung volume. *Ultrasound Obstet Gynecol.* 2005;26:738–44. [PubMed]

© 2012 The Author(s). Licensee IntechOpen. This is an open access article distributed under the terms of the [Creative Commons Attribution 3.0 License](#), which permits unrestricted use, distribution, and reproduction in any medium, provided the original work is properly cited.