

---

# Cardiac Magnetic Resonance T1 Mapping in Cardiomyopathies

---

Christian R. Hamilton-Craig, Mark W. Strudwick and  
Graham J. Galloway

Additional information is available at the end of the chapter

<http://dx.doi.org/10.5772/65327>

---

## Abstract

Cardiac magnetic resonance (CMR) imaging has been widely used to assess myocardial perfusion and scar and is the noninvasive reference standard for identification of focal myocardial fibrosis. However, the late gadolinium enhancement (LGE) technique is limited in its accuracy for absolute quantification and assessment of diffuse myocardial fibrosis by technical and pathophysiological features. CMR relaxometry, incorporating T1 mapping, has emerged as an accurate, reproducible, highly sensitive, and quantitative technique for the assessment of diffuse myocardial fibrosis in a number of disease states. We comprehensively review the physics behind CMR relaxometry, the evidence base, and the clinical applications of this emerging technique.

**Keywords:** cardiac magnetic resonance, T1 mapping, myocardial fibrosis, cardiomyopathy

---

## 1. Introduction

Cardiac Magnetic Resonance (CMR) imaging has been used widely to assess myocardial perfusion and scar [1–5]. It is the noninvasive reference standard for left and right ventricular quantitation, as well as the assessment and quantitation of focal myocardial fibrosis (after infarction or due to other causes of cellular injury). Myocardial necrosis causes high signal on late gadolinium enhancement (LGE) inversion recovery T1-weighted images with excellent signal-noise ratios, and this has become the reference standard for noninvasive scar imaging in cardiomyopathies of various causes [1–4]. However, LGE is limited in its ability to assess and quantitate diffuse (nonfocal) myocardial injury and fibrosis. LGE is

affected by inconsistencies in acquisition parameters, such as choice inversion time, and in postprocessing when signal intensity thresholds may be arbitrarily applied to distinguish normal myocardium from fibrotic tissue [6, 7]. Moreover, the critical issue with LGE is that signal intensity is expressed on an arbitrary scale (*relative* signal intensity compared with “nulled” normal myocardium). Detection of myocardial fibrosis using *relative* differences between scar and normal myocardium tissue is therefore *qualitative*. Thus, in nonischemic cardiomyopathies, such as hypertension or diabetes, LGE CMR is unable to detect signal differential where the collagen deposition is diffuse and widespread throughout the myocardium [8].

## 2. CMR relaxometry

CMR is an evolving technique, providing valuable and comprehensive data on the anatomy and functional integrity of both the heart and coronary blood vessels. Currently, CMR is performed at magnetic field strengths of 1.5 or 3 T.

## 3. T1 mapping with Look–Locker

The initial technique to measure spin–lattice T1 relaxation time values was the eponymously named “Look–Locker” sequence (also known as “TI scout”). It has been widely used to estimate the optimal inversion time for assessment of myocardial LGE [9, 10]. It was originally proposed by Look and Locker in 1968 and analyzed more fully in 1970 [11] and consists of an initial inversion pulse, followed by a train of pulses with a constant, limited flip angle (7–15°).

The development of LL technique is summarized in **Table 1**.

The LL sequence has been widely applied in CMR due to its fast acquisition with minimal breath-hold requirements. The LL sequence has been used to measure T1 values in patients with myocardial fibrosis [9]. However, it suffers from significant limitations: low flip angle RF pulse exciting the magnetization and the two RR intervals in the LL sequence are not sufficient for the magnetization to return to equilibrium. This causes *underestimation* of true T1 values using LL. Furthermore, the LL T1 images with different TIs are acquired at different cardiac phases. Therefore, images are “*cine*” with cardiac motion effect, which requires tedious manual tracking of the myocardial borders for each phase, a labour-intensive and error-prone process, which is challenging in clinical practice. The drawing of regions of interest “ROI” in myocardial segments requires adjusting for cardiac motion, which results in including blood pool (partial volume averaging) and artificially increasing the measured T1 [12].

To address these shortcomings, several myocardial T1 mapping sequences have been created, including modified Look-Locker inversion (MOLLI) recovery.

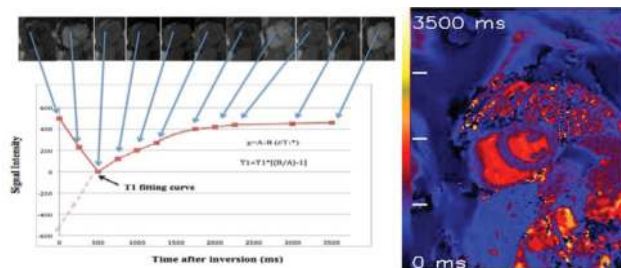
Author	Year	Summary of research findings
Look & Locker	1968	Initial proposition of Look–Locker technique
Look & Locker	1970	Fully analyzed NMR pulse sequence to measure a spin–lattice T1 relaxation time
Kaptein et al.	1976	LL was co-opted to quickly sample the recovery after a preparation pulse during the recovery period
Gerumann	1987	T1 by Multiple Readout Pulses (TOMROP) was proposed through which the multiple samples of a particular recovery after RF preparation each correspond to a separate image
Hinson and Sobol	1988	LL method was applied without preparation pulse
Crawley and Henkelman	1988	Compared (LL, saturation recovery, inversion recovery, and stimulated echo) and concluded that LL was almost as efficient
Brix et al.	1990	TMPROP was used with 32 gradient echoes in a total acquisition time of 4 min
Kay	1991	LL single-shot IR method has been optimized and refined
Gowland	1992	LL single-shot IR method has been optimized and refined
Been et al.	1988	Improved RF preparation pulses
Gowland et al.	1989	Improved RF preparation pulses
Ordidge et al.	1990	Echo-planar imaging (EPI) was incorporated into the inversion recovery LL-based method
Gowland and Mansfield	1993	EPI was applied in vivo in less than 3 s
Freeman et al.	1998	An entire image was acquired at each point on a single recovery of longitudinal magnetization after a saturation pulse
Karlsson and Nordell	1999	EPI- with LL method has found application in pharmacokinetic modeling in the head
Daniel et al.	2004	Modified Look–Locker inversion recovery is proposed to overcome the limitations of the conventional LL approach for cardiac applications
Daniel et al.	2006	Studied the single breath-hold myocardial MR T1 mapping with MOLLI technique with high spatial resolution at 1.5 T MR-reproducibility study
Daniel et al.	2007	Investigated optimization and validation of a fully integrated pulse sequence for (MOLLI) T1 mapping of the heart
Iles et al.	2008	Evaluation of diffuse myocardial fibrosis in heart failure with cardiac magnetic resonance contrast-enhanced T1 mapping

**Table 1.** Summary of development of Look–Locker technique.

#### 4. T1 mapping with Modified Look-Locker Inversion “MOLLI” recovery

Currently, the most evaluated sequence for myocardium T1 mapping is a modified Look-Locker inversion recovery (MOLLI) sequence [13, 14]. The T1 mapping identifies a significant variation between normal and abnormal myocardium. It demonstrates the myocardial fibrosis among different myocardial disorders include ischemia [15], acute/chronic infraction [16], amyloidosis [17], diabetic [18], dilated and hypertrophic cardiomyopathy [19], and heart failure [8].

MOLLI is a CMR pulse sequence that is used for accurate T1 mapping of myocardium with high spatial resolution. MOLLI is an ECG-gated pulse sequence scheme and uses three prepared Look-Locker experiments consecutively within one breath-hold over 17 heartbeats to reconstruct 11 images with different inversion times. Three successive ECG-triggered LL experiments (LL1, LL2, and LL3) are carried out with three, three, and five single-shot readouts, respectively, at end diastole of consecutive heartbeats to sample the recovery of longitudinal magnetization after the inversion pulse. MOLLI pulse sequence scheme is illustrated in **Figure 1**. T1 maps can be generated any time before or after contrast agent (e.g., gadolinium) administration [12].



**Figure 1. T1 map of a healthy volunteer:** Using 17 heartbeats to reconstruct 11 images with different inversion times at end of diastole phase. By merging these images into one data set, T1 values are computed for every pixel with three parameters curve fitting. A reconstructed T1 map with parametric color scale is produced for these pixel values and the segmental and global T1 times can be estimated.

The MOLLI sequence has been described, optimized, tested, and retested in phantoms and in large cohorts of healthy volunteers [12, 14] as well as being applied in cardiomyopathies [8, 15, 17, 19, 20]. In addition, the T1 mapping with MOLLI has been validated against histopathology for assessment of myocardial fibrosis. It demonstrated that the precontrast “native T1” has a linear correlation with the percentage of myocardial fibrosis as measured histologically on invasive myocardial biopsy. T1 times postcontrast administration (10–15 min) had an inverse linear relationship with collagen content in myocardial fibrosis subjects [8, 21, 22].

- Precontrast “Native” T1 = predominant signal from *myocytes* (replacement fibrosis or intracellular accumulation, e.g., Fabry disease)
- Postcontrast T1 = predominant signal from *interstitial* space (interstitial fibrosis)

T1 mapping can be generated for different segments of the myocardium (base, mid-cavity, and apex) within a single breath-hold of about 15–20 s. However, the apex T1 values with MOLLI are slightly higher than basal and mid-cavity. The increasing in T1 values may be caused by partial volume effect and some degree of overestimation effect in apical level of left ventricle [23–25].

T1 mapping with MOLLI has a greater reproducibility, accuracy, and an excellent overall inter- and intra-observer agreement over a wide range of TIs as compared with the traditional LL sequence [13, 14].

However, the T1 mapping with MOLLI sequence is sensitive to extremes of heart rate (bradycardia or tachycardia) [14] leading to a slight underestimation of T1 values. This may be corrected though *heart rate correction* by changing the timing of the readouts with respect to the inversion pulses at different heart rates.

Moreover, MOLLI is also limited by long breath-hold for about 15–20 s (17 heartbeats to acquire the final T1 maps). This may be difficult for elderly and pulmonary compromised patients and generates respiratory and motion artifacts [26]. Modern in-line processing provides registration tools to reduce motion artifacts before the computation of final T1 maps (motion-corrected or “MoCo MOLLI”) [27]. A shortened Modified Look-Locker inversion recovery (*shMOLLI*) with shorter breath-holds has been validated and recently applied for cardiomyopathies [28, 29].

## 5. MRI field strength

At 1.5 T, the pre- and postcontrast (10 mins) T1 times of normal myocardium are  $980 \pm 53$  ms and  $470 \pm 26$  ms, respectively [14]. Precontrast T1 values of myocardial fibrosis (Infarction scar) are significantly longer than those of normal myocardium ( $1060 \pm 61$  ms vs.  $987 \pm 34$  ms) [20]. The postcontrast T1 times (10 mins) were significantly shorter in chronic infarct scar compared with normal myocardium at 0.15 mmol/kg ( $390 \pm 20$  ms vs.  $483 \pm 23$  ms, respectively) [20].

**3 T:** T1 mapping at higher magnetic field (3 T) has been reported in a few studies of interstitial myocardial fibrosis, but minimal data exist for ultra-high field at 7 T. 3 T data are similar to 1.5 T, the precontrast T1 was longer, and postcontrast T1 was shorter in myocardial fibrosis patients compared with normal myocardium. Puntmann et al. [30] reported higher precontrast T1 values for hypertrophic and nonischemic dilated cardiomyopathies at 3 T compared with controls (Hypertrophic  $1.254 \pm 43$  ms, and nonischemic dilated cardiomyopathy  $1.239 \pm 57$  ms vs. healthy  $1.070 \pm 55$  ms). Also, the postcontrast T1 values (10 mins) at 3 T were shorter in hypertrophic and dilated cardiomyopathies compared with healthy (hypertrophic:  $307 \pm 47$  ms, dilated cardiomyopathies:  $296 \pm 43$  ms vs. controls:  $402 \pm 58$  ms) [30].

There are studies published for normal and diffuse myocardial fibrosis of myocardium T1 values, as described comprehensively in **Tables 2** and **3**:

First author (Ref.#)	Sample size	T1/T2* mapping sequence	Result of T1 or T2* mapping (ms)
Wacker et al. [31]	5	srTFL, segmented T2* gradient echo pulse	T1 = 1219 ± 72 ms T2* = 35 ± 3 ms
Sebastian et al. [32]	12	LL	T1 = 1033 ± 126 ms T2* = NA
Messroghli et al. [33]	15	MOLLI	T1 = 980 ± 53 ms T2* = NA
Messroghli et al. [34]	20	MOLLI	T1 = 939 ± 63 ms T2* = NA
Sparrow et al. [35]	15	MOLLI	T1 = 980 ± 53 ms T2* = NA
Iles et al. [8]	20	VAST	T1 = 975 ± 62 ms T2* = NA
Li et al. [36]	13	2 echo times GRE	T1 = NA T2* = 33 ± 6.5 ms
Reeder et al. [37]	5	Multi echo GRE	T1 = NA T2* = 38 ± 6 ms
Anderson et al. [38]	15	Multi echo GRE	T1 = NA T2* = 52 ± 16 ms
Positano et al. [39]	15	Multi echo GRE	T1 = NA T2* = 38 ± 9.2 ms in endocardial sectors, and 33.1 ± 8.4 ms in epicardial sectors
Messroghli et al. [40]	20	Multi echo GRE	T1 = NA T2* = 27.9 ± 3.4 ms in anteroseptal and 23.1 ± 5.2 ms in inferolateral
Piechnik et al. [28]	342	shMOLLI	T1 = 962 ± 25 ms T2* = NA Heart rate only physiologic factors effect on myocardial T1 values

Note: NA, not applicable; srTFL, saturation recovery turboFLASH; LL, Look-Locker; MOLLI, modified Look-Locker inversion recovery sequence; VAST, inversion recovery gradient echo sequence with Variable Sampling of the k-space in Time; GRE, gradient pulse sequence; shMOLLI, short modified Look-Locker sequence.

**Table 2.** Healthy clinical studies using T1 and T2\*.

First author (Ref. #)	Cardiac disease category	Patient sample size	T1 mapping method	Summary of findings
Franck Thuny	Systemic sclerosis	37	MOLLI	LV diastolic dysfunction had a shorter 15 min postcontrast T1 time (ms) than those with a normal diastolic function ( $431 \pm 7$ vs. $464 \pm 8$ , $p = 0.01$ ).
Helene Thibault	Type II diabetic patient	24	MOLLI	Mean myocardial T1 relaxation time was significantly shorter in diabetic patients than in volunteers both at 5 ( $312 \pm 5$ vs. $361 \pm 6$ milliseconds, respectively, $p < 0.001$ ) and 15 min ( $405 \pm 6$ vs. $456 \pm 5$ milliseconds, respectively, $p < 0.001$ ) after gadolinium injection.
Andris H Ellims	Hypertrophy cardiomyopathy	51	VAST	Postcontrast myocardial T1 time was significantly shorter in patients with HCM compared with controls, consistent with diffuse myocardial fibrosis ( $498 \pm 80$ ms vs. $561 \pm 47$ ms, $p < 0.001$ ).
Beatrice A Marzluf	Patients with NH <sub>2</sub> -terminal portion of the precursor of brain natriuretic peptide (NT-proBNP)	37	N/A	In patients with NT-proBNP levels >400 pg/ml mean T1 was significantly shorter than in patients with NT-proBNP <400 pg/ml ( $374.6 \pm 51.1$ vs. $404.6 \pm 34.4$ ms, $p = 0.042$ ) and controls ( $509.4 \pm 46.5$ ms, $p < 0.001$ ).
Christopher T Sibley	Nonischemic cardiomyopathy	73	LL	47 patients had a focal myocardial scar and 26 without scar tissue. The midwall circumferential strain (Ecc) was reduced ( $-13.0 \pm 5.4\%$ ) and mean T1 time was $478 \pm 70$ ms in patients with no scar tissue.
Jellis et al. [18]	Type II diabetic patients	67	VAST	Subjects has a shorter post contrast T1 = $434 \pm 20$ ms. Postcontrast T1 was associated with Echocardiography diastolic dysfunction (Em $r = 0.28$ , $p = 0.020$ ; E/Em $r = -0.24$ , $p = 0.049$ ).
Messroghli et al. [13]	Acute myocardial infarction	8	Inversion recovery (IR)-prepared fast gradient echo sequence	T1 precontrast value of the infarcted myocardium was significantly prolonged compared with noninfarcted normal myocardium ( $+18 \pm 7\%$ ). T1 10-min postcontrast value of the infarct was significantly reduced compared with normal myocardium ( $-27 \pm 4\%$ ).
Messroghli et al. [20]	Acute and chronic myocardial infarction	24	MOLLI	In chronic MI, the precontrast T1 relaxation time of hyper-enhanced areas was higher than T1 of remote areas ( $1060 \pm 61$ vs. $987 \pm 34$ ms, $p < 0.0001$ ). In acute MI, the precontrast T1 value of hyper-enhanced areas was higher

First author (Ref. #)	Cardiac disease category	Patient sample size	T1 mapping method	Summary of findings
				than remote areas ( $1197 \pm 76$ vs. $1011 \pm 66$ ). The hyper-enhanced in acute is higher than chronic infarction.
Flacke and Sebastian [32]	Acute and chronic myocardial infarction	10	LL	Mean T1 values of the normal myocardium postcontrast was $536 \pm 66$ ms, chronically infarcted precontrast and postcontrast was $1000 \pm 67$ ms and $408 \pm 43$ ms, respectively.
Sparrow et al. [35]	Myocardial Fibrosis in Chronic Aortic Regurgitation	8	Molli	There is a significant difference in segmental averaged T1 relaxation between in abnormal wall motion vs. Normal control segments in 10, 15, and 20 min after administration Gd: (510 vs. 476 ms, 532 vs 501 ms, and 560 vs. 516 ms, respectively).
Iles et al. [8]	Chronic heart failure	25	VAST	Postcontrast myocardial T1 times were shorter in heart failure subjects than in controls ( $383 \pm 17$ ms vs. $564 \pm 23$ ms) even when excluding areas of regional fibrosis. T1 15-min postcontrast values correlated significantly with collagen volume fraction on myocardial biopsies ( $R = -0.7$ ).
Maceira 2005	Cardiac amyloidosis	22	Segmented inversion recovery sequence	Subendocardial T1 in amyloid patients was shorter than in controls (at 4 min: $427 \pm 73$ vs. $579 \pm 75$ ms; $p < 0.01$ ).

**Table 3.** Clinical studies using T1 mapping for myocardial diffuse fibrosis in clinical patients.

## 6. Limitations of T1 mapping

Challenges remain with myocardial relaxometry for T1 mapping. These include technical challenges such as variations of T1 times at different field strength and across different vendors, and the rapidity in growth of pulse sequences being released as product and as works-in-progress (WIP), calling into question both the inherent accuracy and the level agreement between these techniques. Furthermore, the variations in T1 relaxometry values with different contrast doses and image timing require further investigation to establish the test-retest and intersite reproducibility of this technique. Next, the challenges to application of T1 mapping to clinical practice include establishment of robust normal ranges in large cohorts across multiple ethnic groups and the observation that T1 mapping appears to be a highly sensitive technique, with the ability to discriminate healthy normal myocardium and identify very early changes in substrate. However, this technique lacks specificity; a wide variety of conditions prolong native T1 and/or shorten postcontrast myocardial T1. Therefore, further clinical data are required in order to establish the use of these parameters in relation to disease (e.g., early



detection of target organ damage in systemic conditions such as hypertension or diabetes), to inform treatment decisions, and their ability to predict or alter clinical outcomes.

## 7. Conclusions

Myocardial T1 mapping using quantitative relaxometry is an emerging and important tool in the assessment of global myocardial fibrosis. It is a highly sensitive marker of disease, but is not specific, with changes in myocardial T1 occurring in many different conditions. Nevertheless, the high sensitivity and excellent reproducibility of the technique offer a tool for the early detection of myocardial damage, over-and-above techniques such as the CMR LGE technique and other modalities such as speckle tracking echocardiography, pulse wave velocity, and tissue tagging. Native T1 mapping is proving to be a robust indicator of early myocardial disease in many conditions, and normal ranges and guidelines for postprocessing have been published by the Society of Cardiovascular Magnetic Resonance [41]. Myocardial T1 mapping is a rapidly evolving technique, now with longitudinal prognostic data emerging, and normal ranges established at 1.5 and 3.0 T in healthy humans and in aging persons. Further questions remain as to the standardization of pulse sequences across field strengths and between vendors, the affect of contrast type, dose and timing, the postprocessing software, and the interpretation of T1 mapping results to inform clinical practice.

## Acknowledgements

The author acknowledges the contribution of Dr Qurain Alshammari's to the background work.

## Abbreviations

CMR	cardiac magnetic resonance
LL	Look-Locker
LGE	late gadolinium enhancement
LV	left ventricle
MOLLI	modified Look-Locker inversion recovery
MRI	magnetic resonance imaging
ROI	regions of interest
RV	right ventricle
<i>sh</i> MOLLI	shortened modified Look-Locker inversion recovery

## Author details

Christian R. Hamilton-Craig<sup>1,2\*</sup>, Mark W. Strudwick<sup>3</sup> and Graham J. Galloway<sup>1,4</sup>

\*Address all correspondence to: c.hamiltoncraig@uq.edu.au

1 Centre for Advanced Imaging, University of Queensland, Brisbane, Australia

2 Department of Radiology, University of Washington, Seattle, WA, USA

3 Medical Imaging and Radiation Science, Monash University, Australia

4 Translational Research Institute, Brisbane, Australia

## References

- [1] Croisille P, Revel D, Saeed M. Contrast agents and cardiac MR imaging of myocardial ischemia: from bench to bedside. *European Radiology* 2006;16:1951–1963.
- [2] Judd RM, Atalay MK, Rottman GA, Zerhouni EA. Effects of myocardial water exchange on T1 enhancement during Bolus administration of MR contrast agents. *Magnetic Resonance in Medicine* 1995;33:215–223.
- [3] Lima JAC. Myocardial viability assessment by contrast-enhanced magnetic resonance imaging. *Journal of the American College of Cardiology* 2003;42:902–904.
- [4] Kim RJ, Chen E-L, Lima JoAC, Judd RM. Myocardial Gd-DTPA kinetics determine MRI contrast enhancement and reflect the extent and severity of myocardial injury after acute reperfused infarction. *Circulation* 1996;94:3318–3326.
- [5] Mahrholdt H, Wagner A, Judd RM, Sechtem U, Kim RJ. Delayed enhancement cardiovascular magnetic resonance assessment of non-ischaemic cardiomyopathies. *European Heart Journal* 2005;26:1461–1474.
- [6] Simonetti OP, Kim RJ, Fieno DS et al. An improved MR imaging technique for the visualization of myocardial infarction. *Radiology* 2001;218:215–223.
- [7] Spiewak M, Malek LA, Misko J et al. Comparison of different quantification methods of late gadolinium enhancement in patients with hypertrophic cardiomyopathy. *European Journal of Radiology* 2010;74:e149–e153.
- [8] Iles L, Pfluger H, Phrommintikul A et al. Evaluation of diffuse myocardial fibrosis in heart failure with cardiac magnetic resonance contrast-enhanced T1 mapping. *Journal of the American College of Cardiology* 2008;52:1574–1580.

- [9] Amano Y, Takayama M, Kumita S. Contrast-enhanced myocardial T1-weighted scout (Look-Locker) imaging for the detection of myocardial damages in hypertrophic cardiomyopathy. *Journal of Magnetic Resonance Imaging* 2009;30:778–784.
- [10] Karlsson M, Nordell B. Analysis of the Look-Locker T1 mapping sequence in dynamic contrast uptake studies: simulation and in vivo validation. *Magnetic Resonance Imaging* 2000;18:947–954.
- [11] Look DC, Locker DR. Time saving in measurement of NMR and EPR relaxation times. *The Review of scientific Instruments* 1970;41:250–251.
- [12] Messroghli DR, Radjenovic A, Kozerke S, Higgins DM, Sivananthan MU, Ridgway JP. Modified Look-Locker inversion recovery (MOLLI) for high-resolution T1 mapping of the heart. *Magnetic Resonance in Medicine* 2004;52:141–146.
- [13] Messroghli DR, Niendorf T, Schulz-Menger J, Dietz R, G. FM. T1 Mapping in patients with acute myocardial infarction. *Journal of Cardiovascular Magnetic Resonance* 2003;5:353–359.
- [14] Messroghli DR, Plein S, Higgins DM et al. Human myocardium: single-breath-hold MR T1 mapping with high spatial resolution—reproducibility study. *Radiology* 2006;238:1004–1012.
- [15] Goldfarb JW, Arnold S, Han J. Recent Myocardial infarction: assessment with unenhanced T1-weighted MR imaging. *Radiology* 2007;245:245–250.
- [16] Messroghli DR, Greiser A, Fröhlich M, Dietz R, Schulz-Menger J. Optimization and validation of a fully-integrated pulse sequence for modified look-locker inversion-recovery (MOLLI) T1 mapping of the heart. *Journal of Magnetic Resonance Imaging* 2007;26:1081–1086.
- [17] Karamitsos TD, Piechnik SK, Banyersad SM et al. Noncontrast T1 mapping for the diagnosis of cardiac amyloidosis. *Journal of American College of Cardiology: Cardiovascular Imaging* 2013;6:488–497.
- [18] Jellis C, Wright J, Kennedy D et al. Association of imaging markers of myocardial fibrosis with metabolic and functional disturbances in early diabetic cardiomyopathy. *Circulation: Cardiovascular Imaging* 2011;4:693–702.
- [19] Dass S, Suttie JJ, Piechnik SK et al. Myocardial tissue characterization using magnetic resonance non-contrast T1 mapping in hypertrophic and dilated cardiomyopathy. *Circulation: Cardiovascular Imaging* 2012.
- [20] Messroghli DR, Walters K, Plein S et al. Myocardial T1 mapping: application to patients with acute and chronic myocardial infarction. *Magnetic Resonance in Medicine* 2007;58:34–40.
- [21] Sibley CT, Noureldin RA, Gai N et al. T1 mapping in cardiomyopathy at cardiac MR: comparison with endomyocardial biopsy. *Radiology* 2012;256:724–732.

- [22] Bull S, White SK, Piechnik SK et al. Human non-contrast T1 values and correlation with histology in diffuse fibrosis. *Heart* 2013;99:923–927.
- [23] Lima JAC, Jeremy R, Guier W et al. Accurate systolic wall thickening by nuclear magnetic resonance imaging with tissue tagging: correlation with sonomicrometers in normal and ischemic myocardium. *Journal of the American College of Cardiology* 1993;21:1741–1751.
- [24] Forbat SM, Karwatowski SP, Gatehouse PD, Firmin DN, Longmore DB, Underwood SR. Rapid measurement of left ventricular mass by spin echo magnetic resonance imaging. *British Journal of Radiology* 1994;67:86–90.
- [25] Aurigemma G, Davidoff A, Silver K, Boehmer J, Pattison N. Left ventricular mass quantitation using single-phase cardiac magnetic resonance imaging. *The American Journal of Cardiology* 1992;70:259–262.
- [26] Solano JP, Gomes B, Higginson IJ. A comparison of symptom prevalence in far advanced cancer, AIDS, heart disease, chronic obstructive pulmonary disease and renal disease. *Journal of Pain and Symptom Management* 2006;31:58–69.
- [27] Messroghli DR, Rudolph A, Abdel-Aty H et al. An open-source software tool for the generation of relaxation time maps in magnetic resonance imaging. *BMC Medical Imaging* 2010:10–16.
- [28] Piechnik S, Ferreira V, Lewandowski A et al. Normal variation of magnetic resonance T1 relaxation times in the human population at 1.5 T using ShMOLLI. *Journal of Cardiovascular Magnetic Resonance* 2013;15:13.
- [29] Piechnik S, Ferreira V, Dall’Armellina E et al. Shortened Modified Look-Locker Inversion recovery (ShMOLLI) for clinical myocardial T1-mapping at 1.5 and 3 T within a 9 heartbeat breathhold. *Journal of Cardiovascular Magnetic Resonance* 2010;12:69.
- [30] Puntmann VO, Voigt T, Chen Z et al. Native T1 mapping in differentiation of normal myocardium from diffuse disease in hypertrophic and dilated cardiomyopathy. *JACC: Cardiovascular Imaging* 2013;6:475–484.
- [31] Wacker CM, Bock M, Hartlep AW et al. Changes in myocardial oxygenation and perfusion under pharmacological stress with dipyridamole: assessment using T\*2 and T1 measurements. *Magnetic Resonance in Medicine* 1999;41:686–695.
- [32] Sebastian J, Flacke SEF, and Christine H. Lorenz measurement of the Gadopentetate Dimeglumine partition coefficient in human myocardium in vivo: normal distribution and elevation in acute and chronic infarction. *Radiology* 2001;218:703–710.
- [33] Messroghli DR, Plein S, Higgins DM et al. Human myocardium: single-breath-hold MR T1 mapping with high spatial resolution-reproducibility study. *Radiology* 2006;238:1004–1012.
- [34] Messroghli DR, Greiser A, Frohlich M, Dietz R, Schulz-Menger J. Optimization and validation of a fully-integrated pulse sequence for modified look-locker inversion-

- recovery (MOLLI) T1 mapping of the heart. *Journal of Magnetic Resonance Imaging* 2007;26:1081–1086.
- [35] Sparrow P, Messroghli DR, Ridgway SP, Bainbridge G, Sivanthan MU. Myocardial T1 mapping for detection of left ventricular myocardial fibrosis in chronic aortic regurgitation: pilot study. *American Journal of Roentgenology* 2006;187:630–635.
- [36] Li D, Dhawale P, Rubin PJ, Haacke EM, Gropler RJ. Myocardial signal response to dipyridamole and dobutamine: Demonstration of the BOLD effect using a double-echo gradient-echo sequence. *Magnetic Resonance in Medicine* 1996;36:16–20.
- [37] Reeder SB, Faranesh AZ, Boxerman JL, McVeigh ER. In vivo measurement of T2 star and field inhomogeneity maps in the human heart at 1.5 T. *Magnetic Resonance in Medicine* 1998;39:988–998.
- [38] Anderson LJ, Holden S, Davis B et al. Cardiovascular T2-star (T2\*) magnetic resonance for the early diagnosis of myocardial iron overload. *European Heart Journal* 2001;22:2171–2179.
- [39] Positano V, Pepe A, Santarelli MF, Scattini B, De Marchi D, et al. Standardized T2\* map of normal human heart in vivo to correct T2\* segmental artefacts. *NMR in Biomedicine* 2007;20:578–590.
- [40] Messroghli DR, Wassmuth R, Zagrosek A, Rudolph A, Schulz-Menger J. Assessment of myocardial T2\* from pixel-by-pixel maps on a clinical MR system. *Journal of Cardiovascular Magnetic Resonance* 2008;10(Suppl 1):A240.
- [41] Moon JC, Messroghli DR, Kellman P et al. Myocardial T1 mapping and extracellular volume quantification: a Society for Cardiovascular Magnetic Resonance (SCMR) and CMR Working Group of the European Society of Cardiology consensus statement. *Journal of Cardiovascular Magnetic Resonance* 2013;15.

