

Chapter

Factors of Cortical Plasticity in Brachial Plexus Injury

Jennifer Reinsch, Anna Zdunczyk, Tarik Alp Sargut, Maren Denker, Melina Engelhardt, Peter Vajkoczy, Thomas Picht and Nora Dengler

Abstract

Cortical plasticity is the brain's capability of decoding new information through growth and reorganization over our whole life span. It is the basis for good outcomes after reinnervation and for rehabilitation of adult and obstetric brachial plexus injury. Knowledge about cortical reorganization is crucial to reconstructive surgeons and physiotherapists that aim to give their patients a reasonable prognosis. This chapter intends to present and summarize the current literature on how to detect and quantify cortical plasticity and how research on factors that influence cortical plasticity, mainly in relation to peripheral nerve and more precise brachial plexus injury progresses. Peculiarities of adult and obstetric brachial plexus injuries and their treatment are given. We present techniques that visualize and quantify cortical plasticity with focus on functional imaging like fMRI and nTMS as well as molecular aspects. Future research is needed to understand mechanisms of how molecular changes on a synaptic level of a neuron influence the macroscopic plasticity, to improve rehabilitative resources, to understand the exact prognostic value of nTMS in brachial plexus injury and to investigate the therapeutic capability of rTMS.

Keywords: cortical plasticity, cortical reorganization, adult brachial plexus injury, obstetric brachial plexus injuries, nTMS, motor cortex, peripheral nerve lesion

1. Introduction

Cortical plasticity in general is the ability of neuronal tissue to adapt to changing requirements. It may either be a regular mechanism in physiological tissue, or it appears after a central or peripheral injury. After brachial plexus injury, for instance, the respective cortical area of the denervated peripheral nerves gets reorganized after a certain time. Neighboring cortical areas migrate in the direction of the newly formed "black whole", until they occupy the area.

This chapter aims to give insights on how cortical plasticity may be detected and quantified, why it is important for the outcome of patients with peripheral nerve injury and how this may impact outcome prediction and outcome modification in our patients.

Treatment of peripheral nerve injury and more precise brachial plexus injury includes rehabilitation as well as reconstructive surgery. Reconstructive surgery is

composed of the restoration of nerve function by nerve graft or nerve transfer or secondary reconstructive techniques that may include tendon or muscle transfers.

Nerve graft means to bridge the proximal and distal end of the affected peripheral nerve with a donor nerve.

Nerve transfer is a technique where a functional donor nerve keeps its proximal connection to the CNS and gets transferred on the affected nerve with its distal end.

Tendon transfer means the transfer of one functional tendon on a second tendon whose muscle is paralytic due to a spinal or peripheral nerve injury.

Muscle transfer is the removal of an autologous muscle and the subsequent implantation on another part of the body to improve functions after nerve injury, for example.

Static techniques offer some benefit, when dynamic procedures cannot be performed. An example would be the glenohumeral fusion after axillary nerve injury.

A major question in past and future research is: what happens with the cortical representation of muscle and nerve function after reconstructive surgery and which associated factors may impact patient's outcome?

It is of high importance to the surgeon to be able to give his or her patient a realistic prognosis of the degree of recovery after surgery. For this purpose, a certain knowledge of how cortical reorganization influences the prognosis of the surgical treatment is essential. Because of that, this chapter dives deeper into some surgical techniques to help answering questions like why, for instance, an intercostal nerve as donor leads to a better outcome in the biceps muscle concerning levels of strength, compared to the hypoglossal nerve.

The passage which follows gives an overview of the most important imaging techniques, which are essential to measure cortical plasticity in humans.

The main body of our chapter thereafter summarizes promising scientific work on cortical plasticity in peripheral nerve injury in animals and humans and tries to answer the main questions of this chapter mentioned above. Naturally, relatively macroscopic changes in motor cortex underlie changes on a molecular basis. The following passage will provide the basic approaches, as well as recent developments in the field of synaptic plasticity, as they are a prerequisite for the understanding of cortical plasticity in the future.

In summary, this chapter gives an introduction in adult and obstetric brachial plexus injury. It gives definitions, and traces different types, surgical treatments, and outcome. Next, two excellent imaging methods, fMRI and nTMS will be introduced.

In the main part, cortical plasticity will be disentangled, progress in research in animals and humans concerning cortical plasticity in peripheral nerve injuries, different types of CNS pathways involved in that, and a short introduction to the molecular background, as mentioned above, are given.

To conclude this, future prospects and suggestions for further research are shown, a conclusion will finally sum it up.

2. Adult brachial plexus injury

2.1 Definitions and types

Although adult brachial plexus injuries are relatively rare, they are nonetheless a highly traumatic injury to a patient and can cause severe disability and pain. A common cause is, above all, high-velocity trauma caused by car or motorcycle accident, which are sudden events leading to lasting physical and psychological handicaps.

Anatomically and clinically, we can subclassify brachial plexus injuries in upper and lower trunk lesions, resulting in different deficiencies. Upper trunk brachial plexus injuries (C5-C6 roots) appear as a loss of shoulder abduction, external rotation, elbow flexion, and forearm supination [1]. In comparison to this, lower trunk brachial plexus injuries (C7, C8, Th1) typically lead to a loss of elbow extension and deficits in finger and wrist movement. The extent or degree of nerve injury may be classified according to Sunderland. The classification specifies five degrees of nerve damage. The first one is neurapraxia, which is an impermanent loss of motor and sensory function due to persistent pressure or overstretching. Degree two to four describe different stages of axonotmesis, grade five stands for neurotmesis (see 2.2) [2].

2.2 Surgical treatment and outcome

For the treatment of brachial plexus injuries, in general, a balanced estimation has to be made in terms of time to wait for spontaneous recovery, which can occur in mild lesions with axonotmesis [3]. Axonotmesis describes the transection of an axon with preserved nerve sheath.

On the other hand, neurotmesis, which describes the rupture of the axon and up to all surrounding structures, or avulsion of the nerve root from the spinal cord will most likely not lead to spontaneous recovery [3]. In this case, a variety of surgical repairing techniques has been developed to reconstruct nerve function.

Basically, there are multiple ways of reconnecting muscle tissue to the central nervous system.

A nerve graft or nerve transplantation is an established way to bridge proximal and distal ends of an injured nerve. An example for a nerve graft would be to bypass an injured accessory nerve by use of smaller donors like the sural or auricularis magnus nerve.

Then there is nerve transfer. In this procedure, a functional donor nerve is sacrificed and gets connected to the affected muscle or the transected distal part of the injured nerve. In terms of upper brachial plexus injuries, Leechavengvuongs and Oberlin transfers are common and successful procedures, which are going to be explained in detail in the next passage.

There are further techniques, like tendon transfer, which is the transfer of one functional tendon on a second tendon whose muscle is paralytic due to a peripheral nerve injury. An example would be a tendon transfer for drop foot correction.

Muscle transfer is the removal of an autologous muscle and the subsequent implantation on another part of the body to improve functions after nerve injury, for example.

For the upper brachial plexus injury, the restoration of elbow flexion should be given the highest priority. Secondly, shoulder abduction, followed by external rotation are important functions.

Concerning elbow flexion, in general, nerve grafting led to better outcomes compared to nerve transfers. But taken alone the Oberlin transfer as an independent procedure, its outcomes are better than nerve grafting, nerve transfers or combined techniques [1].

In upper brachial plexus injury, the failure of the musculocutaneous nerve leads to a deficiency in elbow flexion due to a disconnection to the biceps muscle. In the Oberlin procedure, one fascicle of the ulnar nerve is being sacrificed as a donor nerve for a nerve graft to the musculocutaneous nerve close to the access to the biceps muscle. A fast motor recovery is being observed due to the close transfer to the muscle [4].

Another option is the phrenic or intercostal nerve transfer to the musculocutaneous nerve, which will be discussed as a well-researched example further below.

Regarding shoulder abduction, nerve transfer was significantly more successful than nerve grafting or combined techniques [1]. A disruption of the axillary nerve leads to abductor weakness in the deltoid muscle. The Leechavengvuongs transfer uses one radial nerve branch to be transferred onto the axillary nerve to restore abductor function [5, 6].

For the lower brachial plexus injury, the reinnervation of the median nerve for digital sensibility and forearm flexor function, and the radial nerve for the extension of the elbow, wrist and fingers are higher priorities, compared to the ulnar nerve, because the chance of recovery is lowest here. This is also the reason for usually taking the ulnar nerve as a nerve graft, besides the more commonly used sural nerve, to restore more important functions.

All in all, it is still not clarified why one repairing technique is better than the other in different settings. Presumably, the superiority of nerve transfers in some occasions is based on a combination of different influential factors. A shorter distance for nerve regeneration, only one suture junction and a vascularized donor nerve can be some reasons [1].

A deeper knowledge of how cortical plasticity influences the progress of reorganization of the affected motor areas is therefore an essential prerequisite for a satisfying outcome. What are requirements for a successful reinnervation, concerning the right choice of donor nerve, surgical treatment and rehabilitation procedure on the cortical level? How do other factors, like the age, influence plasticity?

To clarify this later, an overview on obstetric brachial plexus injury follows.

3. Obstetric brachial plexus injury

3.1 Definitions, incidence and types

The obstetric brachial plexus injury (OBPI) is a birth trauma, which may be associated with complicated childbirth. Injuries are more common in the upper brachial plexus (50% C5 and C6, 25% C5 to C7) or the panplexus (20%), rarely in the lower brachial plexus (2%) alone.

With one shoulder blocked by the mother's symphysis and the head already born, the injury is usually caused by tension on the neck and shoulder region, which can lead to a rupture of the neural structures mentioned above. This can occur during natural and vacuum deliveries.

With an incidence of about 0.1 to 3 per 1000 live births, it is a relatively rare injury, which nonetheless influences the child's life and can cause severe disability and pain.

In [7], shoulder dystocia has been identified as the main risk factor for obstetric brachial plexus injury. Others are an exceptionally high birth weight > 4.5 kilograms, breech delivery, instrumented delivery, maternal diabetes and other minor factors. In contrast to that, delivery by cesarean section and twin birth count as protective factors. In addition, there are also references mentioning an intrauterine genesis of obstetric brachial plexus injury [8]. It is important to mention that the majority of cases did not have any risk factors.

The severity of the injury is based on the degree of damage caused to the neurons. Like in adult brachial plexus injury, neurapraxia (reversible stretching) and axonotmesis have a higher chance of recovery, compared to neurotmesis, which is the rupture of the whole axon and up to all its surrounding structures. Avulsion from the spinal cord does not really have a chance for spontaneous improvement.

3.2 Surgical treatment and outcome

Spontaneous recovery occurred in 70 to 80% of all obstetric brachial plexus injuries, the other cases needed treatment due to incomplete motor recovery or an otherwise unsatisfying outcome.

On conservative treatment, no randomized controlled studies could be found. An improved outcome could not be found for primary surgical treatment in comparison to non-operative management. Nonetheless, surgical management was superior to conservative management in severe cases. In those children, primary surgical management led to a better outcome compared to secondary surgical repair, but still improved motor recovery. Overall, treatment of these children required a multidisciplinary team, as still 25% of the patients are affected by permanent disability [8].

Surgical treatment consists of direct suturing or the surgical techniques mentioned above. For minor injuries, exploration of the affected plexus parts and resection of neuroma are treatment options. Primary reconstruction of the obstetric brachia plexus injury leads to a satisfying outcome in terms of motor and sensitivity of hand and elbow for most patients. A second surgical intervention is sometimes needed to improve motor functions in wrist and shoulder [9, 10].

When we compare the outcome of surgical treatments of brachial plexus injury in adults and infants, the second group gains a much better hand function in the long term. This could be justified by the cause of the injury: In adults, this is usually a high-velocity trauma, like a car or motorcycle accident, compared to the forcefully overstretch of the head-shoulder region during birth in infants. On one hand, a worse outcome for hand function could be influenced by other severe injuries in the musculoskeletal area in adults [11]. On the other hand, the major factor influencing cortical plasticity, and therefore the motor outcome, is age, which will be discussed below (5.4).

4. Functional imaging methods

4.1 fMRI

fMRI (functional magnetic resonance imaging) is a variation of MRI (magnetic resonance imaging). It detects changes in tissue perfusion in different brain regions, generated by a changing energy consumption of active nerve cells.

The BOLD (Blood-Oxygenation-Level Dependent)-Effect is a basic principle, which the fMRI is based on. It depends on the presence of oxygenated hemoglobin, which has no magnetic characteristics, compared to deoxygenated blood, which is paramagnetic. This leads to the appearance of a magnetic field, which results in a changing of rotation properties in hydrogen protons.

Briefly, neuronal activation leads to a hemodynamic response in the respective area, which results in a different spinning behavior of protons and therefore to the identification of active areas on the resulting image. It is important to note that this reaction is an indirect measure of neural activity and underlies a delay of about five seconds, which lowers the temporal resolution of this imaging method. In terms of spatial resolution, compared to other imaging techniques, fMRI provides comparatively good outcomes.

Neuronal activity can either be evoked deliberately through tasks carried out by the patient during the measurement, or passively as a resting state fMRI, which shows the patient's baseline bold variance.

Apart from the good spatial resolution, fMRI has the advantages of not using ionizing radiation and being painless for the patient. Also, it covers the whole brain, including deeply localized brain structures.

fMRI can be used to detect sensorimotor, as well as language and visual cortices, but its lack of specificity and sensitivity prevents it from becoming a gold standard for the identification of such cortical regions. Apart from that, it might not always represent real neural activity, as the signal changes with modified vascularization. Finally, the MRI being a relatively loud imaging technique, makes it not the ideal method for examining speech and language functions as it influences its own results [12].

4.2 nTMS

Transcranial magnetic stimulation (TMS) is a non-invasive diagnostic tool to map eloquent areas for motor and speech function on the cortical surface. A figure of eight shaped magnetic coil elicits an electric impulse on the patient's head surface hereby leading to a depolarization of cortical neurons. Navigated TMS (nTMS) uses a high resolution T1 navigation sequence to generate an anatomical model of the patient's head. By navigating the stimulation coil and a head tracker positioned on the subject's forehead a high anatomical precision in cortical mapping can be achieved. Motor responses are recorded by a free running EMG recorded surface electrodes on the corresponding muscles.

A big advantage of the nTMS technique is the possibility to navigate accurately and individualized, but non-invasive.

During the measurement two objects are being located constantly in a 3D space: First, information about the position of the patient's head, in case of movement, has to be transmitted to the system. For this case, a so called "head tracker" is fixed on the forehead, which is in constant connection to an optical positioning sensor. Secondly, the 3D position of the coil and intensity of the resulting magnetic field has to be tracked simultaneously to allow optical orientation and therefore precise stimulation. Here, a coil tracker transmits information about orientation, location and tilting as relative coordinates to the positioning sensor.

The examiner connects the MRI scan and the real head through the use of a digitizer pen at the beginning of a session by pointing given anatomical landmarks on both the MRI scan and the head. Algorithms then link the scan to the patient's head coordinates and enable the examiner to see a real time e-field, which is dependent on the position of the coil on an MRI 3D-model, on the nTMS system display. Apart from those devices, nTMS hardware also includes a stimulator. It produces the output pulse given by the nTMS software.

Furthermore, an EMG is attached on the side of the examination chair to record motor evoked potentials (MEPs). MEPs are displayed on a free running EMG on the display next to the 3D MRI model of the subject's head. They are synchronous to each stimulation and determine the color of the stimulation spot on the MRI, which depends on the amplitude of the MEP. Lastly, a foot pedal is there to apply stimuli and adjust intensity easily without having to move one hand from the coil (**Figure 1**).

For motor mappings, a stimulation along the central sulcus according to the localization of the homunculus is performed. A few of the important parameters of TMS are the Center of Gravity, which resembles the amplitude-weighted position of the determined muscle on the motor map. The Motor threshold is the minimum TMS intensity necessary to induce a motor-evoked potential from a specific muscle. It refers to the inherent excitability [13]. Especially for the hand and arm motor area, stimulation of the central sulcus, precentral gyrus and sulcus and postcentral

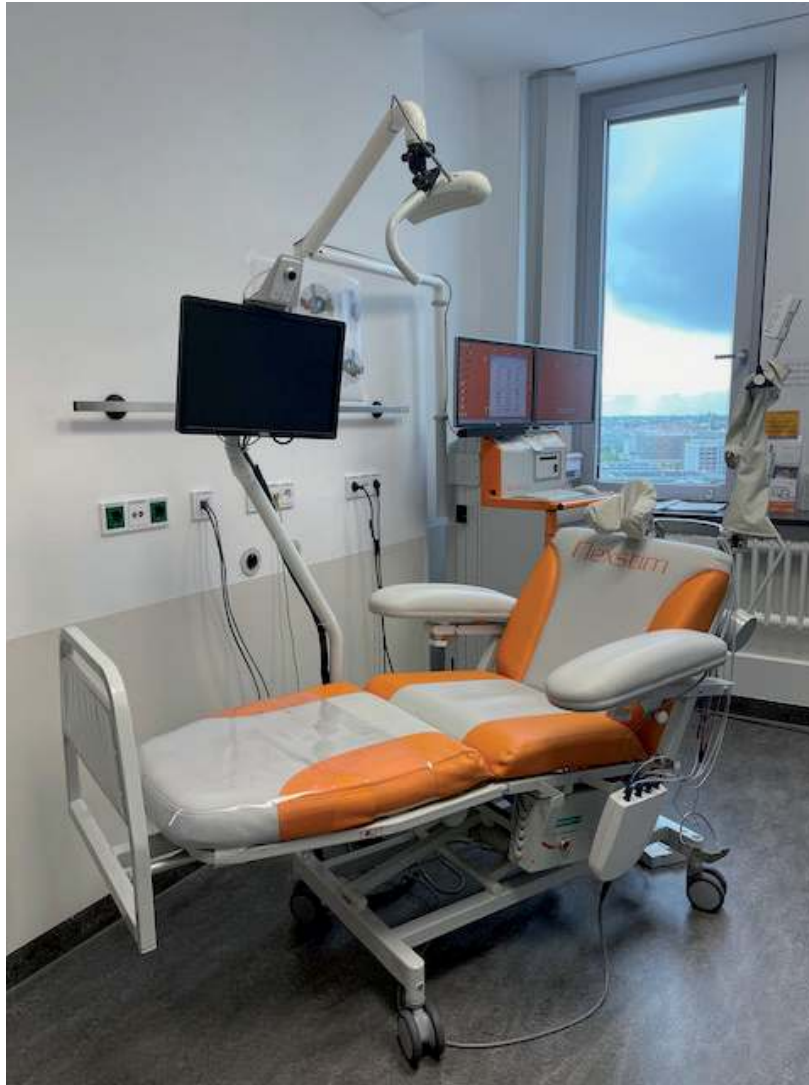

Figure 1.
TMS hardware.

sulcus is recommended (please see [12] for more information on how to perform an nTMS session) (**Figure 2**).

In summary, nTMS is a noninvasive motor mapping technique that allows us to find the precise cortical location of motor or language functions in real time. Clinical applications include in particular the preoperative mapping of language regions and motor mapping in the management of peri-Rolandic tumors to locate the pyramidal tract [12].

As for the limitations of this technique, the first point to mention is precision. A study [14] estimates the spatial accuracy being better than 5 mm. As the tolerance for registration is limited to 2-3 mm, one has to keep in mind that brain and surrounding tissue can undergo changes due to neoplastic activities or intraoperative movement.

Secondly, the magnetic field itself can be a limitation, as magnetic pulses sometimes spread into subcortical white matter tracts. The activation of neurons situated there can be misinterpreted as motor function.

Thirdly, some basic parameters in both motor and language mapping are not yet investigated sufficiently enough, so that small adjustments in intensity and timing can have a bigger impact on the measurement than it is known yet.

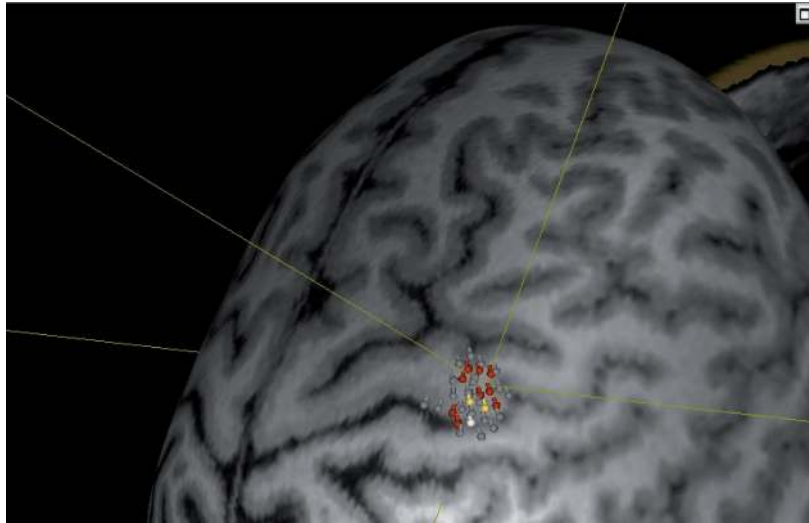


Figure 2.
Example of stimulation results around hand area.

A comparison of the two functional imaging techniques described above includes advantages and disadvantages in terms of temporal and spatial resolution, accurateness and feasibility. fMRI has the disadvantage of measuring neural activity indirectly through the product of three consecutive metabolic reactions, which delays the output by several seconds. In temporal considerations, nTMS is more accurate, as it more or less only takes the conduction velocity of the respective nerve between in- and output. For spatial resolution, fMRI has the advantage of reaching deeper brain regions on the one hand, but is not able to detect white matter connections, on the other hand. Compared to that, nTMS only has a magnetic field strong enough to reach a depth of two to three centimeters. Regarding certain artifacts, nTMS is resistant to abnormal vasculature, whereas fMRI gets affected by that. Although there are some contraindications for nTMS, such as aneurysm clips and deep brain stimulators, they do not pose a risk for the patient, as they would do in an MRI. Also not unimportant is the factor of patient participation. As for motor mappings, no patient participation is required, although sessions can get really long for patients, as well as quite painful during some measurements due to high stimulation intensities. fMRI on the other side can cause claustrophobia, but is usually not painful. In terms of accuracy, nTMS produces motor maps with the highest concordance rates with intraoperative DES motor maps [15].

As both of these techniques have their strengths, it is important to know the indications and to pick the most suitable functional imaging method individually.

4.3 Other measuring techniques

Further measuring techniques, apart from fMRI and nTMS, are summarized in **Table 1**. A short description, strengths and weaknesses are displayed to gain a quick overview. For the sake of completeness and comparability, fMRI and nTMS are again included.

It can be suggested that a multi-modal approach as a combination of some of these techniques could be most effective to gain an integrated picture of cortical plasticity [17]. For instance, it would make sense to combine techniques with the advantage of being able to measure with both a high temporal and spatial resolution.

Measuring technique	How it works	What is measured	Strengths	Weaknesses
fMRI	MRI + BOLD effect (see above)	Active areas through changes in tissue perfusion	Reaches deeply located brain regions; non-invasive	Temporal resolution; indirect measurement; contraindications
nTMS	Magnetic coil induces electric field on cortex (see above)	In general: representation of a muscle on motor cortex (for motor mappings)	Temporal resolution; no patient participation required	Spatial resolution: only cortex (+ close underlying structures) → bidimensional
Cortical stimulation mapping (DES)	Current causes reversible lesion in small area	In general: representation of one or more muscles on motor cortex	Gold standard: temporal and spatial resolution	Craniotomy required
Magneto-encephalography (MEG) [16]	Estimation of magnetic field generated by electric currents in brain	Direct measurement of sensimotor areas	Temporal resolution	MEG device expensive → not as common
Positron emission tomography (PET)	Radioactive tracer accumulates in metabolically active regions	Active areas due to a high metabolism	Spatial resolution	Temporal resolution, radiopharmaceutical injection
Electro-encephalography (EEG)	Electrical potential changes of pyramidal cells displayed as curves	Electrical potential changes over area of a few centimeters	Temporal resolution	Spatial resolution (centimeters)

Table 1.
 Overview of cortical plasticity measuring techniques.

For rehabilitation, [18] combined EEG and rTMS to gain a real time picture of the excitability brain state to control the efficiency of cortical plasticity induced by rTMS, to name only one example.

5. Cortical plasticity after peripheral nerve injuries

5.1 Introduction and definition

It is an established opinion in neuroscience for several decades now that the brain is not a rigid and inflexible organ, but highly capable of decoding new information through growth and reorganization over our whole life span. All cortical areas are able to process practiced movement or sensory experience, which called Cortical Plasticity. It is the ability to increase cortex area that represents a certain peripheral input which is proportionally most used.

To understand the background of cortical plasticity, a closer look has to be taken on molecular mechanisms underlying this phenomenon. Already in 1949, Donald Hebb postulated that “When an axon of cell A is near enough to excite B and repeatedly or persistently takes part in firing it, some growth process or metabolic change takes place in one or both cells such that A’s efficiency, as one of the cells firing B, is increased” [19]. Several molecular mechanisms, including long-term potentiation and long-term depression, underlie this feedback loop, which will be presented below (5.5).

The same basic principles that underlie encoding of practice or experience can be detected in cortical reorganization following lesions of the central nervous system. Although a lot of literature can be found on that, the consequences of cortical reorganization after peripheral denervation and, subsequently, after surgical reinnervation, are still not well investigated and understood, especially humans. Some findings in the field of motor cortex reorganization come from fMRI and TMS studies that were made after peripheral nerve injury or amputation. In contrast to that, there are already interesting findings in animal research.

5.2 Cortical plasticity in animals

Cortical plasticity following peripheral nerve injuries has been investigated in animals, especially in mice, rats and primates.

Merzenich et al. [20] and Jenkins et al. [21] are often-quoted articles from the 1980’s. In [20], the median nerve was transected and ligated in adult monkeys, which lead to the inability of flexing the affected hand’s first three fingers. Through microelectrode mapping several months after the transection of the nerve, one found the former representative areas of the affected fingers occupied by expanded representations of surrounding skin fields. Large new representative fields of finger four and five, as well as of the dorsal parts of fingers one, two, and three were found. Some fields only expanded, some other moved completely into the former areas of the denervated fingers. The topographic order of the remaining fingers was reported to be regular, the size of the expanded or “new” areas approximately correlated with the size of the original ones.

It could be observed that synaptic connections between motor cortex and somatic musculature are continually reshaped in young and adult animals. In terms of timing, it has been found that synaptic changes in motor cortex start developing at most hours after the peripheral nerve transection, and continue their formation at least for months.

Donoghue et al. [22] unmasked latent intracortical connections by pharmacologically blocking intracortical inhibition via GABA antagonists. Thereby,

preexisting excitatory connections inside the motor cortex were revealed. In this experiment, a peripheral nerve of adult rats got transected and simultaneously blocked by GABA on the cortex level, and within a few hours, in the cortical territory of the affected body part, movements represented in adjacent primary motor cortex areas were evoked. Due to this study, one can assume the existence of fibers in healthy subjects which can form a possible basic structure of plasticity after peripheral nerve injury.

The same group gave another example [23] of rapid motor cortex reorganization after motor nerve transection in rats. With the help of maps made by intracortical electrical stimulation, comparisons between healthy rats and animals with a facial nerve lesion showed a shift from vibrissae to forelimb representational areas within hours after facial nerve transection. This again shows a continuous reshaping of synaptic relations between motor cortex and somatic musculature in adult mammals.

Apart from changes in the motor cortex representation within hours after a lesion, [24] found long-term patterns of reorganization after lesions set between one week and four months before. Again, with the help of maps made by intracortical electrical stimulation, comparisons between healthy rats and rats with a facial nerve lesion and, this time, rats with a forelimb amputation, showed an enlarged area representing the forelimb and eye/eyelid output for facial nerve transected animals and an increase of the area for shoulder movements for the limb amputated animals. As the extent of some representations of healthy musculature in both experimental conditions increased, it can be concluded that M1 output relationships with target muscles reorganize in response to nerve injury in adult animals with a long-lasting effect, considering the rat's life span of about two years.

5.3 Cortical plasticity in humans

Cortical plasticity following nerve transection has been investigated in humans, too, whereas literature lacks in studies about cortical reorganization after nerve transfer or nerve graft. In contrast to animal studies, imaging methods like direct cortical stimulation can hardly be used in human subjects concerning the observation of cortical reorganization after peripheral nerve injuries. Therefore, the above-mentioned methods of fMRI, nTMS, as well as magnetoencephalography (MEG), and positron emission tomography (PET) can be used with all their advantages and disadvantages. As mentioned above, TMS provides detailed motor maps, fMRI provides good spatial resolution, MEG provides almost real-time temporal resolution, in return. A well-chosen combination of those techniques and derivatives, like fiber tracking, is essential to study cortical reorganization.

A look on different factors that determine outcome after surgical reinnervation shows that there are multiple criteria on which a successful intervention depends:

In the first place, there is the distance between the cortical areas of donor and receptor neuron. As mentioned previously, latent intracortical connections could possibly be more distinct between areas that are located closer to each other on the motor cortex. For example, in some cases, the hypoglossal nerve has been used for a musculocutaneous transfer. Outcomes had been poor, because cortical motor areas of both nerves are distantly located. In contrast to that, a hypoglossal-facial nerve transfer shows better results, probably due to a closer location. Another good example would be the success rate of the transfer of an intercostal to the musculocutaneous nerve: The two nerves, though not being connected to the same body part, probably share preexisting connections, because of body posture control being an essential requirement for elbow flexion.

Secondly, a presence or absence of lowly active interneural connections are also likely to determine the outcome, which resembles the first point. Immediately after deafferentation, unmasking of those fibers is probably based on the reduction of GABAergic inhibition of neighboring neurons. This theory could be supported by the detection of reduced GABA-staining at least in somatosensory cortex [25]. Also, the unmasking of previously “silent” thalamocortical projections could play a role in the immediate events taking place after a nerve transection.

Thirdly, as a main principle, the recovery of gross movements, like elbow flexion, succeeds more often than that of finer movements, like finger or hand movements. This fact could be based on the large area the hand occupies on motor cortex, which is not so easy to be supported by enough axon donors surgically.

Fourthly, the long-term outcome depends on rehabilitation, which should start early after intervention, include many repetitions and last two years minimum. Additionally, sensory input is important for a motoric rehabilitation, so ideally, sufficient sensory function should be ensured previously.

Finally, outcome clearly depends on the age at transection and on the degree of injury, naturally. As above-mentioned, the treatment of neonatal brachial plexus injuries has excellent results, which can be reasoned by a better axonal regenerative capacity, but also by the shorter distances from the muscle to the brachial plexus. In summary, two basic rules for successful reinnervation could be determined: A close cortical location of the donor and acceptor nerve region and similar motor control pathways, as well as the existence of (latent) connections between them [13, 26].

For studying effects of peripheral reinnervation on the cortex, fMRI might not be the ideal tool, because it shows neural activity related to input and intracortical processing, rather than output signals. In patients with reinnervated biceps muscle, the M1 area representing the biceps of both affected and contralateral side showed no difference between them neither in the number of active pixels, nor in the mean value of their activations. So, although both areas seemed to activate the biceps muscle of the respective side, the affected muscle could not have been reached by it [27, 28].

In contrast to that, TMS studies showed that a lateral shift of the intercostal nerve area takes place shortly after the intercostal-musculocutaneous nerve transfer. Little by little, this area conquers the former musculocutaneous area on motor cortex. At the end of the process, it occupies the physiologic biceps area [27]. In another TMS study, after the above-mentioned intervention, the cortical area of the biceps of the affected arm was smaller and less excitable than the contralateral one. But also, the newly-shifted former intercostal nerve area of the affected side has been found occupying the former biceps side, which is a similar finding to the experiment above [29].

Apart from diagnostics, repetitive transcranial magnetic stimulation (rTMS) is used as a therapeutic tool. Recently, level A evidence was reached in the treatment of neuropathic pain, depression, and for hand motor recovery in the post-acute stage of stroke.

On healthy subjects, TMS was applied with the help of closed-loop stimulation. Passively moving their hand via brain-machine-interface, subjects activated TMS stimulation of their motor cortex. This synchronized coupled stimulation led to the recruitment of additional corticospinal pathways [30].

Additionally, also in a healthy subject, TMS in combination with a brain-machine interface increased the mean motor evoked potential (MEP). Compared to that, the mean MEP could not be increased in a patient with ischemic hemiplegia for five years with this experimental treatment [31].

All in all, experience should be gained on if and how (reinnervated) peripheral nerve injuries could possibly be treated with TMS.

5.4 Different types of CNS pathways involved

As mentioned above, denervation of the musculocutaneous nerve can be reinnervated by a nerve transfer of an intercostal nerve. As intercostal nerves were previously connected to muscles in charge of respiration and posture control, patients are postoperatively able to move their biceps muscle through inhaling. It can be observed that, after months, patients are able to flex their elbow directly, which means without the “trick” of breathing. A TMS-study examined this condition. Patients were stimulated during breathing, rest and voluntary contraction of the biceps. In contrast to shortly after the reinnervation, MEPs were highest for the voluntary contraction, compared to the muscle activity during respiration and rest. That implies that a shift must have been taken place, where the cortical area once responsible for breathing and posture control now enables a muscle of the arm to voluntarily contract. Still, typical respiratory EMG activity could be observed in subjects [32]. This is only one example of many, but the question is: Why and how does this change of cortical connectivity happen?

First, the above-mentioned study named the formation of new direct connections between the cortical intercostal nerve and musculocutaneous nerve area. Through TMS, a lateral shift of the intercostal nerve area in the direction of the biceps area could be observed. In the end, it occupied the original biceps area.

Secondly, axonal sprouting could be one of many, probably colluding, factors contributing to cortical plasticity.

Thirdly, as already mentioned above, the cortex most likely contains a large network of partly inactive, inhibited fibers, which gets stronger once another inhibiting structure fails due to denervation and serves as a matrix or skeletal structure for new connections to build on. These preexisting latent networks are probably stronger between areas with a similar function or movements often done simultaneously, for example stretching of the elbow and stretching of the wrist. Latent connections between the biceps and intercostal muscles could preexist due to the need of posture control during (powerful) biceps contraction.

Below, a table summarizes the above-mentioned factors influencing cortical plasticity after peripheral nerve lesion. These factors should always be kept in mind when planning a reconstructive surgery (**Table 2**).

5.5 Molecular background

Changes in synaptic plasticity seem to be the basic principle underlying cortical plasticity. To study motor cortex reorganization, e.g., after brachial plexus injury, it is crucial to understand how a change in peripheral input modifies patterns of neuronal firing.

The above-mentioned rule of Donald Hebb or, in short, “Neurons that fire together, wire together”, serves as a basic principle underlying synaptic plasticity. Although not much was known then about the molecular background of synaptic firing, Hebb’s rule was experimentally confirmed over the years. In general, high-frequency stimulation induces synaptic potentiation, whereas long lasting, low-frequency stimulation induces synaptic depression. These changes in synaptic strength can last for a short or longer (several minutes) period of time. In this case, the change in firing frequency is called long-term potentiation (LTP) or long-term depression (LTD). Very long-lasting firing patterns depend on a change in protein synthesis. These changes in synaptic activity can be illustrated with the help of differential equations, which shall not be discussed here [41].

Factor	Short explanation	References
Time between injury and repair	Balance between waiting for spontaneous recovery and worsening requirements for surgical repair	[33]
Distance between cortical areas of donor and receptor nerve	The smaller the distance, the higher the chance of an increase in connectivity between areas	[26]
Rough vs. fine movement reconstruction	Rough movement seems to be easier to reconstruct	[34] [35]
Lowly active interneural connections	Lowly active interneural connections are masked and detectable whilst increasing their activity after failure of overlying fibers	[22] [32]
Trauma	In general, "black holes", as results from brain trauma, seem to be occupied by neighboring areas	[20, 21] [23, 24]
Age	The younger the brain, the more potential for cortical plasticity	[36] [37] [38] [39]
Rehabilitation	Starting early preoperatively and lasting at least two years	[40]

Table 2. Summary of factors influencing cortical plasticity after peripheral nerve lesion, modified according to Socolovsky et al. [26].

In the rodent barrel cortex, where sensory input of whisker movement gets processed, information of each single whisker is transmitted to a specific neuronal cell cluster. It has been found out that cutting every but a single one whisker induces the building of further connections between these cell clusters in the form of LTP. Shortly after cutting the whiskers, a few sensorial inputs lead to an increased number of N-methyl-D-aspartate (NMDA) receptors in the postsynaptic membrane, which lead to an increase in glutamate transmission and thus to a higher information transmission. Interestingly, after further usage of the single whisker, further synaptic plasticity gets induced by an increased number of metabotropic glutamate (mGlu) receptors in the postsynaptic membrane, which probably leads to a long-lasting increase of AMPA receptor. This enables the cell of a higher calcium influx, which forms the basic molecular background of LTPs [42, 43]. After all, LTP is now believed to be a more complex, multicomponent process, that is not yet fully understood.

Recent models however have revealed a variety of other forms of plasticity in neocortex. Plasticity of intrinsic excitability, plasticity of GABAergic circuits, homeostatic synaptic scaling and metaplasticity are the most important. As all of these models are based on physiological neuronal tissue, lesion-induced plasticity can possibly depend on partly different mechanisms.

Plasticity of intrinsic excitability is a neuron's electrical excitability, which is influenced by the number of receptors and distribution and number of ion channels that determine the electrical potential of the neuron. A little neglected earlier in synaptic plasticity research, it nowadays seems to play an important role on the microscopic level of cortical plasticity [44].

Plasticity of GABAergic circuits, as mentioned above, is believed to also play an important role in synaptic plasticity in controlling a balance of excitation and inhibition. Inhibitor cells, too, have the ability of the production of LTP and LTD. GABAergic neurons are associated of being one of the regulatory elements in

maintaining homeostatic plasticity. For instance, a twenty-four-hour continuous whisker stimulation decreases cortical activity due to overstimulation, which is a homeostatic mechanism based on the inhibitory activity of GABAergic cells [45].

Homeostatic synaptic scaling is caused by decreased neuronal firing activity, which leads to a decreased somatic calcium concentration. This lowers the amount of activated Calcium/calmodulin-dependent protein kinase type IV (CaMKIV), which then activates the transcription of a “scaling factor”. After this, alpha-amino-3-hydroxy-5-methyl-4-isoxazolepropionic acid (AMPA) receptor accumulation at synapses is increased. Excitatory synaptic strength is enhanced and raises firing rates back to the set level, which represents the “homeostatic” part of the expression [46].

Metaplasticity has been described as learning-dependent changes in synaptic plasticity. So, to say, metaplasticity is a superior form of molecular plasticity mechanisms, influencing the other mechanisms.

It is also important to mention that each of these plasticity mechanism models play larger or smaller roles in different cortical areas and depend as well on developmental stages and complex, still unknown interactions.

The question of how these molecular changes exactly influence synapse-scale structural changes and how these relate to macroscopic cortical plasticity remains unanswered. It will be exciting to discover if those synaptic plasticity models, probably along with other, yet unknown mechanisms, someday can be connected to a broader principle or if there is less diverse interconnectivity then it is assumed these days.

6. Future prospects

So far, studies on factors that influence cortical plasticity in brachial plexus injury are scarce. Although there are multiple elegant ways of picturing structural changes on cortex in humans, such as nTMS or fMRI, without direct cortical stimulation as it is made in animal research, imaging methods are not able to reproduce plasticity on a more microscopic level. Macroscopic anatomy and rough functions of fibers can be assigned properly and molecular backgrounds of synaptic plasticity are understood to some extent as presented above. However, the connection between those two levels has to be investigated by future studies.

Another major point of interest is to understand in detail why the infant neuronal tissue has better capacities of reorganization than the adult as a basis of why, for instance, obstetric brachial plexus injuries have a better rate of recovery than the adult form. Research in this direction could someday probably benefit as a rehabilitative aspect in adult brachial plexus injury.

Generally, in the field of neurorehabilitation, not much literature can be found on aspects of rTMS rehabilitation in (surgically treated) peripheral nerve lesions. Only level A evidence was reached in the treatment of hand motor recovery in the post-acute stage of stroke, which has been investigated in rodents, as well as human subjects.

nTMS studies on the field of adult, as well as obstetric brachial plexus injuries are rare. Structured investigation in the direction of showing motor cortex plasticity sorted by diagnosis (upper brachial plexus injury, lower brachial plexus injury, isolated nerve transection) and treatment (for instance, Oberlin transfer, Leechavengvuongs transfer and so on) may help to understand cortical plasticity in brachial plexus lesions. Comparisons of nTMS with fMR images may deliver even more information.

In the future, these techniques could possibly hold the capacity of helping in decision making for timing and technique of reconstructive surgery. Also, nTMS

could prospectively be helpful in prognosing the rehabilitative capacity after a peripheral nerve injury e.g. brachial plexus lesion. Preoperatively, it could be possible in the future to exactly determine the former motor area of the denervated nerve and the current motor area of the nerve donor to determine the degree of cortical plasticity that will likely happen, and thereby the chance of regaining a certain level of strength in the affected limb. It should also be easy to compare the predictive power of certain questionnaires or walking tests with the predictive power of nTMS.

All in all, nTMS seems to be a useful tool in the research of cortical plasticity after brachial plexus injury. In the best case, a study with a high number of peripheral injury patients with a surgical treatment should be created to observe cortical plasticity pre- and postoperatively and to detect more structural patterns to increase the capability of nTMS of serving as a prognostic gadget.

7. Conclusions

To give insight into the impact of cortical plasticity in brachial plexus injury we disentangled macroscopic and microscopic aspects. Data from human and animal studies related to cortical plasticity after peripheral nerve injury, mainly after an injury of the upper extremity, focus on timing between injury and repair. It was shown that keeping a balance between waiting for spontaneous recovery and surgical repair is essential for patient outcome. The distance between the cortical areas of the donor and receptor nerve influences the time of recovery. The closer two areas are located and the better they are connected, the higher is the probability for a good outcome. A better outcome was found for rough movement in contrast to the reconstruction of fine movements, which can depend on the larger size of fine movement areas, like the hand, on motor cortex. Lowly active interneural connections probably play a larger role in cortical plasticity than it is currently understood. As they are concealed by active fibers in the healthy brain, it could be a challenge to disentangle their functions. Trauma in general is known to be a major driving force of cortical reorganization, although underlying principles still have to be fully discovered. Age strongly influences the outcome after peripheral nerve injuries. Some investigations have been made on differences in the young and adult brain concerning plasticity. Lastly, rehabilitation should already start before reconstructive surgery and should at least last two years. These were the main factors influencing outcome of a peripheral nerve injury concerning cortical plasticity. Some of them can more or less be influenced by careful planning of treatment. Reconstructive surgeons and physiotherapists should consider including this knowledge in their treatment plan.

Future research is needed to understand mechanisms of how molecular changes on a synaptic level of a neuron influence the macroscopic plasticity, to improve rehabilitative resources, to understand the exact prognostic value of nTMS in brachial plexus injury and to investigate the therapeutic capability of rTMS.

Conflict of interest

The authors declare no conflict of interest.

Author details

Jennifer Reinsch¹, Anna Zdunczyk^{1,2}, Tarik Alp Sargut¹, Maren Denker¹,
Melina Engelhardt^{1,2}, Peter Vajkoczy¹, Thomas Picht^{1,2} and Nora Dengler^{1*}

1 Department of Neurosurgery, Charité Universitätsmedizin Berlin, Germany

2 Image Guidance Lab, Charité Universitätsmedizin Berlin, Germany

*Address all correspondence to: nora.dengler@charite.de

IntechOpen

© 2021 The Author(s). Licensee IntechOpen. This chapter is distributed under the terms of the Creative Commons Attribution License (<http://creativecommons.org/licenses/by/3.0>), which permits unrestricted use, distribution, and reproduction in any medium, provided the original work is properly cited. 

References

- [1] Ali ZS, Heuer GG, Faught RW, Kaneriyah SH, Sheikh UA, Syed IS, et al. Upper brachial plexus injury in adults: comparative effectiveness of different repair techniques. *J Neurosurg*. 2015;122(1):195-201.
- [2] Sunderland S. A classification of peripheral nerve injuries producing loss of function. *Brain*. 1951;74(4):491-516.
- [3] Pondaag W, van Driest FY, Groen JL, Malessy MJA. Early nerve repair in traumatic brachial plexus injuries in adults: treatment algorithm and first experiences. *J Neurosurg*. 2018;130(1):172-8.
- [4] Songcharoen P. Management of brachial plexus injury in adults. *Scand J Surg*. 2008;97(4):317-23.
- [5] Leechavengvongs S, Witoonchart K, Uerpaiojkit C, Thuvasethakul P. Nerve transfer to deltoid muscle using the nerve to the long head of the triceps, part II: a report of 7 cases. *J Hand Surg Am*. 2003;28(4):633-8.
- [6] Witoonchart K, Leechavengvongs S, Uerpaiojkit C, Thuvasethakul P, Wongnopsuwan V. Nerve transfer to deltoid muscle using the nerve to the long head of the triceps, part I: an anatomic feasibility study. *J Hand Surg Am*. 2003;28(4):628-32.
- [7] Foad SL, Mehlman CT, Ying J. The epidemiology of neonatal brachial plexus palsy in the United States. *J Bone Joint Surg Am*. 2008;90(6):1258-64.
- [8] Andersen J, Watt J, Olson J, Van Aerde J. Perinatal brachial plexus palsy. *Paediatr Child Health*. 2006;11(2):93-100.
- [9] Lombard A, Bachy M, Fitoussi F. C5-8 neonatal brachial plexus palsy. Operative findings, reconstructive strategy and outcome. *J Hand Surg Eur*. 2020;45(8):798-804.
- [10] Waters PM. Update on management of pediatric brachial plexus palsy. *J Pediatr Orthop*. 2005;25(1):116-26.
- [11] Pondaag W, Malessy MJ. Recovery of hand function following nerve grafting and transfer in obstetric brachial plexus lesions. *J Neurosurg*. 2006;105(1 Suppl):33-40.
- [12] Navigated Transcranial Magnetic Stimulation in Neurosurgery: Springer; 2017. 299 p.
- [13] Anastakis DJ, Malessy MJ, Chen R, Davis KD, Mikulis D. Cortical plasticity following nerve transfer in the upper extremity. *Hand Clin*. 2008;24(4):425-44, vi-vii.
- [14] Schmidt S, Bathe-Peters R, Fleischmann R, Ronnefarth M, Scholz M, Brandt SA. Nonphysiological factors in navigated TMS studies; confounding covariates and valid intracortical estimates. *Hum Brain Mapp*. 2015;36(1):40-9.
- [15] Picht T. Current and potential utility of transcranial magnetic stimulation in the diagnostics before brain tumor surgery. *CNS Oncol*. 2014;3(4):299-310.
- [16] Willemsse RB, Hillebrand A, Ronner HE, Vandertop WP, Stam CJ. Magnetoencephalographic study of hand and foot sensorimotor organization in 325 consecutive patients evaluated for tumor or epilepsy surgery. *Neuroimage Clin*. 2016;10:46-53.
- [17] Rossini PM, Dal Forno G. Integrated technology for evaluation of brain function and neural plasticity. *Phys Med Rehabil Clin N Am*. 2004;15(1):263-306.
- [18] Zrenner C, Desideri D, Belardinelli P, Ziemann U. Real-time

EEG-defined excitability states determine efficacy of TMS-induced plasticity in human motor cortex. *Brain Stimul.* 2018;11(2):374-89.

[19] Hebb D, editor *The Organization of Behavior: A Neuropsychological Theory* 1949.

[20] Merzenich MM, Kaas JH, Wall J, Nelson RJ, Sur M, Felleman D. Topographic reorganization of somatosensory cortical areas 3b and 1 in adult monkeys following restricted deafferentation. *Neuroscience.* 1983;8(1):33-55.

[21] Jenkins WM, Merzenich MM, Recanzone G. Neocortical representational dynamics in adult primates: implications for neuropsychology. *Neuropsychologia.* 1990;28(6):573-84.

[22] Jacobs KM, Donoghue JP. Reshaping the cortical motor map by unmasking latent intracortical connections. *Science.* 1991;251(4996):944-7.

[23] Sanes JN, Suner S, Lando JF, Donoghue JP. Rapid reorganization of adult rat motor cortex somatic representation patterns after motor nerve injury. *Proc Natl Acad Sci U S A.* 1988;85(6):2003-7.

[24] Sanes JN, Suner S, Donoghue JP. Dynamic organization of primary motor cortex output to target muscles in adult rats. I. Long-term patterns of reorganization following motor or mixed peripheral nerve lesions. *Exp Brain Res.* 1990;79(3):479-91.

[25] Garraghty PE, LaChica EA, Kaas JH. Injury-induced reorganization of somatosensory cortex is accompanied by reductions in GABA staining. *Somatosens Mot Res.* 1991;8(4):347-54.

[26] Socolovsky M, Malessy M, Lopez D, Guedes F, Flores L. Current concepts in plasticity and nerve transfers:

relationship between surgical techniques and outcomes. *Neurosurg Focus.* 2017;42(3):E13.

[27] Mano Y, Nakamuro T, Tamura R, Takayanagi T, Kawanishi K, Tamai S, et al. Central motor reorganization after anastomosis of the musculocutaneous and intercostal nerves following cervical root avulsion. *Ann Neurol.* 1995;38(1):15-20.

[28] Malessy MJ, Bakker D, Dekker AJ, Van Duk JG, Thomeer RT. Functional magnetic resonance imaging and control over the biceps muscle after intercostal-musculocutaneous nerve transfer. *J Neurosurg.* 2003;98(2):261-8.

[29] Malessy MJ, van der Kamp W, Thomeer RT, van Dijk JG. Cortical excitability of the biceps muscle after intercostal-to-musculocutaneous nerve transfer. *Neurosurgery.* 1998;42(4):787-94; discussion 94-5.

[30] Kraus D, Naros G, Guggenberger R, Leao MT, Ziemann U, Gharabaghi A. Recruitment of Additional Corticospinal Pathways in the Human Brain with State-Dependent Paired Associative Stimulation. *J Neurosci.* 2018;38(6):1396-407.

[31] Gharabaghi A, Kraus D, Leao MT, Spuler M, Walter A, Bogdan M, et al. Coupling brain-machine interfaces with cortical stimulation for brain-state dependent stimulation: enhancing motor cortex excitability for neurorehabilitation. *Front Hum Neurosci.* 2014;8:122.

[32] Malessy MJ, Thomeer RT, van Dijk JG. Changing central nervous system control following intercostal nerve transfer. *J Neurosurg.* 1998;89(4):568-74.

[33] Fu SY, Gordon T. Contributing factors to poor functional recovery after delayed nerve repair: prolonged

- denervation. *J Neurosci.* 1995;15(5 Pt 2): 3886-95.
- [34] Li T, Hua XY, Zheng MX, Wang WW, Xu JG, Gu YD, et al. Different cerebral plasticity of intrinsic and extrinsic hand muscles after peripheral neurotization in a patient with brachial plexus injury: A TMS and fMRI study. *Neurosci Lett.* 2015;604:140-4.
- [35] Simon NG, Franz CK, Gupta N, Alden T, Kliot M. Central Adaptation following Brachial Plexus Injury. *World Neurosurg.* 2016;85:325-32.
- [36] Pondaag W, Malessy MJ. The evidence for nerve repair in obstetric brachial plexus palsy revisited. *Biomed Res Int.* 2014;2014:434619.
- [37] Ghasemian-Shirvan E, Farnad L, Mosayebi-Samani M, Verstraelen S, Meesen RLJ, Kuo MF, et al. Age-related differences of motor cortex plasticity in adults: A transcranial direct current stimulation study. *Brain Stimul.* 2020;13(6):1588-99.
- [38] Johnston MV. Clinical disorders of brain plasticity. *Brain Dev.* 2004;26(2):73-80.
- [39] Fullarton AC, Myles LM, Lenihan DV, Hems TE, Glasby MA. Obstetric brachial plexus palsy: a comparison of the degree of recovery after repair of a C6 ventral root avulsion in newborn and adult sheep. *Br J Plast Surg.* 2001;54(8):697-704.
- [40] Socolovsky M, Di Masi G, Battaglia D. Use of long autologous nerve grafts in brachial plexus reconstruction: factors that affect the outcome. *Acta Neurochir (Wien).* 2011;153(11):2231-40.
- [41] Peter Dayan LFA. *Theoretical Neuroscience: Computational and Mathematical Modeling of Neural Systems.* Revised ed. Edition ed: The MIT Press; 2005. 480 p.
- [42] Feldman DE, Brecht M. Map plasticity in somatosensory cortex. *Science.* 2005;310(5749):810-5.
- [43] Fox K. Anatomical pathways and molecular mechanisms for plasticity in the barrel cortex. *Neuroscience.* 2002;111(4):799-814.
- [44] Kim SJ, Linden DJ. Ubiquitous plasticity and memory storage. *Neuron.* 2007;56(4):582-92.
- [45] Knott GW, Quairiaux C, Genoud C, Welker E. Formation of dendritic spines with GABAergic synapses induced by whisker stimulation in adult mice. *Neuron.* 2002;34(2):265-73.
- [46] Turrigiano GG. The self-tuning neuron: synaptic scaling of excitatory synapses. *Cell.* 2008;135(3):422-35.