

Chapter

The Regenerative Effect of Intra-Articular Injection of Autologous Fat Micro-Graft in Treatment of Chronic Knee Osteoarthritis

*Sabah S. Moshref, Yasir S. Jamal, Amro M. Al-Hibshi
and Abdullah M. Kaki*

Abstract

The study started in 2010 to find the effect of autologous fat micrograft for osteoarthritis (OA); the result was published on normal animal's model, in 10 patients, then in 80 patients with knee osteoarthritis, and the current study in 205 patients. The study was conducted at King Abdulaziz University Hospital (January 2012–October 2015); 80 adult patients were suffering from moderate to severe knee osteoarthritis. About 10–20 mL fat micrograft was prepared with liposuction and injected intra-articularly into the affected knee/s. The results revealed that pain improvement after the fat injection during rest and with activity with the visual analogue scale. The Western Ontario and McMaster Universities Osteoarthritis Index (WOMAC) indicated improvement, both in the three domains (pain, stiffness, and physical function) and in total. The use of intra-articular autologous fat micrograft is simple, safe, and effective for degenerative knee osteoarthritis.

Keywords: autologous fat micrograft, intra-articular injection, knee osteoarthritis, cartilage degeneration, regenerative therapy repair

1. Introduction

Fat grafting and its use in aesthetic and reconstructive surgeries are considered a state of art, but looking back at the history, it is just a revival in the techniques, which was described previously by others when **Gustav Neuber** on 1893 was the first to perform fat graft for orbital depression in human and **Erich Lexer** who is a skilled German orthopedic and plastic surgeon reported a variety of clinical uses of fat graft in management of knee ankylosis and fat graft wrapped around the tendon during tendon repair to prevent skin tendon adhesion and restore gliding [1, 2].

The revolution in surgical specialty directed toward minimally invasive therapeutic modalities where endoscopic surgery replaced the open surgical operations; similarly, the recent discovery of the regenerative effect of fat micrograft due to presence of adipose-derived stem cells (ADSCs), cytokines, growth factors, pre adipocytes, and mature adipocytes led to a growing interest for the

use fat graft as regenerative treatment replacing the major surgical rejuvenative operation, and Liu et al. [3] in his major review article, which includes over 265 clinical trials about therapeutic application of mesenchymal stem cells (MSCs) for common bone and joint diseases, indicated that the MSCs are considered as an ideal source of cell therapy for different types of diseases including bone and joint diseases [3–5].

In this chapter we present our experience over the current decade in management of osteoarthritis (OA) by intra-articular injection of fat micrograft (IAFMG), describing our approach, which was developed from the belief in the powerful reparative effect of autologous fat graft for damage tissue as well as natural lubricating effect on the joints. We started on animal model, and upon confirming its safety and positive regenerative effects, we applied this minimally invasive modality on patients with advanced and moderate chronic osteoarthritis with fulfillment of ethical approval requirement for the trials on human subjects. The satisfactory outcome of this minimally invasive modality indicates that intra-articular injection of fat micrograft can replace or delay considerably the need for the classical major joint replacement surgery (JRS), with its impact on the quality of life of patients and financial cost of JRS, and long hospitalization and absence of work when compared to our minimally invasive procedure [6, 7].

2. Disease characteristics

Chronic osteoarthritis is a common complex disorder affecting middle-aged and elderly females more than males but all races. The main risk factors are constitutional, including sedentary lifestyle, obesity and aging, and genetic and local factors (biomechanical consequences of joint injury, joint laxity, or malalignment). Therefore, the stress from mechanical force plays an important critical role in the initiation and progression of the disease; it is also associated with chronic disease such as diabetes, gout, and poor diet [8–15].

Osteoarthritis is the disease of the whole joint, including the bone, cartilage, tendons, ligaments, synovium, and synovial fluid. Osteoarthritis mainly affects weight-bearing joints (i.e., knees, hips, or spine) due to chronic high stress, which leads to degradation of the cartilage; subchondral cysts; sclerosis, which stimulates new bone outgrowths (osteophytes); and synovitis leading to reduction of joint viscosity and lubrication with more friction, irritation, consequently more cartilage damage and effusion, ligament laxity and meniscal tears, and progressive narrowing of joint space. The usual patient presentation is joint pain, swelling, crepitus, morning joint stiffness, and, after prolonged rest, hyperthermia, progressively restricted movement, and major disability with deterioration in quality of life [9, 10, 16, 17].

3. Management

Management included the diagnosis of the disease and its extent based on clinical presenting symptoms and signs of the patient, evaluating the degree of pain, mobility, and functions of the diseased joint, and then utilizing the radiological modalities to confirm the disease and its severity with plain X-ray, CT scan, MRI, and other available imaging modalities; following clinical and radiological diagnoses, the plan of treatment is established according to the extent of the disease, which is ranging from nonsurgical to minimally invasive or major surgical procedure.

4. Nonsurgical therapy

Currently there is no curative intervention; all treatment modalities are directed toward pain control, improvement of joint mobility and functions, and avoiding drugs with adverse effects. Non-pharmacological management should include a combination approach in the form of patient education, modification of lifestyle, self-management, weight reduction, exercise, conventional physiotherapy, electrotherapy, hydrotherapy, and occupational therapy to prevent excessive stress on the joint.

The pharmacological symptomatic therapies for pain control are in the form of nonsteroidal anti-inflammatory medications such as acetaminophen and COX-2-specific inhibitors and topical nonsteroidal anti-inflammatory drugs. On the other hand, intra-articular injection of corticosteroids and viscous supplementation injections of hyaluronic acid improve pain and viscosity, but these pharmacological treatments have short-term improvement effect and are costly, and the intra-articular injections have a risk of acute synovitis [18–23].

Recently, the intra-articular injection of platelet-rich plasma to human osteoarthritic joints associated with significant clinical symptomatic improvements of inflammation and pain and viscosity [24].

5. Surgical therapy

Surgical therapy included minor and major surgical operations, but the recent use of the minimally invasive surgical procedure of intra-articular injection fat micro-graft with the contained adipose-derived stem cells, which we studied on animal model followed by human joints, showed very satisfactory outcome; this modality of treatment is the main theme of this chapter which will be discussed in details.

The minor surgical procedures include arthroscopic joint lavage debridement, which demonstrated short-term symptom relief with more improvement when combined with marrow-stimulating microfracture and drilling procedures of articular surface; this improvement in joint functions would postpone the need for knee replacement [25].

6. The major surgical procedures

On the other hand, joint replacement as major surgical intervention is reserved for patients with failure of other modalities and in patients with joint end-stage disease, as joint implants have a finite life span (~10–15 years). After that a variety of complications might occur such as wear particle formation, which contribute to loosening which required revision surgery; therefore the use of artificial joints in young patients (e.g., <55 years) is associated with higher revision rates of this operation with its associated disadvantages as being a major procedure with complications, long hospitalization, absence from work, and high cost, which indicate the need to develop new treatment options. Therefore tissue engineering regeneration offers a long-term solution for repair of the affected tissue components of the joints such as the bone, ligament, and knee meniscus [26–28].

7. The stem cell line therapy

Osteoarthritis is an active disease process with an imbalance between the repair and destruction and degeneration of joint with poor intrinsic healing power and

regeneration due to poor vascularization and absence of direct access to progenitor cells of bone marrow [29].

For many years, researchers have been seeking to understand the body’s ability to repair and replace the damaged tissues; these researches led them to the discovery of the unique mesenchymal stem cell, which is partly responsible for maintenance and repairing of damaged connective tissues after injury. They can migrate toward injured tissues, where they display trophic effects of synthesis of proliferative, proangiogenic, and regenerative molecules. Mesenchymal stem cells undergo site-specific differentiation into a variety of connective tissues including cartilage, bone, fat, tendon, ligament, marrow stroma, and others, with its reparative and regenerative effects with anti-inflammatory and immunomodulatory actions via direct cell-cell interaction or secretion of bioactive factors, resulting in differentiation, stemness maintenance, self-renewal, prevention, and modification of progress of the disease [17, 30–38].

Mesenchymal stem cells can be isolated from several human sources other than the bone marrow and fetal tissues, including adipose tissue (ADSCs) with similar phenotypic characteristics but different propensities in proliferation and differentiation potentials, and provide an abundant and easily accessible source of stem cells [39–46].

With all these properties, MSCs are considered as an ideal source of cell therapy for different types of diseases including bone and joint diseases as reviewed by Liu et al. [3] as a review article about therapeutic application of MSCs for common bone and joint diseases, which include over 265 clinical trials of MSCs registered with clinical trial for knee osteoarthritis and other joint and bone diseases; they conclude that MSC is a promising prospect in clinical application for bone and joint diseases, without any reports of post application adverse immune side effects [5].

8. Animal and human researches on uses of MSCs in joints

With the growing interest of using MSCs as biological treatment for cartilage repair in arthritic joint diseases on different animal models where stem cells grown on different media scaffolds include synthetic or natural extracellular matrix, implantation of stem cells into the joints is either as invasive via arthroscopy with possible increased risk of infection or noninvasive intra-articular injection MSCs. These trials are summarized in **Table 1** [6, 46–59].

Animal model trial				
Publication	MSCs	Description	Intervention	Outcome
Murphy et al. [46]	BMC	MSC and suspension of hyaluronan injected in goat OA joint Intra-articular injection	Minimally invasive	+ Cartilage regeneration
Guo et al. [47]	BMC	MSCs grow on scaffolds of bioceramic beta-tricalcium phosphate via open arthrotomy	Invasive with risk of infection	Marked improvement
Hui et al. [48]	BMC	MSCs grow on scaffolds of fibrin glue by open arthrotomy implantation	Invasive with risk of infection	Marked improvement
Liu et al. [49]	BMC	MSCs grow on scaffolds of hyaluronic acid and gelatin by open arthrotomy	Invasive risk of infection	Marked improvement

Animal model trial				
Publication	MSCs	Description	Intervention	Outcome
Kayakabe et al. [50]	BMC	MSCs grow on scaffold of hyaluronic gel sponge by open arthrotomy	Invasive with risk of infection	Marked improvement
Yan et al. [51]	BMC	MSCs grow on scaffolds of polylactic acid by open arthrotomy	Invasive with risk of infection	Marked improvement
Lee et al. [52]	BMC	MSC and suspension of hyaluronan in injected mini pig OA joint Intra-articular injection	Minimally invasive	+Cartilage regeneration
Kuroda et al. [53]	BMC	MSCs grow on scaffolds of collagen gel by open arthrotomy	Invasive with risk of infection	+Cartilage regeneration
Black et al. [54, 55]	ADMSCs	Double-blinded, placebo-controlled clinical trial on the effect? IN dogs with chronic OA of the coxofemoral and humeroradial joints Intra-articular injection	Minimally invasive	Significant improvement
Noth et al. [56]	BMC	MSCs seeded on three-dimensional biodegradable scaffolds Intra-articular injection	Minimally invasive	+Cartilage regeneration
Horie et al. [57]	Synovium MSCs	Synovium MSCs in massive meniscal defect knee rat intra-articular injection	Minimally invasive	Promoted meniscal regeneration
Mokbel et al. [58]	BMC	MSC and suspension of hyaluronan in donkey Intra-articular injection	Minimally invasive	+Cartilage regeneration
Sato et al. [59]	BMC	MSC and suspension of hyaluronan in Hartley strain guinea pig Intra-articular injection	Minimally invasive	+Cartilage regeneration
Moshref et al. [6]	ADMSCs	Intra-articular injection of autologous fat micrograft in normal sheep hind joints, intra-articular injection	Minimally invasive	Increase of the articular hyaline cartilage thickness Significant chondrocyte proliferation

Table 1.
 The other animal model trial studies.

9. Our animal trial

Our study started as an idea on 2010, when we plan to use autologous fat micrograft for treatment of osteoarthritis and we started by injecting fat micrograft into normal hind joints of sheep to determine the safety and effects of intra-articular injection of autologous fat micrograft, followed by observing the animal's activities in using their injected joints, and by examining any macroscopic or microscopic changes in the articular cartilage of the fat-injected joints compared to other similar

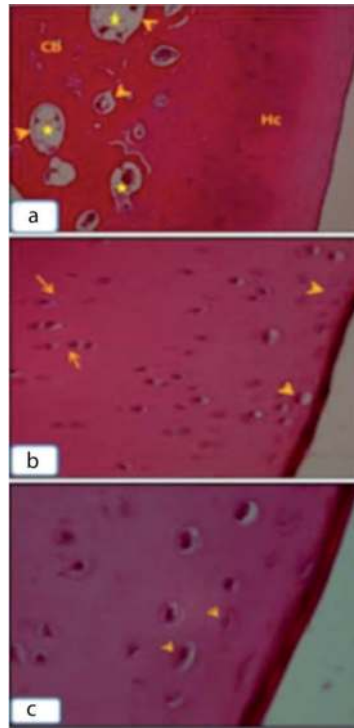


Figure 1. (a–c) The control sheep H&E stain; longitudinal sections in femoral diarthrosis of left hind knee. (a) Normal histological structure of the articular hyaline cartilage (Hc) compact bone (Cb), spongy bone (head arrows), and bone marrow (*), 100×. (b, c) Flattened chondrocytes (head arrows) of the surface layer of hyaline cartilage followed by internal globular chondrocytes arranged in rows (arrows), 400×; 1000×.

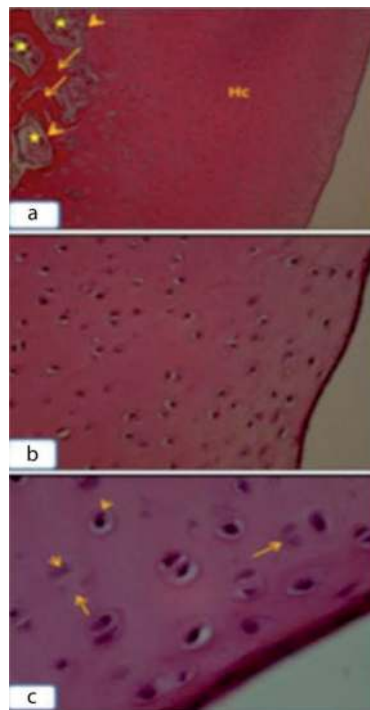


Figure 2. (a–c) The treated sheep right hind knee; longitudinal sections in femoral diarthrosis H&E stain. (a) Increasing the thickness of the articular hyaline cartilage (Hc) layer; compact bone (arrows), spongy bone (head arrows), and bone marrow (*) were observed in normal view, 100×. (b) Increasing the number of chondrocytes (arrows), 400×. (c) Chondrocyte division, metaphase (head arrows), telophase (arrows) 1000×.

Knee Joints	Femoral diarthrosis	Tibial diarthrosis
Control	40.90 ± 0.432 Left joints	42.72 ± 0.700
Treated	55.31 ± 0.681** Right joint	49.10 ± 0.585*

*Significant at $p \leq 0.01$.

**High significant at $p \leq 0.001$.

Table 2.

Number of chondrocytes in control and treated articular cartilage of sheep knee joints.

non-injected joint of the same animal; the study confirmed the safety, without any associated detrimental effects, on the joint tissues. Furthermore, it had positive microscopic findings as there was increase of the thickness of the articular hyaline cartilage layer with significant proliferation of chondrocytes including different mitosis stages (**Figures 1 and 2, Table 2**). Therefore, intra-articular injection of fat micrograft is an ideal minimally invasive choice for joint lubrication with high potential healing effects.

10. Our human trial

After the successful encouraging results of our previous animal study, which demonstrates the potential healing power and regenerative effect of autologous fat micrograft with its stem cells and all other study reports of clinical trials and publication by using mesenchymal stromal/stem cells for management of osteoarthritis, which offer a great hope for the treatment of osteoarthritic joints, we decided to evaluate the efficacy of fresh non-processed autologous fat micrograft with its ADSCs for management of osteoarthritic joints as prospective interventional clinical trial, which was conducted at King Abdulaziz University Hospital, Jeddah, Saudi Arabia, after obtaining the ethical approval from the local research and ethics committee, No. 822-12, according to latest vision of the Declaration of Helsinki. Over the period of 2012–2013, a preliminary clinical trial was conducted on 10 adult patients of both genders suffering from severe to moderate knee osteoarthritis with encouraging results as an effective and safe method for the treatment of knee osteoarthritis, then we expand the trial on 80 adult patients which confirm our previous finding, and then the clinical trial concluded with the final reporting to ethical committee on December 2016 [2, 3, 6, 7, 66].

But our work in utilizing this modality of treatment continued, and we are currently presenting the outcome in 205 adult patients (392 knee joints) who were managed and completed the required period of follow-up [7, 60–75, 77, 78].

The other studies were mainly revolving around the use of bone marrow or expanded adipose tissues and non-expanded autologous MSCs although some trials use allogenic MSCs. Most researchers focus on the use of intra-articular injections without the use of scaffolds or major surgeries since injections are more cost-effective, have little morbidity, and are a desirable way of treatment. The satisfactory outcome of our study over 10 years indicated that MSC treatment appears to be a good option for treatment of moderate to severe OA in the elderly; other studies reported similar results to ours in demonstrating promising prospect of cell therapy in many refractory diseases, including bone and joint diseases, in great improvement of pain, mobility, and other joint functions; these have high potential for clinical use in tissue engineering and regenerative and reparative medicine. Other studies found MSCs effective in cartilage healing; these trials are summarized in **Table 3** [28, 70–73, 76].

Human clinical studies				
Publication	Type of MSCs	Description	Intervention	Outcome
Davatchi et al. [76]	BMC	MSCs injected with autologous BMSCs intra-articularly of four patients	Minimally invasive	Marked improvement
Wakitani et al. [70]	BMC Human autologous culture expanded	MSC embedded in collagen gel injected into medial femoral condyle of 12 patients and 12 as control	Invasive with risk of infection	Marked improvement
Ohgushi et al. [71]	BMC	MSC seeded at ceramic ankle prosthesis and injected in the three-severe arthritic ankle for patients	Invasive with risk of infection	Marked improvement
Centeno et al. [72]	BMC	MSCs injected intra-articularly for 46-A case report study year	Minimally invasive	Marked improvement
Buda et al. [73]	BMC Human autologous culture expanded	MSC and hyaluronic acid for 20 patients (12 males and eight females)	Minimally invasive	Marked improvement
Pak et al. [74, 75]	ADSCs	MSC and hyaluronic acid, calcium chloride, a nanogram dose of dexamethasone, and platelet-rich plasma injected intra-articularly for knee osteoarthritis or hip osteonecrosis	Minimally invasive	Marked clinical improvement and cartilage thickening
Koh et al. [77]	ADSCs Infrapatellar fat pad	Autologous AMSCs from infrapatellar fat pad injected at intra-articular injection for 25 patients	Minimally invasive	Significant regeneration of cartilage
Koh et al. [78]	ADSCs Infrapatellar fat pad	AMSCs autologous injection intra-articular of 18 patients	Minimally invasive	Marked improvement
Moshref et al. [7]	ADSCs	Intra-articular injection of autologous fat micrograft for the treatment of knee osteoarthritis Preliminary trail of 10 patients	Minimally invasive	Significant clinical improvement
Moshref et al. [66]	ADSCs	Intra-articular injection of autologous fat micrograft for the treatment of knee osteoarthritis. 80 patients and 148 joints	Minimally invasive	Significant clinical improvement
Moshref 2019 (under consideration)	ADSCs	Intra-articular injection of autologous fat micrograft for the treatment of knee osteoarthritis. 205 patients and 392 joints	Minimally invasive	Significant clinical improvement

Table 3.
The other human clinical studies.

11. Study guidelines and patient selection

- **Patients:** all patients were adult patients from both genders and were screened for eligibility to participate in the study; each patient underwent a complete medical history, a physical examination, and a full assessment of the joint.

- **Informed written consent** was obtained from each patient before treatment after explaining to him all about the study and this modality of treatment.
- **Inclusion criteria:** all cases of severe to moderate knee osteoarthritis, the changes to be confirmed by bilateral anterior-posterior standing and lateral supine radiographs involving one or both knees.
- **Exclusion criteria:** recent knee surgery, chronic opioid intake, bleeding disorders, malignant disease, congenital or traumatic deformity of the knee joint, and refusal of the patient to be included in the study.
- **For the evaluation of patient,** we used **the visual analogue scale** for pain assessment (on scale 0–10 cm line, 0 = no pain and 10 = worst imaginable pain) was explained to patients during the preoperative visit; visual analogue scale at rest and during activity was obtained.
- **The Western Ontario and McMaster Universities Osteoarthritis Index (WOMAC)** is a questionnaire widely used to assess the symptoms and physical disability associated with osteoarthritis; we used five-point Likert-type Western Ontario and McMaster Universities Osteoarthritis Index to collect information regarding the three subscales of Western Ontario and McMaster Universities Osteoarthritis Index. Pain (five items): while sitting or lying, walking, using stairs, standing, and in bed. Stiffness (two items): after first walking and later in the day. Physical function (17 items): standing, walking, sitting, rising from sitting, stair use, bending, putting on or taking off socks, lying in bed, rising from bed, getting in or out of the bath, sitting on or rising from the toilet, getting in or out of a car, shopping, light household duties, and heavy household duties
- **Anesthesia and surgical interventions** were explained to the patients. A list of adverse effects was reviewed with the patients to allow for reporting of any side effect that may arise post-procedure.

12. Anesthesia

The procedures were performed under controlled local anesthesia and sedation. Dexmedetomidine 0.7 mcg/kg/hour was administered intravenously as a sedative and pain reliever. Patients were monitored for heart rate, pulse oximetry, temperature, and noninvasive blood pressure.

13. Procedures

The surgical site of liposuction was carefully chosen based on the availability of fat and the patients' wishes. Liposuction was performed under complete aseptic technique and antibiotic coverage of cefuroxime 1.5 g IV one dose, 1 hour preoperative followed by 500 mg orally every 12 hours for 7 days. Fat harvesting was obtained using 10-hole, Olivaire blunt cannula (Pouret Medical, Clichy, France) with 1 mm tip attached to a 10 mL Luer-Lok syringe (Terumo, Auburn, WA, USA). Fifty milliliters of fat micrograft was collected and then left for thirty minutes to settle and separate into various layers; the upper and lower layers were removed, while the middle layer of fat was kept for intra-articular injection (**Figure 1**).

The surgical site was prepared and injected with 100–200 mL of tumescent solution. Solution was prepared by mixing 30–50 mL of 1% lidocaine and 0.5 mg (0.5 mL) of epinephrine in 449.5 mL of lactated ringers. The osteoarthritic knee joint was injected with autologous intra-articular fat micrograft 15–20 mL through the lateral approach according to the case in an amount that did not produce high pressure inside the joint and did not produce pain to the patients due to tension of the joint capsule.

14. Postoperative advice and care

- After operation, the patient received antibiotics at home for 1 week and on regular pain killer for 2 weeks and is to start walking immediately as early as possible and increase activity as tolerated.
- Stress the preoperative advice to reduce weight, improve diet regimen, and perform regular exercise especially aqua or hydrotherapy therapy to strengthen muscle with consequently more improvement of outcome of the procedure.
- All patients were followed up in the clinic on a regular basis every 1–2 weeks in the first month and then every 3 months to assess incidence of side effects, complications, pain evaluation, stiffness and knee function problems, and recurrence of pain.
- The patient was informed that the improvement will start during the first month and increase with time, and the maximum appreciated improvement at 6 months, provided he will follow the given instructions and improve the predisposing risk and comorbid factors.

15. Statistical analysis

IBM SPSS Statistics for Windows, Version 20 (IBM Corp., Armonk, NY USA), was used for data analysis. Data were presented as mean \pm SD and minimum-maximum or number and percentage (n , %) as appropriate. Wilcoxon test for nonparametric variables was used to compare preinjection to postinjection values. A probability of ≤ 0.05 was considered significant.

16. The current study outcome of 205 patients

In this current study, we used the same methodology and patient's selection that we applied in the preliminary trial and in the main study of 80 patients indicated in the requested ethical approval, but in this chapter, we are presenting our experience in the management of 205 patients.

Table 4 showed the demographic data and the clinical characteristics of the patients. The median age of the patients was 61.59 years, and the body mass index was 35.10 kg/m². The female patients were more than male (74.10% versus 25.90%) with a ratio of 2.88:1. Only five patients (2.90%) were smoking. The associated comorbidities were obesity (74.60%), hypertension (34.60%), *diabetes mellitus* (21.50%), hypothyroidism (6.80%), rheumatoid arthritis (4.90%), low back pain (4.90%), hepatitis (2.00%), and lower limb edema (1.50%).

Parameters	Data
Age (years)	61.59 ± 10.32 (33–92)
Weight (kg)	87.25 ± 16.89 (48–164)
Height (meter)	1.56 ± 0.10 (1.14–1.86)
Body mass index (kg/m ²)	35.10 ± 5.77 (22.00–50.60)
Gender	
Male	53 (25.90%)
Female	152 (74.10%)
Smoking	5 (2.90%)
Comorbidity	
Obesity	153 (74.60%)
Hypertension	71 (34.60%)
Type 2 diabetes mellitus	44 (21.50%)
Hypothyroidism	14 (6.80%)
Rheumatoid arthritis	10 (4.90%)
Low back pain	10 (4.90%)
Lower limb edema	3 (1.50%)
Hepatitis	4 (2.00%)

Data are expressed as mean ± SD (minimum-maximum) or number (%) as appropriate.

Table 4.
 Demographic and clinical characteristics of patients (n = 205).

Parameters	Data
Disease duration (years)	8.00 ± 5.98 (1.00–33.00)
Knee affected	
Right knee	13 (6.30%)
Left knee	5 (2.40%)
Bilateral knees	187 (91.20%)
Medications	
Nonsteroidal anti-inflammatory	204 (99.50%)
Glucosamine	18 (8.80%)
Prednisone	10 (4.90%)
Methotrexate	7 (3.40%)
Relaxon	9 (4.40%)
Fat injection	
Single injection	199 (97.10%)
Two injections	5 (2.40%)
Three injections	1 (0.50%)

Data are expressed as mean ± SD (minimum-maximum) or number (%) as appropriate.

Table 5.
 Disease duration and treatment of patients (n = 205).

The duration of OA ranged from 1 to 33 years. The right knee was affected in 6.30% of patients and left knee in 2.40%, while both knees were affected in 91.20% of the cases. 99.50% of patients used NSAID, while glucosamine was used by 8.80%, prednisone by 4.90%, methotrexate by 3.40%, and relaxon by 4.40%. The number of fat injection was single in 97.10%, twice in 2.4%, or triple in 0.50% of cases (Table 5).

VAS values were significantly higher in preinjection versus postinjection both during rest (8.02 ± 1.81 versus 0.69 ± 0.64 , $p < 0.0001$) and with activity (9.53 ± 0.88 versus 1.46 ± 0.80 , $p < 0.0001$) which reflected a highly significant improvement in OA pain (Table 6 and Figure 3).

Table 7 presented the Western Ontario and McMaster Universities Osteoarthritis Index before and after intra-articular fat micrograft injection. The three domains of WOMAC index, pain, stiffness, and physical function, were significantly lower in the post intra-articular fat injection period than the preinjection values. The total score of WOMAC test and its percentage were significantly lower in the post intra-articular fat injection period than the preinjection values (77.65 ± 11.84 versus 5.69 ± 4.60 , $p < 0.0001$; 80.89 ± 12.34 versus 5.93 ± 4.79 , $p < 0.0001$) (Table 7 and Figures 4–7).

Visual analogue scale	Preinjection	Postinjection	Significance (P-value)
Rest	8.02 ± 1.81 (2.00–10.00)	0.69 ± 0.64 (0.00–4.00)	0.0001
Exercise	9.53 ± 0.88 (6.00–10.00)	1.46 ± 0.80 (0.00–5.00)	0.0001

Table 6. Visual analogue scale values at rest and with activity before and after intra-articular fat micrograft injection.

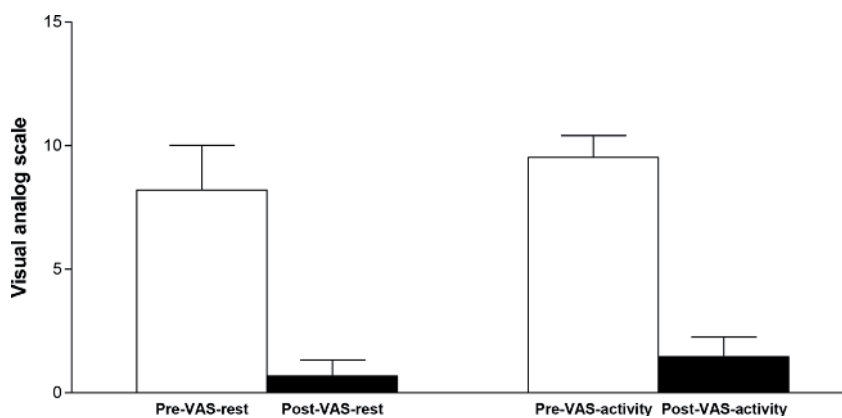


Figure 3. Visual analogue scale values at rest and with activity before and after intra-articular fat micrograft injection.

Western Ontario and McMaster Universities Osteoarthritis Index	Preinjection	Postinjection	Significance (P-value)
Pain			
1. Walking	3.85 ± 0.401 (2.00–4.00)	0.65 ± 0.52 (0.00–2.00)	0.0001
2. Stair climbing	3.95 ± 0.24 (2.00–4.00)	0.98 ± 0.40 (0.00–2.00)	0.0001
3. Nocturnal	3.36 ± 0.76 (0.00–4.00)	0.25 ± 0.50 (0.00–4.00)	0.0001
4. Rest	3.15 ± 0.79 (0.00–4.00)	0.11 ± 0.32 (0.00–1.00)	0.0001
5. Weight-bearing	3.94 ± 0.29 (2.00–5.00)	0.96 ± 0.45 (0.00–2.00)	0.0001
Stiffness			
6. Morning stiffness	3.103 ± 0.89 (0.00–4.00)	0.20 ± 0.40 (0.00–1.00)	0.0001

Western Ontario and McMaster Universities Osteoarthritis Index	Preinjection	Postinjection	Significance (P-value)
7. Stiffness occurring later in the day	2.04 ± 1.17 (0.00–4.00)	0.14 ± 0.35 (0.00–1.00)	0.0001
Physical function			
8. Descending stairs	3.90 ± 0.34 (2.00–4.00)	0.93 ± 0.36 (0.00–2.00)	0.0001
9. Ascending stairs	3.92 ± 0.32 (2.00–4.00)	0.94 ± 0.45 (0.00–4.00)	0.0001
10. Rising from sitting	3.28 ± 0.76 (1.00–4.00)	0.20 ± 0.47 (0.00–4.00)	0.0001
11. Standing	3.52 ± 0.69 (1.00–4.00)	0.47 ± 0.58 (0.00–4.00)	0.0001
12. Bending to floor	3.09 ± 0.86 (0.00–4.00)	0.22 ± 0.43 (0.00–2.00)	0.0001
13. Walking on flat surface	3.20 ± 0.75 (1.00–4.00)	0.21 ± 0.41 (0.00–1.00)	0.0001
14. Getting in/out of car	3.40 ± 0.80 (1.00–4.00)	0.64 ± 0.54 (0.00–2.00)	0.0001
15. Going shopping	3.87 ± 0.41 (2.00–4.00)	1.02 ± 0.52 (0.00–2.00)	0.0001
16. Putting on socks	2.62 ± 0.84 (0.00–4.00)	0.22 ± 0.41 (0.00–1.00)	0.0001
17. Lying in bed	2.80 ± 0.91 (0.00–4.00)	0.12 ± 0.32 (0.00–1.00)	0.0001
18. Taking off socks	2.16 ± 0.86 (0.00–4.00)	0.05 ± 0.22 (0.00–1.00)	0.0001
19. Rising from bed	2.86 ± 0.86 (0.00–4.00)	0.14 ± 0.34 (0.00–1.00)	0.0001
20. Getting in/out of bath	3.84 ± 0.60 (0.00–4.00)	1.17 ± 0.60 (0.00–2.00)	0.0001
21. Sitting	2.95 ± 0.78 (0.00–4.00)	0.14 ± 0.40 (0.00–3.00)	0.0001
22. Getting on/off toilet	2.65 ± 0.79 (1.00–4.00)	0.14 ± 0.36 (0.00–2.00)	0.0001
23. Heavy domestic duties	3.91 ± 0.40 (1.00–4.00)	1.15 ± 0.53 (0.00–4.00)	0.0001
24. Light domestic duties	2.35 ± 0.76 (0.00–4.00)	0.04 ± 0.22 (0.00–2.00)	0.0001
Total score			
Out of 96	77.65 ± 11.84 (32.00–96.00)	5.69 ± 4.60 (0.00–24.00)	0.0001
Percentage (%)	80.89 ± 12.34 (33.33–100.00)	5.93 ± 4.79 (0.00–25.25)	0.0001

The activities in each category are rated according to the following scale of difficulty: 0 = none; 1 = slight; 2 = moderate; 3 = very; 4 = extremely. Data are expressed as mean ± SD (minimum-maximum). Wilcoxon test for nonparametric variables was used to compare pre- to postinjection values.

Table 7.
 The Western Ontario and McMaster Universities Osteoarthritis Index before and after intra-articular fat micrograft injection.

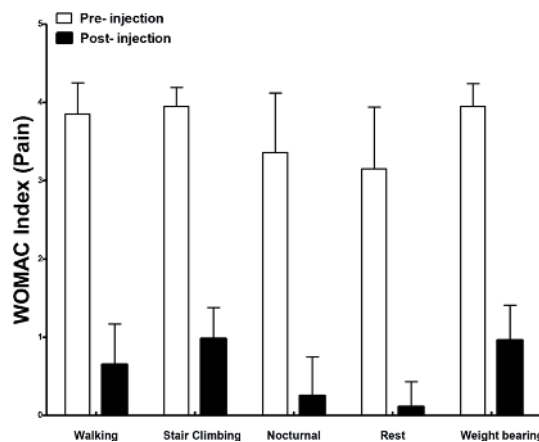


Figure 4.
 The Western Ontario and McMaster Universities Osteoarthritis Index Pain before and after intra-articular fat micrograft injection.

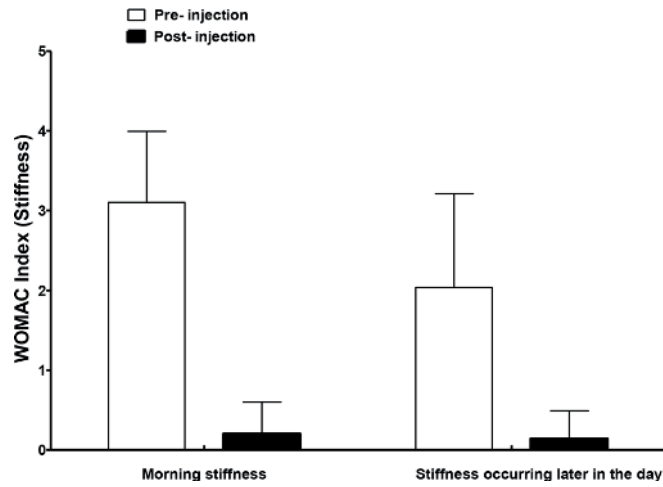


Figure 5. The Western Ontario and McMaster Universities Osteoarthritis Index Stiffness before and after intra-articular fat micrograft injection.

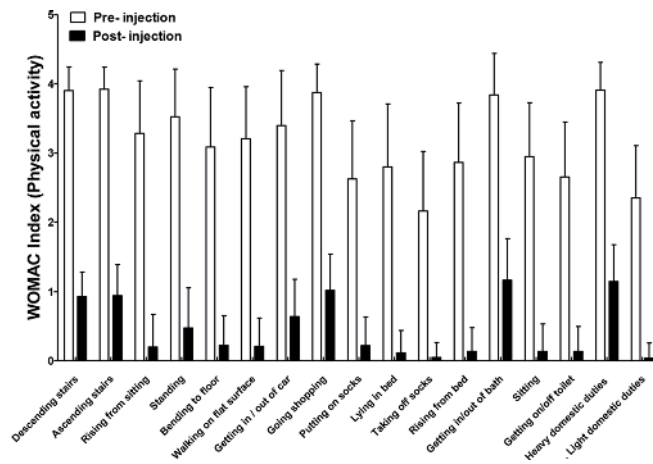


Figure 6. The Western Ontario and McMaster Universities Osteoarthritis Index Physical activity before and after intra-articular fat micrograft injection.

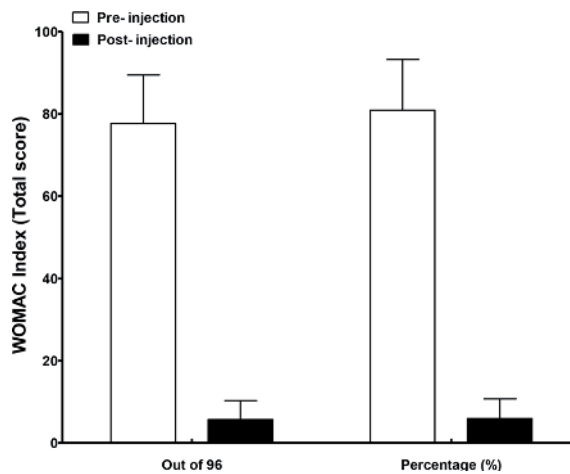


Figure 7. The Western Ontario and McMaster Universities Osteoarthritis Index Total Score before and after intra-articular fat micrograft injection.

Wilcoxon test for nonparametric variables was used to compare pre- to postinjection values.

17. Complications

We did have complication like infection or graft rejection; it was well tolerated because it is autologous.

18. Conclusion

Over 10 years our clinical study of treatment of chronic osteoarthritis using intra-articular injection of autologous fat micrograft offers an effective and safe treatment as a nonantigenic, lubricating, regenerative, and reparative modality which helps to restore the damaged cartilages and in turn improve joint pain, mobility, and other functions of the osteoarthritic joints; it is minimally invasive, without scars, and with lower cost than other lines of therapy, improves the quality of life, and is mostly effective with single injection, but reinjection is needed in some patients according to disease severity and chronicity. We found a selection of patients and preoperative correction of risk factors, e.g., obesity muscle weakness led to better outcome of the procedure.

Conflict of interest

The authors have no conflict of interest.

Disclosure

The authors did not receive any type of commercial support either in forms of compensation or financial support for this study. The authors have no financial interest in any of the products or devices or drugs mentioned in this article.

Ethical approval

The study design was reviewed and approved by the Unit of Biomedical Ethics Research Committee at King Abdulaziz University.

Author details

Sabah S. Moshref^{1*}, Yasir S. Jamal¹, Amro M. Al-Hibshi² and Abdullah M. Kaki³

1 Department of Surgery, Faculty of Medicine, King Abdulaziz University Hospital, Jeddah, Saudi Arabia

2 Department of Orthopedics, Faculty of Medicine, King Abdulaziz University Hospital, Jeddah, Saudi Arabia

3 Department of Anesthesia and Critical Care, Faculty of Medicine, King Abdulaziz University Hospital, Jeddah, Saudi Arabia

*Address all correspondence to: dr.sabahmoshref@gmail.com

IntechOpen

© 2019 The Author(s). Licensee IntechOpen. This chapter is distributed under the terms of the Creative Commons Attribution License (<http://creativecommons.org/licenses/by/3.0>), which permits unrestricted use, distribution, and reproduction in any medium, provided the original work is properly cited. 

References

- [1] Neuber G. Gustav Adolf Neuber (24 June 1850-13 April 1932) was a German surgeon born in Tondern (today-Tønder. Wir Kieler)
- [2] Lexer E. Fettegewebe verpflanzung. In: Lexer E. Die freien Transplantation en. I Teil. Stuttgart: Enke; 1919. pp. 264-547
- [3] Zuk PA, Zhu M, Mizuno H, Huang J, Futrell JW, Katz AJ, et al. Multilineage cells from human adipose tissue: Implications for cellbased therapies. *Tissue Engineering*. 2001;7:211-228
- [4] Rigotti G, Marchi A, Galie M, Baroni G, Benati D, Krampera M, et al. Clinical treatment of radiotherapy tissue damage by lipoaspirate transplant: A healing process mediated by adipose-derived adult stem cells. *Plastic and Reconstructive Surgery*. 2007;119:1409-1422
- [5] Liu Y, Wu J, Zhu Y, Han J. Therapeutic application of mesenchymal stem cells in bone and joint diseases. *Clinical and Experimental Medicine*. 2014;14(1): 13-24. DOI: 10.1007/s10238-012-0218-1. Epub: 3 November 2012 (Review)
- [6] Moshref S, Jamal Y, Hummdi L, Kaki A, Al-Hibshi A. Intra-articular injection of autologous fat micro graft in sheep hind knee joints. *Life Science Journal*. 2013;10(4):2115-2120. (ISSN: 1545-1003). Available from: <http://www.lifesciencesite.org>. 281
- [7] Moshref S, Kaki A, Al-Hibshi A, Jamal YS. Intra-articular injection of autologous fat micro-graft for the treatment of knee osteoarthritis: Preliminary experience. *Life Science Journal*. 2014;11(2):55-60
- [8] Sun HB. Mechanical loading, cartilage degradation, and arthritis. *Annals of the New York Academy of Sciences*. 2010;1211:37-50
- [9] The National Collaborating Centre for Chronic Conditions: Osteoarthritis. National clinical guideline for care and management in adults. Available from: www.nice.org.uk/nicemedia/pdf/CG59NICEguideline.pdf
- [10] Goldring SR, Goldring MB. Bone and cartilage in osteoarthritis: Is what's best for one good or bad for the other? *Arthritis Research and Therapy*. 2011;12:143
- [11] Aigner T, Rose J, Martin J, Buckwalter J. Aging theories of primary osteoarthritis: From epidemiology to molecular biology. *Rejuvenation Research*. 2004;7:134-145
- [12] Mobasheri A. Applications of proteomics to osteoarthritis, a musculoskeletal disease characterized by aging. *Frontiers in Physiology*. 2011;2:108
- [13] Gharbi M, Deberg M, Henrotin Y. Application for proteomic techniques in studying osteoarthritis: A review. *Frontiers in Physiology*. 2011;2:90
- [14] Hunter DJ. Lower extremity osteoarthritis management needs a paradigm shift. *British Journal of Sports Medicine*. 2011;45:283-288
- [15] Wilson DR, McWalter EJ, Johnston JD. The measurement of joint mechanics and their role in osteoarthritis genesis and progression. *Rheumatic Diseases Clinics of North America*. 2013;39(1):21-44. DOI: 10.1016/j.rdc.2012.11.002
- [16] Schroepel JP, Crist JD, Anderson HC, Wang J. Molecular regulation of articular chondrocyte function and its significance in osteoarthritis. *Histology and Histopathology*. 2011;26(3):377-394
- [17] Chen FH, Tuan RS. Mesenchymal stem cells in arthritic diseases. *Arthritis Research and Therapy*. 2008;10(5):223

- [18] Pendleton A, Arden N, Dougados M, et al. EULAR recommendations for the management of knee osteoarthritis: Report of a task force of the Standing Committee for International Clinical Studies Including Therapeutic Trials (ESCISIT). *Annals of the Rheumatic Diseases*. 2000;**59**(12):936-944
- [19] Hernández-Díaz S, García-Rodríguez LA. Epidemiologic assessment of the safety of conventional nonsteroidal anti-inflammatory drugs. *The American Journal of Medicine*. 2001;**110**(Suppl 3):20S-27S
- [20] Flood J. The role of acetaminophen in the treatment of osteoarthritis. *The American Journal of Managed Care*. 2010;**16**(Suppl Management):S48-S54
- [21] Hameed F, Ihm J. Injectable medications for osteoarthritis. *PM and R: The Journal of Injury, Function, and Rehabilitation*. 2012;**4**(5 Suppl):S75-S81
- [22] Miller LE, Block JE. US-approved intra-articular hyaluronic acid injections are safe and effective in patients with knee osteoarthritis: Systematic review and meta-analysis of randomized, saline-controlled trials. *Clinical Medicine Insights: Arthritis and Musculoskeletal Disorders*. 2013;**6**:57-63
- [23] Rudzinski M. What Are Optimal Strategies in the Management of Osteoarthritis? *Medscape Family Medicine*. May 2001. Available at: <http://www.medscape.com/viewarticle/413591> [Accessed: February 2016]
- [24] Spaková T, Rosocha J, Lacko M, Harvanová D, Gharaibeh A. Treatment of knee joint osteoarthritis with autologous platelet-rich plasma in comparison with hyaluronic acid. *American Journal of Physical Medicine & Rehabilitation*. 2012;**91**(5):411-417
- [25] Douleh D, Frank RM. Marrow stimulation: Microfracture, drilling, and abrasion. *Operative Techniques in Sports Medicine*. 2018;**26**(3):170-174
- [26] Malchau H, Herberts P, Garellick G, Soderman P, Eisler T. Prognosis of total hip replacement: Update of results and risk-ratio analysis for revision and re-revision from the Swedish National Hip Arthroplasty Register 1979-2000. In: Scientific Exhibition. Presented at: 69th Annual Meeting of the American Academy of Orthopaedic Surgeons; 11-15 June 2002; Dallas, TX, USA
- [27] Santaguida PL, Hawker GA, Hudak PL, et al. Patient characteristics affecting the prognosis of total hip and knee joint arthroplasty: A systematic review. *Canadian Journal of Surgery*. 2008;**51**(6):428-436
- [28] Roberts S, Genever P, McCaskie A. Prospects of stem cell therapy in osteoarthritis. *Regenerative Medicine*. 2011;**6**(3):351-366. DOI: 10.2217/RME.11.21
- [29] Vinatier C, Bouffi C, Merceron C, Gordeladze J, Brondello JM, Jorgensen C, et al. Cartilage tissue engineering: Towards a biomaterial-assisted mesenchymal stem cell therapy. *Current Stem Cell Research & Therapy*. 2009;**4**(4):318-329
- [30] Oh W, Kim DS, Yang YS, Lee JK. Immunological properties of umbilical cord blood-derived mesenchymal stromal cells. *Cellular Immunology*. 2008;**251**:116-123
- [31] Di Nicola M, Carlo-Stella C, Magni M, Milanese M, Longoni PD, Matteucci P, et al. Human bone marrow stromal cells suppress T-lymphocyte proliferation induced by cellular or nonspecific mitogenic stimuli. *Blood*. 2002;**99**:3838-3843
- [32] Ren G, Su J, Zhang L, Zhao X, Ling W, L'huillie A, et al. Species variation in the mechanisms of mesenchymal stem cell-mediated immunosuppression. *Stem Cells*. 2009;**27**:1954-1962

- [33] Beyth S, Borovsky Z, Mevorach D, Liebergall M, Gazit Z, Aslan H, et al. Human mesenchymal stem cells alter antigen-presenting cell maturation and induced T-cell unresponsiveness. *Blood*. 2005;**105**:2214-2219
- [34] Salibian AA, Widgerow AD, Abrouk M, Evans GRD. Stem cells in plastic surgery: A review of current clinical and translational applications. *Archives of Plastic Surgery*. 2013;**40**:666-675. Available from: <http://dx.doi.org/10.5999/aps.2013.40.6.666> [Accepted: 25 September 2013] pISSN: 2234-6163, eISSN: 2234-6171
- [35] Walia B, Satija N, Tripathi RP, et al. Induced pluripotent stem cells: Fundamentals and applications of the reprogramming process and its ramifications on regenerative medicine. *Stem Cell Reviews*. 2012;**8**:100-115
- [36] Caplan AI, Dennis JE. Mesenchymal stem cells as trophic mediators. *Journal of Cellular Biochemistry*. 2006;**98**(5):1076-1084
- [37] Lodi D, Iannitti T, Palmieri B. Stem cells in clinical practice: Applications and warnings. *Journal of Experimental & Clinical Cancer Research*. 2011;**30**:9
- [38] Caplan AI. Review: Mesenchymal stem cells: Cell-based reconstructive therapy in orthopedics. *Tissue Engineering*. 2005;**11**(7-8):1198-1211
- [39] da Silva ML, Chagatelles PC, Nardi NB. Mesenchymal stem cells reside in virtually all post-natal organs and tissues. *Journal of Cell Science*. 2006;**119**:2204-2213
- [40] Campagnoli C, Roberts IA, Kumar S, Bennett PR, Bellantuono I, Fisk NM. Identification of mesenchymal stem/progenitor cells in human first-trimester fetal blood, liver, and bone marrow. *Blood*. 2001;**98**:2396-2402
- [41] Kim JY, Jeon HB, Yang YS, Oh W, Chang JW. Application of human umbilical cord blood-derived mesenchymal stem cells in disease models. *World Journal of Stem Cells*. 2010;**2**:34-38
- [42] Rodriguez AM, Elabd C, Amri EZ, Aihaud G, Dani C. The human adipose tissue is a source of multipotent stem cells. *Biochimie*. 2005;**87**:125-128
- [43] Ilancheran S, Moodley Y, Manuelpillai U. Human fetal membranes: A source of stem cells for tissue regeneration and repair? *Placenta*. 2009;**30**:2-10
- [44] Vishnubalaji R, Al-Nbaheen M, Kadalmani B, Aldahmash A, Ramesh T. Comparative investigation of the differentiation capability of bone-marrow-and adipose-derived mesenchymal stem cells by qualitative and quantitative analysis. *Cell and Tissue Research*. 2012;**347**:419-427
- [45] Guilak F, Awad HA, Fermor B, Leddy HA, Gimple JM. Adipose-derived adult stem cells for cartilage tissue engineering. *Biorheology*. 2004;**41**:389-399
- [46] Murphy JM, Fink DJ, Hunziker EB, Barry FP. Stem cell therapy in a caprine model of osteoarthritis. *Arthritis and Rheumatism*. 2003;**48**:3464-3474
- [47] Guo X, Wang X, Zhang Y, Xia R, Hu M, Duan C. Repair of large articular cartilage defects with implants of autologous mesenchymal stem cells seeded into beta-tricalcium phosphate in a sheep model. *Tissue Engineering*. 2004;**10**:1818-1829
- [48] JHP H, Chen F, Thambyah A, Lee EH. Treatment of chondral lesions in advanced osteochondritis dissecans: a comparative study of the efficacy of chondrocytes, mesenchymal stem cells, periosteal graft, and mosaicplasty (osteochondral autograft) in animal models. *Journal of Pediatric Orthopedics*. 2004;**24**:427-433

- [49] Liu Y, Shu XZ, Prestwich GD. Osteochondral defect repair with autologous bone marrow-derived mesenchymal stem cells in an injectable, in situ, cross-linked synthetic extracellular matrix. *Tissue Engineering*. 2006;**12**:3405-3416
- [50] Kayakabe M, Tsutsumi S, Watanabe H, Kato Y, Takagishi K. Transplantation of autologous rabbit BM-derived mesenchymal stromal cells embedded in hyaluronic acid gel sponge into osteochondral defects of the knee. *Cytotherapy*. 2006;**8**:343-353
- [51] Yan H, Yu C. Repair of full-thickness cartilage defects with cells of different origin in a rabbit model. *Arthroscopy*. 2007;**23**:178-187
- [52] Lee KBL, Hui JHP, Song IC, Ardany L, Lee EH. Injectable mesenchymal stem cell therapy for large cartilage defects—A porcine model. *Stem Cells*. 2007;**25**:2964-2971
- [53] Kuroda R, Ishida K, Matsumoto T, Akisue T, Fujioka H, Mizuno K. Treatment of a full-thickness articular cartilage defect in the femoral condyle of an athlete with autologous bone marrow stromal cells. *Osteoarthritis and Cartilage*. 2007;**15**:226-231
- [54] Black LL, Gaynor J, Adams C, Dhupa S, Sams AE, Taylor R, et al. Effect of intraarticular injection of autologous adipose-derived mesenchymal stem and regenerative cells on clinical signs of chronic osteoarthritis of the elbow joint in dogs. *Veterinary Therapeutics*. 2008;**9**:192-200
- [55] Black LL, Gaynor J, Gahring D, Adams C, Aron D, Harman S, et al. Effect of adipose-derived mesenchymal stem and regenerative cells on lameness in dogs with chronic osteoarthritis of the coxofemoral joints: A randomized, double-blinded, multicenter, controlled trial. *Veterinary Therapeutics*. 2007;**8**:272-284
- [56] Noth U, Steinert AF, Tuan RS. Technology insight: Adult mesenchymal stem cells for osteoarthritis therapy: Delivery modes for mesenchymal stem cells. *Nature Clinical Practice. Rheumatology*. 2008;**4**:371-380
- [57] Horie M, Sekiya I, Muneta T, Ichinose S, Matsumoto K, Saito H, et al. Intra-articular injected synovial stem cells differentiate into meniscal cells directly and promote meniscal regeneration without mobilization of distant organs in rat massive meniscal defect. *Stem Cells*. 2009;**27**:878-887
- [58] Mokbel AN, El Tookhy OS, Shamaa AA, Rashed LA, Sabry D, El Sayed AM. Homing and reparative effect of intra-articular injection of autologous mesenchymal stem cells in osteoarthritic animal model. *BMC Musculoskeletal Disorders*. 2011;**12**:259
- [59] Sato M, Uchida K, Nakajima H, Miyazaki T, Guerrero AR, Watanabe S, et al. Direct transplantation of mesenchymal stem cells into the knee joints of Hartley strain guinea pigs with spontaneous osteoarthritis. *Arthritis Research and Therapy*. 2012;**14**:R31
- [60] Ameye LG, Young MF. Animal models of osteoarthritis: Lessons learned while seeking the 'Holy Grail'. *Current Opinion in Rheumatology*. 2006;**18**:537-547
- [61] Desando G, Cavallo C, Sartoni F, Martini L, Parrilli A, Veronesi F, et al. Intra-articular delivery of adipose derived stromal cells attenuates osteoarthritis progression in an experimental rabbit model. *Arthritis Research and Therapy*. 2013;**15**:R22. DOI: 10.1186/ar4156
- [62] van Lent PLEM, van den Berg WB. Mesenchymal stem cell therapy in osteoarthritis: Advanced tissue repair or intervention with smouldering synovial activation? *Arthritis Research and Therapy*. 2013;**15**:112

- [63] Hou T, Xu J, Wu X, Xie Z, Luo F, Zhang Z, et al. Umbilical cord Wharton's Jelly: A new potential cell source of mesenchymal stromal cells for bone tissue engineering. *Tissue Engineering. Part A*. 2009;**15**:2325-2334
- [64] Fan CG, Zhang QJ, Zhou JR. Therapeutic potentials of mesenchymal stem cells derived from human umbilical cord. *Stem Cell Reviews*. 2011;**7**:195-207
- [65] Fong CY, Subramanian A, Gauthaman K, Venugopal J, Biswas A, Ramakrishna S, et al. Human umbilical cord Wharton's Jelly stem cells undergo enhanced chondrogenic differentiation when grown on nanofibrous scaffolds and in a sequential two-stage culture medium environment. *Stem Cell Reviews*. 2012;**8**:195-209
- [66] Moshref S, Jamal S, Al-Hibshi A, Kaki A. Intra-articular injection of autologous fat graft for the treatment of knee osteoarthritis. *Life Science Journal*. 2017;**14**(4):30-35. DOI: 10.7537/marslsj140417.05. ISSN: 1097-8135 (Print)/ISSN: 2372-613X (Online). Available from: <http://www.lifesciencesite.com>
- [67] Kon E, Filardo G, Roffi A, Andriolo L, Marcacci M. New trends for knee cartilage regeneration: From cell-free scaffolds to mesenchymal stem cells. *Current Reviews in Musculoskeletal Medicine*. 2012;**5**(3, 243):236
- [68] Madry H, Grun UW, Knutsen G. Cartilage repair and joint preservation: Medical and surgical treatment options. *Deutsches Arzteblatt International Impact Factor*. 2011;**108**(40):669-677
- [69] Filardo G, Madry H, Jelic M, Roffi A, Cucchiaroni M, Kon E. Mesenchymal stem cells for the treatment of cartilage lesions: From preclinical findings to clinical application in orthopaedics. *Knee Surgery, Sports Traumatology, Arthroscopy*. 2013;**21**:1717-1729. DOI: 10.1007/s00167-012-2329-3
- [70] Wakitani S, Imoto K, Yamamoto T, Saito M, Murata N, Yoneda M. Human autologous culture expanded bone marrow mesenchymal cell transplantation for repair of cartilage defects in osteoarthritic knee. *Osteoarthritis and Cartilage*. 2002;**10**:199-206
- [71] Ohgushi H, Kotobuki N, Funaoka H, Machida H, Hirose M, Tanaka Y, et al. Tissue engineered ceramic artificial joint—Ex vivo osteogenic differentiation of patient mesenchymal cells on total ankle joints for treatment of osteoarthritis. *Biomaterials*. 2005;**26**:4654-4661
- [72] Centeno CJ, Busse D, Kisiday J, Keohan C, Freeman M, Karli D. Increased knee cartilage volume in degenerative joint disease using percutaneously implanted, autologous mesenchymal stem cells. *Pain Physician*. 2008;**11**:343-353
- [73] Buda R, Vannini F, Cavallo M, Grigolo B, Cenacchi A, Giannini S. Osteochondral lesions of the knee: A new one-step repair technique with bone-marrow-derived cells. *The Journal of Bone and Joint Surgery American Volume*. 2010;**92**(Suppl 2):2-11
- [74] Pak J. Regeneration of human bones in hip osteonecrosis and human cartilage in knee osteoarthritis with autologous adipose-tissue-derived stem cells: A case series. *Journal of Medical Case Reports*. 2011;**5**:296
- [75] Koh YG, Choi YJ. Infrapatellar fat pad-derived mesenchymal stem cell therapy for knee osteoarthritis. *The Knee*. 2012;**19**(6):902-907
- [76] Davatchi F, Abdollahi BS, Mohyeddin M, Shahram F, Nikbin B. Mesenchymal stem cell therapy for knee

osteoarthritis. Preliminary report of four patients. *International Journal of Rheumatic Diseases*. 2011;**14**:211-215

[77] Koh YG, Jo SB, Kwon OR, Suh DS, Lee SW, Park SH, et al. Mesenchymal stem cell injections improve symptoms of knee osteoarthritis. *Arthroscopy: The Journal of Arthroscopic and Related Surgery: Official Publication of the Arthroscopy Association of North America and the International Arthroscopy Association*. 2013;**29**(4):748-755

[78] Koh YG, Choi YJ, Kwon SK, Kim YS, Yeo JE. Clinical results and second-look arthroscopic findings after treatment with adipose-derived stem cells for knee osteoarthritis. *Knee Surgery, Sports Traumatology, Arthroscopy*. 2015;**23**(5):1308-1313