

---

# What is a Low Frequency of the Disseminated Cysticercosis Suggests that Neurocysticercosis is Going to Disappear?

---

Humberto Foyaca Sibat and Lourdes de Fátima Ibañez Valdés

Additional information is available at the end of the chapter

<http://dx.doi.org/10.5772/51395>

---

## 1. Introduction

The zoonotic infections that affect the man can be caused by viruses (rabies, avian influenza, immunodeficiency virus from apes [VIS]), bacteria (brucellosis, salmonellosis), parasites (leishmaniasis and schistosomiasis, neurocysticercosis, toxocariasis) and other non-conventional agents such as prions (bovine spongiform encephalopathy and a variant of Jakob-Creutzfeldt disease) on which enough has been written[1].

There are 1407 pathogens that affect humans (excluding the ectoparasites), more than half (816) are zoonotic and 73% (130) cause zoonotic diseases that affect community health [2]. Parasitic diseases have occurred through the times more deaths and economic damage to humanity that all the genocidal wars together. Parasitic infections previously seen only in developing tropical settings can be currently diagnosed worldwide due to travel and population migration. Generally in countries with little socio-economic development is where parasitic diseases are presented with greater frequency, still this is offered by climatic conditions warm or temperate zone and by the lack of education for health in the population; because in the developed countries social, medical and economically, parasitic diseases have been eradicated or have very little significance [3].

Neurocysticercosis (NCC) is the parasitic disease more frequent of the CNS and the causal agent of the same is the larval stage of the *T solium* cysticerci when invades brain of a human being that has swallowed the viable eggs from food or contaminated liquids, from a carrier, by infection secondary to a reverse peristalsis or by the well-known fecal-oral route [4-6]. The man is in turn the only known host for the adult form of the parasite. This disease is a serious health problem for many third-world countries of Asia, Africa, and Latin America; moreover, a growing number of cases are being reported in many highly developed countries in Europe and North America, notwithstanding the foregoing, the

incidence and prevalence accurate of this disease have not been confirmed from well-designed studies. Disseminated cysticercosis (DCC) was reported in 1912 by doctors of the English Navy stationed in India. Priest in 1926, describes a British soldier patient presenting an inflammation of the skeletal muscles, seizures, mental dulling and a large amount of subcutaneous nodules distributed throughout the body [7]. An intensive search performed in 1988 revealed 22 cases [7] and only 16 additional cases were reported until 2006 reported in the international medical literature most of them from India. [8]. It is considered that cysticercosis (CC) is a major problem for public health in several developing countries where the social, economic and cultural conditions favor the maintenance of this zoonotic disease and it is seen as a growing community problem in those developed countries with a high rate of immigrants from endemic areas. WHO includes the NCC between neglected diseases that cause a significant impact on the economy in several regions of the world. It affects 4% of the population in endemic areas [4, 9] and is the main cause of symptomatic epilepsy worldwide [1, 10-15] but where the hygiene habits-food and sometimes religious trends can determine the incidence and prevalence of the disease [1].

Based in our experience and according to this review of the literature we can say that in regions where the CC is endemic, the presence of late onset seizures in subjects older than 25 years of age is highly suggestive of NCC what had already been established since 1982 [16]. In the published series, the age group most commonly affected by the NCC, is the group of 35 to 63 years [18-20]. The males are most affected than females in the majority of the studies [17-19]. In 2003, Mafojane [20] reported a high prevalence in children and young South Africans in a region where the CC virtually does not exist.

Probably, there is a progressive decrease incidence of DCC based in our local perception and disseminated cysticercosis is always associated with NCC but it does not mean that the NCC is on the way to disappear completely in the next decade. In this chapter we will present a bibliographic investigation on the DCC, its prevalence in our region, and our arguments on the because we are going to spend many years before that the DCC eradicated from the face of the earth.

The pathogenesis and clinical manifestations of CC depend on the number, size, location, evolutionary state of the parasite and the host's immune response [1,5,10-15, 21-23]. In the above-mentioned studies, appear only the seizures and the headache as initial clinical manifestations while in others it is reported: meningitis, dementia, intracranial Hypertension, psychiatric symptoms, ischemic stroke, and radicular compression [10-15,17, 24-30]. It is important to note that the headache is not the most frequent clinical manifestation of the NCC in the majority of published studies but that occupies the second place; only in one of the studies consulted is presented as the main reason for consultation [19]. In the majority of the series, the frequency of headache varies from 4.6 % to 61.5 % [19,23-24]. While the frequency of seizures as a form of presentation of the NCC ranges from 54.3 % to 62.5 % in general series [12, 23, 27, 31-34]. In children the frequency of seizures to be the initial manifestation is higher, ranging from 72% to 94.8 % according to other authors [29, 35]. In summary, the majority of published studies confirm that the epilepsy and headache were the most frequent clinical manifestations of the NCC [1,10-15, 17, 24, 27-30,

36]. These manifestations begin between one and 35 years after the exposure to the parasite, as demonstrated in patients from the British army stationed in India where it is defined exactly the time of exposure to the parasite and the onset of clinical manifestations. The average life Expectancy of the parasite is estimated to be between four and five years [37]. The epilepsy secondary to NCC (ESNCC) responds well to first line antiepileptic drugs (AED) [1,10-15, 19,24, 28,31, 33, 38]. Other AED as the levetiracetam has also shown good results, but its high cost and lack of availability in the public sector and the primary health care system make it considered without practical usefulness for the control of the ESNCC [1]. Patients with DCC can present: refractory epilepsy, neuropsychiatric disturbances, pseudo hypertrophy in the four limbs and affection of any other organ or system [8]. However, a fairly typical manifestation of the DCC is the subcutaneous cyst that occurs as a asymptomatic nodule. These subcutaneous nodules can be slide easily in the muscle tissue and measure up to 1.5 cm in diameter. In the case of patients who have suffered from the disease for more than five years, usually these are calcified [39].

Recently, Bielsa-Fernández [40] reported a patient carrier of severe rheumatic polymyalgia of the trunk and limbs with serological surveys negative for the CC and two muscle biopsy confirmed encapsulated nodules with diffuse calcification, compatible with parasitic diseases, whose state of calcification prevented identify the characteristics of the parasite. Logically, the presence of active NCC leaves no doubt about the nature of the subcutaneous nodules and reinforces the importance of bearing in mind the diagnostic criteria of Del Brutto for the correct differential diagnosis [41].

The main characteristic the DCC is structural epilepsy due to neurocysticercosis and the pseudo-hypertrophy in the four members and the allocation of any other organ or system [8]. However, a manifestation fairly typical of the DCC may be subcutaneous cyst that occurs as a nodule asymptomatic. These subcutaneous nodules can be sliders in the muscle and measure up to 1.5 cm. In the case of patients who have had for more than 5 years cysticerci, these are calcified [39]. A few months ago, Bielsa-Fernández [40] reported a female patient with a severe rheumatic polymyalgia of the trunk and limbs with serological studies for the CC negative and two muscle biopsy confirmed two nodes encapsulated with diffuse calcification, compatible with parasitosis, whose calcification of the content made it difficult determine the type of parasite. Logically, the presence of NCC active leaves no doubt about the nature of the subcutaneous nodules.

The pharmacological treatment of DCC reported good results for some patients with subcutaneous and muscular involvement if the CNS is not severely affected [41, 42]. On the other hand, have been confirmed cases with DCC and chronic liver disease in which case even if the ELISA test was suggestive, the final diagnosis was obtained by CT scans of the brain [43], and have been reported cases with unilateral eye lesion [44], and even bilaterally [80], thyroid involvement [8, 45], pancreatic enzyme alterations [46] or without clinical or biochemical alterations of pancreatic function [47], spleen damage [47,47], cardiac [8, 48-53], even without associated DCC [52], lung [45, 53-55], joints [56] and muscles of the face and neck [44, 48]. There is not reported cases of DCC without involvement of CNS and its frequency may be the expression of an increase or decrease in the overall prevalence of

porcine cysticercosis in general [1]. The host inflammatory response depends on the parasite's ability to evade host immunity. Usually both 'healthy' (active) and 'involved' (inactive) cysticerci lack inflammatory response, which is restricted to 'currently degenerating' cysts whose ability to evade host defenses is becoming faulty. Involution of cysts implies granulomatous inflammation [56].

Epilepsy is the most common neurological manifestation of DCC in our region and it has been well documented in previous publication. [41,50] However seizures disorder in HIV patients present special problem with regard to choice of antiepileptic drugs (AED) and the potential for drug-drug interactions with antiretroviral (ARV) treatments also in our region. Newer AEDs with simpler pharmacokinetic profiles may be the preferred agents, particularly when protease inhibitors form part of ARV regimens. Seizures in NCC are easily controlled with the first line AEDs. Although there has been some debate about the value of anti-parasitic drugs in NCC, accumulating data suggest that the use of these agents in active disease decreases the risk for development of chronic epilepsy [57].

## 2. Methodology

In this chapter we included only cases reported to the medical literature, therefore no major ethical problems are afforded. Nevertheless, in order to protect all subjects participating in our studies, as part of a general measure aimed at protecting patients selected it was agreed that the principal investigator (HFS) and collaborators (LdeFIV) should adopt a program of basic training on the protection of human beings and animals participating in research studies and obtain the corresponding certificate which was done. All protocols were approved by the Review Committee from the University of Transkei and the Walter Sisulu University plus their respective Committee on Medical Ethics and the numbers of references are the following: Mthatha Hospital (UGH: 0001/99, letter of approval by the Director of Medical Services), University of Transkei (UNITRA:0018/05), and Walter Sisulu University (IRB) and their respective Ethics Committee (WSU:0068/09). The model of informed consent was signed by all participants in the first contact as a prerequisite to participate. To illiterate patients were explained the objectives of the study, the procedures which were to be subjected and their risks and the model of consent was signed by a family member, relative or a witness. To all patients we explained their rights to participate or not, with the assurance that in any case, this would not cause change in management or the attention of the same or other rights of any patient, their rights on anonymity (personal data replaced by keys), and to keep any information in strict confidentiality. In this chapter we did not use any graphical or written confidential information from patients reported by other author.

## 3. Results

### 3.1. Disseminated cysticercosis in South Africa

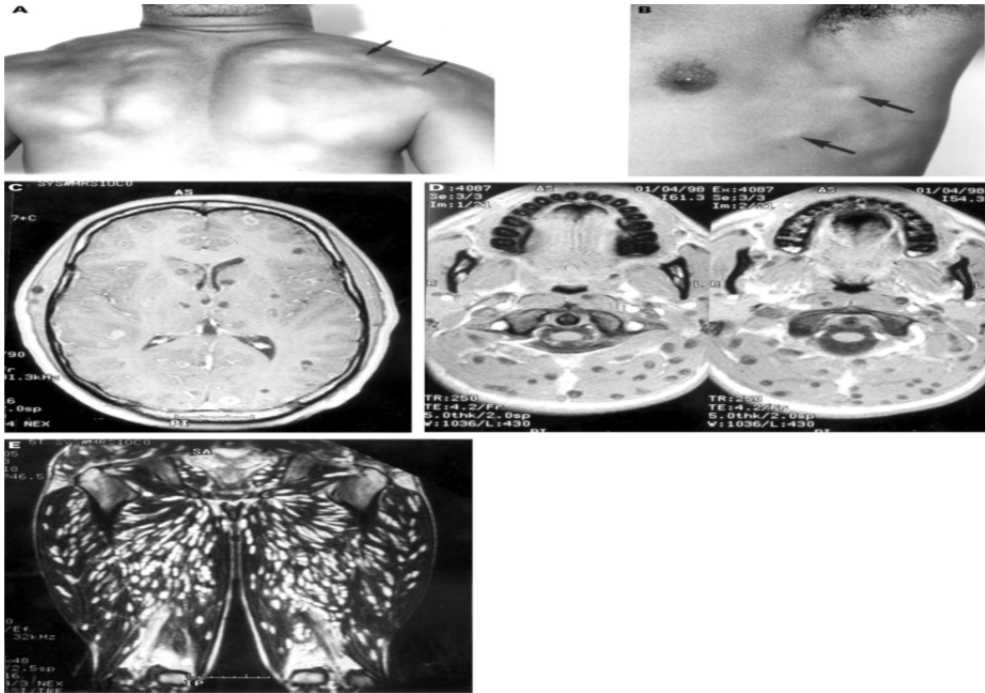
The former Transkei is the poorest region in South Africa and it was a well known batustan during the apartheid régime before 1994. To the population of Xhosa origin were assigned the regions of the Ciskei and Transkei and Transkei is termed as an independent state in

1974 but was only recognized by South Africa with whom confronted territorial disputes between 1974 and 1978. The natural history of the NCC must be viewed within the historical context of this region in order to understand why the NCC has been confined almost to the former Transkei (currently region C and D of Eastern Cape Province), still the only endemic area of the country from where they come from all the sick people who could be diagnosed in the rest of the country.

Human cysticercosis appears to be most prevalent in Eastern Cape Province particularly in the poor, former black homeland, rural areas of Transkei, where pigs are allowed to roam freely and sanitation facilities are inadequate or nonexistent. Pig keeping and pork consumption have increased significantly during the past decade especially in rural smallholder communities, primarily due to the lack of grazing land for ruminants and the recognition of farmers of a quicker and more impressive return on their investment from raising pigs.

The first inform about patients presenting DCC in South Africa was made by Schultz and Mentis [58] In 1987. They reported a 48-year-old black man with two month history of a painless mass on the left side of his neck. He also complained of mild attacks of paroxysmal dyspnoea at night and progressive deafness of his left ear. On direct questioning the patient referred few grand mal seizures during the 6 years before admission. No other complaints or previous illnesses of note were elicited. The patient was born in Transkei (near to Mthatha) and had travelled throughout many parts of the country seeking work. On examination he appeared healthy and was of normal build. The pulse rate was 72/min, blood pressure 110/60 mmHg and temperature 37,2°C. Numerous subcutaneous nodules, ranging from one to three centimeter in diameter, which were well circumscribed and freely movable, could be palpated all over the neck, chest and legs. A bigger mass was palpable inferior to the left ear, extending down the left side of the neck. There was conduction deafness of the left ear. On chest auscultation a few fine crepitations were audible at the bases of both lungs, chest radiography revealed multiple nodular opacities; computed tomography of the brain, neck, thorax and upper abdomen revealed extensive organ involvement, including brain, thyroid, lungs, pancreas, kidney, spleen and muscle; and biopsies of two of the subcutaneous nodules were histologically pathognomonic of cysticercosis. The patient received praziquantel (Biltricide; Bayer-Miles) 1, 75 g twice daily and prednisone 20 mg per day for 4 weeks. He was reassessed radiologically after 4 weeks. There was marked regression in the size and numbers of nodules in the lung fields. Clinically, most of the subcutaneous nodules had disappeared. This is the only report in the international medical literary on CCD with so large involvement of organs and systems including the kidneys.

Bhigjee in 1999 [59], reported the second patient presenting DCC in South Africa. His patient was an Indian male presenting generalized subcutaneous and muscular nodules and neurocysticercosis. Diagnosis was confirmed by plain X-rays of the soft tissues in upper and lower limbs and CT scan of the brain where multiple bilateral active and calcify cysticerci on both cerebral hemisphere were found. (Figure 1)

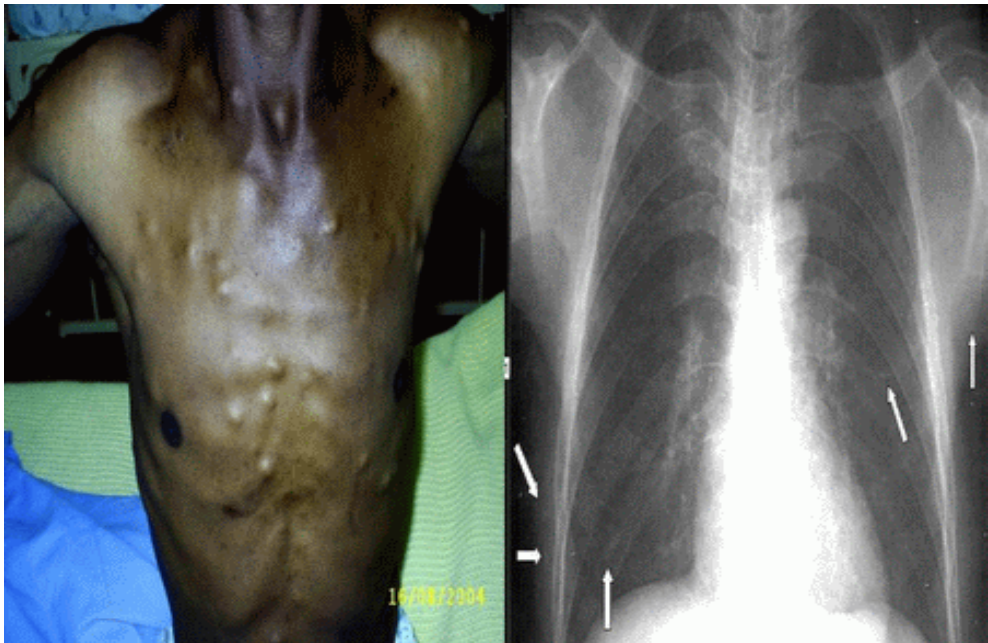


**Figure 1.** Shows generalized subcutaneous and intramuscular calcified nodules on lower limbs and intraparenchymal neurocysticercosis in vesicular, colloid and calcified stages. (Source: J Neurol Neurosurg Psychiatry 1999; 66(4): 545. Bhigjee A).

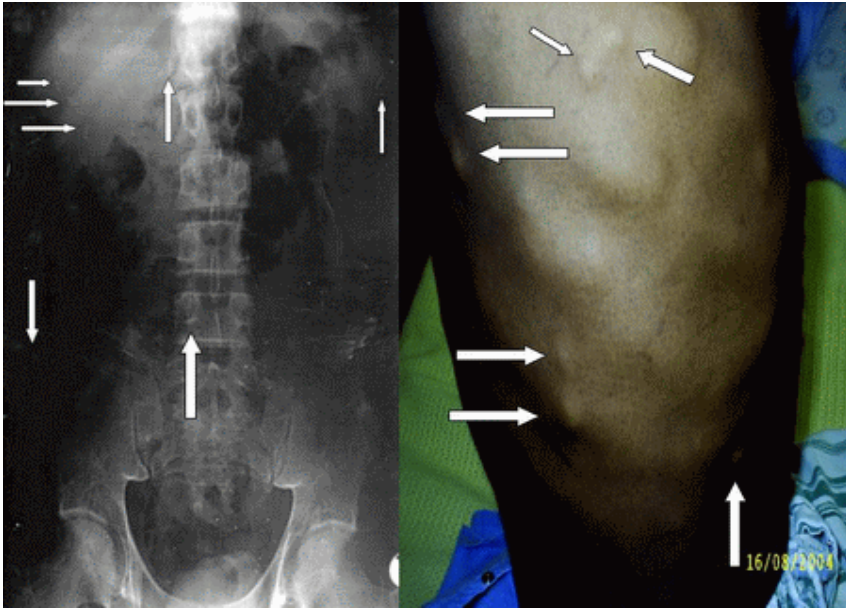
Five years later we reported a 42-year-old man (third report) admitted at Nelson Mandela Academic Hospital Mthatha in South Africa. He presented a history of recurrent generalized tonic-clonic epileptic seizures of six years duration, disseminated nodules all over the body of two-year duration and headache. On general examination multiple subcutaneous and intramuscularly, mobile, no tender nodules, measuring from 0.7 to 2.5 cm, were palpable on the chest, back, abdomen, and proximal regions of the four limbs. (Figure 2-3-4) Respiratory and cardiovascular system were normal except for a bradycardia of 42 bpm. A computed tomography (CT) scan of the brain showed multiple active and calcified lesions. Biopsy of the subcutaneous nodules confirmed the diagnosis of cysticercosis (Figure 3). A detailed neurological examination revealed unremarkable findings. Laboratory data were normal, ELISA test and IgG for cysticercosis were strongly positive. ECG and cardiac ultrasound confirmed: sinus bradycardia, II grade heart block, and calcifications in papillary muscles and upper septum respectively. CT Scan of the brain (Figure 4) shows bilateral cysts in different active stages and calcified NCC. [41]

We referred this patient to the cardiology clinic in our hospital for assessment of bradycardia and some findings were reported later by other authors [60]. Patient felt dizzy on getting up suddenly from a supine position. His pulse rate was 41/min, irregular and his blood pressure 76/124 mmHg. An electrocardiogram (ECG) showed sinus bradycardia with

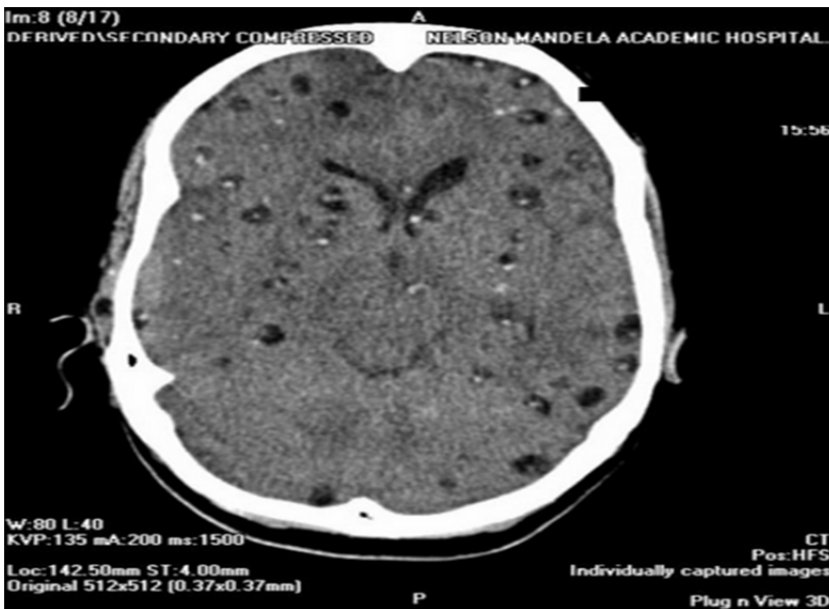complete heart block (Figure 5). The patient was initially treated only with prednisolone, and anti-helminthic treatment was deferred fearing peri-cystic inflammation and aggravation of the conduction abnormalities. Five days later praziquantel 50 mg/kg/day for 14 days were added to the treatment regimen. Repeat ECG after a week of treatment showed sinus rhythm with a heart rate of 70/min. Diagnostic criteria for disseminated cysticercosis for this patient is based on the presence of NCC, subcutaneous, and muscular cysticercosis simultaneously.



**Figure 2.** Multiple subcutaneous nodules on the chest wall and a few calcified lesions on chest X-ray. (Photo taken by H Foyaca-Sibat. Source: Foyaca et al., *Rev Electron Biomed / Electron J Biomed* 2004;3:39-43. Written patient consent is obtained).



**Figure 3.** Multiple calcified subcutaneous and paravertebral nodules. (Photo taken by H Foyaca-Sibat. Source: Foyaca et al., Rev Electron Biomed / Electron J Biomed 2004;3:39-43. Patient written consent is obtained).



**Figure 4.** CT scan of the brain showing multiples intraparenchymal cysticerci in vesicular, colloid and calcified stages.



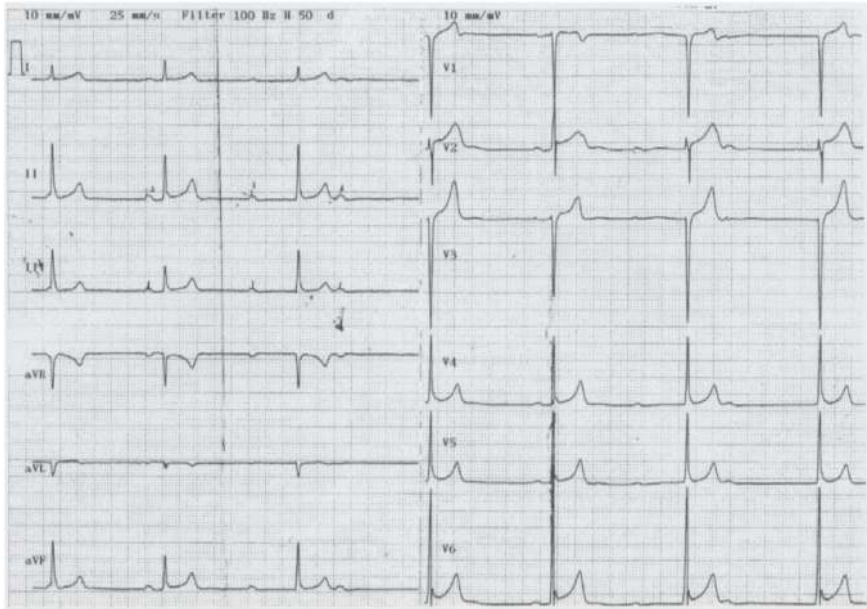


Figure 5. shows sinus bradycardia with complete heart block.[60]

The principal electrocardiographic (ECG) alterations are first-degree atrioventricular (AV) block, low QRS (QRS interval of the ECG) voltage, and primary T-wave changes (as can be seen in Chagas' disease).

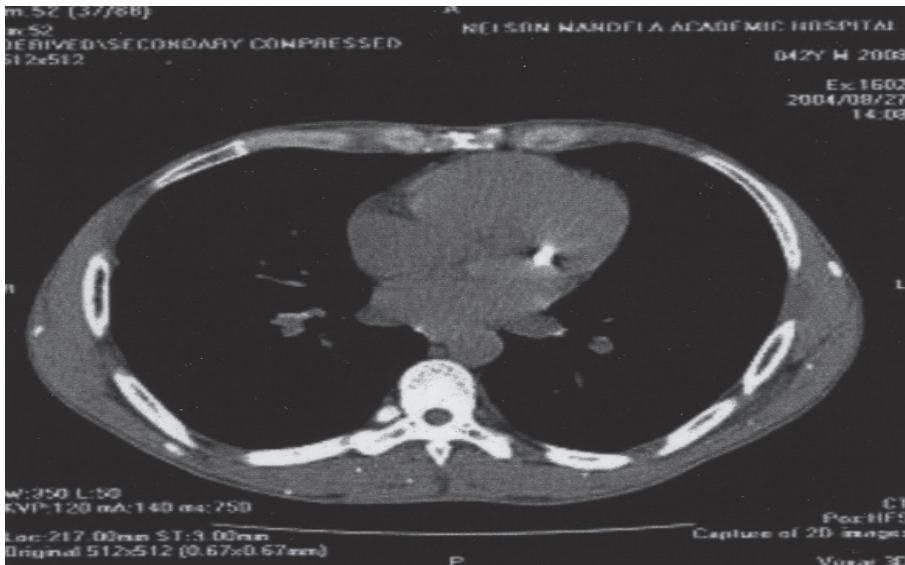
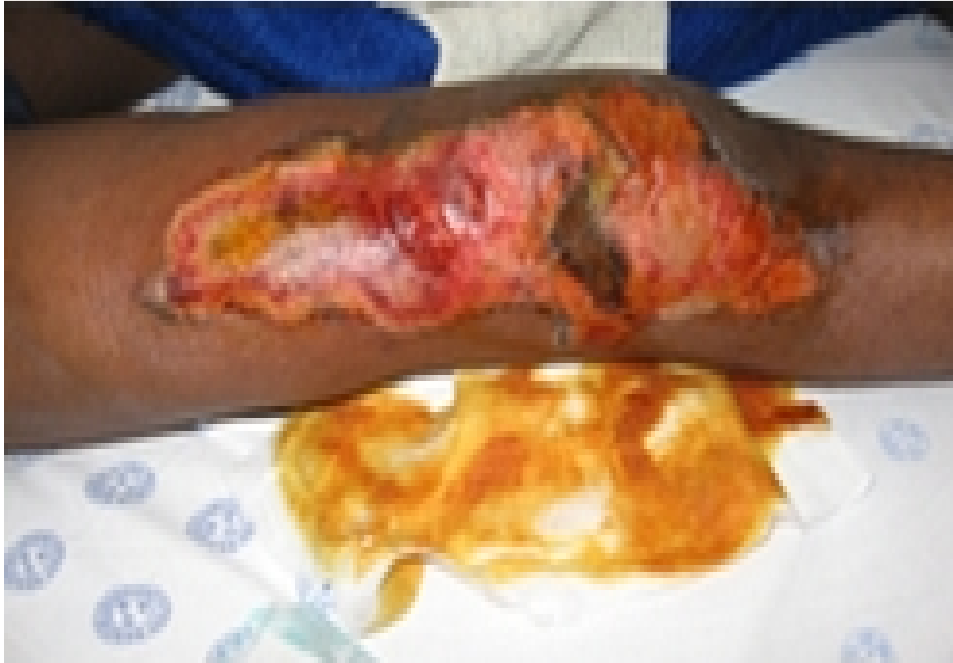

Figure 6. CT scan of chest confirmed the presence of cysts within the myocardium.[60]

In 2007, we reported a 48-year-old African male patient (Fourth patient) admitted at Nelson Mandela Academic Hospital in Mthatha, South Africa presenting a history of recurrent generalized tonic-clonic epileptic seizures with urinary incontinence of five years duration. Patient reported to have fainted at home with three episodes on the day of admission and sustained burns on the right leg while he was unconscious (Figure 7).



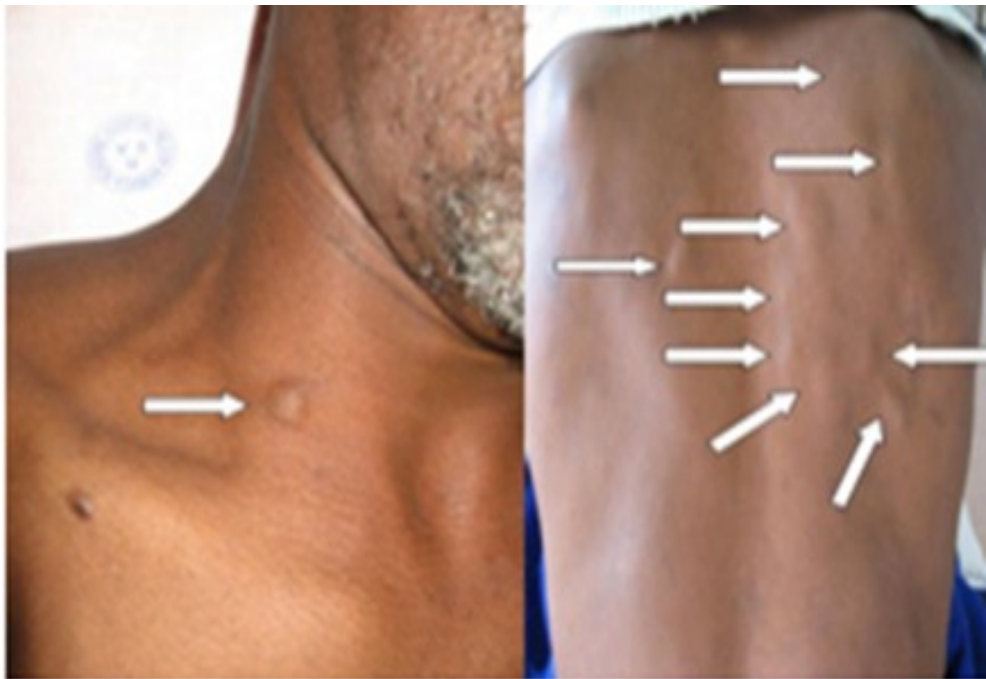
**Figure 7.** Show a burning lesion acquired during tonic-clonic generalized epileptic seizure. (Photo taken by H Foyaca-Sibat. Source: H. Foyaca-Sibat & L. Ibanez-Valdes: Generalized Cysticercosis With Cardiac Involvement. *The Internet Journal of Neurology*. (ISSN: 1531-295X) 2007; 7(2):6-11.

Burn is a frequent accident for epileptic peoples while they having epileptic seizures in rural areas when electricity is not available and they need to keep small fire inside the room as alternative way to survive during the winter. Unfortunately, there is not sustainable solution for this problem at the present moment.

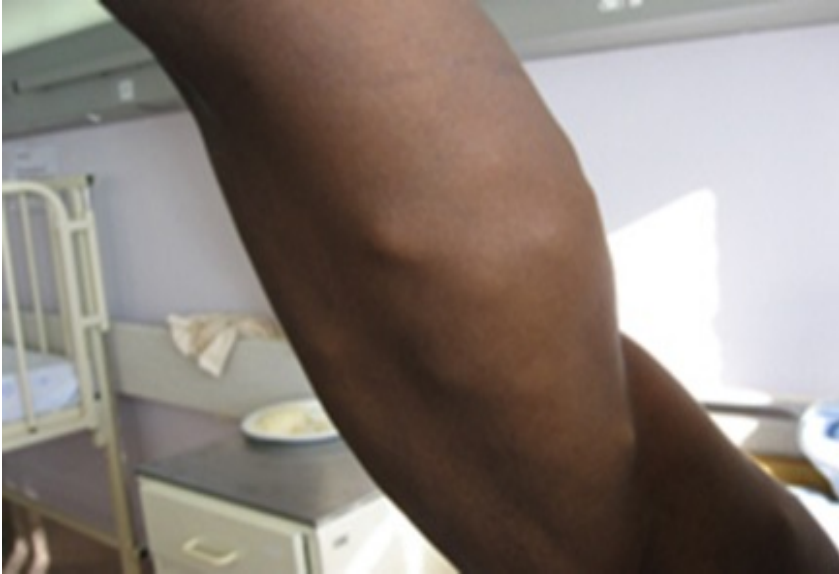This patient was on oral carbamazepine 200mg three times a day, but he discontinued treatment 2 weeks back because medication was not available at the nearest medical clinic. On general examination multiple subcutaneous and intramuscularly, mobile, no tender nodules, measuring from 0.7 to 2.5 cm, were palpable on the chest, back, abdomen, proximal regions of the four limbs and hemi-face (Figure 8-12). Respiratory and cardiovascular system were normal except for a bradycardia of 46 beat per minute. A detailed neurological examination revealed unremarkable findings. Laboratory data included routine blood test

(FBC, U&E, glucose, urinalysis) were normal, erythrocyte sedimentation rate and cardiac enzymes were also normal. ELISA test and IgG for cysticercosis were strongly positive.

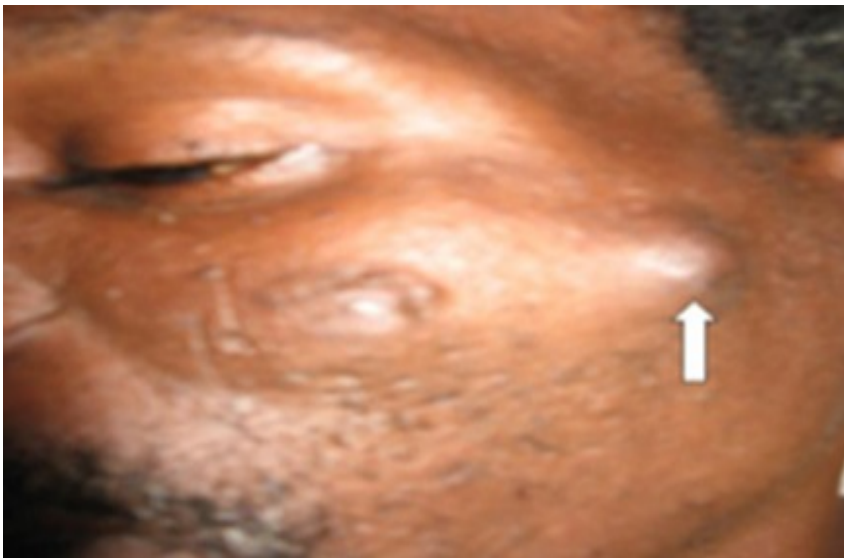Plain chest X-rays and X-rays of long bones showed multiple “cigar-shape calcifications” (Figure 11) and abdomen ultrasound confirmed multiple subcutaneous cystic lesions seen with centric enhancing form remembering the typical “dot-in-hole”. ECG and cardiac ultrasound confirmed: sinus bradycardia, II grade heart block and calcifications in papillary muscles and upper septum respectively (Figure 7). CT scan of the brain showed bilateral cystic lesions in vesicular and colloid stages, and calcified NCC [50]. Plain X-ray studies of the muscles are also useful to identify the typical “cigar-shape” calcifications on the subcutaneous tissue, and if any query arise then a positive serological test for *T. solium* (antigen/antibody) will help while the final diagnosis is confirmed by biopsy of the subcutaneous nodules or confirming NCC by imagenology.



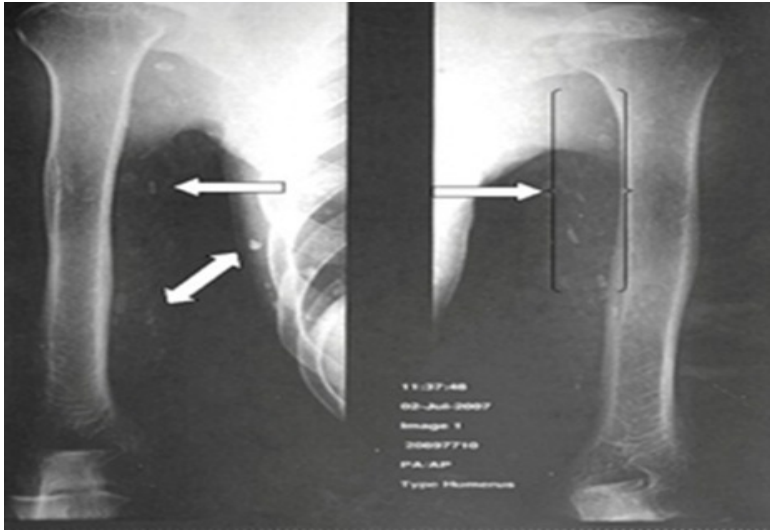
**Figure 8.** Show subcutaneous nodule on the right lateral aspect of the neck and multiple subcutaneous nodules in the upper back mainly on the right side. (Photo taken by H Foyaca-Sibat. Source: H. Foyaca-Sibat & L. Ibanez-Valdes: Generalized Cysticercosis With Cardiac Involvement. *The Internet Journal of Neurology*. 2007 Volume 7 Number 2.)



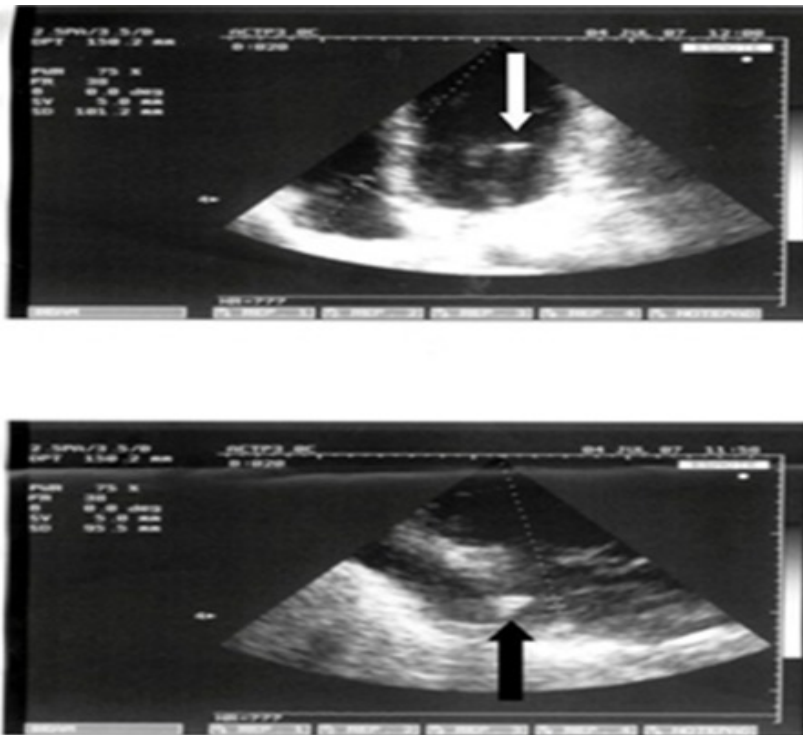
**Figure 9.** Shows multiple subcutaneous nodules in the left arm some of them were located in the biceps brachialis. (Photo taken by H Foyaca-Sibat. Source: H. Foyaca-Sibat & L. Ibanez-Valdes: Generalized Cysticercosis With Cardiac Involvement. *The Internet Journal of Neurology*. 2007 Volume 7 Number 2.)



**Figure 10.** Shows a nodular lesion in the left hemiface at the zygomatic arch level removed by surgical procedure and histological examination confirmed subcutaneous cysticercosis (Photo taken by H Foyaca-Sibat. Source: H. Foyaca-Sibat & L. Ibanez-Valdes: Generalized Cysticercosis With Cardiac Involvement. *The Internet Journal of Neurology*. 2007 Volume 7 Number 2. Patient written consent is obtained)



**Figure 11.** Plain X-ray of the chest and upper limbs show multiple subcutaneous and intramuscular “cigar-shape” calcifications.



**Figure 12.** Cardiac ultrasound shows cysticercus in the cardiac muscle.

Ultrasography to diagnose subcutaneous cysticercosis was introduced a few years ago and from the beginning we also found some limitations to differentiated cysticercosis from lymphadenopathies, neurofibromas, and epidermoid cysts [41] however at the present moment is possible to confirm a diagnosis for subcutaneous nodules showing the scolex inside. Echocardiogram has a high level of accuracy in cardiocysticercosis and we could confirm it in patients.

All South African patients presenting CCD also suffering of symptomatic epilepsy because all had cerebro-cortical lesions caused by *T. solium*.

#### **4. Disseminated cysticercosis and epilepsy**

Epilepsy is also the most common clinical manifestation of NCC in our region [61-64] and its prevalence has been well documented in several communities of Eastern Cape Province in South Africa. [65-71]. While disseminated cysticercosis is an exceptional expression of CC characterized by high morbidity due to massive symptomatic parasite burden in the central nervous system, striated muscles, subcutaneous tissues and other organs. Less than 50 such cases have been reported worldwide and fewer than 10 children. In 2010, Kumar and collaborators [72] reported their findings on whole-body MRI as a diagnostic tool for extensively disseminated cysticercosis in a child and highlighted its role in diagnosis and management of this pleomorphic disease. Unfortunately, MRI is not available for most of patients with CCD worldwide and it can not replace the traditional way of diagnosis based on CT scan of the brain for NCC and plain X-ray for muscular and subcutaneous cysticercosis. Diagnosis of NCC can be made by Del Brutto's recommendation [73] but novel criterias suggested by Carpio in this book, should be considered

#### **5. The disseminated cysticercosis going to disappear in the near future?**

Before moving to another topic we would like to answer that research question.

We are convinced that CC will be eradicated from our planet, but today this is far from happen especially in some countries of Sub-Saharan Africa, Asia and Latin America, where there are communities who live, or have lived, either by choice (peoples living in voluntary isolation) or by circumstance, without significant contact with globalized civilization, therefore their current epidemiological situation is unknown and we even don't know how many peoples are infected by parasites.

We know that *T. solium* infested man long before there was any evidence of animal domestication (See chapter 1) [74, 75] by which we can assume that even in communities where very backward the taming of animals there is no zoonotic diseases may be acquired by other means.

For the other hand, there is an important number of hidden groups of peoples such as: racist groups and racist activists; drug traffickers in prisons; natives from the Central African Rain Forest; male and female prisoners and guards from a number of prison colonies; nationalists

expressing anti-Semitic sentiment and young people participating in radical social and political mobilization among others [76]. How many of these hidden groups suffer of *T. solium* cysticercosis? We do not know.

In our opinion, even when the poverty disappear from underdeveloped countries and every person get a proper access to clean and safe water, living in very good hygienic conditions under an ideal health education and primary health care sustainable system program, we could not proclaim that the CC has been eradicated because of that important number of human beings sharing our planet whose epidemiological situation remain unknown. We are aware about an important number of individuals that still remains in that situation.

Congo region is included in our Cysticercosis Working Group for Eastern and Southern Africa (CGWESA). The Bambuti are pygmy hunter-gatherers, and are one of the oldest indigenous people of the Congo region of Africa. They are composed by bands which are relatively small in size, ranging from 15 to 60 people. The Bambuti population totals about 30,000 to 40,000 people. The forest where they live is a moist, humid region strewn with rivers and lakes. Disease is prevalent in the forests and can spread quickly, killing not only humans, but plants, and animals, the major source of food, as well. Their animal foodstuffs include crabs, shellfish, ants, larvae, snails, pigs, antelopes, monkeys, fishes, and honey. The vegetable component of their diet includes wild yams, berries, fruits, roots, leaves, and cola nuts [77]. Anyone is infected by *T. solium*?, Who knows? We do not know.

Many parts of the Americas are still populated by indigenous Americans; some countries have sizable populations, especially Bolivia, Peru, Mexico, Guatemala, Colombia, and Ecuador. Some indigenous peoples still live in relative isolation from Western society, and a few are still counted as uncontacted peoples [78]. Most uncontacted communities are located in densely forested areas in South America and New Guinea. Knowledge of the existence of these groups comes mostly from infrequent and sometimes violent encounters with neighboring tribes, and from aerial footage. Isolated tribes may lack immunity to common diseases, which can kill 50 to 80 per cent of their people after contact [79] but nobody knows how many parasites are affecting them.

The Sentinelese continues to actively and violently reject contact. They live on North Sentinel Island, a small and remote island which lies to the west of the southern part of South Andaman Island. They are thus considered the most isolated people in the world, and they are likely to remain so [73]. The current epidemiological situation on parasitic zoonoses of Sentinel is still unknown.

In Paraguay remains perhaps as many as 300 Totobiegosode who have not been contacted; they belong to the Ayoreo ethnicity, which numbers around 2,000. As of 2006, the presence of five uncontacted groups was confirmed in Bolivia; three more uncontacted groups are believed to exist. On January 18, 2007, the National Indian Foundation reported that it had confirmed the presence of 67 uncontacted tribes in Brazil, up from 40 in 2005. With this reported increase, Brazil has surpassed the island of New Guinea as the region having the highest number of uncontacted tribes. Ecuador continues to be the country with the largest number of uncontacted people killed since 2000. After Brazil and New Guinea (Papua New

Guinea and Iriyan Jaya), Peru has the largest number of uncontacted tribes in the world [79] and there is not available information about their current situation related to incidence or prevalence of infectious diseases.

Today there are more than 150 million tribal peoples worldwide, including at least 70 uncontacted tribes, living in 60 countries. Some organization such as: Survival International supports these endangered tribes on a global level, with campaigns established in America, Africa and Asia [80, 81]. In our opinion, many of them can be parasitized by *T. solium* as was the *H. ergatus* more than a million of the year ago (See chapter 1).

Due to globalization, a growing number of uncontrolled immigrants from an endemic area in Latin America come to the USA every day, significantly increasing the number of cases of NCC in the country especially in Texas and California [82-91] where a total of 1494 patients with NCC were confirmed between 1980 and 2004 of which 66% suffered from epilepsy, 16% had a obstructive hydrocephalus and the 15% headache due to intraparenchymal NCC (91 % ), intraventricular (6 %) or subarachnoid (2 %) either because travelled to endemic areas, were of Hispanic origin or had any contact with carriers of the parasite [92-93]. In Latin America has been described the existence of NCC in 18 countries with an estimated 350,000 patients infected by the complex CC/TE. In 2008, Pawlowski stipulated that in the world would have approximately 2.5 million people infected *T. solium* and at least 20 million with CC [70].

Disseminate presentations of cysticercosis is not common in our region, only six patients were previously confirmed and four of them reported to the medical literature [41, 50, 58, 59]. Typical manifestation is subcutaneous cyst present as nodules that tend to be asymptomatic [41, 50]. The natural history of the infection remains unknown up to date. However, is well known that most cysticercus complete their development within two to four months after larval entry living there months to years, and their locations in order of frequency are the central nervous system, subcutaneous tissues, striated muscle, heart, orbits, and other tissues. Human cysticercosis is acquired after eating food contaminated with fertilized eggs excreted in the feces of *Taenia's* carriers. In humans the most common routes of infection (cysticercosis) are ingestion of *T. solium* eggs from contaminated food and fecal-oral auto-infestation in patients harbouring the adult parasite in their intestines. While the cysts can develop in most human tissue, they have a predilection for CNS. Cysticercosis is estimated to affect approximately 50 million people worldwide and is common in rural South Africa [1, 10-15, 61-71].

## **6. Disseminated cysticercosis with involvement of other organs**

### **6.1. Cardiac cysticercosis**

The vast majority of patients with DCC reported to international medical literature are from India and although CC can affect almost any tissue the most frequently reported are the central nervous system and skeletal muscles [41,50,58]. Myocardial cysticercosis is rare [94,95] but its diagnosis is easier with modern radiological tools [95-97] . We will see in more



detail the most important features of the cysticercosis of the cardiac muscle followed by cysticercosis in the lungs and the combination of both presentations.

As before-mentioned DCC means distribution of cysticerci along to the brain, skeletal muscles and subcutaneous tissues. In this part of the chapter we will discuss about other organs affected.

Long before the emergence of computerized tomography knew each other from the first cases with cardiocysticercosis with other associated diseases of the heart in living patients [98], even with silent presentation [99] or disorders of cardiac conduction [100]. The lack of brain imaging studies did not confirm the presence of associated NCC in those cases. Spent 10 years and then was possible achieve a better image of the heart and confirm best results with the use of praziquantel in this type of presentation associated with DCC [101]. Some parasites may directly or indirectly affect various anatomical structures of the heart, with infections manifested as myocarditis, pericarditis, pancarditis, or pulmonary hypertension. In other situations, parasitic infections may have more direct effects on various structures of the heart (myocardium, pericardium, endocardium, or the cardiac vasculature). The involvement of the myocardium may lead to myocarditis or different types of cardiomyopathies (i.e., dilated or restrictive). When the pericardium is affected, it may lead to pericarditis, pericardial effusion, cardiac tamponade, or constrictive pericarditis. Due to growing migration, population displacement, and travel, clinicians anywhere around the globe must be aware of the potential cardiac manifestations of parasitic diseases [57,102].

The myocardial inflammatory response is variable, resulting in granuloma formation and fibrosis, which subsequently leads to arrhythmias and conduction abnormalities either spontaneously or during treatment [57,103-105].

Cardiac involvement in cysticercosis was thought to be rare, but autopsy studies have shown a prevalence of 20 to 25% in patients with concomitant documented neurocysticercosis [104,105]. Cardiac cysticercosis is often asymptomatic and discovered during cardiac surgery or at autopsy. Cysticerci are usually multiple and randomly distributed in cardiac tissues, including the subpericardium, subendocardium, and myocardium [104]. Rarely, a single cardiac cyst may be present [102]. The computed tomography and ultrasonographic studies have demonstrated a fundamental importance in the diagnosis of cysticercosis of the heart according with results reported by other authors [57,106-108] and own personal experience [41, 50].

The DCC also affects children severely, an example of that is in the five years old patient reported by Asrani [108] in 2004, who presented subcutaneous swellings all over her body. The swellings were each between 0.5 and 2 cm in size. There were only 1 or 2 to start with on the back of the neck, and then they gradually increased to involve the chest, head, neck, arms, and legs in 2 to 3 months. These swellings were accompanied by onset of abnormal behavior in the form of irritability, talkativeness, disobeying commands, and bladder incontinence (secondary enuresis). Also, there was abnormal weight gain of 10 kg. The patient also had decreased vision for one month. Examination revealed multiple

subcutaneous nodules between 0.5 and 2 cm in size over the forehead, abdomen, back, and legs. She weighed 29 kg (19 kg in a previous month). Her vision was 6/30 according to the Snellen chart. The patient was referred for sonography of the abdomen. The abdominal viscera on examination with a 3.5-MHz convex transducer were unremarkable, but the abdominal wall showed some tiny cystic lesions. Further examination using a high-frequency 7- to 12-MHz linear transducer (HDI 3000; Philips Medical Systems, Andover, MA) showed innumerable oval to circular, 0.5- to 1.5-cm, predominantly anechoic lesions in the subcutaneous tissues and abdominal wall muscles. Similar lesions were distributed over the back, neck, thighs, calves, legs, axillae, forearms, and arms. Sonography of the tongue also revealed similar multiple lesions. There was no increased vascularity surrounding these lesions on color Doppler examination. Only the palms and soles seemed to be uninvolved. A sonographic diagnosis of disseminated muscular cysticercosis was made. Whole-body contrast-enhanced computed tomography (CT) confirmed the sonographic findings and showed the classic "starry night" in the brain. The entire muscular system and the subcutaneous tissue had hypodense, nonenhancing, approximately 1-cm lesions without calcification, suggesting that all the cysts were live. Magnetic resonance imaging (MRI) of the brain, orbit, and musculoskeletal system showed multiple hyperintense lesions on transverse relaxation time (T2)-weighted images.

A biopsy of the subcutaneous nodules showed classic cysts with a central scolex. Multiple ocular cysts were also found on ocular examination. After this, the patient started receiving steroids and anthelmintic agents. Within 4 weeks of starting treatment, the patient's weight decreased by 10 kg (to 19 kg again). She became quiet and began obeying commands. Her vision became 6/12 (Snellen chart). Echocardiography revealed extensive myocardial involvement. The major differential diagnosis is hydatid cyst, which is usually larger and multilocular. Anthelmintic treatment may result in pericystic inflammatory reaction which might worsen the clinical state [109].

Other parasite can also affect the myocardium and the pericardium as we have previously pointed out, and that the most widely studied parasitic infection affecting the heart is Chagas' disease or American trypanosomiasis but African trypanosomiasis may also cause a myocarditis. The protozoan parasite, *Entamoeba histolytica* rarely causes a pericarditis while *Toxoplasma gondii* may cause myocarditis, usually in immunocompromised hosts. The larval forms of the tapeworms *Echinococcus* and *T. solium* may cause space occupying lesions of the heart. Severe infection with the nematode *Trichinella spiralis* may cause myocarditis [110].

Not always cardiocysticercosis is part of the disseminated cysticercosis as reported by Eberly and collaborators and it may occur as an isolated infection of the left ventricle [111].

In 2009, Shogan [112] reported a 17-year-old boy from Cameroon presenting a sessile cystic cardiac mass. A CT scan revealed a 1.0 × 1.5 cm nonenhancing, exophytic, ovoid mural-based fluid density in the left ventricle along the endocardial surface of the anterior wall near the anteroseptal basal region. On T1-weighted MR images, the mass was hypointense. On T2-weighted MR images, the mass was hyperintense, with a rounded hypointense signal

visible at the posterior wall of the cyst. One internal septation of the mass was noted. After gadolinium administration, no enhancement was present. The patient underwent biopsy of the mass. Histologic evaluation showed a fluid-containing cystic structure, which exhibited a single protoscolex consistent with a cysticercus. These authors mentioned that involvement of the heart by *T. solium* is very rare and is usually diagnosed postmortem. After review the international medical literature we agree it is rare but diagnosis of cardiocysticercosis is made accurately in most of patient seeking for medical attention. Shogan’s report is extremely uncommon because his patient had not an associated DCC or NCC [112], but without doubt the cardiocysticercosis must always be borne in mind in patients with similar presentations and because it is commonly associated with intraparenchymal NCC therefore to look for epilepsy is strong recommended. (See figure 13)

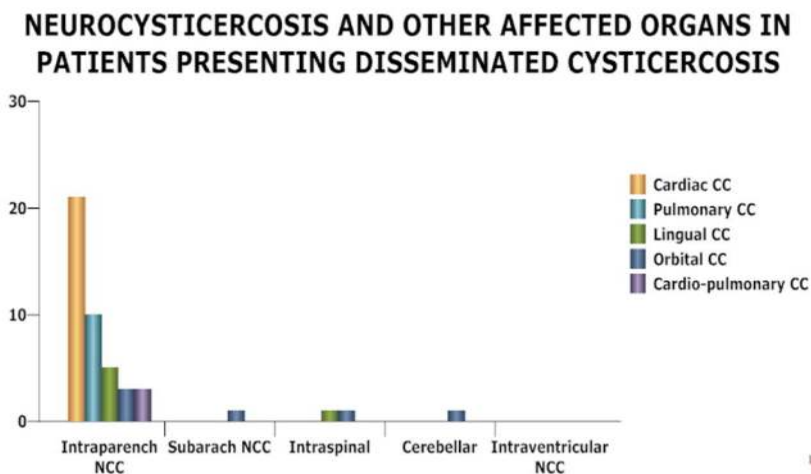


Figure 13. Graphical representation of other affected organs and location of cysticerci in the CNS.

## 6.2. Pulmonary cysticercosis

Most of patients presenting pulmonary cysticercosis have multiple rather than solitary pulmonary nodules (a “spot” on the lung that is less than 3 cm or 1½ inches in diameter by chest X-ray).

The differential diagnosis of multiple pulmonary nodules is large and includes congenital and inherited disorders, malignancy, infectious etiologies, noninfectious granulomatous and inflammatory conditions, among many others. Disseminated cysticercosis with pulmonary involvement should be suspected in any patient presenting with multiple pulmonary nodules who is an immigrant from an endemic region or an individual who has resided in one of the countries where cysticercosis is endemic [113].

Taking into consideration that the only infectious disease causing multiple pulmonary nodules and associated cutaneous manifestation are: blastomycosis, coccidiomycosis,

tuberculosis and cysticercosis then the differential diagnosis of pulmonary cysticercosis is very easy if DCC/NCC complex is present.

In 1971, Bassermann [114] found some radiographic problems in pulmonary cysticercosis because at that time computed tomography system was not available. Siemens Medical Solutions (then known as Siemens Medical Engineering) presented the first machine commercially available in May 1974. Therefore confirmation of NCC by imagenology was not done. Other authors studied patients with pulmonary cysticercosis at different times and all of them agree that this is an uncommon condition [115-119].

Schotz and Mentis [116] in 1987 reported a 48-years-old black man admitted to hospital with a 2-month history of a painless mass on the left side of his neck. He also complained of mild attacks of paroxysmal dyspnoea at night and progressive deafness of his left ear. On direct questioning the patient referred a few grand mal seizures during the six years before admission. No other complaints or previous illnesses of note were elicited. The patient was born in Transkei (near to Mthatha in South Africa) and had travelled throughout many parts of the country seeking work, which he secured in the gold mines mainly. He ate a variety of meats including pork and smoked and drank excessively at times. On examination he appeared healthy and was of normal build. The pulse rate was 72/min, blood pressure 110/60 mmHg and temperature 37,2°C. Numerous subcutaneous nodules, ranging in size from 1 cm to 3 cm in diameter, which were well circumscribed and freely movable, could be palpated all over the neck, chest and legs. A bigger mass was palpable inferior to the left ear, extending down the left side of the neck. There was conduction deafness of the left ear. On chest auscultation a few fine crepitations were audible at the bases of both lungs. Computed tomography of the brain, neck, thorax and upper abdomen revealed extensive organ involvement, including brain, thyroid, lungs, pancreas, kidney, spleen and muscle; and biopsies of two of the subcutaneous nodules were histologically pathognomonic of *T. solium* cysticercosis. The patient received praziquantel (Biltricide; Bayer-Miles) 1,75 g twice daily and prednisone 20 mg per day for 4 weeks. He was reassessed radiologically after 4 weeks. There was marked regression in the size and numbers of nodules in the lung fields. Clinically, most of the subcutaneous nodules had disappeared. Authors highlighted that the radiological appearance of cysticercosis in the lung cannot be differentiated from other parasitic infections, e.g. echinococcosis, pentastomiasis, paragonimiasis and histoplasmosis, or conditions such as tuberculosis, alveolar carcinoma and metastases due to the varying reaction of the lung tissue and difference in size of the larvae [114]. Pulmonary sparganosis should be excluded from the list of differential diagnosis as well [120]. Although rare, pulmonary cysticercosis does occur and in developing countries should not be overlooked in the differential diagnosis of multiple lung opacities.

From our knowledge, this is the only patient with renal involvement reported to the medical literature ever.

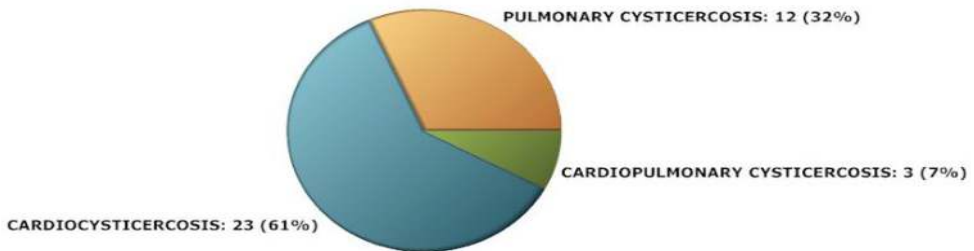
From one case reported in Korea, authors concluded that the presence of cysticerci are difficult to discern from pulmonary infiltrates, because other parasitic infestations or tuberculosis, as well as metastatic lesions, produce similar chest X-ray findings and similar

clinical symptoms (as before-mentioned) and they suggest open lung biopsy for confirmation, for treatment PZQ (50 mg/kg per day for 15 days) and to consider pulmonary cysticercosis as a diagnostic possibility in patients with nodular infiltrates in the lungs, especially in endemic areas, until such infiltrates are otherwise explained [118].

In 2011, a radiologist from Punjab, India [119] reported a well documented 28-year-old man presented with a history of fever, dry cough, headache and decreased responsiveness over 7 days. One year previously, he had suffered seizures and was hospitalised in another centre with an initial diagnosis of NCC and received treatment for it. MRI at that time depicted numerous ring enhancing lesions with eccentric scolex ('cyst with dot' appearance) in the cerebral hemispheres, subarachnoid space and orbits. The patient had a history of pork intake and intravenous drug misuse. Physical examination at the time of admission revealed small, movable, painless subcutaneous nodules that were palpable over the arms, axillae and trunk. No abnormalities were noted on auscultation of the lungs. Blood and urine cultures were negative. Sputum analysis was normal. A chest x-ray revealed small nodules in both lungs. This is the first report about pulmonary cysticercosis in a patient presenting DCC and subarachnoid NCC.

Next patient was reported by Strawter et.al., [113] a few weeks ago. They studied a 31-year-old incarcerated Hispanic male presented with a nonproductive cough for several months and one episode of blood tinged sputum. He admitted to weight loss and night sweats, headaches, and visual disturbances. He was an immigrant from Honduras and lived in Arizona for the past 15 years. He had chronic hepatitis C infection and was receiving treatment with pegylated interferon-alfa-2a (IFN- $\alpha$ ) and ribavirin. His symptoms began one month after initiating antiviral therapy. They confirmed pulmonary nodules with cutaneous manifestations and concluded that: Disseminated cysticercosis with pulmonary involvement should be suspected in any patient presenting with multiple pulmonary nodules who is an immigrant from an endemic region or an individual who has resided in one of the countries where cysticercosis is present or when NCC is well documented. Lung are the second thoracic organ affected by *T solium* cysticercosis preceded by the heart (See Figure 14)

**CARDIAC AND PULMONARY INVOLVEMENT IN PATIENTS PRESENTING DISSEMINATED CYSTICERCOSIS**



**Figure 14.** Thoracic organs involved in disseminated cysticercosis

### 6.3. Cardio-pulmonary cysticercosis

The heart and the lungs are the thoracic organs more frequently affected by parasitic infections. The involvement of the heart may be part of a more generalized illness, as is the case with human African trypanosomiasis [102] and other parasitic diseases as before-cited. The first case reported under this condition presented a massive cardiopulmonary cysticercosis and an associated leukemia. [121] being this one the only patient presenting this type of co-morbidity. Bastos et al., [122] from Brazil reported another patient and highlighted the importance of imagenology (CT scan) of the chest for confirmation of diagnosis based on their findings: multiple pulmonary, cardiac and chest wall nodules concluding that cysticercosis should be considered in the differential diagnosis of multiple pulmonary nodules, mainly in those patients with similar lesions in the cardiac muscle and/or in the chest wall which made the overall diagnosis easy to perform.

Other important contribution is made by Jain et al., [123]. They reported a 19-year-old boy from Mumbai (India) who presented with a history of headache and vomiting for six months, seizures for three months, and decreased vision and bilateral proptosis (right more than left) for one month. The patient was apparently asymptomatic six months back. The patient was a vegetarian. Examination revealed subcutaneous nodules over the right eyelid, with mild proptosis of both eyes. Using the Snellen chart, his vision was found to be 6/30 in the right eye and 7/30 in the left eye. Neurological examination did not reveal any abnormality. All the laboratory investigations were normal. The patient was referred for MRI of the brain, which revealed multiple 3–8 mm-sized cystic lesions with T2-hypointense foci within both cerebral hemispheres, cerebellum, extraocular muscles of both orbits and soft tissues of the neck. Similar lesions were distributed in the muscles and adjacent subcutaneous tissues of the back, abdominal wall, thighs, calves, legs, forearms and arms as well as the extradural spinal space. Multiple cystic lesions were seen in both lungs and in the cardiac muscles. Hyperintense nodules were also seen in the pancreas. For further evaluation, a high-resolution CT (HRCT) of the lungs was performed, which revealed bilateral multiple, randomly distributed, 3–8 mm nodules. A B-scan USG was performed, which revealed a large intravitreal cyst within the right eye, with a tiny hyperechoic scolex. The left eye was normal. On superficial probe evaluation of the heart and pericardium through a parasternal window, using a high-frequency 7 to 12 MHz linear transducer (HDI 3000; Philips Medical Systems, Andover, MA, USA), there were multiple oval to circular, 0.5–1.5-cm sized, predominantly anechoic lesions in the heart muscle. Later, a dedicated 2D echocardiography was performed, which revealed multiple disseminated cysticerci involving the muscle of the heart. On the basis of these imaging findings, a diagnosis of disseminated cysticercosis was made. The patient also had right bundle branch block on electrocardiogram; however, other functional parameters such as ejection fraction, valve function, systolic function and chamber size were normal on 2D echocardiography. A final diagnosis of cysticercosis was made and this was confirmed on muscle biopsy. Because drug-induced inflammation due to praziquantel may cause irreversible damage in cases with ocular lesions, this medication was not given, and the patient was treated symptomatically with antiepileptic drugs, steroids, and diuretics. To the best of our knowledge, this is the best documented patient presented with disseminated cysticercosis

with cardiac, pulmonary, pancreatic, spinal, extradural, and ocular involvement reported in the international medical literature up to today and clearly demonstrate the extent to which cysticercosis can be disseminated and almost all probable combination of involved organs.

Although this report does not describe the state of the evolutionary of cysticercus, it is logical to assume that a parasitic infection of this magnitude is due to uninterrupted ingestion of *T. solium* eggs which is only possible under deplorable sanitary conditions. Such a quantity of larvae of *T. solium* solium when driving through the bloodstream in a young patient allows its dissemination almost uniformly throughout the body including the CNS. This aspect will be discussed below.

#### **6.4. Orbital cysticercosis**

In the next chapter we will refer more details to the ocular cysticercosis according to their different locations within and outside of the eyeball but without exceeding the limits of the orbital cavity. In this chapter we will review only the clinical features of the ocular cysticercosis associated with damage to other organs as part of the disseminated cysticercosis, based on the results published in the international medical literature.

Almost all patients presenting cysticercotic orbital involvement and associated DCC were from India as we show below. Cheung et al., [124] in 1987 reported a patient with disseminated cysticercosis involving orbit, tongue, parotid glands, epicardial fat tissue, muscles, and subcutaneous tissues confirmed by MRI. This was the first communication on combination of cysticercosis of the orbit, parotid gland and epicardial fat. Cysticercosis of the eyelid was studied by Gupta et al., [125]. One of the youngest patient (5-years-old) ever studied was reported by Asrani and Morani [108] their patient apart from cardiocysticercosis (before-mentioned) also presented multiple orbital cysts with decreased visual acuity and neuropsychiatric manifestations. Despite this ocular involvement this patient received anthelmintic agents and no further complications were informed. Combination of epilepsy, DCC, proptosis of the eyes, fever and arthralgia can be seen [8]. Disseminated cysticercosis can cause intravitreal lesions with exudative retinal detachment and bilateral extra ocular muscular damage at the same time [126] or affect only the brain, orbits, subcutaneous tissue [127, 128] the eyes, tongue and spinal cord [127] or the tongue, eyes, face and scalp muscles [130], and an extensive involvement of both orbits [131]; face, scalp muscles, subconjunctival cysts in the eyes and cysticercotic encephalitis [132], cardiopulmonary cysticercosis plus proptosis of the eyes, extra ocular muscles of both orbits, extradural spinal, and cerebellar involvement [123] and other combinations such as: subarachnoid NCC, Brown syndrome, different extra ocular muscles involvement, mimicking idiopathic orbital inflammation, retina involvement, and canine tooth syndrome have been reported to the medical literature [119, 133-138].

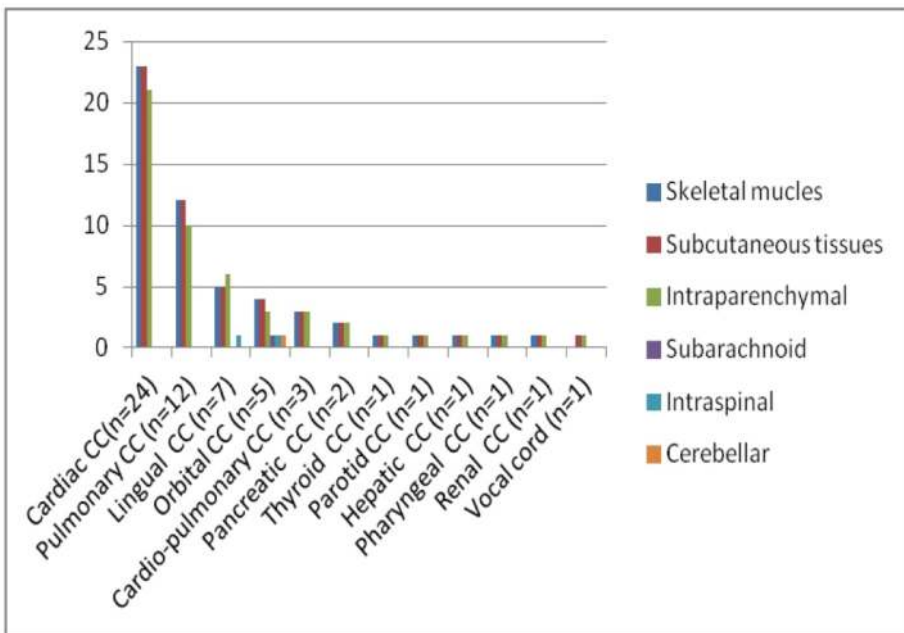
#### **6.5. Other organs affected**

As we have seen, the disseminated cysticercosis (muscular and subcutaneous tissue) is always associated with the NCC and in addition, it can be associated to heart, lung, eyes,

spleen, pancreas, parotid, liver, kidneys and pharynx involvement. Here we will discuss about some cases presenting this modalities of DCC.

Other presentations of the DCC include epilepsy with extensive muscular involvement, predominantly [139-144], associated liver damage [145], epilepsy with damage of the soft tissues of the scalp plus supra and infratentorial lesions; spinal cord [129] epilepsy and DCC with huge muscle involvement [146-148], vocal cord [149], thyroid gland [150], the tongue [129,151], spleen and pancreas [46]; or even without neurological symptoms [152] or immunocompromised patient [153].

Cysticercosis of the pharynx the kidneys have been reported in South Africa only [58, 61], as we have mentioned previously that serves to highlight that these two locations must also keep in mind when planning to perform clinical investigations for this type of patient. Most of isolated damaged organs by CC without dissemination of cysticerci throught the subcutaneous tissues are not associated with NCC and when it happen then extraparenchymal location can be seen. Because only anecdotic reports to the medical literature are available at the present moment (See figure 15) we can not arrive to solid conclusions and only advices are suggested.



**Figure 15.** Graphic representation of number of patients with cysticercosis in different organs as part of disseminated cysticercosis with involvement of the central nervous system at different levels.

India has the highest prevalence of disseminate cysticercosis worldwide (Figure 17). Given the fact that cysticercosis is an endemic disease in India and that WB-MRI is now available on most modern MRI scanners, especially in academic institutions, Goenka and Kumar [154,



155] believe that awareness about this technique may enable to his fellow colleagues to explore its valuable potential in disseminated cysticercosis. Most of patients presenting DCC are from India (New Delhi) as can be seen in the figure 16 but even there, the number of well documented patient is still no enough to design an accurate clinical trial looking for a medication of choice for this condition. Based on our experiency, to combine Praziquantel and Albendazole with steroids provide good results if there is not involvement of the heart, the eyes or massive NCC.

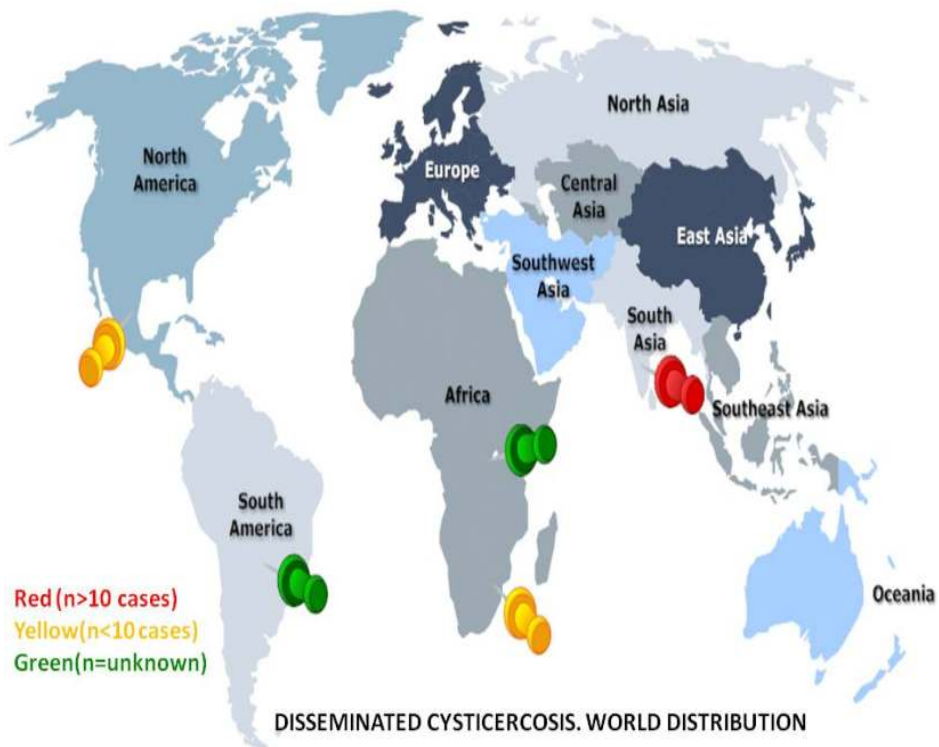


Figure 16. Distribution of disseminated cysticercosis worldwide.

As noted in the previous map there are two large areas in Latin America and Africa where the disease is may be present but the ignored epidemiological conditions of those not having established contact with the civilized world make impossible to predict the possible number of patients although by photos published in Internet we could not identified anyone.

## 7. Mortality rate in disseminated cysticercosis

The mortality rate for the cysticercosis is widespread and extremely low, in our series was always below 0.05 % in the past 15 years.

Based on our experience and in the cases reported in the international medical literature the causes of death are almost always related to the NCC and anecdotal cases secondary to pancreatic or cardiopulmonary complications.

The most frequent cause of death related to the NCC in patients with CCD is the intraventricular NCC with intracranial hypertension by obstructive hydrocephalus, the subarachnoid NCC with cerebrovascular complications, the NCC of the insula with associated neurog enic heart or sudden unexpected death and the massive NCC. When there are more than a thousand cysts in the brain the mortality rate is extremely high (see figure 17).

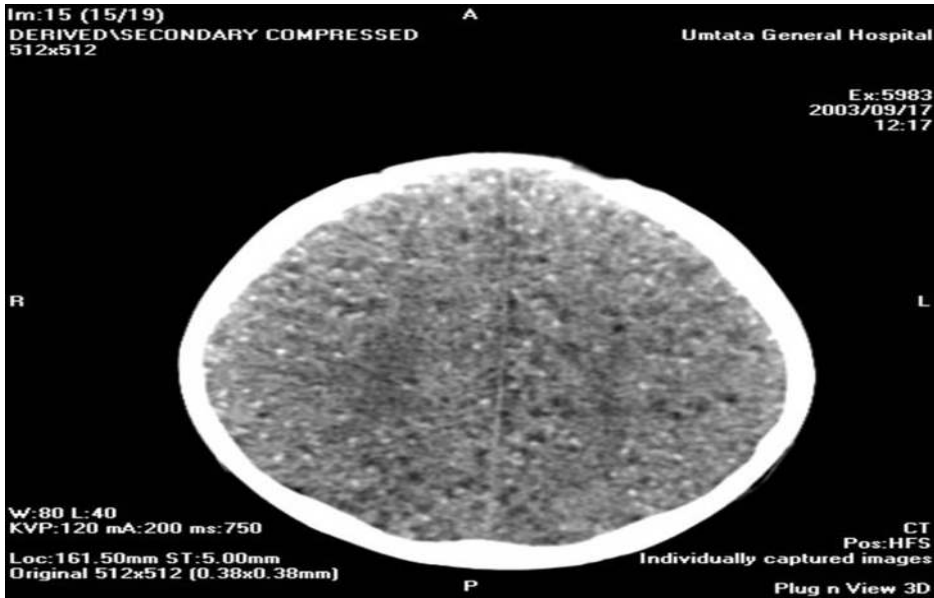


Figure 17. CT scan of the brain showing massive neurocysticercosis.

### 8. Why some cisticercus move to one path while other move to another one?

The cerebellar lesions are an expression of this type of distribution as they generally cisticercotic lesions in the posterior fossa are only seen when there are massive infestations or when the cisticerci traveling through a non-laminar flow secondary to vascular lesions not described in the medical literature (See figure 18).

We think this situation happen because of the haemodynamic characteristic of the blood flow can change in different blood vessel. Let us to explain what probably happen when cisticerci coincide in the same place at the same time. When between two cisticercus in movement speed gradient exists, or is that a moves faster than the other, they develop friccion forces acting tangentially to the same. The friction forces are trying to introduce rotation between the cisticerci in motion, but simultaneously the viscosity seeks to prevent

rotation. Depending on the relative value of these forces can be produce different flow states. When the gradient of speed is low, the inertia force is greater than the friction, the cysticerci move but do not rotate, or they make it but with very little power, the final result is a movement in which the particles follow paths defined, and all of the particles that pass by a point in the field of flow follow the same trajectory. This type of flow was identified by O. Reynolds and is called "laminar", meaning that the particles are moving in the form of layers or sheets. The increase of velocity gradient increases the friction between neighboring cysticercus to the fluid, and these become a significant energy of rotation, the viscosity loses its effect, and due to the rotation of the cysticercus change trajectory. Going from one path to another, the cysticerci collide and change course in erratic. This type of flow is called "turbulent". Turbulent flow can also be due to abnormalities in the wall of blood vessels. The turbulent flow is characterized by:

- The cysticercus in the fluid does not move along with defined trajectories.
- The action of the viscosity is negligible.
- The cysticerci in the fluid possess appreciable energy of rotation, and they move erratically colliding with each other.

When entering the fluid articles to layers of different speed, its linear time increases or decreases, and the particles of the neighboring does so in a manner that is contrary. When the forces of inertia of the fluid in movement are very low, the viscosity is the dominant force and the flow is laminar. When dominated by the forces of inertia the flow is turbulent.

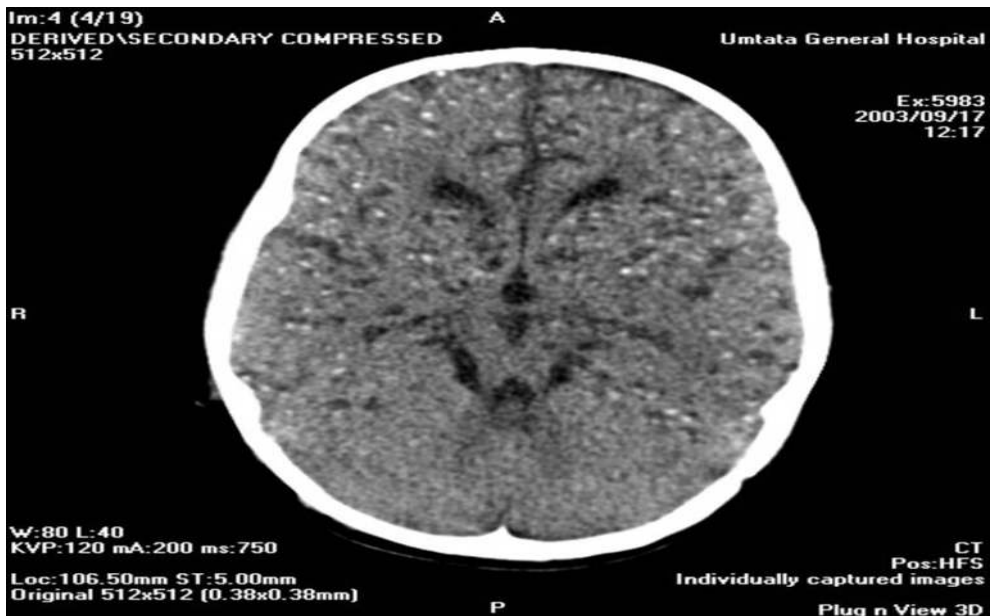


Figure 18. Massive neurocysticercosis showing very few active cerebellar lesions.

## 9. Conclusion

The disseminated cysticercosis is a rare disease and the largest number of cases have been confirmed and published in India. Disseminated cysticercosis is accompanied by neurocysticercosis especially in its intraparenchymal localization but other locations are possible. There have been no reported cases of neurocysticercosis intraventricular associated to disseminated cysticercosis.

Apart from the subcutaneous tissue, muscles and the brain, the organ most frequently affected is the heart and the disorder of cardiac conduction is the main problem. Orbital cysticercosis (intra or extra ocular) is not associated with the disseminated cysticercosis in South Africa while in India makes it with more frequency.

At the present time, DCC seems to be not associated to HIV infections.

The low prevalence of the disseminated cysticercosis does not mean that cysticercosis is about to disappear in the near future.

It is possible that the defining characteristics of blood flow may be determined by the erratic locations of cysticerci, but well designed hemodynamic studies are needed to demonstrate this hypothesis.

## Author details

Humberto Foyaca Sibat and Lourdes de Fátima Ibañez Valdés  
*Walter Sisulu University, Faculty of Health Sciences, Nelson Mandela Academic Hospital,  
Department of Neurology, Mthatha, South Africa*

## Acknowledgement

We like to thanks to all veterinarian researches working on this field.

We also want to thank to all radiologists and radiographers from Nelson Mandela Academic Hospital and Inkhosi Albert Luthuli Central Hospital in South Africa for their contribution to this study.

Special thanks are due to the Cuban Ministry of Health and Institute of Tropical Medicine “Pedro Kouri”, and authorities of Nelson Mandela Academic Hospital, School of Medicine, Faculty of Health Sciences and Directorate: Research Development from Walter Sisulu University for their kind support. Finally, we would like to declare our eternal and deepest gratitude to Lorna María Foyaca García, Fátima Susana Foyaca Ibañez and Thabo Humberto Foyaca Ibañez for their delight support.

Hereby, we acknowledge financial support from the South African Medical Research Council. The founder had no role in study design, data collection and analysis, decision to publish, or preparation of the manuscript

## 10. References

- [1] Foyaca-Sibat H. Epilepsy Secondary to Parasitic Zoonoses of the Brain, Novel Aspects on Epilepsy, Humberto Foyaca-Sibat (Ed.), ISBN: 978-953-307-678-2, InTech, Rijeka, 2011.
- [2] Woolhouse M.E.J, Gowtage-Sequeria S. Host range and emerging and reemerging pathogens. *Emerg Infect Dis.* 2005;11:1842-1847.
- [3] Bautista IR. Neurocysticercosis una realidad y sus limitantes en el diagnóstico. SIRIVS. Curso: Investigación II. Maestría en Salud Animal. Universidad Nacional Mayor de San Marcos Facultad de Medicina Veterinaria.2008
- [4] Garg RK. Neurocysticercosis. *Postgrad Med J* 1998; 74(872):321-326.
- [5] White AC Jr. Neurocysticercosis: updates on epidemiology, pathogenesis, diagnosis and management. *Ann Rev Med* 2000;51:187-206.
- [6] Uddin J, Gonzalez AE, Gilman RH, Thomas LH, Rodriguez S, Evans CA, Remick DG, Garcia HH, Friedland JS. Mechanisms regulating monocyte CXCL8 secretion in neurocysticercosis and the effect of antiparasitic therapy. *J Immunol.* 2010;185(7):4478-4484.
- [7] Wadia N, Desai S, Bhatt M: Disseminated cysticercosis. New observations, including CT scan findings and experience with treatment by praziquantel. *Brain* 1988, 111:597-614.
- [8] Bhalla A, Sood A, Sachdev A, Varma V. Disseminated cysticercosis: a case report and review of the literature *Medical Case Reports* 2008; 2:137-140.  
<http://www.jmedicalcasereports.com/content/2/1/137> (accessed May 04, 2012).
- [9] Sarti E, Schantz PM, Plancharte A, Wilson M, Gutierrez R, Lopez AS, Roberts J, Flisser. Prevalence and risk factor for *Taenia solium* taeniasis and cysticercosis in humans and pigs in a village in Morelos, Mexico. *Am J Trop Med Hyg* 1992; 46:677-684.
- [10] Foyaca-Sibat H, Ibañez-Valdés L de F. Clinical trial of praziquantel and prednisone in rural patients with neurocysticercosis presenting recurrent epileptic attacks *The Internet Journal of Neurology* 2002;2):41-50.  
[http://www.ispub.com/journal/the\\_internet\\_journal\\_of\\_neurology/volume\\_1\\_number\\_2\\_39/article/clinical\\_trial\\_of\\_praziquantel\\_and\\_prednisone\\_in\\_rural\\_patients\\_with\\_neurocysticercosis\\_presenting\\_with\\_recurrent\\_epileptic\\_attacks.html](http://www.ispub.com/journal/the_internet_journal_of_neurology/volume_1_number_2_39/article/clinical_trial_of_praziquantel_and_prednisone_in_rural_patients_with_neurocysticercosis_presenting_with_recurrent_epileptic_attacks.html)
- [11] Foyaca-Sibat H, "Tapeworm and the brain" *Journal of Sciences of Africa* 2002;1:5-12.  
<http://www.scienceofafrica.co.za/2002/june.worn.htm>
- [12] Foyaca-Sibat H, Ibañez-Valdés L de F "Neurocysticercosis in HIV-positive patients" *The Internet Journal of Infectious Diseases* 2003;2(2):15-23.
- [13] Foyaca-Sibat H, Ibañez-Valdés L de F & J. Moré-Rodríguez : Parasitic Zoonoses Of The Brain: Another Challenger?. *The Internet Journal of Neurology.* 2010;12(2).  
[http://www.ispub.com/journal/the\\_internet\\_journal\\_of\\_neurology/volume\\_12\\_number\\_2\\_4/article/parasitic-zoonoses-of-the-brain-another-challenger.html](http://www.ispub.com/journal/the_internet_journal_of_neurology/volume_12_number_2_4/article/parasitic-zoonoses-of-the-brain-another-challenger.html)
- [14] Foyaca-Sibat H and Ibañez-Valdés L de F. editor . Treatment of Epilepsy Secondary to Neurocysticercosis, Novel Treatment of Epilepsy. InTech, Rijeka, 2011

- [15] Foyaca-Sibat H and Lourdes de Fátima Ibañez Valdés L de F (2011). Clinical Features of Epilepsy Secondary to Neurocysticercosis at the Insular Lobe, Novel Aspects on Epilepsy. InTech, Rijeka, 2011.
- [16] McComick G, Zec Chi-S, Heiden J. Cysticercosis Cerebri. Review of 127 cases. *Arch Neurol* 1982; 39:534-539.
- [17] Pfuetzenreiter MR, de Avila-Pires FD. Clinical manifestations in patients with computerized tomography diagnosis of Neurocysticercosis. *Arq Neuropsiquiatr* 1999;57(3A):653-658.
- [18] Agapejev S. Epidemiology of Neurocysticercosis. in Brazil. *Rev Inst Med Trop Sao Paulo* 1996;38(3):207-216.
- [19] Doder R, Madle-Samardzija N, Canak G, Vukadinov J, Tukulov V, Singhi sincerely. Neurocysticercosis-5 years' experience at the Clinic for Infectious Diseases. *Med Pregl* 2002; 55(11-12):523-527.
- [20] Mafojane NA, Appleton CC, Krecek RC, Michael LM & Willingham AL, III The current status of neurocysticercosis in Eastern and Southern Africa. *Acta Tropica* 2003;87: 25–33.
- [21] Villa AM, Monteverde DA, Rodríguez W, Boero A, Sica RE. Neurocysticercosis in a hospital of the city of Buenos Aires: study of 11 cases. *Arq Neuropsiquiatr* 1993;51(3):336-336.
- [22] García HH, Gonzalez AE, Evans CA, Gilman RH; Cysticercosis Working Group in Peru. *Taenia solium* cysticercosis. *Lancet*. 2003; 362: 547-556.
- [23] García HH, Del Brutto OH; Cysticercosis Working Group in Peru. Neurocysticercosis: updated concepts about an old disease. *Lancet Neurol*. 2005; 4:653-661.
- [24] ] Takayanagui OM, Jardim E. Clinical aspects of neurocysticercosis: analysis of 500 cases. *Arq Neuropsiquiatr* 1983; 41(1):50-63.
- [25] Takayanagui OM. Neurocysticercosis: I.Clinical and laboratory course of 151 cases. *Arq Neuropsiquiatr* 1990; 48(1):1-10.
- [26] Takayanagui OM, Leite JP. Neurocysticercosis. *Rev Soc Bras Med Trop* 2001;34(3):283-290.
- [27] Pitella JEH. Neuro schistosomiasis. *Brain Pathol* 1997;7:649-662.
- [28] Sanchez, A.L.; Lindback, J.; Schantz, P.M.; Sone, M.; Sakai, H.; Medina, M.T. & Ljungstrom I. A population based case-control study of *Taenia solium* taeniosis and cysticercosis. *Ann Tropical Medical Parasitology* 1999;93: 247-258.
- [29] Morales NM, Agapejev S, Morales RR, Padula NA, Lima MM. Clinical aspects of neurocysticercosis in children. *Pediatr Neurol* 2000; 22(4):287-291.
- [30] Varma A, Gaur KJ. The clinical spectrum of Neurocysticercosis in the Uttaranchal region. *Assoc Physicians India* 2002;50:1398-1400.
- [31] Scharf D. Neurocysticercosis. Two hundred thirty-eight cases from a California Hospital. *Arch Neurol* 1988; 45:777-780.
- [32] Foyaca-Sibat H, Del Rio- Romero AI: Prevalence of Epilepsy in an Endemic Area For Neurocysticercosis In South Africa. *The Internet Journal of Neurology*.2008;9(1):8-18. [http://www.ispub.com/journal/the\\_internet\\_journal\\_of\\_neurology/volume\\_9\\_number\\_1\\_6/article/prevalence\\_of\\_epilepsy\\_in\\_an\\_endemic\\_area\\_for\\_neurocysticercosis\\_in\\_south\\_africa.html](http://www.ispub.com/journal/the_internet_journal_of_neurology/volume_9_number_1_6/article/prevalence_of_epilepsy_in_an_endemic_area_for_neurocysticercosis_in_south_africa.html)

- [33] Turkulov V, Madle-Samardzija N, Canak G, Vukadinov J, Aleksic-Dordevic M. Clinical and diagnostic approaches to neurocysticercosis. *Med Pregl* 2001; 54(7-8):353-356.
- [34] Sotelo J, Guerrero V, Rubio F. Neurocysticercosis: a new classification based on active and inactive forms. *Arch Intern Med.* 1985;145:442-445.
- [35] Singh G. Neurocysticercosis in South-Central America and the Indian subcontinent. A comparative evaluation. *Arq Neuropsiquiatr* 1997; 55(3A):349-356.
- [36] Del Brutto OH. Neurocysticercosis. *Rev Neurol* 1999; 29(5):4456-4466.
- [37] Salata et al. Parasitic Infections of the Central Nervous System p 821. In Aminoff MJ et al., (eds) the Neurology and General Medicine. Churchill Livingstone, Philadelphia 2001
- [38] Sotelo J, Penagos P, Escobedo F, Del Brutto OH: Short course of albendazole therapy for neurocysticercosis. *Arch Neurol* 45:1130-1133, 1988.
- [39] Flisser A. Cisticercosis subcutáneo. *Ciencias*, UNAM 2011.  
<http://hydra.ciencias.unam.mx:8080/xmlui/handle/123456789/62343?show=full>  
(accessed May 04, 2011)
- [40] Bielsa-Fernández MV. Hallazgo incidental de cisticercosis generalizada *Rev Gastroenterol (Mex)* 2011;76(2):169-170.
- [41] Foyaca-Sibat H, Ibanez-Valdes LdeF, Mashiyi MK. Disseminate Cysticercosis. One-day treatment in a case. *Rev Electron Biomed / Electron J Biomed* 2004;3:39-43.  
<http://biomed.uninet.edu/2004/n3/foyaca-n.html> (accessed 05 May, 2012).
- [42] Park SY, Min HK, Jung HK, Kwan YS. Disseminated cysticercosis. *Journal of Korean Neurosurgical Society.* 2011;49(3):190-193.
- [43] Basu G, Surekha V, Ganesh A. Disseminated cysticercosis. *Trop Doct.* 2009;39(1):48-99.
- [44] Pushker N, Bajaj MS, Balasubramanya R. Disseminated cysticercosis involving orbit, brain and subcutaneous tissue. *J Infect.* 2005;51(5):245-248.
- [45] ] Narang P, Chhibbers S, Puri SK. Middle-aged man with altered behaviour and seizures. *The British Journal of Radiology*, 81 (2008), 984-986.
- [46] Jakhere SG, Chemburkar VC, Yeragi BS, Bharambay HV. Imaging findings of disseminated cysticercosis with unusual involvement of spleen and pancreas. *J Glob Infect Dis.* 2011 Jul;3(3):306-308.
- [47] Sandeep GJ, Vipul CC, Bhakti SY, Himanshu VB. Imaging Findings of Disseminated Cysticercosis with Unusual Involvement of Spleen and Pancreas. *J Glob Infect Dis.* 2011;3(3):306-308.
- [48] Niakara A, Cisse R, Traore A, Niamba PA, et al. Myocardial localization of a disseminated cysticercosis. Echocardiographic diagnosis of a case. *Arch Mal Coer Vaiss* 2002;95(6):606-608.
- [49] Blandon R, Leandro IM: Human Cardiac cysticercosis. *Rev Med Panama.* 2002; 27:37-40.
- [50] Foyaca-Sibat H, L. Ibanez-Valdes L: Generalized Cysticercosis With Cardiac Involvement. *The Internet Journal of Neurology.* 2007 Volume 7 Number 2.  
<http://www.ispub.com/journal/the-internet-journal-of-neurology/volume-7-number-2/generalized-cysticercosis-with-cardiac-involvement.html>. (accessed 05 May 2012)

- [51] Thomas MB, Thomas KM, Awotedu AA, Blanco-Blanco E, Anwary M. Cardiocysticercosis. *S Afr Med J* 2007;97(7):504-505.
- [52] Eberly MD, Soh EK, Bannister SP, Taraf-Motamen H, Scott JS: Isolated Cardiac Cysticercosis in an adolescent; *Pediatr Infect Dis J.* 2008; 27(4); 369-71.
- [53] Jain BK, Sankhe SS, Agrawal MD, Naphade PS. Disseminated cysticercosis with pulmonary and cardiac involvement. *Indian J Radiol Imaging* 2010;20:310-313.
- [54] Scholtz L & Mentis H, Pulmonary cysticercosis. *SAMT* 1987 ;72(17) :573
- [55] Mamere AE, Muglia VF, Simao GN, Belucci AD, Carlos dos Santos A, Trad CS, et al. Disseminated cysticercosis with pulmonary involvement. *J Thorac Imaging* 2004;19:109–111.
- [56] Banu A, Veena N. A rare case of disseminated cysticercosis: Case report and literature review. *Case Report.* 2011;29(2):180-183.
- [57] Bhigjee AI, Rosemberg S. Neurology. Optimizing therapy of seizures in patients with HIV and cysticercosis. *Neurology* 2006;67(12 Suppl 4):19-22.
- [58] Scholtz L, Mentis H. Pulmonary cysticercosis. *SAMT*1987; 72( 1): 573.
- [59] Bhigjee AI. Disseminated cysticercosis. *J Neurol Neurosurg Psychiatry* 1999;66(4):545
- [60] Thomas MB, Thomas KM, Awotedu AA, Blanco-Blanco E, Anwary M. Cardiocysticercosis. *South Africa Medical Journal.* 2007; 97(7): 504-505
- [61] Sobnach S, Khosa SA, Pather S, Longhurst S, Kahn D, Raubenheimer PJ. First case report of pharyngeal cysticercosis. *Trans R Soc Trop Med Hyg.* 2009;103(2):206-208.
- [62] Foyaca-Sibat H, Ibañez-Valdés LdeF. "Pseudoseizures and Epilepsy in neurocysticercosis" *Electron J Biomed* 2003;2(2):20-29.  
<http://www.uninet.edu/reb/2003/n2/2foyaca.html>
- [63] Ibañez-Valdés LdeF, Foyaca-Sibat H. Refractory epilepsy in neurocysticercosis. *The Internet Journal of Neurology* 2006;5(2):34-41.  
[http://www.ispub.com/journal/the\\_internet\\_journal\\_of\\_neurology/volume\\_5\\_number\\_2\\_19/article/refractory\\_epilepsy\\_in\\_neurocysticercosis.html](http://www.ispub.com/journal/the_internet_journal_of_neurology/volume_5_number_2_19/article/refractory_epilepsy_in_neurocysticercosis.html)
- [64] Foyaca-Sibat H. Ibañez-Valdés LdeF. Insular Neurocysticercosis: Our Finding and Review of the Medical Literature. *The Internet Journal of Neurology* 2006;5(2).  
[http://www.ispub.com/journal/the\\_internet\\_journal\\_of\\_neurology/volume\\_5\\_number\\_2\\_19/article/insular\\_neurocysticercosis\\_our\\_findings\\_and\\_review\\_of\\_the\\_medical\\_literature.html](http://www.ispub.com/journal/the_internet_journal_of_neurology/volume_5_number_2_19/article/insular_neurocysticercosis_our_findings_and_review_of_the_medical_literature.html)
- [65] Foyaca-Sibat H, Del Rio AR, Ibañez-Valdés LdeF, Vega-Novoa EC, Awotedu A. "Neuroepidemiological survey for Epilepsy and knowledge about neurocysticercosis at Sidwadweni location, South Africa" *Electron J Biomed* 2004;2(1):40-48.  
<http://www.biomed.edu/2004/n1/foyaca.html>
- [66] Foyaca-Sibat H, Del Rio-Romero AH, Ibañez-Valdés LdeF, Vega-Novoa E. Neuroepidemiological Survey For Epilepsy And Knowledge About Neurocysticercosis At Ngqwala Location, South Africa. *The Internet Journal of Neurology* 2005 3(2).  
[http://www.ispub.com/journal/the\\_internet\\_journal\\_of\\_neurology/volume\\_3\\_number\\_2\\_31/article/neuroepidemiological\\_survey\\_for\\_epilepsy\\_and\\_knowledge\\_about\\_neurocysticercosis\\_at\\_ngqwala\\_location\\_south\\_africa.html](http://www.ispub.com/journal/the_internet_journal_of_neurology/volume_3_number_2_31/article/neuroepidemiological_survey_for_epilepsy_and_knowledge_about_neurocysticercosis_at_ngqwala_location_south_africa.html)



- [67] Foyaca-Sibat H, Del Rio-Romero A, Ibañez-Valdés LdeF Prevalence Of Epilepsy And General Knowledge About Neurocysticercosis At Ngangelizwe Location, South Africa . *The Internet Journal of Neurology*. 2005;4 (1).  
[http://www.ispub.com/journal/the\\_internet\\_journal\\_of\\_neurology/volume\\_4\\_number\\_1\\_30/article/prevalence\\_of\\_epilepsy\\_and\\_general\\_knowledge\\_about\\_neurocysticercosis\\_at\\_ngangelizwe\\_location\\_south\\_africa.html](http://www.ispub.com/journal/the_internet_journal_of_neurology/volume_4_number_1_30/article/prevalence_of_epilepsy_and_general_knowledge_about_neurocysticercosis_at_ngangelizwe_location_south_africa.html)
- [68] Foyaca-Sibat H, Del Rio A: "Epilepsy, Neurocysticercosis and, Poverty at Mphumaze and Marhambeni Locations, in South Africa". *The Internet Journal of Neurology* ( ISSN: 1531-295X). 2007;7(1):8-14.  
[http://www.ispub.com/journal/the\\_internet\\_journal\\_of\\_neurology/volume\\_7\\_number\\_1\\_7/article/epilepsy\\_neurocysticercosis\\_and\\_poverty\\_at\\_mphumaze\\_and\\_marhambeni\\_locations\\_in\\_south\\_africa.html](http://www.ispub.com/journal/the_internet_journal_of_neurology/volume_7_number_1_7/article/epilepsy_neurocysticercosis_and_poverty_at_mphumaze_and_marhambeni_locations_in_south_africa.html)
- [69] Foyaca-Sibat H, Ibañez-Valdés LdeF, Del Rio IA: "Prevalence of Epilepsy and General Knowledge about Neurocysticercosis at Ngangelizwe Location, South Africa". *The Internet Journal of Neurology*.( ISSN: 1531-295X). 2005; 4(1):23-37.  
[http://www.ispub.com/journal/the\\_internet\\_journal\\_of\\_neurology/volume\\_4\\_number\\_1\\_30/article/prevalence\\_of\\_epilepsy\\_and\\_general\\_knowledge\\_about\\_neurocysticercosis\\_at\\_ngangelizwe\\_location\\_south\\_africa.html](http://www.ispub.com/journal/the_internet_journal_of_neurology/volume_4_number_1_30/article/prevalence_of_epilepsy_and_general_knowledge_about_neurocysticercosis_at_ngangelizwe_location_south_africa.html)
- [70] Foyaca-Sibat H, Del Rio- Romero AI: "Prevalence Of Epilepsy In An Endemic Area For Neurocysticercosis In South Africa". *The Internet Journal of Neurology*.( ISSN: 1531-295X). 2008;9(1):8-18.  
[http://www.ispub.com/journal/the\\_internet\\_journal\\_of\\_neurology/volume\\_9\\_number\\_1\\_6/article/prevalence\\_of\\_epilepsy\\_in\\_an\\_endemic\\_area\\_for\\_neurocysticercosis\\_in\\_south\\_africa.html](http://www.ispub.com/journal/the_internet_journal_of_neurology/volume_9_number_1_6/article/prevalence_of_epilepsy_in_an_endemic_area_for_neurocysticercosis_in_south_africa.html)
- [71] Del Rio- Romero A, Foyaca-Sibat H, Ibañez-Valdés LdeF: Neuroepidemiology Findings As Contributors For Epilepsy Due To Neurocysticercosis At Mngceleni Location, South Africa . *The Internet Journal of Neurology*. 2008 Volume 9 Number 1.  
[http://www.ispub.com/journal/the\\_internet\\_journal\\_of\\_neurology/volume\\_9\\_number\\_1\\_6/article/neuroepidemiology\\_findings\\_as\\_contributors\\_for\\_epilepsy\\_due\\_to\\_neurocysticercosis\\_at\\_mngceleni\\_location\\_south\\_africa.html](http://www.ispub.com/journal/the_internet_journal_of_neurology/volume_9_number_1_6/article/neuroepidemiology_findings_as_contributors_for_epilepsy_due_to_neurocysticercosis_at_mngceleni_location_south_africa.html)
- [72] Kumar A, Goenka AH, Choudhary A, Sahu JK, Gulati S. Disseminated cysticercosis in a child: whole-body MR diagnosis with the use of parallel imaging. *Pediatr Radiol*. 2010;40(2):223-227.
- [73] Del Brutto OH, Rajshekhar V, White AC jun., *et al*. Proposed diagnostic criteria for neurocysticercosis. *Neurology* 2001; 57: 177-183.
- [74] Hoberg EP, Alkire NL, de Queiroz A, and Jones A. Out of Africa: origins of the Taenia tapeworms in humans. *Proc. R. Soc. Lond.B* 2001;268:781-787.
- [75] Heslip , S. 2001. Time-Space chart. ANP440. Hominid fossils. Spring Semester, 2001.  
<http://www.msu.edu/~heslipst/contents/ANP440/index.htm> (accessed 07 May, 2012).
- [76] Critical Issues in Researching Hidden Communities. University of Glasgow,  
<http://www.gla.ac.uk/departments/esharp/otherpublications/specialissues/hiddencommunities/>

- [77] Wikipedia, the free encyclopedia: Mbuti people.  
[http://en.wikipedia.org/wiki/Mbuti\\_people](http://en.wikipedia.org/wiki/Mbuti_people). (accessed 08May, 2012).
- [78] Wikipedia, the free encyclopedia: Indigenous peoples of the Americas.  
[http://en.wikipedia.org/wiki/Indigenous\\_peoples\\_of\\_the\\_Americas](http://en.wikipedia.org/wiki/Indigenous_peoples_of_the_Americas). (accessed 08, May, 2012).
- [79] Wikipedia, the free encyclopedia: Uncontacted peoples.  
[http://en.wikipedia.org/wiki/Uncontacted\\_peoples](http://en.wikipedia.org/wiki/Uncontacted_peoples).
- [80] Survival International website - About Us/Work for Survival.
- [81] Wikipedia, the free encyclopedia: Survival International.  
[http://en.wikipedia.org/wiki/Survival\\_International](http://en.wikipedia.org/wiki/Survival_International)
- [82] Shanley JD, Jordan MC: Clinical aspects of CNS cysticercosis. *Arch Inter Med* 1980;140:1309-1315.
- [83] Loo L, Braude A: Cerebral cysticercosis in San Diego: a report of 23 cases and review of the literature. *Medicine* (Baltimore) 1982;61:341-350.
- [84] McComick G, Zec Chi-S, Heiden J. Cysticercosis Cerebri. Review of 127 cases. *Arch Neurol* 1982; 39:534-539.
- [85] Schantz PM, Moore AC, Muñoz JL, et al.: Neurocysticercosis in an Orthodox Jewish community in New York City. *N England J Med* 1992;327:692-696.
- [86] White AC Jr. Neurocysticercosis: a major cause of neurological disease worldwide. *Clin Infect Dis* 1997;24:101-106.
- [87] White AC Jr. Neurocysticercosis: updates on epidemiology, pathogenesis, diagnosis and management. *Ann Rev Med* 2000;51:187-206.
- [88] Rousseau MC, Guillotel B, Delmont J. Neurocysticercosis in the South-East of France 1988-1998. *Presse Med* 1999;28(39):2141-2144.
- [89] García HH, Del Brutto OH; Cysticercosis Working Group in Peru. Neurocysticercosis: updated concepts about an old disease. *Lancet Neurol*. 2005; 4:653-661.
- [90] O'Neal S, Noh J, Wilkins P, Keene W, Lambert W, Anderson J, Compton Luman J, Townes J. *Taenia solium* Tapeworm Infection, Oregon, 2006-2009. *Emerg Infect Dis*. 2011;17(6): 1030-1036.
- [91] Kelesidis T, Tsiodras S. Extraparenchymal neurocysticercosis in the United States: a case report. *Journal of Medical Case Reports* 2011;5:359 .
- [92] Serpa JA, Gravis EA, Kas Js, White ACJr. Neurocysticercosis in Houston, Texas: an update. *Medicine* (Baltimore) 2011;90(1):81-86.
- [93] Wallin M, Kurtzke J. Neurocysticercosis in the United States: review of an important emerging infection. *Neurology* 2004; 63: 1559-1564.
- [94] Saxena H, Samuel KC, Singh B. Cysticercosis of the heart. *Indian Heart J* 1972;24: 313-315.
- [95] Niakara A, Cisse R, Traore A, et al. Myocardial localization of a disseminated cisticercosis.
- [96] Cutrone JA, Georgiou D, Gil-Gomez C, Burndage BH. Myocardial cysticercosis detected by ultrafast CT. *Chest* 1995; 108:1752-1754.

- [97] Rahalkar MD, Shetty DD, Kelkar AB, Kelkar AA, Kinare AS, Ambardekar ST. The many faces of cysticercosis. *Clin Radiol* 2000; 55 (9): 668-674.
- [98] Ibarra-Perez C, Fernandez-Diez J, Rodriguez-Trujillo F. Myocardial cysticercosis, report of two cases with coexisting heart disease. *South Med J* 1972; 65: 484-486;
- [99] Deshpande VL, Patil SD. Silent myocardial cysticercosis. *Indian Heart J* 1976; 28(1): 58-60.
- [100] Belagavi CS, Goravalingappa JP. Cysticercosis of the heart. A case report. *Indian Heart J* 1978;30: 118-119.)
- [101] Wadia N, Deasi S, Bhat M. Disseminated cysticercosis; new observations, including CT scan finding and experience with treatment by praziquantel. *Brain* 1988; 111: 597-614;
- [102] Hidron A, Vogenthaler N, Santos-Preciado JL, Rodriguez-Morales AJ, Franco-Paredes C, Rassi A. Cardiac Involvement with Parasitic Infections. *Clin. Microbiol. Rev.* 2010; 23(2): 324-349.
- [103] Botero, D., H. B. Tanowitz, L. M. Weiss, and M. Wittner. 1993. *Taeniasis and cysticercosis*. *Infect. Dis. Clin. North Am.* 7:683-697.
- [104] Lino, R. D. S, Ribeiro PM, Antonelli EJ, Faleiros AC, Terra SA, dos Reis MA, Teixeira VDPA.. Developmental characteristics of *Cysticercus cellulosae* in the human brain and heart. *Rev. Soc. Bras. Med. Trop.* 2002;35:617-622. (In Portuguese.)
- [105] Schantz, P. M., M. Cruz, E. Sarti, and Z. Pawlowski. 1993. Potential eradicability of taeniasis and cysticercosis. *Bull. Pan Am. Health Organ.* 27:397-403.
- [106] Cutrone JA, Georgiou D, Gil-Gomez C, Burndage BH. Myocardial cysticercosis detected by ultrafast CT. *Chest* 1995; 108:1752-1754.)
- [107] Niakara A, Cisse R, Traore A, Niamba PA, Barro F, Kabore J. Myocardial localization of a disseminated cysticercosis. Echocardiography diagnosis of a case. *Arch Mal Coer Vaiss* 2002;95(6):606-608
- [108] Asrani A, Morani A. Primary Sonographic Diagnosis of Disseminated Muscular Cysticercosis. *J Ultrasound Med* 2004; 23:1245-1248
- [109] Takayanagui MO, Chimelli L. Disseminated muscular cysticercosis with myositis induced by praziquantel therapy. *Am J Trop Med Hyg* 1998; 56: 1002-1003.)
- [110] Kirchhoff LV, Weiss LM, Wittner M, Tanowitz HB. Parasitic diseases of the heart. *Front Biosci.* 2004 Jan 1;9:706-23.
- [111] Eberly MD, Soh EK, Bannister SP, Tavaf-Motamen H, Scott JS. Isolated cardiac cysticercosis in an adolescent. *Pediatr Infect Dis J.* 2008 Apr;27(4):369-71.
- [112] Shogan PJ, Yasmer JF, Monson M. Cardiac Cysticercosis. *AJR* 2009;192(5): xxx
- [113] Strawter C, Quiroga P, Zaidi S, Ardiles T. Pulmonary nodules with cutaneous manifestations: A case report and discussion. *Southwest J Pulm Crit Care* 2012;4:116-121.
- [114] Bassermann FJ. Radiographic problems in pulmonary cysticercosis. *PTax Klin001 Pneumo.* 1971;11:669-676.
- [115] Veliath AJ, Ratnalcar C, Thalcur Le. Cysticercosis in south India. *J TTop Med Hyg* 1985; 1: 25-29.
- [116] Scholtz L, Mentis H. Pulmonary cysticercosis. *SAMT*1987; 72( 1): 573.

- [117] Walts AE, Nivatpumin T, Epstein A. Pulmonary cysticercus. *Mod Pathol* 1995;8:299-302.
- [118] Choi JH, et al. A case of pulmonary cysticercosis. *The Korean Journal of Internal Medicine*.1991;6(1):38-43.
- [119] Singh P, Saggar K, Kalia V, Sandhu P, Galhotra RD. Thoracic imaging findings in a case of disseminated cysticercosis. *Postgrad Med J*.2011;87:158-159.
- [120] Iwatani K, Kubota I, Hirotsu I, Wakimoto J, Yoshioka M, Mori T, et al. Sparganum mansoni parasitic infection in the lung showing a nodule. *Pathology International* 2006;56 (11):674-677.
- [121] Mauad T, Battlehner CN, Bedrikow CL, Capelozzi VL, Nascimento Saldiva PH. Massive Cardiopulmonary Cysticercosis in a Leukemic Patient, *Pathology Research and Practice*.1997;193(7):527-529.
- [122] Bastos AL, Marchiori E, Gasparetto EL, Andrade BH, Junior GC, Carvalho RC, Escuissato DL, Souza AS. Pulmonary and cardiac cysticercosis: helical CT findings. *British Journal of Radiology* .2007; 80(951):58-60.
- [123] Jain BK, Sankhe SS, Agrawal MD, Naphade PS. Disseminated cysticercosis with pulmonary and cardiac involvement. *Indian J Radiol Imaging*. 2010; 20(4):310–313.
- [124] ] Cheung YY, Steinbaum S, Yuh WT, Chiu L. MR findings in extracranial cysticercosis. *J Comput Assist Tomogr*. 1987 Jan-Feb;11(1):179-81.
- [125] Gupta S, Jain VK, Sen J, Gupta S, Arora B. Subcutaneous cysticercosis involving the eyelid: sonographic diagnosis. *J Dermatol* 2000; 27:35–39.
- [126] Chadha V, Pandey PK, Chauhan D, Das S. Simultaneous intraocular and bilateral extraocular muscle involvement in a case of disseminated cysticercosis. *Int Ophthalmol*. 2005 Feb-Apr;26(1-2):35-7. Epub 2006 Jun 15.
- [127] Pushker N, Bajaj MS, Balasubramanya R. Disseminated cysticercosis involving orbit, brain and subcutaneous tissue. *J Infect*. 2005;51(5):245-248.
- [128] Nijjar I, Singh JP, Arora V, Abrol R, Sandhu PS, Chopra R, et al. MRI in intraocular cysticercosis - A case report. *Indian J Radiol Imaging*. 2005;15:309–10.
- [129] Devi S, Singh B, Singh S, Singh B, Singh J, Chingsuingamba Y. A rare case of disseminated cysticercosis. *Neurology Asia* 2007;12 :127 –130.
- [130] Kadhiravan T, Soneja M , Hari S , Sharma SK. Images in Clinical Tropical Medicine. Disseminated Cysticercosis. *Am. J. Trop. Med. Hyg*.2009; 80(5):699.
- [131] Pushker N, Mehta M, Meel R, Bajaj MS. Disseminated cysticercosis with multiple bilateral orbital cysts. *Ophthal Plast Reconstr Surg*. 2009 Nov-Dec;25(6):499-501.
- [132] Tamilarasu K, Manish S, Smriti H; Surendra SK. Images in clinical tropical medicine: disseminated cysticercosis *The American Journal of Tropical Medicine and Hygiene*, 2009;80 (5):699
- [133] Pandey PK, Chaudhuri Z, Bhatia A. Extraocular muscle cysticercosis presenting as Brown syndrome. *Am J Ophthalmol*. 2001 Apr; 131(4):526-527.
- [134] Sundaram PM, Jayakumar N, Noronha V. Extraocular muscle cysticercosis - a clinical challenge to the ophthalmologists. *Orbit*. 2004 Dec; 23(4):255-262.

- [135] Review Extraocular muscle cysticercosis mimicking idiopathic orbital inflammation: case report. Angotti-Neto H, Gonçalves AC, Moura FC, Monteiro ML. *Arq Bras Oftalmol.* 2007 May-Jun; 70(3):537-9.
- [136] Sharma A, Mahajan C, Rath GP, Mohapatra S, Padhy UP, Kumar L. Neurocysticercosis: Acute presentation and intensive care management of two cases. *Indian J Crit Care Med.* 2011 Jul; 15(3):185-7
- [137] Gangadhar K, Santhosh D. An Uncommon Manifestation of a Common Tropical Disease: Disseminated Cysticercosis. *Neuroradiology Journal* 2012;25(2):200-205.
- [138] Pandey PK, Bhatia A, Garg D, Singh R. Canine tooth syndrome due to superior oblique myocysticercosis. *J Pediatr Ophthalmol Strabismus.* 2006 May-Jun; 43(3):185-187.
- [139] Goenka AH, Garg A. Pseudomuscular male with seizures: disseminated cysticercosis. *Int J Infect Dis.* 2010;14(3):385-387.
- [140] Thomas B, Krishnamoorthy T. Extensive brain and muscular cysticercosis. *Neurology.* 2006;66(3):13.
- [141] Juhl ZK, Løgager VB. Subcutaneous cysticercosis and neurocysticercosis. *Ugeskr Laeger.* 2000 Dec 4;162(49):6691-6692.
- [142] Chopra JS, Nand N, Jain K, Mittal R, Abrol L. Generalized muscular pseudohypertrophy in cysticercosis. *Postgrad Med J* 1986; 62:299–300.
- [143] Kuruvilla A, Pandian J, Nair M, Joseph S. Neurocysticercosis: A clinical and radiological appraisal from Kerala State, South India. *Singapore medical journal.* 2001; 42(7): 297-303.
- [144] Goenka AH, Garg A. Pseudomuscular male with seizures: disseminated cysticercosis. *Int J Infect Dis.* 2010 Sep;14 385-387.
- [145] Satyanarayana S, Gorthi SP, Bhardwaj JR, Nath N, Sharma S. Disseminated Cysticercosis. *J Assoc Physicians India* 2002; 50:1180–1182.
- [146] Saranya D, M Jawahar, K Bhanu. A case of disseminated neurocysticercosis. *Images in Neurology.* 2011;14(1):56-57.
- [147] Kadhivaran T, Soneja M, Hari S, Sharma SK. Images in Clinical Tropical Medicine. Disseminated Cysticercosis. *Am. J. Trop. Med. Hyg.* 2009; 80(5):699.
- [148] Saranya D, Jawahar M, Bhanu K. A case of disseminated neurocysticercosis. *Images in Neurology* 2011;14(1):56-57
- [149] Hashmi MA, Sharma SK, Bera SP, Saha B. Disseminated cysticercus involving the vocal cords. *Annals Tropical Medicine and Public Health.* 2008;1(2):66-67.
- [150] Gupta S, Sodhani P. Clinically Unsuspected Thyroid Involvement in Cysticercosis. A Case Report. *Acta Cytologica* 2010;54(5): 853-856.
- [151] Verma R, Sharma P, Khurana N. Thousands of Lesions in Disseminated Cysticercosis. *Am J Trop Med Hyg.* 2011; 85(4): 583.
- [152] Nakamura-Uchiyama F, Kobayash K, Ohnishi K. *An Imported Case of Disseminated Cysticercosis and Taeniasis.* *Internal Medicine* 2012; 51(3):347-348.
- [153] CCD immunocompromised patient.

- [154] Goenka AH, Kumar A. Whole body MR and disseminated cysticercosis. *Indian J Radiol Imaging.* 2011; 21(2): 157–158.
- [155] Kumar A, Goenka AH, Choudhary A, Sahu JK, Gulati S. Disseminated cysticercosis in a child: whole-body MR diagnosis with the use of parallel imaging. *Pediatr Radiol.* 2010;40(2):223-227.