

---

# **Distraction Osteogenesis in the Treatment of Maxillary Hypoplasia**

---

Sultan Olmez-Gurlen

Additional information is available at the end of the chapter

<http://dx.doi.org/10.5772/62545>

---

## **Abstract**

The aim of this chapter is to review literature reporting on the use of internal distraction osteogenesis and rigid external distraction osteogenesis and to determine the biomechanical effects of internal distractors in the treatment of maxillary hypoplasia, especially in patients with cleft lip and palate (CLP), and compare the results with non-cleft patient. The standard osteotomy used for distraction osteogenesis of the hypoplastic maxilla is LeFort I. An advancement of more than 10 mm in patients with no cleft and 6 mm in patients with CLP is beyond the limit of LeFort I osteotomy, and in such cases distraction osteogenesis for advancement of the maxilla can be used. Distraction osteogenesis (DO) is a biological process involving the formation of new bone between viable bone segments that are gradually separated by incremental traction. The external and internal usage of distraction osteogenesis in the treatment of maxillary hypoplasia in patients with cleft lip and palate is a reliable, reproducible and stable alternative method to conventional one-step LeFort I advancement techniques. Biomechanical evaluation of internal maxillary distraction osteogenesis produces mathematical results to help the surgeon and the orthodontist to understand better the therapeutic effects on the maxillofacial bones and sutures of the craniofacial system.

**Keywords:** maxillary advancement, distraction osteogenesis, cleft lip and palate, finite element analysis, maxillary hypoplasia

---

## **1. Introduction**

Distraction osteogenesis (DO) is an effective method used for bone regeneration. Advancement of the maxilla by use of rigid external distraction (RED) device has been performed

---

successfully and many other internal devices have been introduced for better results regarding the patient's comfort [1].

Patients with cleft lip and palate and maxillary hypoplasia usually present with a collapsed maxillary dental arch and impaired forward and downward growth of the maxilla [2–4]. Two factors have been proposed for the growth deficiency [2]: One such factor is the intrinsic factor, mainly introduced by developmental deficiency leading to the formation of a cleft and the growth potential of midfacial skeleton. The other factor is the iatrogenic factor, including surgical repair. Therefore, management of cleft-related maxillary hypoplasia is more complex due to the larger degree of malocclusion and advancement, the risk of post-surgical relapse and the potential velopharyngeal incompetence following maxillary advancement [1, 5].

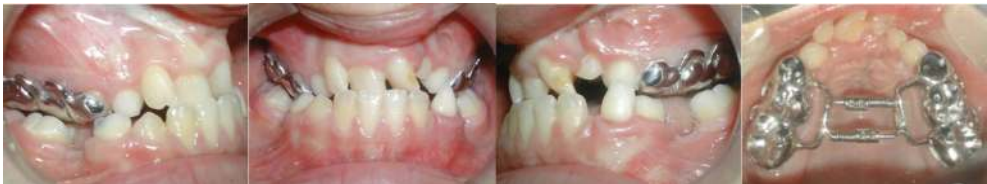The general aim of this chapter is to present a brief review of sagittal distraction osteogenesis in sagittal maxillofacial advancement and the biomechanical effects of maxillary sagittal distraction osteogenesis both in patients with unilateral cleft lip and palate and in patients with no cleft.

## 2. Traditional treatment options for maxillary hypoplasia

Patients with maxillary hypoplasia secondary to orofacial cleft present multiple challenging problems. Traditional orthodontic/orthopaedic approaches to treat these patients, while sometimes successful in obtaining stable occlusal relationships, often fall short of expectations with respect to facial balance and aesthetics.

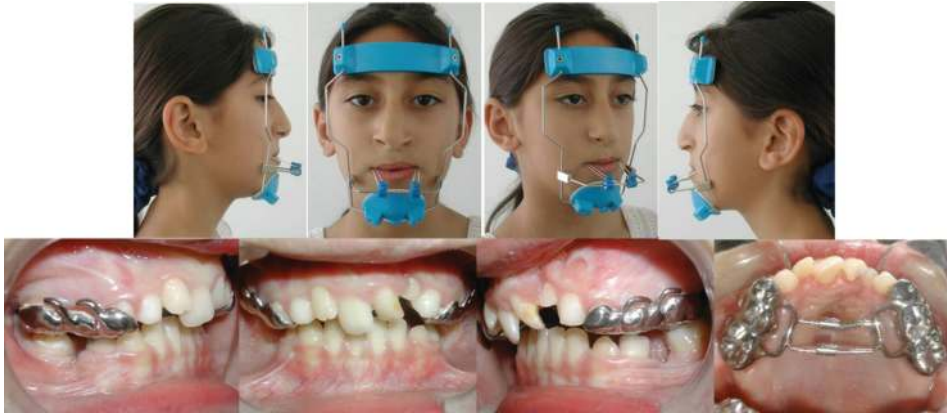
Usual treatment sequence can be explained as follows: (1) at the ages of 5–7 years orthodontic expansion apparatus can be used such as Quad Helix, Spring jet appliance or Hyrax type palatal expanders (**Figure 1**); (2) protraction with facial mask is used at 8 years or later (**Figure 2**); (3) bone grafting harvested from iliac crest is performed at 7–9 years of age (**Figure 3**). To overcome three-dimensional constriction of the maxilla due to the previous surgical scars, different types of therapeutic concepts are used [6].

The patient with complete unilateral cleft lip and palate shown below (**Figures 1–4**) was a rare case that could be treated in terms of only orthodontics and orthopaedics. However, most of

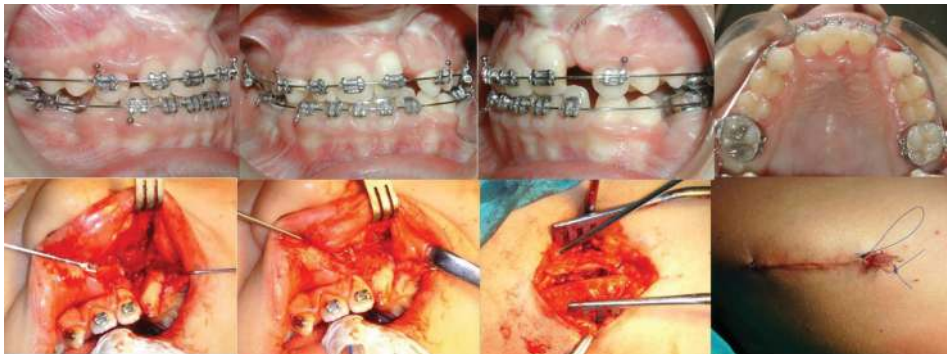


**Figure 1.** An alternative type of maxillary expansion apparatus (Modified spring jet appliance) used in UCLP patients to achieve appropriate transversal dimension in the maxillary arch.

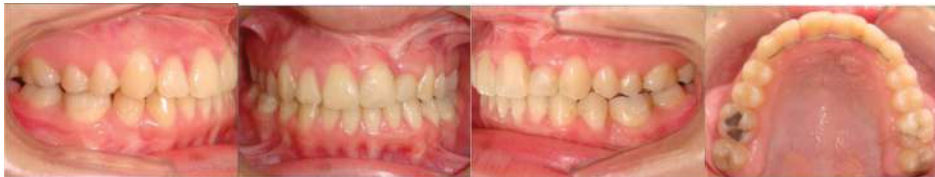the patients need surgical intervention to overcome both intrinsic and iatrogenic factors that caused serious maxillary hypoplasia.



**Figure 2.** Maxillary sagittal protraction with Delaire type facial mask.



**Figure 3.** Secondary alveolar bone grafting harvested from iliac crest of the patient.



**Figure 4.** Clinical appearance of the patient one year after both orthopaedic and orthodontic treatment (Figures 1–4 reprinted [6]).

### 3. Conventional LeFort I osteotomy

In the treatment of severe hypoplastic cleft palate with conventional LeFort I osteotomy, the major advancement and the extreme discrepancies made stabilization difficult, and the added effect of palatal scarring can result in significant surgical relapse [7].

### 4. Distraction osteogenesis

“Distraction osteogenesis” (DO) is a biological process involving the formation of new bone between viable bone segments that are gradually separated by incremental traction. Soft tissue envelope (mucosa, muscle, tendon, skin, cartilage, blood vessels and peripheral nerves) beside bone has been also observed to form under tension stress [8, 9]. Experimental studies also have demonstrated formation of the mature lamellar bone by distraction osteogenesis [7, 10, 11].

#### 4.1. History of distraction osteogenesis

Manipulation of the bone segments was first described by Codivilla in 1905 [12]. Gavriel Awramowitch Ilizarov performed several studies to advance the technique in orthopaedic therapy in 1950s [13–16]. Ilizarov performed this technique in two steps and observed the bone regeneration between the two time periods.

Application of mandibular lengthening in maxillofacial complex with the usage of external fixation device was first performed in a canine animal model by Synder et al. [17] in 1972. In 1977, Michielli and Miotti [18] used internal devices in lengthening of mandible in a canine animal model by gradual distraction.

McCarthy and colleagues [19] first used distraction osteogenesis in human mandible in 1992. Mandibular lengthening in four young patients and bilateral mandibular expansion in one patient were performed by gradual distraction. Since the first mention of distraction osteogenesis in the human mandible, it was recognized that the development of simple, multidirectional, miniaturized and buried devices would be necessary to broaden the application of distraction osteogenesis throughout the craniofacial skeleton [20].

#### 4.2. Distraction histogenesis and phases

The gradual increase in soft tissue volume in response to the tension forces applied with bony distraction is called “distraction histogenesis”. Conventional LeFort I osteotomy provides immediate bone advancement but, however, does not allow for compensatory growth of the soft tissues. The high rate of relapse after conventional maxillary advancement seems to be a result of scarring and memory of the soft tissues, though the soft tissue often contracts to its pre-operative state. On the other hand, DO creates a gradual increase in the amount of soft tissue by preventing its contraction [21].

In the distraction process, different biologic phenomena are produced and these can be summarized in three phases: **latency phase** is the period between the performance of

osteotomy and the start of the traction, during which bone healing begins and soft callus (initial bone formation) is formed. The period is typically between 3–5 days, although in neonates and infants the latency period may be omitted or last only 24 hours. Waiting too long before distraction (beyond 10 to 14 days) increases the risk of premature bone union; **distraction phase** is the period in which the process of distraction is activated to transport the bone fragment and the formation of new immature woven and parallel-fibered bone commences. The total time of the distraction phase is customized to the severity of the deformity. This phase usually lasts 1–2 weeks, and the traction modifies the normal development of the regeneration process. In contrast to the latency period, the rate and the rhythm (frequency) of distraction are important factors [22]. If lengthening of the osteotomy site occurs too slowly (<0.5 mm per day), premature bony union prevents lengthening to the desired dimension, whereas if the rate is too rapid (>2 mm per day), a fibrous nonunion will result. Therefore, most reports recommend a distraction rate of 1 mm per day. The ideal rhythm of DO is a continuous steady-state separation of the bone fragments [13–16]. However, this is not practical, and therefore, the recommended distraction frequency is 1 or 2 times daily [23–25]; and **consolidation phase** is the period that allows the maturation and corticalization of the regenerated bone and the surrounding soft tissues adapt to their new positions and lengths. In craniofacial bones, a 3–5 week phase is recommended for children and a 6–12 week phase for adults. In craniofacial skeleton the general rule is that the consolidation period should be at least twice the duration of the distraction phase [22, 26, 27]. The appearance of bone with identical characteristics to those of the initial bone may take more than a year [9].

#### 4.3. Distraction osteogenesis in sagittal maxillary advancement

Maxillary surgical advancement is the most common surgical technique for correcting maxillary hypoplasia in patients with cleft lip and palate. An advancement of more than 10 mm in patients with no cleft and 6 mm in patients with cleft lip and palate is beyond the limit of conventional LeFort I advancement, and in such cases DO for advancement of the maxilla can be used [28–32].

The application of the force according to the center of resistance of the maxilla plays an important role in sagittal maxillary advancement. The mostly desired directions of the maxillary movements in DO are forward and downward. The center of the mass of the maxilla is considered to be located at the apex of the maxillary premolars. When the force is applied at the center of resistance of the maxilla, a straight anterior movement of the maxilla without any rotation is expected. If the same force is applied above, a clockwise rotation will be expected with a predictable increase in over bite and overjet negligible mandibular rotation. If the force is applied below, a counterclockwise rotation will be expected with a tendency of an anterior open bite [33].

External and internal distraction systems can be used for maxillary distraction osteogenesis [34].

#### 4.3.1. Rigid external distraction osteogenesis

The rigid external distraction (RED) was developed by Polley and Figueroa [26, 35], and is composed by an external bow, which is fixed to the cranium screws, and by a custom-made intraoral splint cemented to the maxillary first molars. External traction hooks with eyelets are soldered to the splint, allowing the connection with the external device via surgical wires [36].

##### *Advantages and disadvantages*

RED devices have the ability to change the distractor vector during the distraction phase. Another advantage of this system is the ease of the installation and removal of the distractors. However, the main disadvantage is that the device is physically and socially inconvenient and uncomfortable for the patients [26, 35, 37, 38].

##### *Technique and protocol*

High-level complete LeFort I osteotomy is the most commonly performed osteotomy since tooth buds are located on a standard level of LeFort I osteotomy line in young patients [1, 36, 39–43]. Standard LeFort I and the 3-piece LeFort I osteotomies are also used with this protocol [7, 26, 35, 44, 45].

After a latency period of 4–7 days, initial activation of the RED device starts. The rate of distraction is 1 mm per day in two or three rhythms. The planned maxillary advancement is usually obtained in 2 to 3 weeks of active distraction. The duration of the activation varies according to the severity of the maxillary hypoplasia; therefore, many authors mention different protocols on this issue. Some activate the distractor until the proper overjet, overbite and stable posterior occlusion are achieved [39], some continued the activation until 5–8 mm of positive overjet is achieved [45], and some activate the distractor until the desired facial profile convexity, skeletal and dental relationships are achieved clinically [1, 7]. Long consolidation period of 8 to 12 weeks is generally accepted in UCLP patients to prevent the risk of possible skeletal relapse [1, 7, 43]. Radiographic bone healing and the presence of cortical outline should be checked using radiographs before removal of the distractors [43]. However, different consolidation period and retention period protocols exist. Nonunion of the external maxillary distraction after a consolidation period of 4–6 weeks was reported by He et al. [41] in 2010. The very first patients of them treated with external distraction had relapse after the early removal of the distractors, so they lengthened the consolidation time up to 12 weeks and had successful results without nonunion. After a consolidation period of 6–8 weeks, distractors and intraoral splints are removed and the maxillary retention by Class III intraoral elastics can be used [45]. Some radical rigid retention periods (consolidation period) such as 2–3 weeks were also mentioned in some studies [26, 39]. In these studies, after the removal of the RED devices, 4–8 weeks of face mask elastic traction at night time were utilized.

### *Skeletal changes (horizontal and vertical)*

The sagittal maxillary advancement is measured as the forward movement of particular landmarks. Anterior maxillary movement (horizontal change in point A) varies between 8.03 to 13.4 mm [1, 26, 38–45].

For patients undergoing RED devices, the average increase in SNA angle is between 7.6 to 12.4 degrees [26, 38, 40, 42–45].

Clockwise rotation of the maxilla is one of the goals in most of the patients with unilateral cleft lip and palate due to the vertical maxillary growth deficiency. The vertical changes in point A are between -1.3 and -7 mm pointing an inferior movement [26, 43, 44]. Although there can be a positive downward displacement of the maxilla, an undesired counterclockwise rotation of the maxilla can be a result of inconvenient distraction force vector [1, 42]. Desired change in the palatal plane angle varies according to the application point of the distraction force. In patients without secondary alveolar bone graft, distraction force may also lead to a counterclockwise rotation. This reversible undesired rotation of the maxilla can be corrected with the aid of intraoral elastics [1].

### *Dental changes*

Dentoalveolar sagittal movement can be measured by the dental overjet and the displacement of the upper incisor tip. The increase of the overjet ranged from 12.7 to 15.8 mm, whereas the angular change of the upper incisor according to the palatal plane ranged from -1.2 to 3.6 degrees [7, 26, 42, 44].

### *Soft tissue changes*

The main changes accompanying RED procedure are located in the upper lip and nasal region, with improved facial aesthetics. In these patients, the profile of the face changes from concave to convex. The increase in facial convexity angle is between 15.59 and 26.2 degrees [7, 26, 39, 43, 44].

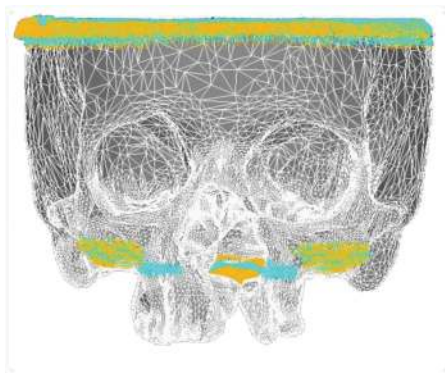
#### *4.3.2. Internal distraction osteogenesis*

Internal miniature distractor was first reported by Cohen et al. [20] in 1997 on maxillary distraction in patients with CLP using an internal miniature distractor. This device produced no complications and permitted maxillary and midfacial advancement in patients with CLP and craniofacial syndromes.

Most surgeons accept that advancement of more than 6 mm in patients with CLP and more than 10 mm in non-cleft patients is beyond the present limit of one-stage maxillary advancement surgery using LeFort I osteotomy, and can only be achieved by distraction osteogenesis [29, 30].

There are many clinical research studies and case reports about sagittal maxillary advancement with DO. The biomechanical effects associated with this procedure still remain speculative. In

2011, we investigated the effects of DO in a patient with CLP using finite element analysis (FEM) and improved this preliminary study with another comparative study in 2014 [4, 46] (Figures 5–8). Three-dimensional (3D) finite element model (FEM) analysis is a helpful mathematical instrument for use in orthodontics and can determine the amount of stress, strain and displacement in the maxillofacial complex after different loading conditions of force.



**Figure 5.** Three-dimensional finite element model of our patient with unilateral cleft lip and palate. Yellow colours represent the boundary conditions at the foramen magnum, upper side of the cranial vault and the zygomatic buttress, where the superior plates of the internal distractor are assumed to be placed.

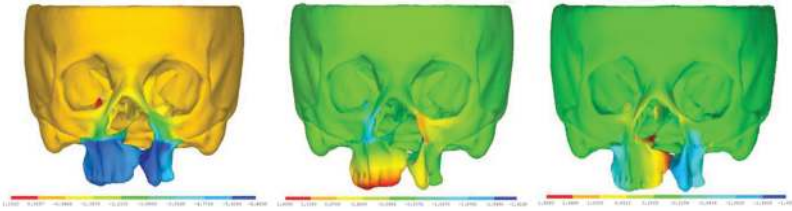
The results of our study are similar to the clinical outcomes in some ways, and therefore may help surgeons and orthodontists to understand better the therapeutic effect of internal maxillary DO on the basal bones and sutures of the craniofacial system. The displacement distribution in the sagittal plane was asymmetric in the UCLP model rather than the non-cleft model. The non-cleft side of the UCLP FEM showed more anterior displacement than did the cleft side, which can result from the asymmetrical skeletal development of the anatomical structures.

The amount of transversal change at the lateral nasal walls was found to have expanded in both FEMs.


The maxillary rotation showed differences in both models. On the UCLP model, the maxilla rotated in a clockwise direction after maxillary advancement of 6 mm. On the cleft side, more inferior displacements were observed. In the control model, a counterclockwise rotation of the maxilla occurred. This can be the result of different placement of the anterior advancement vector in this finite element model.

Moreover, our results showed that the sagittal distraction forces produced not only advancement forces at the intermaxillary sutures but also higher stress values at the sutura nasomaxillaris, sutura frontonasalis and sutura zygomaticomaxillaris on the cleft side compared to the non-cleft side. In the non-cleft model, relatively high stress values were found at the sutura frontomaxillaris and sutura nasomaxillaris, similar to the findings on the non-cleft side of the UCLP FEM.

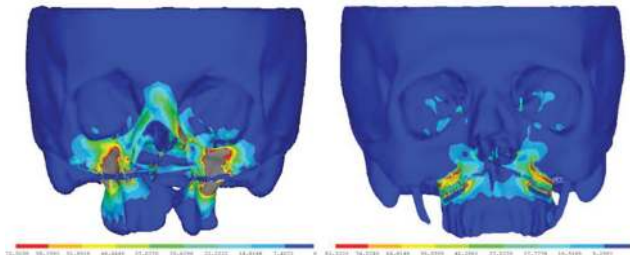




**Figure 6.** Displacement distribution in (a) sagittal, (b) transversal and (c) vertical planes after 6 mm of maxillary advancement for the UCLP model, respectively.



**Figure 7.** Displacement distribution in (a) sagittal, (b) transversal and (c) vertical planes after 6 mm of maxillary advancement for the non-cleft control model, respectively.



**Figure 8.** The magnitude and distribution of the von Mises stresses after 1 mm of maxillary advancement for the UCLP model and for the non-cleft control model, respectively.

### *Advantages and disadvantages*

Internal distractors are socially and psychologically more tolerated than the external distractors [36, 47–49]. However, there are some disadvantages: (1) the difficulty of the position process, (2) the need for a second operation to remove the distractors, (3) the inability to change the distraction vector during the distraction phase (control of the maxillary segment can be achieved by intraoral elastics by which an adjustment in “molding the regenerate” bone corrects for an error in distraction direction or vector), (4) the difficulty in placement of the two parts of the distractors parallel to each other, (5) the limitation of the distraction length,

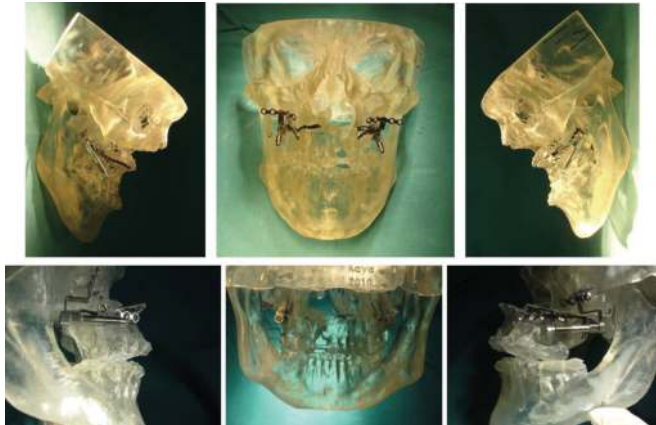(6) the discomfort due to the stretch of the buccal tissues by the distractor's rods, (7) the need for pre-operative planning and/or stereolithographic modelling [34, 50–55].

### *Stereolithographic modelling*

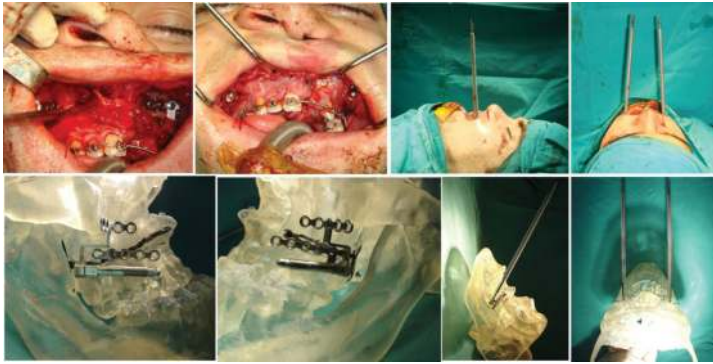The desired vectors of the maxillary advancement are necessary and can be controlled via stereolithographic models. In patients with CLP, visualization of the bone thickness and decision of the bony cuts and distractor placements should be made on these models pre-operatively. However, in some countries there is an extra cost for stereolithographic modelling; therefore, pre-operative planning can also be simulated using specific computer software, which allows for three-dimensional craniofacial reconstruction from computed tomography scan images [51–54, 56] (**Figures 9–11**). Three-dimensional finite element model analysis is also a helpful mathematical instrument for use both in orthodontics and in orthopaedics, and can determine the amount of stress, strain and displacement in the maxillofacial complex [4, 57]. However, this technique cannot be used for all patients individually due to the long elapsed time for the analysis.



**Figure 9.** Stereolithographic model of our patient with UCLP.



**Figure 10.** Demonstration of the surgery on the stereolithographic model, bending of the distractor plates during this section, and finally insertion of the bended distractor plates on the model.



**Figure 11.** LeFort I osteotomy, and the checking for the parallelism of the inserted distractor plates using extension rods.

### *Technique and protocol*

The need for the correction and severity of the maxillary deficiency is the key to choose the type of osteotomy. The maxillary osteotomies can be divided into three subgroups: (1) horizontal osteotomy, for anterior advancement of the maxilla, (2) oblique osteotomy, for forward and downward movement of the maxilla, (3) step osteotomy, for children in whom canine and premolar teeth buds are in a high position [51, 58]. The standard LeFort I osteotomy and down fracturing of the maxilla are the most commonly performed osteotomies since this technique is used in older patients than those treated with RED [51, 54, 59–61]. High LeFort I and the 2–3 piece LeFort I osteotomies (this can be performed after completion of distraction, at the time of device removal) are also used with this protocol [34, 54].

After the insertion of the internal bone-borne maxillary distractors, the screws were activated for a few millimeters or more to check the correctness of the maxillary movement and to overcome premature bony contacts during the activation process [4, 34, 60–62]. Mandibular osteotomies, if needed according to the skeletal diagnosis, can be performed in the same operation [59, 60, 62].

After the operation a latency period of 3–7 days, initial activation of the internal distraction device starts. The rate of distraction is 0.5 to 1 mm per day in one or two rhythms. Activation of the distractors can be performed by the patients themselves or by the patients' parents or relatives. The planned maxillary advancement is usually obtained in several days of active distraction. The duration of the activation phase depends on the severity of the maxillary deficiency. Activation of the distractors performed until the proper overjet, overbite and relative stable posterior and anterior occlusion (overcorrected Class I molar and incisal relationship) are achieved [4, 5, 36, 51, 54, 60–62].

In early post-operative period, many clinicians use orthodontic elastic traction to control the occlusion, to prevent posterior or anterior openbite and to guide the maxilla into position [34, 59–61].

Consolidation period of 8 to 12 weeks is generally accepted in UCLP patients to prevent the risk of possible skeletal relapse [32, 51, 54, 62]. During consolidation period, bone mineralization of the distraction zone and bone remodelling occur according to the Ilizarov's principles.

*Skeletal changes (horizontal and vertical)*

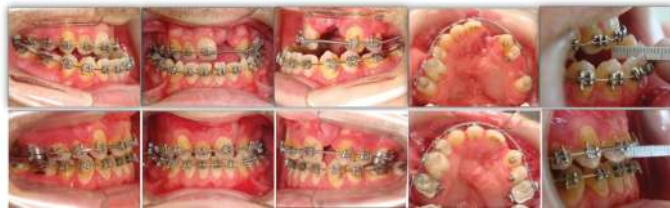The horizontal maxillary advancement usually measured as the advancement of point A ranged from 5.7 to 34 mm [34, 54, 59, 61, 62]. The average increase in SNA angle is between 5.65 and 10.8 degrees [40, 54].

The vertical changes in point A are between -1.1 mm (meaning counterclockwise rotation of the maxilla) to 7 mm (meaning clockwise rotation of the maxilla) [34, 54, 61, 62].

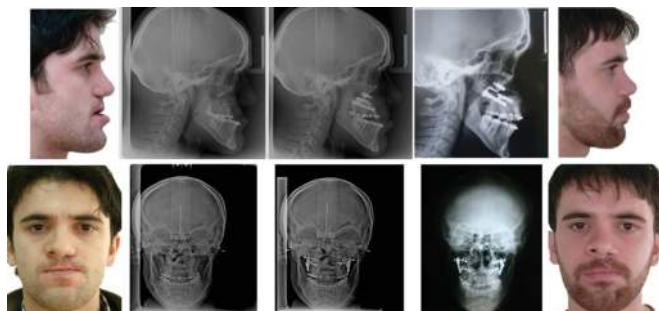
The counterclockwise rotation of the maxilla can be a result of inconvenient distraction force vector and can be changed by the use of the orthodontic elastic traction that can be applied between upper and lower teeth [1, 4, 34, 42].

*Dental changes*

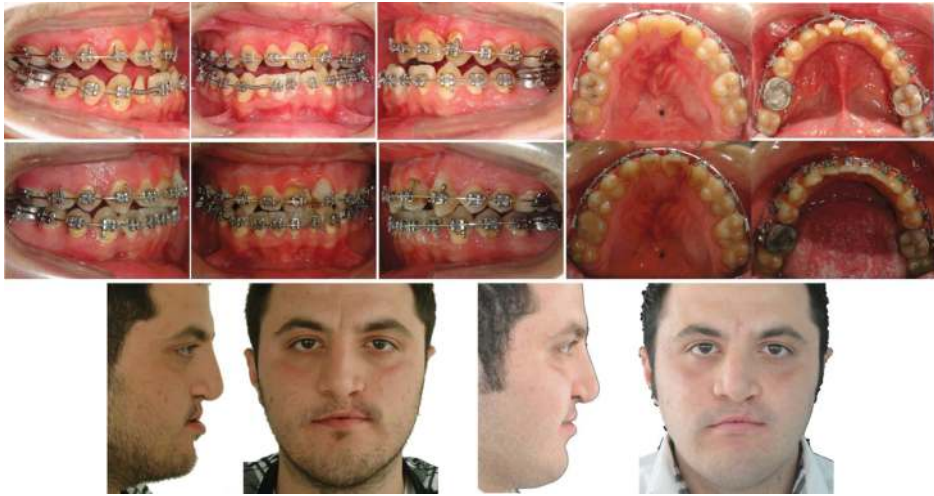The increase of the overjet ranged from 6.59 to 13.66 mm [51, 61].



**Figure 12.** Intra-oral photographs of a 21-year-old boy affected by severe maxillary hypoplasia due to unilateral cleft lip and palate treated in our clinic before internal distraction and after consolidation period (after using orthodontic elastic traction and removal).



**Figure 13.** Pre-operative and post-operative extra-oral photographs and cephalometric films of the same patient.



**Figure 14.** Intra-oral and extra-oral photographs of a 20-year-old boy affected by severe maxillary hypoplasia due to unilateral cleft lip and palate treated in our clinic before and after internal distraction osteogenesis.

## 5. Conclusion

The use of distraction osteogenesis was proved as a predictable method for major bone elongation with the generation of new bone in the distraction site. Newly formed bone can provide good support and thus contribute to stability. Many surgeons and orthodontists prefer sagittal maxillary distraction osteogenesis in maxillary deficiency, especially in patients with cleft lip and palate or in syndromic patients. Virtual surgical planning and/or stereolithographic modelling allow more predictable operation and distraction.

Sagittal distraction forces produce not only advancement forces at the intermaxillary sutures but also higher stress values at the sutura nasomaxillaris, sutura frontonasalis and sutura zygomaticomaxillaris on the cleft side of the patients with unilateral cleft lip and palate rather than the non-cleft side. Some patients feel pressure under the eyes, around the lateral nasal walls and generally throughout the face during and after the distractor activations. One should consider the consequences of the activation of the distractors under the light of these findings. Since the clinical effectiveness of the maxillary distraction osteogenesis, especially in patients with cleft lip and palate, is highly dependent on the presence of the scar tissue, it would be helpful to incorporate this soft tissue into future mathematical models.

For patients with mild to severe maxillofacial deficiencies, conventional one-step LeFort I maxillary advancement is out of limits, and advancement using distraction osteogenesis has been shown to be a stable, reliable treatment modality in such cases.

## Author details

Sultan Olmez-Gurlen

Address all correspondence to: sultanolmez@gmail.com

Private Practitioner, Izmir, Turkey

## References

- [1] Aksu M, Saglam-Aydinatay B, Akcan CA, El H, Taner T, Kocadereli I, Tuncbilek G, Mavili ME Skeletal and dental stability after maxillary distraction with a rigid external device in adult cleft lip and palate patients. *J Oral Maxillofac Surg.* 2010;68:254-259.
- [2] Ross RB Treatment variables affecting facial growth in complete unilateral cleft lip and palate. *Cleft Palate J.* 1987;24:5-77.
- [3] Cheung LK, Chua HDP A meta-analysis of cleft maxillary osteotomy and distraction. *Int J Oral Maxillofac Surg.* 2006;35:14-24.
- [4] Olmez S, Dogan S, Pekedis M, Yildiz H Biomechanical evaluation of sagittal maxillary internal distraction osteogenesis in unilateral cleft lip and palate patient and noncleft patients-a three dimensional finite element analysis. *Angle Orthod.* 2014;84:815-824.
- [5] Austin SL, Mattick CR, Waterhouse PJ Distraction osteogenesis versus orthognathic surgery for the treatment of maxillary hypoplasia in cleft lip and palate patients: a systematic review. *Orthod Craniofac Res.* 2015;18:96-108.
- [6] Dogan S, Olmez S, Bilkay U, Aydinli E Treatment modalities of a unilateral cleft lip and palate patient from birth to adulthood-case report. *Ortho Techniques.* 2011;3(4):digital issue.
- [7] Rachmiel A, Even-Almos M, Aizenbud D Treatment of maxillary cleft palate: distraction osteogenesis vs orthognathic surgery. *Ann Maxillofac Surg.* 2012;2(2):127-130.
- [8] Constantino PD, Friedman CD Distraction osteogenesis: application for mandibular regrowth. *Otolaryngol Clin North Am.* 1991;24:1433-1442.
- [9] Cohen SR, Rutrick RE, Burstein FD Distraction osteogenesis of the human craniofacial skeleton: initial experience with new distraction system. *J Craniofac Surg.* 1995;6:368-374.
- [10] Rachmiel A, Laufer D, Jackson IT, Lewinson D Midface membranous bone lengthening: a one year histological follow-up of distraction osteogenesis. *Calcif Tissue Int.* 1998;62:370-376.

- [11] Rachmiel A, Rozen N, Peled M, Lewinson D Characterization of midface maxillary membranous bone formation during distraction osteogenesis. *Plast Reconstr Surg.* 2002;109:1611-1620.
- [12] Codivilla A On the means of lengthening in the lower limbs, the muscles and tissues which are shortened through deformity. *Clin Orthop Relat Res.* 1994;301:4-9.
- [13] Ilizarov GA Basic principles of transosseous compression and distraction osteosynthesis. *Orthop Travmatol Protez.* 1971;32:7-15.
- [14] Ilizarov GA The principles of the Ilizarov method. *Bull Hosp Jt Dis Orthop Inst.* 1988;48:1-12.
- [15] Ilizarov GA The tension-stress effect on the genesis and growth of tissues. Part I. The influence of stability of fixation and soft tissue preservation. *Clin Orthop Relat Res.* 1989a;238:249-281.
- [16] Ilizarov GA The tension-stress effect on the genesis and growth of tissues. Part II. The influence of the rate and frequency of distraction. *Clin Orthop Relat Res.* 1989b; 239:263-285.
- [17] SynderCC, Levine GA, Swanson HM, Browne EZ Jr Mandibular lengthening by gradual distraction. Preliminary report. *Plas Reconstr Surg.* 1973;51(5):506-508.
- [18] Michielli S, Miotti B Lengthening of mandibular body by gradual surgical-orthodontic distraction. *J Oral Surg.* 1977;35(3):187-192.
- [19] McCarthy JG, Schreiber J, Karp N, Thorne CH, Grayson BH Lengthening of the human mandible by gradual distraction. *Plas Reconstr Surg.* 1992;89(1):1-8.
- [20] Cohen SR, Burstein FD, Stewart MB, Rathburn MA Maxillary-midface distraction in children with cleft lip and palate: a preliminary report. *Plas Reconstr Surg.* 1997;99(5): 1421-1428.
- [21] Shah AR Distraction osteogenesis of the maxilla [Internet]. [Updated: December 15, 2014]. Available from: <http://emedicine.medscape.com/article/844742-overview>.
- [22] Aronson J Experimental and clinical experience with distraction osteogenesis. *Cleft Palate Craniofac.* 1994;31:473-482.
- [23] Guererero CA, Bell WH, Contasti GI Mandibular widening by intraoral distraction osteogenesis. *Br J Oral Maxillofac Surg.* 1997;35:383-392.
- [24] Mommaerts MY Transpalatal distraction as a method of maxillary expansion. *Br J Oral Maxillofac Surg.* 1999;37(4):268-272.
- [25] Bell WH, Gonzalez M, Samchukov ML Intraoral widening and lengthening of mandible in baboons by distraction osteogenesis. *J Oral Maxillofac Surg.* 1999;57(5):548-562.
- [26] Polley JW, Figueroa AA Rigid external distraction: its application in cleft maxillary deformities. *Plast Reconstr Surg.* 1998;102:1360-1372.

- [27] Shetye PR, Davidson EH, Sorkin M Evaluation of three surgical techniques for advancement of the midface in growing children with syndromic craniosyntosis. *Plast Reconstr Surg.* 2010;126(3):982-994.
- [28] Saelen R, Tornes K, Halse A Stability after Le Fort I osteotomy in cleft lip and palate patients. *Int J Adult Orthod Orthognath Surg.* 1998;13:317-323.
- [29] Molina F, Monasterio F, Aguliar M Maxillary distraction: aesthetic and functional benefits in cleft lip and palate and prognathic patients during mixed dentition. *Plast Reconstr Surg.* 1998;101:951-963.
- [30] Costa F, Robiony M, Politi M Stability of Le Fort I osteotomy in maxillary advancement: review of the literature. *Int J Adult Orthod Orthognath Surg.* 1999;14:207-213.
- [31] Yu H, Wang X, Fang B, Shen SG Comparative study of different osteotomy modalities in maxillary distraction osteogenesis for cleft lip and palate. *J Oral Maxillofac Surg.* 2012;70:2641-2647.
- [32] Adolphs N, Ernst N, Menneking H, Hoffmeister B Significance of distraction osteogenesis of the craniomaxillofacial skeleton: A clinical review after 10 years of experience with the technique. *J Craniomaxillofac Surg.* 2014;42:966-975.
- [33] Ahn JG, Figueroa AA, Braun S, et al. Biomechanical considerations in distraction of the osteotomized dentomaxillary complex. *Am J Orthod Dentofacial Orthop.* 1999;116:264-270.
- [34] Tomita D, Omura S, Ozaki S, et al. Maxillary movement in distraction osteogenesis using internal devices in cleft palate patients. *Cleft Palate Craniofac J.* 2011;48(2): 161-166.
- [35] Polley JW, Figueroa AA Management of severe maxillary deficiency in childhood and adolescence through distraction osteogenesis with an external, adjustable, rigid distraction device. *J Craniofac Surg.* 1997;8:181-185.
- [36] Scolozzi P Distraction osteogenesis in the management of severe maxillary hypoplasia in cleft lip and palate patients. *J Craniofac Surg.* 2008;19(5):1199-1214.
- [37] Figueroa AA, Polley JW, Ko EW Maxillary distraction for the management of cleft maxillary hypoplasia with a rigid external distraction system. *Semin Orthod.* 1999;5:46-51.
- [38] Figueroa AA, Polley JW, Friede H, et al. Long-term skeletal stability after maxillary advancement with distraction osteogenesis using a rigid external distraction device in cleft maxillary deformities. *Plast Reconstr Surg.* 2004;114:1382-1392.
- [39] Ko EWC, Figueroa AA, Polley JW Soft tissue profile changes after maxillary advancement with distraction osteogenesis by use of a rigid external distraction device: a 1 year follow-up. *J Oral Maxillofac Surg.* 2000;58:959-969.



- [40] Rachmiel A, Aizenbud D, Peled M Distraction osteogenesis in maxillary deficiency using a rigid external distraction device. *Plast Reconstr Surg.* 2006;117:2399-2406.
- [41] He D, Genecov DG, Barcelo R Nonunion of the external maxillary distraction in cleft lip and palate: analysis of possible reasons. *J Oral Maxillofac Surg.* 2010;68:2402-2411.
- [42] Gürsoy S, Hukki J, Hurmerinta K Five-year follow-up of maxillary distraction osteogenesis on the dentofacial structures of children with cleft lip and palate. *J Oral Maxillofac Surg.* 2010;68:744-750.
- [43] Dua G, Kumar AN, Roy ID, Roy SK Maxillary distraction osteogenesis in cleft lip and palate cases with midfacial hypoplasia using rigid external distractor: an alternative technique. *J Craniofac Surg.* 2014;25(3):746-751.
- [44] Daimaruya T, Imai Y, Kochi S, Tachi M, Takano-Yamamoto T Midfacial changes through distraction osteogenesis using a rigid external distraction system with retention plates in cleft lip and palate patients. *J Oral Maxillofac Surg.* 2010;68:1480-1486.
- [45] Rattan V, Jena AK, Singh SP, Utreja AK Maxillary distraction osteogenesis at Lefort I level induces bone apposition at infraorbital rim. *Clin Oral Invest.* 2014;18:1741-1748.
- [46] Olmez S, Dogan S, Pekedis M, Yildiz H The evaluation of maxillary advancement technique using internal distraction osteogenesis in unilateral cleft lip and palate patient with finite element analysis. *Journal of Biomechanics.* 2011;44:e13-e14. DOI: 10.1016/j.jbiomech.2011.02.053.
- [47] Gulsen, Ozmen S, Tuncer S, et al. Maxillary advancement with internal distraction device in cleft palate patients. *J Craniofac Surg.* 2007;18:177-185.
- [48] Aikawa IS, Isomura ET, Namikawa M, Yatsuoka Y, Yamada C, Yamamoto T, Takigawa Y Breakage of internal maxillary distractor: considerable complication of maxillary distraction osteogenesis. *Oral Surg Oral Med Oral Pathol Oral Radiol Endod.* 2008;106:e1-e7.
- [49] Bevilacqua RG, Ritoli EL, Kang C, Mabry K, Castiglione CL Midmaxillary internal distraction osteogenesis: ideal surgery for the mature cleft patients. *Plast Reconstr Surg.* 2008;121:1768-1778.
- [50] Nakagawa K, Ueki K, Takatsuka S, Marukawa K, Yamamoto E A device for determining the position of intraoral distractors for protracting the maxilla. *J Craniofac Surg.* 2003;31:234-237.
- [51] Rachmiel A, Aizenbud D, Peled M Long term results in maxillary deficiency using intraoral devices. *Int J Oral Maxillofac Surg.* 2005;34:473-479.
- [52] Wang XX, Wang X, Yi B Internal midface distraction in correction of severe maxillary hypoplasia secondary to cleft lip and palate. *Plast Reconstr Surg.* 2005;116:51-60.

- [53] Gateno J, Engel ER, Teichgraeber JF, et al. A new Le Fort I internal distraction device in the treatment of severe maxillary hypoplasia. *J Oral Maxillofac Surg.* 2005;63:148-154.
- [54] Kumar A, Gabbay JS, Nikjoo R, et al. Improved outcomes in cleft patients with severe maxillary deficiency after Le Fort I internal distraction. *Plast Reconstr Surg.* 2006;117:1499-1509.
- [55] Van Sickels JE, Madsen MJ, Cunningham LL Jr, Bird D The use of internal maxillary distraction for maxillary hypoplasia: a preliminary report. *J Oral Maxillofac Surg.* 2006;64:1715-1720.
- [56] Olmez S Evaluation of maxillary distraction osteogenesis in patients with cleft lip and palate using finite element method [thesis]. Izmir-Turkey:2012.
- [57] Ozan F, Yildiz H, Bora OA, et al. The effect of head trauma on fracture healing: biomechanical testing and finite element analysis. *Acta Orthop Traumatol.* 2010;44:313-321.
- [58] Rachmiel S, Aizenbud D, Ardekian L, Peled M, Laufer D Surgically-assisted orthopedic protraction of the maxilla in cleft lip and palate patients. *Int J Oral Maxillofac Surg.* 1999;28:9-14.
- [59] Cheung LK, Chua HDP, Hagg MB Cleft maxillary distraction versus orthognathic surgery: clinical morbidities and surgical relapse. *Plast Reconstr Surg.* 2006;118:996-1008.
- [60] Chua HDP, Whitehill TL, Samman N, Cheung LK Maxillary distraction versus orthognathic surgery in cleft lip and palate patients: effects on speech and velopharyngeal function. *Int Journal Oral Maxillofac Surg.* 2010a;39:633-640.
- [61] Chua HDP, Cheung LK Soft tissue changes from maxillary distraction osteogenesis versus orthognathic surgery in patients with cleft lip and palate: a randomized controlled clinical trial. *J Oral Maxillofac Surg.* 2012;70:1648-1658.
- [62] Chua HDP, Hagg MB, Cheung LK Cleft maxillary distraction versus orthognathic surgery- which one is more stable in 5 years? *Oral Surg Oral Med Oral Pathol Oral Radiol Endod.* 2010b;109:803-814.