

---

# Dental and Craniofacial Effects on Childhood Cancer Survivors

---

Orsolya Németh

Additional information is available at the end of the chapter

<http://dx.doi.org/10.5772/67040>

---

## Abstract

The availability and adoption of modern therapeutic protocols for childhood cancer have continuously reduced the mortality rate of childhood malignancies in most countries over the past decades. Children being treated for cancer are actively growing, creating unique problems not only in the short-term but also in the long-term development of both the orofacial hard and soft tissue. Complications during and after cancer therapy depend on the type of malignancy, age at diagnosis, and the drugs used during the therapy. The adverse oral effects of irradiation have long been known, and high-dose chemotherapy can cause similar oral late effects, such as dental disturbances, delayed tooth eruption, oral mucosa changes, and craniofacial effects. There are many protocols to prevent acute oral toxicity and infections like mucositis, candidiasis, or hyposalivation. The aim of this chapter is to define the short-term and long-term effects of cancer therapy on the oral health.

**Keywords:** oral health, dental disturbances, craniofacial effects, saliva flow rate

---

## 1. Introduction

### 1.1. Craniofacial development

An understanding of dental and craniofacial effects of cancer therapy is an essential knowledge of distinct mechanism of postnatal craniofacial development, growth, and capacities for adaptation during growth.

The craniofacial complex can be organized according to four anatomic regions: desmocranium, chondrocranium, splanchnocranium, and the most specialized anatomic component, dentition.

---

There are three principal growth-related cranial base synchondroses that separate the bones of cranial base at birth. Fuses of intersphenoid synchondrosis finished around the time of birth and it does not contribute to postnatal growth. The sphenothmoidal synchondrosis is most active with respect to growth of the cranial base through approximately 7 years of age (synchondrosis loses its cartilage phenotype). Growth of the anterior cranial base is essentially complete. As a result, the anterior wall of sella turcica, the greater wing of the sphenoid, and the cribriform plate are commonly used after age 7 as stable reference structures for analyses of lateral cephalograms. The third synchondrosis (sphenoccipital) is most prominent throughout the period of active craniofacial growth and fuses only after puberty at 16–19 years.

The cranial base undergoes a dramatic shift in its growth pattern during the early postnatal years. Cranial base dimensions (anterior and posterior lengths) and cranial base angulations show greater growth changes at the age of 2 and 3 years. The changes after 2–3 years of age are smaller and steady. So the irradiation in this time causes the greatest cranial disturbances.

The midface at the time of birth is well developed, but slightly relative to the neurocranium. Significant anterior and vertical growth of the midface through the first several years after birth can be observed due to interstitial cartilaginous growth of midline nasal septum. Nasomaxillary complex of postnatal development occurs via intramembranous ossification except nasal septum. Growth at the sutures of midface leads to inferior and anterior, and lateral midfacial displacements means vertical, transverse, and anteroposterior changes. Growth continues until premaxillary/maxillary suture closes at 3–5 years of life [1]. The major intermaxillary growth sites are midpalatal and transpalatal sutures, associated with transverse and anteroposterior midface growth. Growth of midpalatal and transpalatal sutures continues until 20–25 years of age [2, 3]. The midface undergoes a complex remodeling pattern throughout childhood and adolescence. The length of entire maxilla and dental arches, and height of the midface are increased by continued development of the dentition and alveolar bone. Growth of cranial base displaces the maxilla in a downward and forward direction [4]. The age of 7 years is something of a benchmark for growth of the midface [4]. Relatively, anterior cranial base is stable but the growth of cartilages of the nasal capsule and nasal septum changes significantly. The cartilaginous nasal capsule becomes ossified and the nasal septum, which remains cartilaginous throughout life, decreases significantly in growth activity. Structures within the midfacial complex also affect its displacement and rotation. Growth of the eyeball is associated with both the anterior and lateral displacements of the midface; enucleation of the eyeball during growth results in deficiencies in the anterior and lateral growth of the midface [5]. Sexual dimorphism increases substantially throughout the midfacial complex. Adult males are larger and wider midfaces than females. The reason is males have the two extra years of childhood's growth; males enter the adolescence phase of growth at 12 years of age, while females enter at 10 years.

During postnatal development, mandible increases in size as a result of the combined processes of proliferation and ossification of secondary cartilage at the condyle, as well as differential formation and remodeling of bone along the entire surface of the mandible. Because the posterior mandible generally undergoes greater inferior displacement than the anterior mandible, the mandible rotates forward. Growth of the mandible is expressed in a downward and

forward growth direction relative to the rest of the cranium. In this overall pattern, the growth of the mandible follows the growth of the midface. As the midface is translated downward and forward, the mandible keeps pace in the normally growing face [4, 6]. Midfacial growth and the associated changes in the position of the maxillary dentition are also thought to play an important role in mandibular growth displacements [7–9].

## 1.2. Dental development

The primary (milk teeth) and secondary dentitions all form in essentially the same manner, although at different times. The entire primary dentition is initiated between 6th and 8th week in utero, the successional permanent teeth between the 20th week of embryonic development and 21 years of age for third molar [10]. Teeth development (initiation) is regulated by epithelial-mesenchymal interactions between oral epithelium and neural crest-derived mesenchyme [11]. During the proliferation stage, tooth formation proceeds through increased mitotic activity, leading to the development of ameloblasts and odontoblasts, which produce enamel prism and dentin. The internal enamel rods will differentiate into ameloblasts and then begin the production of enamel rods. During histodifferentiation stage, the cells lose the ability to multiply. Aberrations in initiation and proliferation typically result in failure of tooth development, while insults during histodifferentiation result lead to abnormal structure of enamel and dentin (amelogenesis and dentinogenesis imperfecta, and discolored enamel). Disturbances during morphodifferentiation can cause abnormal shape and size of teeth. The next stage of individual tooth development is appositional growth, while the ameloblast and odontoblast produce a deposition of an extracellular (organic) matrix. The process of mineralization begins with formation of small nidus (ionic calcium and phosphate precipitation), and this nidus increases in size and leads to homogeneously mineralized layer. Environmental insults during due to lack of fusion of the calcospherites, which could leads to less resistant to dental caries.

Root formation begins when the epithelial layers penetrate into underlying mesenchyme and form the Hertwig's epithelial root sheath. This sheath grows around the dental papilla until it encloses the apical foramen. As a result root disturbance, which is a lack of root structure, leads to shortened and tapered root. Root development plays a dominant role in the eruption [6].

## 2. Short-term effects

### *Radiotherapy*

Radiation therapy of children with malignancies requires attention to physical and biological principles to maximize efficacy and reduce late effects. Biologically, effective forms of radiation produce energetic charged particles in tissue, resulting in direct and indirect ionization of intracellular molecules with attendant biological effect [12]. The reaction of normal tissues to irradiation can occur during or immediately after therapy as acute effects, within 3–6 months after treatment as subacute effects, and later 6 months after radiotherapy as late effects [13].

Acute radiation injury is expressed in rapidly proliferating tissues like mucous membrane. Acute changes follow depletion of the actively proliferating stem cells, time of onset, and degree depending on the size of the stem cell compartment and response of the cell renewal system. Acute effects do not correlate with subacute and late parenchymal complications after radiotherapy [14] (**Table 1**).

Immediate radiation reaction often occurs xerostomia, which is symptomatically expressed within several days of treatment encompassing the salivary glands. The radiotherapy damage to the salivary glands is due to an alteration in their vascular supply.

---

#### Chemotherapy

- Oral mucositis and stomatitis
- Xerostomia
- Infections:
  - Bacterial
  - Viral (herpes simplex, varicella zoster, and cytomegalovirus)
  - Fungal (*Candida albicans*)
- Bleeding: anywhere in the mouth, spontaneous or induced
- Neurotoxicity: bilateral mimics toothache

#### Radiation therapy

- Oral mucositis and stomatitis
- Xerostomia
- Radiation caries
- Taste alteration
- Infections:
  - Bacterial
  - Viral (herpes simplex, varicella zoster, cytomegalovirus)
  - Fungal (*Candida albicans*)
- Trismus: inability to open mouth completely osteoradionecrosis

#### Hematopoietic cell transplantation (HCT)

- Oral mucositis (10–14 days posttransplant)
  - Gingival hyperplasia
  - Xerostomia
  - Viral and fungal infections
- 

**Table 1.** Short-term effects of cancer therapy in CCS.

Saliva can become sparse, thick, and ropy after just 4–5 fractions [15]. According to Epstein et al. whole stimulated and resting saliva productions are decreased by 36.67 and 47.9%, respectively, by the end of 1 week of RT [16]. The pH after radiation falls from 7.0 to 5.0, which is cariogenic [17, 18]. As the pH and buffering capacity of saliva are low, the minerals of enamel and dentin dissolve easily [19]. Thus, the process of remineralization of the dental hard tissue does not occur in the oral environment of HNC patients after radiotherapy is prone to demineralization. Consequently, remineralization capacity of saliva is hampered [19]. Accompanied by the reduced oral clearance, these effects result in troublesome changes of the oral flora, with an increase in acidogenic and cariogenic microorganisms (*Streptococcus mutans*, *Lactobacillus*, and *Candida* species) [20].

In Spinger's study, it is said that irradiation is thought to have a direct destructive effect on dental hard tissue, especially at the dentinoenamel junction (DEJ) [21].

### *Chemotherapy*

In therapeutic doses, actively dividing normal host tissues, such as mucosal epithelial and bone marrow cells, are sensitive to the cytotoxic effects of anticancer drugs [22]. Unfortunately, the nonselective mechanism of action and resulting low therapeutic indices of these agents mean that high incidence of potentially severe toxicities must be tolerated to administer effective doses [23]. The dose intensity of anticancer drugs is limited primarily. Many drugs have unique toxicities affecting various organs or tissues such as oral complications associated antimetabolites, alkylating agents, plant alkaloids, and antitumor antibiotics [24]. Therapy affects the oral epithelial cell directly by interfering with actual cell production, maturation, and replacement indirectly to bone marrow depression. Myelosuppression (neutropenia and thrombocytopenia) increases risk of mucosal bleeding and viral, bacterial, and fungal oral infection. The most frequented acute complication of methotrexate in mouth is oral intestinal mucositis. Mucositis occur 5–14 days after dose [25–29]. The development of mucositis is related to the concentration of drug (mg/m<sup>2</sup>/week) and during exposure [30] (**Table 1**).

Chemotherapy not only affects the rapidly dividing oral mucosa but also alters the volume of saliva, microbial flora, and shelter line of the mucosa. The oral mucosa of these children have a greater mitotic index, so, its complications in children occur more frequently than those in adult patients. Clinical features include swelling, bleeding, dry mouth, desquamation of gingiva and palate, and cracked and dry lips.

### *HSCT*

Stem cell transplantation is the most dramatic example of rescue approach. Children with malignancies are treated with lethal doses of myelosuppressive drugs or combination with total body irradiation and then we expect infusion of stem cell, bone marrow to prevent permanent marrow aplasia. The oral complications of HSCT are xerostomia, mucositis, oral infection, and gingival hyperplasia [31] (**Table 1**).

#### **2.1. Infections (oral mucositis)**

The gastrointestinal system's mucosal toxicity is a frequent immediate or short-term side effect of chemotherapy. It appears only when pen torch erythema illuminates the oral cavity,

causing extraordinarily severe pain, and thus becoming impossible for the children to eat or drink. In the case of combined therapy, induced mucositis can develop, which can lead to bleeding and infections [32].

The most frequented causes are therapy of 5-FU, azathioprine, bleomycin, cyclophosphamide, dactinomycin, daunorubicin, doxorubicin, nitrogen mustards, melphalan, 6-mercaptopurine, methotrexate, mitomycins-C, novantrone, mithramycin, procarbazine, streptozotocin, 6-thioguanine, and vinblastine [15, 33].

Mucositis or stomatitis occurs due to the damage and destruction of epithelial cells. In principle cancer therapy can be directly impaired by the cell maturation and replacement and leads to bone marrow depression- myelosuppression and immunosuppression (neutropenia, thrombocytopenia) increase the viral (herpes simplex, varicella zoster, cytomegalovirus), bacterial and fungal (*Candida albicans*) infections or bleeding [25, 27–29].

In the histological aspect, collagen degradation, hyperplasia, glandular degeneration, and dysplasia can be observed. This means that the chemical and microbiological barrier function of mucosal cease and cause reduced humoral factors (antibody and antimicrobial proteins) formation and the agents cause infections.

Management involves maintenance of meticulous oral hygiene, prevention of infection, and maintenance of oral function (swallowing and chewing). Systematic analgetics, ice packs to throat and cheeks 4–6 times daily for 15–20 minutes. Chlorhexidine mouthwashes are not recommended for cytotoxic-induced mucositis [34]. The newest treatment of mucositis can be cryotherapy [35].

## **2.2. Salivary glands—hyposalivation and xerostomia**

The salivary glands derive their fluid with electrolytes, small organic molecules, and macromolecules. Secretion occurs in response to nervous stimulation. Interference with the supply of blood to the gland may lead to decrease in the production of saliva [31, 36, 37]. The secretory cells, the blood supply, and the nerves may all be affected by ionizing radiations. Serous cells are more sensitive to the radiation than the mucous secreting cells. After radiotherapy, the produced saliva is in reduced amount and thicker. Initially, saliva becomes more viscous and lubrication is decreased, as the salivary gland damage progresses. The lips become dry and cracked, and swallowing (dysphagia) and chewing become difficult with pain [38, 39].

The hyposalivation was regarded as a short-term side effect for quite a long-term. In the case of patients undergoing radiotherapy, especially in the area of head and neck irradiation (rare in children), immediate organ toxicity has been described, which could last there for a long time; the patients felt improvement just after 4–12 months [40]. According to Nemeth et al. study, one can draw the conclusion that hyposalivation can be regarded as a long-term side effect after only chemotherapy. Even if this low secretion improves under or after the direct treatment improved a bit, it never ever reaches the pretreatment state [41].

Unstimulated and stimulated saliva flow rate after cancer therapy (radiotherapy and chemotherapy) shows decreasing values. It seems the minor salivary glands constantly try to

compensate an appropriate amount of saliva. Nemeth et al. believe that the slight damage in the major salivary glands caused in these children by the chemotherapy was not a real reason for this, since it was compensated by the minor salivary gland function and that is the reason why unstimulated whole saliva flow rate was normal and the buffer capacity of the saliva was higher than in the healthy controls [41].

Lee et al. investigated patients suffering from xerostomia and concluded that the palatal salivary secretion remains held. The palatal minor salivary glands play a protection function in the oral cavity saliva balance with their operation after chemotherapy [42, 43].

Management involves non-alcohol-based mouth rinses, saliva substitute, methyl cellulose, frequent intake of water, and neutral sodium fluoride application [44].

### **2.3. Herpes virus**

Herpes simplex manifests labial and oropharyngitis which may lead to generalized sepsis. Clinically, the lesions appear as clear vesicle eruptions in cluster on the erythematous base, but herpesvirus infection can occur as nondescript and atypical appearance.

Herpes simplex and Herpes zoster infections are acute effects, but when immunosuppression is protracted, persistent infection can occur as indolent ulcers [45–48].

Management includes prevention and treatment with oral or intravenous acyclovir. Oral acyclovir needs large doses because 20–30% of drug is absorbed (750 mg/m<sup>2</sup> per day given every 8 h) [45–48].

### **2.4. Candida**

The most common mucosal infection is thrush, a superficial infection due to *Candida albicans*. Clinically, the lesions appear as whitish plaques with indurated borders.

Careful attention should be paid to oral hygiene. Clotrimazole troches, nystatin suspension, and oral fluconazole are used to treat the infection (50–100 mg per day) [45, 46].

### **2.5. Dental caries and periodontal status**

Because of the hyposalivation that is an acute side effect of cytostatic agents, children often consume sugary and carbonated soft drinks. As a result of this, the pH of saliva is in the acidic range for long periods because of the qualitative and quantitative changes in the mouth. Because of the oral ulceration, mucositis, and xerostomia during the treatment, the consumption of solid foods may be painful for the children who prefer the soft and mushy foods.

The tooth brushing frequency unfortunately reduces and the duration becomes shorter. These bad habits may persist later and increase late side effects. In most of the study for DMF-T index, the children had mixed so we do not get a valid value. In Dens's examination, the children were 2–17 years old; in Alberth's study they were 4–25 years old, while in Welbury et al., the oral hygiene and periodontal status of survivors of malignant cancer were between 3 and 20 years of age [49–53].

Pajari et al. and Sonis et al. measured DMF-T index, dental hygiene, and gingival index of children with ALL treated. They found the caries' frequency much higher and prevalence of gingivitis is more frequent in the survivor children's group than in the healthy ones' [54–56].

Ayanoglou et al. found gingival overgrowth in rats gum after cyclosporin A injection [57].

Saliva flow seems to play an important role in the rate of dental caries in this population, since saliva has a significant protective effect against cariogenic bacteria due to its enzymatic and immunological activity. The increased caries risk is correlated with the decreased saliva flow rate and the adverse side effect of the treatment can be hyposalivation and concomitant changes of oral microflora.

When teeth are located in the irradiation field, hypovascularity results in a decrease in the circulation through pulpal tissue and increase of the collagen cross-links hydroxylysylpyridinoline and lysylpyridinoline [21]. The effect of radiation on vascular flow to the dentition as a whole also plays a role in this multifaceted caries-promoting cycle [58]. Caries is the main factor contributing to the atypical and comparatively rapid progress of irradiation caries, which may not be explained by hyposalivation alone [16, 59–69]. The increased stiffness is hypothesized due to a radiation-induced decrease in the protein content, with a much greater reduction in the enamel sites as compared to dentin. These changes of mechanical properties and chemical composition can contribute to DEJ biomechanical failure and enamel delamination [Reed]. It was observed that minimal tooth damage occurs below 30 Gy; there was a 2–3 times increased risk of tooth breakdown between 30 and 60 Gy likely related to salivary gland impact; and a more increased risk of tooth damage when the tooth-level dose is above 60 Gy indicating radiation-induced damage to the tooth in addition to salivary gland damage. These findings suggest a direct effect of radiation on tooth structure with increasing radiation dose to the tooth [70–75]. Thus, radiogenic dental damage is the result of reduced salivary flow, as well as possible direct radiogenic damage [76].

Management: try to avoid cariogenic foods and drinks. Perform routine daily personal oral care including biofilm removal and fluoride application (gel and rinse). Dental check up is useful every 3 months.

### 3. Late effects

#### Radiotherapy

Late consequences of children cancer can be anticipated based on exposures, but the magnitude of risk and the manifestations in an individual patient are influenced by numerous factors (Table 2). There are total dose, fraction size, organ or tissue volume, and type of machine energy in radiotherapy. The extent of oral late effects is dependent upon the age of the children, at the time of treatment.

The lack of specificity of radiotherapy in terms of differentiating neoplastic cells from metabolic active cells may result in dental and craniofacial abnormality. This is a direct effect of



#### Chemotherapy

- Hyposalivation
- Craniofacial effects
- Orodontal disturbances
  - Tooth agenesis
  - Microdontia
  - Enlarged pulp chamber (taurodontism)
  - Enamel hypoplasia (hypomineralization)
  - Enamel discoloration
  - Short, tapered, and blunted roots

#### Radiation therapy

- Taste alteration
- Xerostomia
- Radiationcaries
- Osteoradionecrosis
- Muscular trismus
- Orodontal disturbances
  - Tooth agenesis
  - Microdontia
  - Enlarged pulp chamber (taurodontism)
  - Enamel hypoplasia (hypomineralization)
  - Enamel discoloration
  - Short, tapered, and blunted roots
- Craniofacial effects

#### Hematopoietic cell transplantation (HCT)

- Xerostomia (respond pilocarpine injection)
  - Nongingival soft tissue growth (like pyogenic granuloma)
  - Exophytic soft tissue lesion
  - Gingival hyperplasia
  - Mucosal lichenoid changes
  - Mucocele
- 

**Table 2.** Late-term effects of cancer therapy in CCS.

therapy on growing cells. Indirect effects of therapy may occur in altered hypothalamic-pituitary function resulting in diminished growth hormone production [7–11].

Hard tissue development of craniofacial region occurs with intramembranous and endochondral bone formation and odontogenesis, and the adjoining soft tissue influences hard tissue development. Radiation level of 200cGy in the patient under 6 years of age may be observed with microscopic changes, and when a radiation is greater than 1800 cGy, it affects the calvaria growth and growth in the anteroposterior length. Anomalies of cranial base and orbital development result in a lack of midface development. Enucleation and orbital radiotherapy in growing child age can inhibit the growth of bony structure and detrimental to facial growth especially on transverse facial development. Denys et al. said children with retinoblastoma treated with 3000 cGy are at high risk of craniofacial deformities. Sonis et al. studied craniofacial abnormalities as measured by cephalometric analysis and observed significant deficient mandibular development in 2400 cGy RT before 5 years of age group. Studies of mandibular growth suggest irradiation must exceed 1800 cGy before it is detectable clinically.

Kaste and Hopkins describe a patient with maxillary hypoplasia after 10 years of therapy.

Do not forget craniofacial growth which is not proportional. While calvarial growth is almost completed by age 5 years, the nasomaxillary complex and mandible continue to grow throughout adolescence explaining the huge differences in facial appearance of the 1 and 18 years of age. Most studies may suggest that after 12 years of age radiation-induced facial growth alterations are negligible [77–81].

Growth of alveolar bone is completely dependent on the presence, eruption, and root length of teeth. Odontoblasts are most susceptible to low-dose radiation just prior to their initiation of dentin matrix formation, because presecretory odontoblasts are rapidly proliferating. Following radiotherapy, odontoblastic mitotic activity ceases. Defective enamel is created, because osteodentin interferes with the normal interaction of dentin and enamel. Enamel and dentin defects lead to tooth dwarfism, blunted and tapered root, incomplete calcification, premature apical closure, and lack of eruption [77, 78, 82–87].

## Chemotherapy

The late effects of only chemotherapy on the dental- and craniofacial development are limited but some studies of the last 10 years have been shown to affect facial growth directly in humans **Table 2**.

Two chemotherapeutic agents, methotrexate and ifosfamide are well known in the protocols. Both of them are well-known and documented about the negative impact on the growth of bone system. The folic acid antagonist methotrexate can be found in most of the protocols against leukemia and osteosarcoma. Methotrexate over the activity of osteoblasts and osteoclasts decrease the activity of the increasing negative effect on the bone volume and shape. Stanislavljevic and Babcock repeatedly documented osteoporosis and various fractures among children treated against leukemia [88]. Not only after the long-term treatment with MTX, but

among the osteosarcoma patients treated with high-dose methotrexate of short-term therapy, Ecklund et al. showed similar lesions in 1997 [89].

After cyclophosphamide analogue ifosfamide treatment, Fanconi syndrome were described several times, which may lead to irreversible impairment of the kidney (hypocalcemia and hypophosphatemia) in the isotretinoin treatment of neuroblastoma, which describes diffuse cortical hyperostosis, ligaments calcification, and periostitis as side effects [90].

Reade and Roberts had already described the cyclophosphamide's negative impact on the development of the rat's incisor in 1978 [91]. Burn Murdoch also mentioned the negative effect of cyclophosphamide [92]. Mataka et al. demonstrated the inhibition of dentinogenesis in the case of vinblastine and colchicine-treated rats [93]. Animal studies have shown that the chemotherapeutic drugs induce qualitative and quantitative changes in the dental tissue, and inhibit the tooth eruption and odontogenesis. The chemotherapeutic agents received between 1 and 5 years of age have negative impact on the rapidly dividing ameloblasts and odontoblasts, and the disorder of the ameloblast's production, the reduction of secretory function, the permeability of membrane and this can lead to the changes in calcium homeostasis. It causes inhibition of the formation of dentin, colchicine, vinblastine, which is dose dependent, of course. This was proved with animal experiments by Mataka et al. Moe et al. wrote three articles about the impact of vinblastine on ameloblasts in 1977 [93–96]. Lyaruu et al. studied the effect of actinomycin-D on the tooth development of hamsters, where it was found that depending on the size of the dose, the preodontoblasts necrotize, and the proliferation and differentiation do not occur. During their human studies, Hsieh et al. confirmed the results of Kaste et al., and noticed that above 7500 mg/m<sup>2</sup> of cyclophosphamide entry, there will be serious dental abnormalities [85, 97].

## HSCT

Chronic GVHD occurs later in the transplant course, typically after day 100. Xerostomia, oral mucositis, and mucosal ulceration are frequent manifestations of chronic GVHD [98]. Dysphagia and pain on swallowing are common effects after HSCT [99–101]. Intensive chemotherapy and high-dose total body irradiation preceding SCT and young age at transplantation (that is mean before 6 years of age) lead to the worst dental and craniofacial late effects **Table 2**.

Calcification of permanent teeth begins after birth, taking 15–17 years (excluded third molars). After dental crown development, the cells of Hertwig epithelial root sheath initiate dental root development that can be seen on orthopantomogram or CBCT starting at age 3 years to 8 years. It is a slow and long process. The first sign of dental disturbances can be expected in 1–2 years. The same treatment can lead to dental agenesis or microdontia in an early age of life or tapered and blunted root later. The disturbing effect of HSCT is dependent on chemotherapeutic agents and irradiation. It has been revealed in animal and in vitro studies [96, 102, 103].

Decreased salivary function is a common finding in patients with GVHD who respond well to pilocarpine administration [39].

### 3.1. Impact of cancer therapy on tooth development

#### 3.1.1. *Delayed odontogenesis*

Odontoblasts' activity decreases, which results in a change in the secretion of the microtubules, and thus resulting in a different tooth crowns' and roots' development.

The cronology of human dentition may vary between wide limits nevertheless among the cytostatic treatments' late side effect in delayed eruption and retention can be commonly seen.

Several controversial literatures can be found about the standard of the development of the teeth. One the most common and widest range was published by Kronfeld, in 1935, who dealt with the development of the teeth calcification. Kronfeld's modified chronology is used most widely.

During the development of enamel, because of the inducing effects of the predentin selected by the odontoblasts, the ameloblasts emits dentinenamel junction, which separates the enamel crystals and the dentin.

The ameloblasts' apical end is stretched and the granular texture of Tomes' processes is formed. This, peeled from the cell, gives the organic matrix of the enamel prism. This is followed by the calcification process, where millions of crystals deposit in the matrix—here hypomineralized enamel is formed due to the effect of cytostatics on the Ca balance) [104].

#### 3.1.2. *Dental disturbances*

##### 3.1.2.1. *Enamel anomalies and hypoplasia*

The cytostatic agents alter the cell cycle, the regeneration of ameloblast's reproduction, and the membrane's permeability. As a result of this process, an irregular surface of the enamel and enamel matrix is created, which changes the opacity of the enamel, and can lead to color differences and hypoplasia.

In the 80% of children who sustained remission but had been treated with chemotherapy, structural abnormalities was found in the enamel [105–107]. Vincristine, cyclophosphamide, and actinomycin can disturb the odontogenesis as well. Besides this, the amelogenesis also becomes impaired, which may create the emergence of hypomineralized enamel [96, 108, 109].

According a study by Alpaslan et al., among children treated with chemotherapy, the enamel discoloration's frequency was 57%, while in the healthy control group received no cancer treatment the enamel disturbance was 13%. Hypoplasia was observed among the 47% of the recovered children—this value was 15% among the healthy ones [110].

Oguz's study carried out in 2004 showed similar results. According to their study, the most common disorder was the enamel discoloration (67% vs. 25%) and enamel hypoplasia (56% vs. 44%) [111]. If the children were 5 years old or more at the time of the diagnosis of malignant

tumors, the enamel discoloration (71%) and the hypoplasia (58%) were significantly higher [111].

Minicucci et al. showed the effect of cytostatic agents causing enamel anomalies. Among the 71 % of children treated with chemotherapy, detectable difference could be seen [112].

### 3.1.2.2. *Dentin anomalies*

Ayanoglou et al. examined the effect of cyclosporine A (CsA) in rats' molars. The reduction in dentin matrix mineralization and time prolongation was observed in the process, and as a consequence of this, lesions similar to dentinogenesis imperfecta starts in the dentin [57, 113].

The tooth development begins to form between the 6th and the 8th week of the prenatal development, and permanent tooth start to form in the 20th week and **can last until the 21th year** [114]. Thus, not only the in prenatal, but the postnatal diseases also can create serious malformations. The 4 years prior to the period of the tooth change are the most important and also the most critical period regarding the development of the permanent teeth. Chemotherapy given during this period has a negative impact on the rapidly dividing ameloblasts and odontoblasts. It can lead to malformations in the ameloblast's productions, decrease in the secretory functions, and changes in membrane permeability and the calcium homeostasis. Colchicine and vinblastine can cause inhibit the formation of dentine, which is dose dependent [93]. Moe et al. wrote three articles about the effect of vinblastine on ameloblasts in 1977 [95, 115]. Lyaruu et al. studied the effect of actinomycin-D on the tooth development of hamsters. They found that, depending on the size of the dose, the preodontoblasts necrotize. The proliferation and differentiation does not occur. Hsieh et al. confirmed the results of Kaste during their human studies saying that above 7500mg/m<sup>2</sup> cyclophosphamide entry, there will be serious dental abnormalities [97].

Fromm et al. studied ear, nose and throat, ophthalmological, and dental differences of children with soft tissue sarcomas 5, 5 years after the completion of the treatment [79]. In 93% of the children, some dental abnormalities were found, and in 73%, there were short roots and agenesis. The decrease in parotid saliva production was detected in 23% of the cases.

In the study, the patients were not differentiated according to the treatment, so it is likely that the big difference was because of the children who underwent radiotherapy.

Estilo et al. investigated children diagnosed with head and neck region rhabdomyosarcoma [105]. Dental malformations were found in the case of 8 children from 10.

### 3.1.3. *Anodontia and hypodontia*

The hypodontia usually shows familiarity disorder. Acquired forms occur in children treated with radiation therapy or chemotherapy as the developing teeth are extremely sensitive to these chemical and physical disturbances.

Among children treated with chemotherapy, the frequency of hypodontia is supported by several international studies.

Alpaslan et al. found hypodontia among the 50% of children treated cytotoxic due to Hodgkin and non-Hodgkin's lymphoma [110]. Based on studies of Oguz et al., in which 36 children previously treated with chemotherapy for non-Hodgkin's lymphoma were observed, they found agenesis in the 44% of the test group, while in the control group, they found it in only 9 people that is 25% [111].

Kaste et al. found hypodontia in the half of 22 patients of rhabdomyosarcoma, and in 77% of the cases, other oral lesions were observed [84]. Kaste et al. observed 52 active children with neuroblastoma in the stage of tooth development. In 71% of them, dental deviations were detected and in 21%, hypodontia were observed [85].

Avsar et al. studied 96 malignant disease's survivor: agenesis was found in 19.8% [116]. Holttä et al. observed hypodontia of 31% between the 1-year survivors of benign and malignant tumors [117].

#### 3.1.4. *Microdontia*

Microdontia is morphological anomalies the disorders in the size and shape of the teeth. In order to determine the tooth size differences, we compare these differences to the permanent teeth during the clinical tests. Garn et al. conducted a number of studies and determined the size of the average values of teeth in the second half of the last century [118, 119]. There are several tables about these figures in Wheeler's dental anatomy book.

One of the most common disorders in the size and shape of the teeth are the microdontia and taurodontismus (Appendix 1). These changes cause aesthetic, functional, and occlusion problems to the patient who needs professional dental care in adult's age.

The microdontia—similar to the hypodontia—is considered as a late side effect of radiation therapy, although several studies have shown that not only the X-ray radiation, but some cytostatics may cause microdontia, hypodontia, enamel hypoplasia, and root developmental differences (Appendix 1).

Minicucci et al. reported 76 children treated for cytotoxic drugs because of ALL [112]. From these data, it is clear that in childhood the cytostatic treatment received under the age of 6 years can cause microdontia.

Oguz et al. found microdontia in only 1 child from 36 children treated with chemotherapy due to NHL [111].

Jaffe et al. tested 68 patients who had been treated against cancer earlier. Twenty-three of them received only chemotherapy [77]. Based on their observations, higher incidence of the praemolaris' microdontia occurred in the group, which received cytostatic treatment earlier. This article does not mention the exact time, but most of the treatments could happen in the development of the premolars.

Nunn et al. [2, 120] during their examination found microdontia or indications in 27% cases of 52 children with hematology cancer. Less than a quarter of those children diagnosed with

the malignant hematological disease received radiation, and this did not affect the head and neck region.

Höltta et al. observed the dental differences of children treated with neuroblastoma in their follow-up studies. Agenesis was observed in all members of the TBI group, while relevant differences occurred in 40% of the chemotherapy group [121]. Microdontia was found in 80% cases of children participating in the study [121].

### 3.1.5. Root malformation

#### 3.1.5.1. Taurodontism

Taurodontism is defined as a disorder when the molar tooth crown will extend at the expense of the roots, so the bifurcation (or trifurcation) is close to the root tips. This means that the tooth will be a column, which is based on divergent short. Cytostatics received in the early years of life prevent or slow the formation of Hertwig epithelial root sheath, thereby forming taurodontism [122].

Kaste et al. examined 423 children treated with ALL cytotoxic drugs. In the case of 6 % of the children, taurodontism was observed [86].

Jaffe et al. also observed taurodontism in children after chemotherapy. They tested 23 children who received cytostatic treatment only, and they also showed microdontia and amelogenesis imperfecta differences [77].

Nunn et al. found taurodontism among the 27% of children treated with chemotherapy [120].

Lopes et al. found this lesion in 14% of the cases during the examination of 137 children with solid tumors and lymphoproliferative [123] (Appendix 1).

#### 3.1.5.2. Thin, short, and tapered roots

The cytostatic agents change the ameloblast's reproduction which reduces the secretory function, the membrane permeability, and change calcium homeostasis. This could lead to disorders of enamel formation, which can result in the development of thin, short, and fragile roots. At the time of the tooth crown mineralization development, the root development begins. The crowns of the large incisors and the first molars can be seen on X-rays around at the age of three. As the tooth development is a long-term process, the lesions can be detected only after some years (Appendix 1).

The effects of cytostatic agents on the crown and root development have been supported with animal studies as well. Nasman et al. gave 13–30 mg/kg cyclophosphamide 1 ml of 0.9% NaCl to 18 between 3 and 10 days of age [124]. Disorders were found in the first and second molars, and the third molars (wisdom) teeth of the rats in the SEM examinations. The first and second molar roots were shorter and thinner than the average. In the case of the third molars, there were not only differences in root development, but crown deficit was detected as well [125].

Rosenberg et al.'s investigation confirms that the root brevity and slow mineralization are frequent among children with cytostatic treatment frequent [126].

Oguz et al. found root deformation in 23 teeth of nine children from the examination of 36 children. Most of the anomalies were noticed in the lower central and lateral incisors, but the premolar and molar roots also showed lesion [111].

Alpaslan et al. observed premature apexification in the 6% of the patients, while other malformation affecting the roots occurred with 44% incidence [110]. Kaste et al. described that in 54% of 22 children treated with cytotoxic drugs due to rhabdomyosarcoma, some tooth root malformations were detected [86].

Marec-Berard et al. tested the dental developmental differences of children with Wilms' tumor depending on the duration of chemotherapy [127]. At least one tooth developmental difference was found in 70% of the examined children. Before this, in 2002, they tested children with Ewing sarcoma where in 50% of them, root malformations were found [128].

Rosenberg's study examined 17 patients who received cytostatic agents because of ALL: in the case of 5 patients, the praemolaris' shortened roots were well demonstrated by X-ray, and in the case of 13 children, much thinner roots were found [126].

Runge et al. drew attention to the orthodontic difficulties due to the malformations in the root development. The high forces applied to the fixed devices can trigger external resorption in the above shorter roots [129].

## 3.2. Craniofacial effects

### 3.2.1. Osteoporosis and catch up growing

It was assumed that the chemotherapeutic agents affect the craniofacial development. The only question is that these consequences are temporary or permanent changes. Vincristine and doxorubicin experiments in young rats by Karsila et al. showed that the first vincristine injection has a crucial role in the skull development, but 100 days after the exposure, the lag is caught up [130]. The female rats regenerated significantly faster and achieved the development of the young rats not treated with chemotherapy. It was also found that all vincristine received rats' cranial values differ from the healthy control animals and the animals treated with doxorubicin. The length and height of the mandible, the front and rear face height is significantly different in the case of the vincristine-treated rats.

The serum levels of Ca and P is normal or low, after the chemotherapy treatment since the supportive treatments include vitamin D and calcium supplementation. During 1–2 years of chemotherapy, the bones' mineral content is reduced so routine ultrasound bone measurements are done. After the treatment, an increased 'importing' growth starts; the growth curve is higher than the normal increment, so the vitamin D and calcium supplementation is important. The permanent tooth's development will be completed, however, and therefore shorter roots are established. After the end of the treatment, the bone age will be 1–1.5 years less compared to the chronological age, and the dental age will be 1–1.5 more years older.



Halton et al. found abnormal extremely low-1, 25 dihydroxyvitamin D3 synthesis with calciuria of ALL children, which caused the deficiency of calcium and phosphorus that reduced bone mineralization. The children undergone cancer treatment, especially if the protocol contained antifolate (MTX), alkylating agents (ifosfamide) or plain agents (cisplatin) [131, 132].

Fanconi syndrome (proximal tubular toxicity) can occur with calciuria and hypophosphatemia. ALL Halton and his co-s examined children treated with ALL, and found changes in bone mineralization, in the process of vitamin D metabolism and several skeletal discrepancies [132]. The amount of bone decrease and the risk of fractures increase. The bone hemostasis degrades because of the decrease in the resorption of the intestinal calcium and the increased calcium usage. Nesbit et al. wrote about this in 1976 [133]. They diagnosed the signs of osteoporosis. Clinicians try to maintain a balance with bisphosphonates, inhibiting the increased osteoclast activity that leads to osteolysis. They prevent the formation of macrophages, from monocytes; reduce the phagocytosis and cytokine production.

The bone growth of children with cancer and leukemia treatment is affected by the high dose and intensive steroid. It is very important to notice the damage on time. (e.g., fractures, cartilage formation disorder, and deformity). Certain chemotherapy treatments can affect hormone production, which leads to osteoporosis, or thinning bones (trabecular structure is maintained, but the quality varies). Although the hormone levels return to normal after treatment, the bone density does not return to normal level. Suitable calcium and vitamin D supplementation is necessary. Both osteoporosis and periodontitis are risk factors but these lesions were not reported in children. However, differences were found in the skull's development. Kaste's Working Group dealt with the issue of bone age, chronological age, and dental age. They found that the chronological age of the bone is lower and the dental age was significantly higher in children who underwent cancer therapy [134].

Karsila-Tenovuo et al. tested 40 children; in the 1st group, there were 18 children who received 1 cranial irradiation and chemotherapy, eight of them got hormone therapy. In the 2nd group, there were 11 children with extracranial solid tumor treated with alkylating agents, while 11 children with Wilms' tumor belonged to Group 3 who received only chemotherapy [135].

Normal growth was found in the second group. In the group 3, the cephalometria results remained within the normal range, except for certain details of the maxilla and the rear face height [135].

#### **4. Common Toxicity Criteria**

The WHO Common Toxicity Criteria (CTC) was founded in 1999; it currently has 4:03 version in force, which was modified in 2010 under the name Common Terminology Criteria for Adverse Events (CTCAE). The table is included in the "Gastrointestinal System Differences" cheilitis and gingivitis, lip pain, mucositis, oral fistula, pain, periodontal disease, dental mal formations, dental pain, "Systemic side effects", the facial pain, "Infectious Diseases" the gingivitis, the lips, mucous and infectious diseases, sinusitis salivary glands. In the

"musculoskeletal system diseases," the mouth bone necrosis and trismus, in the "The neurological lesions" the dysgeusia, the mimical- and chewing muscle weakness, facial nerve lesions, trigeminal neuralgia, and sinus pain, and in the "Skin and subcutaneous lesions," the oral cavity, erythema multiforme, pruritus, and purpura were included.

## **5. Follow-up guidelines for survivors of childhood, adolescent, and young adult cancers**

All children undergoing high-dose chemotherapy and/or radiotherapy or SCT should be referred for dental and oral hygiene assessment prior to commencement of therapy. All children with diagnosis of malignant disease should be encouraged to maintain good oral hygiene, which requires not only tooth brushing but proper oral hygiene during and after anticancer therapy. Our guidelines are shown in **Figure 1**.

It is important to know the possible side effects encountered in the treatment. The family must be provided with the proper advice according to the changed life situation (daily routine, nutrition, oral and dental hygiene). The play specialist has an important role in facilitating the child's understanding of cancer therapy. They make use of various types of play and game depending on the child's needs, age, culture issues, and understanding to provide information about hospitalization and teach new information [136, 137].

During the treatment, a specialized team (dental hygienist) should monitor the daily oral hygiene routine for children, as many banal and painful infections can be prevented.

The oral hygiene habits should be immediately restored after the completion of therapy, in order not to increase the serious side effects.

In my opinion, the children undergone cancer therapy should be controlled in every 3 months during the first year, but from the next year, it does not have to be more frequent, rather more thorough and accurately documented. The most important is that parents do not have to forget the necessary check-ups.

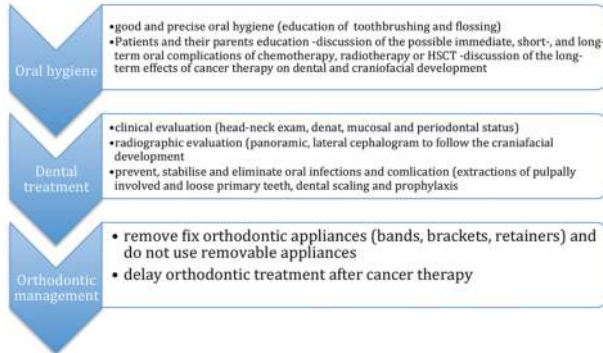
The dental care of children with malignant disease does not differ from the healthy ones, except for the invasive interventions. It would be interesting and obvious that children cancer patients should belong to territorial care pedodontists, but unfortunately the current children's dental network is not suitable in many countries for this because the children will not receive effective care.

It would be worth to follow and treat them in the university center, near the oncology centers. It will be good to create a patient card, where the dental status of the survivors could be followed.

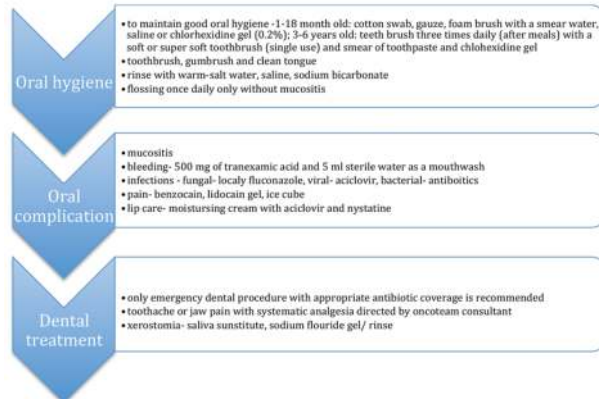
It is important to mention here that cooperation between pediatric clinics and dental clinics should be encouraged to enforce the implication of oral preventive measures for children in chemotherapy in a way to improve their oral health. Clinicians and dentist should provide treatment to improve both the oral hygiene and the nutritional status of children cancer survivors.

## Dental management for children with diagnosis of malignant disease

### Pre-treatment



### During cancer therapy



### Post-treatment

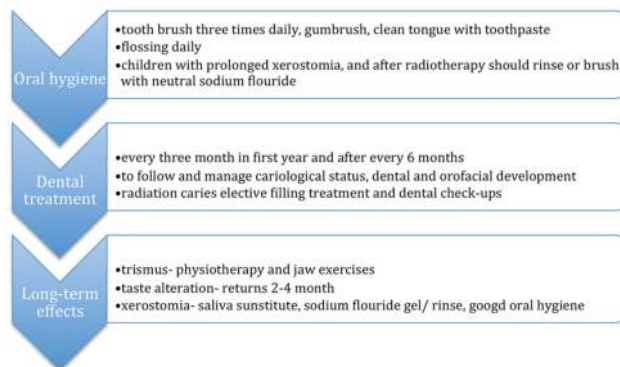


Figure 1. Dental management for children with diagnosis of malignant disease.

## Appendix 1

### Disturbances

#### Delayed odontogenesis

The chronology of human dentition may vary between wide limits nevertheless among the cytostatic treatments' late side effect in dentitio tarda and retention dentis can be commonly seen.

The most sensitive age for dental disturbances is 2–5 years of age. Microdontia (orange arrows), Delayed eruption of second premolar (blue arrow).

#### Shape and size of teeth

The most frequented anomalies of shape and size of teeth development are microdontia (blue circles) and aplasia.

### Disturbances

#### Microdontia

Microdontia is in the most of cases late effects of radiotherapy.

#### Thin, short, and tapered roots

Late effects of cancer therapy are anomalies of root development (blue circles).

#### Taurodens

Taurodens is defined as a disorder when the molar tooth crown will extend at the expense of the roots, so (red circles).

### Disturbances

Delayed eruption of second premolars.

Taurodens of first molars.

## Abbreviation

5-FU	Fluorouracil, a drug used in medicine
ALL	Acute lymphoblastic leukemia
Ca	Calcium
CBCT	Cone beam computed tomography
CTCAE	Common Terminology Criteria for Adverse Events
CsA	Cyclosporin A
DEJ	Dentinoenamel junction

DMF-T index	Decay-missing-filled index, a quantification of dental caries burden
GVHD	Graft-versus-host disease
Gy	Gray, SI unit of absorbed radiation
HNC	Head and neck cancer
HSCT	Hematopoietic stem cell transplantation
MTX	Methotrexate, a drug used in medicine
NHL	Non-Hodgkin lymphoma
P	Phosphorus
pH	Numeric scale used to specify the acidity or basicity of an aqueous solution
RT	Radiation therapy
SCT	Stem cell transplantation
TBI	A form of radiation therapy used most commonly in bone marrow transplantation
WHO CTC	World Health Organization Common Toxicity Criteria

## Author details

Orsolya Németh

Address all correspondence to: [drnemethorsolya@gmail.com](mailto:drnemethorsolya@gmail.com)

Department of Community Dentistry, Semmelweis University, Budapest, Hungary

## References

- [1] Melsen B. Palatal growth studied on human autopsy material. A histologic microradiographic study. *Am J Orthod.* 1975;68(1):42–54.
- [2] Persson M, Thilander B. Palatal suture closure in man from 15 to 35 years of age. *Am J Orthod.* 1977;72(1):42–52.
- [3] Enlow DH, BANG S. Growth and remodeling of the human maxilla. *Am J Orthod.* 1965;51:446–64.
- [4] Carlson DS, Buschang P. Craniofacial growth and development: evidence-based perspectives. In: Graber LW, Vanarsdall RL, Vig KWL, editors. *Orthodontics Current Principles and Techniques.* Philadelphia: Elsevier Mosby; 2012. pp. 215–43.
- [5] Sarnat BG, Shanedling PD. Postnatal growth of the orbit and upper face in rabbits after exenteration of the orbit. *Arch Ophthalmol.* 1965;73:829–37.

- [6] Ten Cate AR. Development of the tooth and its supporting tissues. In: Ten Cate AR, editor. *Oral Histology Development, Structure and Function*. Missouri: Mosby; 1985. pp. 56–77.
- [7] Petrovic AG, Oudet CL, Shaye R. [Mandible positioning with a maxillary activator appliance with lateral occlusal blocks of various heights in relation to daily treatment time]. *Fortschr Kieferorthop*. 1982;43(4):243–70.
- [8] Lavergne J, Petrovic A. Discontinuities in occlusal relationship and the regulation of facial growth. A cybernetic view. *Eur J Orthod*. 1983;5(4):269–78.
- [9] McNamara JA, Carlson DS. Quantitative analysis of temporomandibular joint adaptations to protrusive function. *Am J Orthod*. 1979;76(6):593–611.
- [10] Sandler TW. Head and Neck. In: Sandler TW, editor. *Langman's Medical Embriology*. Philadelphia: Lippincott Williams & Wilkins; 2012. pp. 260–87.
- [11] Ten Cate AR. Dentinogenesis. In: Ten Cate AR, editor. *Oral Histology Development, Structure and Function*. Missouri: Mosby; 1985. pp. 129–46.
- [12] Kun L, Moulder J. General principles of radiation therapy. In: Poplack DG, Pizzo AP, editors. *Principles and Practice of Pediatric Oncology*. Philadelphia: J.B. Lippincott Company; 1993. pp. 273–303.
- [13] Doline S, Needleman HL, Petersen RA, Cassady JR. The effect of radiotherapy in the treatment of retinoblastoma upon the developing dentition. *J Pediatr Ophthalmol Strabismus*. 1980;17(2):109–13.
- [14] Rubin P. The Franz Buschke lecture: late effects of chemotherapy and radiation therapy: a new hypothesis. *Int J Radiat Oncol Biol Phys*. 1984;10(1):5–34.
- [15] Naidu MU, Ramana GV, Rani PU, Mohan IK, Suman A, Roy P. Chemotherapy-induced and/or radiation therapy-induced oral mucositis--complicating the treatment of cancer. *Neoplasia*. 2004;6(5):423–31.
- [16] Epstein JB, Loh R, Stevenson-Moore P, McBride BC, Spinelli J. Chlorhexidine rinse in prevention of dental caries in patients following radiation therapy. *Oral Surg Oral Med Oral Pathol*. 1989;68(4):401–5.
- [17] Keene HJ, Daly T, Brown LR, Dreizen S, Drane JB, Horton IM, et al. Dental caries and *Streptococcus mutans* prevalence in cancer patients with irradiation-induced xerostomia: 1–13 years after radiotherapy. *Caries Res*. 1981;15(5):416–27.
- [18] Kielbassa AM, Hellwig E, Meyer-Lueckel H. Effects of irradiation on in situ remineralization of human and bovine enamel demineralized in vitro. *Caries Res*. 2006;40(2):130–5.
- [19] Kielbassa AM, Hinkelbein W, Hellwig E, Meyer-Lückel H. Radiation-related damage to dentition. *Lancet Oncol*. 2006;7(4):326–35.
- [20] Epstein JB, Chin EA, Jacobson JJ, Rishiraj B, Le N. The relationships among fluoride, cariogenic oral flora, and salivary flow rate during radiation therapy. *Oral Surg Oral Med Oral Pathol Oral Radiol Endod*. 1998;86(3):286–92.

- [21] Springer IN, Niehoff P, Warnke PH, Böcek G, Kovács G, Suhr M, et al. Radiation caries–radiogenic destruction of dental collagen. *Oral Oncol.* 2005;41(7):723–8.
- [22] Spiegel RJ. The acute toxicities of chemotherapy. *Cancer Treat Rev.* 1981;8(3):197–207.
- [23] Blatt J, Bleyer A, D C. Late effects of childhood cancer and its treatment. In: Pizzo, Philip A., and David G. Poplack editors. *Principles and Practice of Pediatric Oncology.* 6<sup>th</sup> ed. Philadelphia: J. B. Lippincott Company; 1993. p. 1091–114.
- [24] Wong KY, Lampkin BC. Anthracycline toxicity. *Am J Pediatr Hematol Oncol.* 1983;5(1):93–7.
- [25] Eghbali A, Taherkhanchi B, Bagheri B, Sadeghi Sedeh B. Effect of chewing gum on oral mucositis in children undergoing chemotherapy: a randomized controlled study. *Iran J Ped Hematol Oncol.* 2016;6(1):9–14.
- [26] Pixberg C, Koch R, Eich HT, Martinsson U, Kristensen I, Matuschek C, et al. Acute toxicity grade 3 and 4 after irradiation in children and adolescents: results from the IPPARCA collaboration. *Int J Radiat Oncol Biol Phys.* 2016;94(4):792–9.
- [27] Bardellini E, Amadori F, Majorana A. Oral hygiene grade and quality of life in children with chemotherapy-related oral mucositis: a randomized study on the impact of a fluoride toothpaste with salivary enzymes, essential oils, proteins and colostrum extract versus a fluoride toothpaste without menthol. *Int J Dent Hyg.* 2016.
- [28] Bardellini E, Amadori F, Schumacher RF, D'Ippolito C, Porta F, Majorana A. Efficacy of a solution composed by verbascoside, polyvinylpyrrolidone (PVP) and sodium hyaluronate in the treatment of chemotherapy-induced oral mucositis in children with acute lymphoblastic leukemia. *J Pediatr Hematol Oncol.* 2016.
- [29] Bardellini E, Schumacher F, Conti G, Porta F, Campus G, Majorana A. Risk factors for oral mucositis in children receiving hematopoietic cell transplantation for primary immunodeficiencies: a retrospective study. *Pediatr Transplant.* 2013;17(5):492–7.
- [30] Bleyer WA. The clinical pharmacology of methotrexate: new applications of an old drug. *Cancer.* 1978;41(1):36–51.
- [31] Sonis AL. Craniofacial development, teeth and salivary glands. In: Daniel Green, Hamish Wallace, editors. *Late effects of childhood cancer.* 1<sup>st</sup> ed. London: Arnold; 2004. p. 176–86.
- [32] Gupta A, West HJ. Mucositis (or Stomatitis). *JAMA Oncol.* 2016.
- [33] Ribeiro RA, Wanderley CW, Wong DV, Mota JM, Leite CA, Souza MH, et al. Irinotecan- and 5-fluorouracil-induced intestinal mucositis: insights into pathogenesis and therapeutic perspectives. *Cancer Chemother Pharmacol.* 2016.
- [34] Keefe DM, Rassias G, O'Neil L, Gibson RJ. Severe mucositis: how can nutrition help? *Curr Opin Clin Nutr Metab Care.* 2007;10(5):627–31.
- [35] Riley P, McCabe MG, Glenny AM. Oral cryotherapy for preventing oral mucositis in patients receiving cancer treatment. *JAMA Oncol.* 2016.

- [36] Sonesson M. On minor salivary gland secretion in children, adolescents and adults. *Swed Dent J Suppl.* 2011(215):9–64.
- [37] Sonesson M, Eliasson L, Matsson L. Minor salivary gland secretion in children and adults. *Arch Oral Biol.* 2003;48(7):535–9.
- [38] Köstler WJ, Hejna M, Wenzel C, Zielinski CC. Oral mucositis complicating chemotherapy and/or radiotherapy: options for prevention and treatment. *CA Cancer J Clin.* 2001;51(5):290–315.
- [39] Fox PC, van der Ven PF, Baum BJ, Mandel ID. Pilocarpine for the treatment of xerostomia associated with salivary gland dysfunction. *Oral Surg Oral Med Oral Pathol.* 1986;61(3):243–8.
- [40] Belfield PM, Dwyer AA. Oral complications of childhood cancer and its treatment: current best practice. *Eur J Cancer.* 2004;40(7):1035–41; discussion 42–4.
- [41] Nemeth O, Kivovics M, Pinke I, Marton K, Kivovics P, Garami M. Late effects of multiagent chemotherapy on salivary secretion in children cancer survivors. *J Am Coll Nutr.* 2014;33(3):186–91.
- [42] Lee SK, Lee SW, Chung SC, Kim YK, Kho HS. Analysis of residual saliva and minor salivary gland secretions in patients with dry mouth. *Arch Oral Biol.* 2002;47(9):637–41.
- [43] Lee YL, Santacroce SJ. Posttraumatic stress in long-term young adult survivors of childhood cancer: a questionnaire survey. *Int J Nurs Stud.* 2007;44(8):1406–17.
- [44] Ribelles Llop M, Guinot Jimeno F, Mayné Ación R, Bellet Dalmau LJ. Effects of xylitol chewing gum on salivary flow rate, pH, buffering capacity and presence of *Streptococcus mutans* in saliva. *Eur J Paediatr Dent.* 2010;11(1):9–14.
- [45] Barbería E, Hernandez C, Miralles V, Maroto M. Paediatric patients receiving oncology therapy: review of the literature and oral management guidelines. *Eur J Paediatr Dent.* 2008;9(4):188–94.
- [46] Committee AAoPDCA, Affairs AAoPDCoC. Guideline on dental management of pediatric patients receiving chemotherapy, hematopoietic cell transplantation, and/or radiation. *Pediatr Dent.* 2008;30(7 Suppl):219–25.
- [47] Sheller B, Williams B. Orthodontic management of patients with hematologic malignancies. *Am J Orthod Dentofacial Orthop.* 1996;109(6):575–80.
- [48] Singh N, Scully C, Joyston-Bechal S. Oral complications of cancer therapies: prevention and management. *Clin Oncol (R Coll Radiol).* 1996;8(1):15–24.
- [49] Welbury RR, Craft AW, Murray JJ, Kernahan J. Dental health of survivors of malignant disease. *Arch Dis Child.* 1984;59(12):1186–7.
- [50] Alberth M, Kovalecz G, Nemes J, Máth J, Kiss C, Márton IJ. Oral health of long-term childhood cancer survivors. *Pediatr Blood Cancer.* 2004;43(1):88–90.



- [51] Alberth M, Majoros L, Kovalecz G, Borbás E, Szegedi I, J Márton I, et al. Significance of oral candida infections in children with cancer. *Pathol Oncol Res*. 2006;12(4):237–41.
- [52] Dens F, Boute P, Otten J, Vinckier F, Declerck D. Dental caries, gingival health, and oral hygiene of long term survivors of paediatric malignant diseases. *Arch Dis Child*. 1995;72(2):129–32.
- [53] Dens FL, Boute P, Vinckier F, Declerck D. Salivary caries risk factors in long-term event-free survivors of pediatric malignant diseases. *J Clin Pediatr Dent*. 1996;20(3):241–5.
- [54] Pajari U, Larmas M, Lanning M. Caries incidence and prevalence in children receiving antineoplastic therapy. *Caries Res*. 1988;22(5):318–20.
- [55] Pajari U, Ollila P, Lanning M. Incidence of dental caries in children with acute lymphoblastic leukemia is related to the therapy used. *ASDC J Dent Child*. 1995;62(5):349–52.
- [56] Sonis AL, Waber DP, Sallan S, Tarbell NJ. The oral health of long-term survivors of acute lymphoblastic leukaemia: a comparison of three treatment modalities. *Eur J Cancer B Oral Oncol*. 1995;31B(4):250–2.
- [57] Ayanoglou CM, Godeau G, Lesty C, Septier D, Goldberg M. Cyclosporin A-induced alterations of dentinogenesis in rat molars. *J Oral Pathol Med*. 1997;26(3):129–34.
- [58] Squier CA. Oral complications of cancer therapies. Mucosal alterations. *NCI Monogr*. 1990(9):169–72.
- [59] Askins MA, Moore BD. Preventing neurocognitive late effects in childhood cancer survivors. *J Child Neurol*. 2008;23(10):1160–71.
- [60] Askins MA, Moore BD. Psychosocial support of the pediatric cancer patient: lessons learned over the past 50 years. *Curr Oncol Rep*. 2008;10(6):469–76.
- [61] Bielack SS, Rerim JS, Dickerhoff R, Dilloo D, Kremens B, von Stackelberg A, et al. Osteosarcoma after allogeneic bone marrow transplantation. A report of four cases from the Cooperative Osteosarcoma Study Group (COSS). *Bone Marrow Transplant*. 2003; 31(5):353–9.
- [62] Challinor J, Miaskowski C, Moore I, Slaughter R, Franck L. Review of research studies that evaluated the impact of treatment for childhood cancers on neurocognition and behavioral and social competence: nursing implications. *J Soc Pediatr Nurs*. 2000;5(2):57–74.
- [63] de Moor JS, Mariotto AB, Parry C, Alfano CM, Padgett L, Kent EE, et al. Cancer survivors in the United States: prevalence across the survivorship trajectory and implications for care. *Cancer Epidemiol Biomarkers Prev*. 2013;22(4):561–70.
- [64] De Moor R. [Direct and indirect effects of medication (including chemotherapy) and irradiation on the pulp]. *Rev Belge Med Dent* (1984). 2000;55(4):321–33.
- [65] Hockenberry M, Krull K, Moore K, Gregurich MA, Casey ME, Kaemingk K. Longitudinal evaluation of fine motor skills in children with leukemia. *J Pediatr Hematol Oncol*. 2007;29(8):535–9.

- [66] Kaemingk KL, Carey ME, Moore IM, Herzer M, Hutter JJ. Math weaknesses in survivors of acute lymphoblastic leukemia compared to healthy children. *Child Neuropsychol.* 2004;10(1):14–23.
- [67] Ki Moore IM, Hockenberry MJ, Krull KR. Cancer-related cognitive changes in children, adolescents and adult survivors of childhood cancers. *Semin Oncol Nurs.* 2013;29(4):248–59.
- [68] Krull KR, Hockenberry MJ, Miketova P, Carey M, Moore IM. Chemotherapy-related changes in central nervous system phospholipids and neurocognitive function in childhood acute lymphoblastic leukemia. *Leuk Lymphoma.* 2013;54(3):535–40.
- [69] Nathan PC, Patel SK, Dilley K, Goldsby R, Harvey J, Jacobsen C, et al. Guidelines for identification of, advocacy for, and intervention in neurocognitive problems in survivors of childhood cancer: a report from the Children's Oncology Group. *Arch Pediatr Adolesc Med.* 2007;161(8):798–806.
- [70] Grundy RG, Wilne SH, Robinson KJ, Ironside JW, Cox T, Chong WK, et al. Primary postoperative chemotherapy without radiotherapy for treatment of brain tumours other than ependymoma in children under 3 years: results of the first UKCCSG/SIOP CNS 9204 trial. *Eur J Cancer.* 2010;46(1):120–33.
- [71] Mitchell C, Pritchard-Jones K, Shannon R, Hutton C, Stevens S, Machin D, et al. Immediate nephrectomy versus preoperative chemotherapy in the management of non-metastatic Wilms' tumour: results of a randomised trial (UKW3) by the UK Children's Cancer Study Group. *Eur J Cancer.* 2006;42(15):2554–62.
- [72] Reed R, Xu C, Liu Y, Gorski JP, Wang Y, Walker MP. Radiotherapy effect on nano-mechanical properties and chemical composition of enamel and dentine. *Arch Oral Biol.* 2015;60(5):690–7.
- [73] Sanpakit K, Triwatanawong J, Sumboonnanonda A. Long-term outcome in pediatric renal tumor survivors: experience of a single center. *J Pediatr Hematol Oncol.* 2013;35(8):610–3.
- [74] Walker DA. Health status measures in young people's cancer trials; a time to move health-related quality of life up to primary outcome measures. *Qual Life Res.* 2006;15(1):159–60.
- [75] Walker MP, Wichman B, Cheng AL, Coster J, Williams KB. Impact of radiotherapy dose on dentition breakdown in head and neck cancer patients. *Pract Radiat Oncol.* 2011;1(3):142–8.
- [76] Nishihori T, Shirato H, Aoyama H, Onimaru R, Komae T, Ishii N, et al. Three-dimensional conformal radiotherapy for astrocytic tumors involving the eloquent area in children and young adults. *J Neurooncol.* 2002;60(2):177–83.
- [77] Jaffe N, Toth BB, Hoar RE, Ried HL, Sullivan MP, McNeese MD. Dental and maxillofacial abnormalities in long-term survivors of childhood cancer: effects of treatment with chemotherapy and radiation to the head and neck. *Pediatrics.* 1984;73(6):816–23.

- [78] Kaste SC, Goodman P, Leisenring W, Stovall M, Hayashi RJ, Yeazel M, et al. Impact of radiation and chemotherapy on risk of dental abnormalities: a report from the Childhood Cancer Survivor Study. *Cancer*. 2009;115(24):5817–27.
- [79] Fromm M, Littman P, Raney RB, Nelson L, Handler S, Diamond G, et al. Late effects after treatment of twenty children with soft tissue sarcomas of the head and neck. Experience at a single institution with a review of the literature. *Cancer*. 1986;57(10):2070–6.
- [80] Cubukçu CE, Sevinir B. Dental health indices of long-term childhood cancer survivors who had oral supervision during treatment: a case-control study. *Pediatr Hematol Oncol*. 2008;25(7):638–46.
- [81] Cubukcu CE, Sevinir B, Ercan I. Disturbed dental development of permanent teeth in children with solid tumors and lymphomas. *Pediatr Blood Cancer*. 2012;58(1):80–4.
- [82] Hölttä P, Hovi L, Saarinen-Pihkala UM, Peltola J, Alaluusua S. Disturbed root development of permanent teeth after pediatric stem cell transplantation. Dental root development after SCT. *Cancer*. 2005;103(7):1484–93.
- [83] Hong CH, Napeñas JJ, Hodgson BD, Stokman MA, Mathers-Stauffer V, Elting LS, et al. A systematic review of dental disease in patients undergoing cancer therapy. *Support Care Cancer*. 2010;18(8):1007–21.
- [84] Kaste SC, Hopkins KP, Bowman LC. Dental abnormalities in long-term survivors of head and neck rhabdomyosarcoma. *Med Pediatr Oncol*. 1995;25(2):96–101.
- [85] Kaste SC, Hopkins KP, Bowman LC, Santana VM. Dental abnormalities in children treated for neuroblastoma. *Med Pediatr Oncol*. 1998;30(1):22–7.
- [86] Kaste SC, Hopkins KP, Jones D, Crom D, Greenwald CA, Santana VM. Dental abnormalities in children treated for acute lymphoblastic leukemia. *Leukemia*. 1997;11(6):792–6.
- [87] Kawakami T, Nakamura Y, Karibe H. Cyclophosphamide-induced morphological changes in dental root development of ICR mice. *PLoS One*. 2015;10(7):e0133256.
- [88] Stanisavljevic S, Babcock AL. Fractures in children treated with methotrexate for leukemia. *Clin Orthop Relat Res*. 1977(125):139–44.
- [89] Ecklund K, Laor T, Goorin AM, Connolly LP, Jaramillo D. Methotrexate osteopathy in patients with osteosarcoma. *Radiology*. 1997;202(2):543–7.
- [90] Pennes DR, Ellis CN, Madison KC, Voorhees JJ, Martel W. Early skeletal hyperostoses secondary to 13-cis-retinoic acid. *AJR Am J Roentgenol*. 1984;142(5):979–83.
- [91] Reade PC, Roberts ML. Some long-term effects of cyclophosphamide on the growth of rat incisor teeth. *Arch Oral Biol*. 1978;23(11):1001–5.
- [92] Burn-Murdoch RA. The effect of corticosteroids and cyclophosphamide on the eruption of resected incisor teeth in the rat. *Arch Oral Biol*. 1988;33(9):661–7.
- [93] Mataka S. Comparison of the effect of colchicine and vinblastine on the inhibition of dentinogenesis in rat incisors. *Arch Oral Biol*. 1981;26(12):955–61.

- [94] Moe H, Mikkelsen H. On the effect of vinblastine on ameloblasts of rat incisors in vivo. 2. Protracted effect on secretory ameloblasts. A light microscopical study. *Acta Pathol Microbiol Scand A*. 1977;85(3):319–29.
- [95] Moe H, Mikkelsen H. Light microscopical and ultrastructural observations on the effect of vinblastine on ameloblasts of rat incisors in vivo. I. Short-term effect on secretory ameloblasts. *Acta Pathol Microbiol Scand A*. 1977;85A(1):73–88.
- [96] Lyaruu DM, van Duin MA, Bervoets TJ, Wöltgens JH, Bronckers AL. Effects of vincristine on the developing hamster tooth germ in vitro. *Connect Tissue Res*. 1995;32(1–4):281–9.
- [97] Hsieh SG, Hibbert S, Shaw P, Ahern V, Arora M. Association of cyclophosphamide use with dental developmental defects and salivary gland dysfunction in recipients of childhood antineoplastic therapy. *Cancer*. 2011;117(10):2219–27.
- [98] Schubert MM, Correa ME. Oral graft-versus-host disease. *Dent Clin North Am*. 2008;52(1):79–109, viii–ix.
- [99] Rodu B, Gockerman JP. Oral manifestations of the chronic graft-v-host reaction. *JAMA*. 1983;249(4):504–7.
- [100] Sullivan KM. Longterm followup and quality of life after hematopoietic stem cell transplantation. *J Rheumatol Suppl*. 1997;48:46–52.
- [101] Barrett AJ, Le Blanc K. Prophylaxis of acute GVHD: manipulate the graft or the environment? *Best Pract Res Clin Haematol*. 2008;21(2):165–76.
- [102] Stene T, Koppang HS. Autoradiographic investigation of proliferative responses in rat incisor pulp after vincristine administration. *Scand J Dent Res*. 1980;88(2):96–103.
- [103] Dahllöf G. Oral and dental late effects after pediatric stem cell transplantation. *Biol Blood Marrow Transplant*. 2008;14(1 Suppl 1):81–3.
- [104] Kaste SC, Hopkins KP, Jenkins JJ. Abnormal odontogenesis in children treated with radiation and chemotherapy: imaging findings. *AJR Am J Roentgenol*. 1994;162(6):1407–11.
- [105] Estilo CL, Huryh JM, Kraus DH, Sklar CA, Wexler LH, Wolden SL, et al. Effects of therapy on dentofacial development in long-term survivors of head and neck rhabdomyosarcoma: the memorial sloan-kettering cancer center experience. *J Pediatr Hematol Oncol*. 2003;25(3):215–22.
- [106] Maciel JC, de Castro CG, Brunetto AL, Di Leone LP, da Silveira HE. Oral health and dental anomalies in patients treated for leukemia in childhood and adolescence. *Pediatr Blood Cancer*. 2009;53(3):361–5.
- [107] Purdell-Lewis DJ, Stalman MS, Leeuw JA, Humphrey GB, Kalsbeek H. Long term results of chemotherapy on the developing dentition: caries risk and developmental aspects. *Community Dent Oral Epidemiol*. 1988;16(2):68–71.
- [108] Dahl JE. Immediate and delayed effects of repeated doxorubicin injections on rat incisor mesenchymal cells. *Acta Odontol Scand*. 1985;43(3):155–62.

- [109] Vahlsing HL, Feringa ER, Britten AG, Kinning WK. Dental abnormalities in rats after a single large dose of cyclophosphamide. *Cancer Res.* 1975;35(8):2199–202.
- [110] Alpaslan G, Alpaslan C, Gögen H, Oğuz A, Cetiner S, Karadeniz C. Disturbances in oral and dental structures in patients with pediatric lymphoma after chemotherapy: a preliminary report. *Oral Surg Oral Med Oral Pathol Oral Radiol Endod.* 1999;87(3):317–21.
- [111] Oğuz A, Cetiner S, Karadeniz C, Alpaslan G, Alpaslan C, Pinarli G. Long-term effects of chemotherapy on orodental structures in children with non-Hodgkin's lymphoma. *Eur J Oral Sci.* 2004;112(1):8–11.
- [112] Minicucci EM, Lopes LF, Crocci AJ. Dental abnormalities in children after chemotherapy treatment for acute lymphoid leukemia. *Leuk Res.* 2003;27(1):45–50.
- [113] Ayanoglou CM, Lesty C. Maintenance of new cementum formed during cyclosporin A administration after suspension of the treatment. *J Periodontal Res.* 1997;32(7):614–8.
- [114] Sadler TW. *Langman's Medical Embryology.* 12th ed. Philadelphia, Lippincott Williams & Wilkins a Wolters Kluver; 2012.
- [115] Moe H. On the effect of vinblastine on ameloblasts of rat incisors in vivo. 3. Acute and protracted effect on differentiating ameloblasts. A light microscopical study. *Acta Pathol Microbiol Scand A.* 1977;85(3):330–4.
- [116] Avşar A, Elli M, Darka O, Pinarli G. Long-term effects of chemotherapy on caries formation, dental development, and salivary factors in childhood cancer survivors. *Oral Surg Oral Med Oral Pathol Oral Radiol Endod.* 2007;104(6):781–9.
- [117] Hölttä P, Alaluusua S, Saarinen-Pihkala UM, Peltola J, Hovi L. Agenesis and microdontia of permanent teeth as late adverse effects after stem cell transplantation in young children. *Cancer.* 2005;103(1):181–90.
- [118] Garn SM, Lewis AB, Kerewsky RS. Size interrelationships of the mesial and distal teeth. *J Dent Res.* 1965;44:350–4.
- [119] Garn SM, Lewis AB, Kerewsky RS. Genetic, nutritional, and maturational correlates of dental development. *J Dent Res.* 1965;44:Suppl:228–42.
- [120] Nunn JH, Welbury RR, Gordon PH, Kernahan J, Craft AW. Dental caries and dental anomalies in children treated by chemotherapy for malignant disease: a study in the north of England. *Int J Paediatr Dent.* 1991;1(3):131–5.
- [121] Hölttä P, Alaluusua S, Saarinen-Pihkala UM, Wolf J, Nyström M, Hovi L. Long-term adverse effects on dentition in children with poor-risk neuroblastoma treated with high-dose chemotherapy and autologous stem cell transplantation with or without total body irradiation. *Bone Marrow Transplant.* 2002;29(2):121–7.
- [122] Goho C. Chemoradiation therapy: effect on dental development. *Pediatr Dent.* 1993;15(1):6–12.

- [123] Lopes NN, Petrilli AS, Caran EM, França CM, Chilvarquer I, Lederman H. Dental abnormalities in children submitted to antineoplastic therapy. *J Dent Child (Chic)*. 2006;73(3):140–5.
- [124] Näsman M, Hammarström L. Influence of the antineoplastic agent cyclophosphamide on dental development in rat molars. *Acta Odontol Scand*. 1996;54(5):287–94.
- [125] Näsman M, Forsberg CM, Dahllöf G. Long-term dental development in children after treatment for malignant disease. *Eur J Orthod*. 1997;19(2):151–9.
- [126] Rosenberg SW, Kolodney H, Wong GY, Murphy ML. Altered dental root development in long-term survivors of pediatric acute lymphoblastic leukemia. A review of 17 cases. *Cancer*. 1987;59(9):1640–8.
- [127] Marec-Berard P, Azzi D, Chaux-Bodard AG, Lagrange H, Gourmet R, Bergeron C. Long-term effects of chemotherapy on dental status in children treated for nephroblastoma. *Pediatr Hematol Oncol*. 2005;22(7):581–8.
- [128] Marec-Berard P, Bergeron C, Frappaz D, Philip T, Gorry F, Chaux-Bodard AG, et al. [Anomalies of dental development in children receiving chemotherapy]. *Arch Pediatr*. 2002;9(11):1212–3.
- [129] Runge ME, Edwards DL. Orthodontic treatment for an adolescent with a history of acute lymphoblastic leukemia. *Pediatr Dent*. 2000;22(6):494–8.
- [130] Karsila S, Salmi T, Helenius H, Rönning O. Craniofacial growth of immature rats following administration of vincristine and doxorubicin. *Eur J Orthod*. 2000;22(5):545–53.
- [131] Halton JM, Atkinson SA, Fraher L, Webber C, Gill GJ, Dawson S, et al. Altered mineral metabolism and bone mass in children during treatment for acute lymphoblastic leukemia. *J Bone Miner Res*. 1996;11(11):1774–83.
- [132] Halton JM, Atkinson SA, Fraher L, Webber CE, Cockshott WP, Tam C, et al. Mineral homeostasis and bone mass at diagnosis in children with acute lymphoblastic leukemia. *J Pediatr*. 1995;126(4):557–64.
- [133] Nesbit M, Krivit W, Heyn R, Sharp H. Acute and chronic effects of methotrexate on hepatic, pulmonary, and skeletal systems. *Cancer*. 1976;37(2 Suppl):1048–57.
- [134] Kaste SC, Jones-Wallace D, Rose SR, Boyett JM, Lustig RH, Rivera GK, et al. Bone mineral decrements in survivors of childhood acute lymphoblastic leukemia: frequency of occurrence and risk factors for their development. *Leukemia*. 2001;15(5):728–34.
- [135] Karsila-Tenovuo S, Jahnukainen K, Peltomäki T, Minn H, Kulmala J, Salmi TT, et al. Disturbances in craniofacial morphology in children treated for solid tumors. *Oral Oncol*. 2001;37(7):586–92.
- [136] Vessey JA, Mahon MM. Therapeutic play and the hospitalized child. *J Pediatr Nurs*. 1990;5(5):328–33.
- [137] Webster NR, Galley HF. Nutrition in the critically ill patient. *J R Coll Surg Edinb*. 2000;45(6):373–9.