

---

# Triple Cannulation ECMO

---

L. Christian Napp and Johann Bauersachs

Additional information is available at the end of the chapter

<http://dx.doi.org/10.5772/63392>

---

## Abstract

Extracorporeal membrane oxygenation (ECMO) has emerged as an invaluable tool for bridging severe isolated or combined failure of lung and heart. Due to massive technical improvements, the application of ECMO is growing fast. While historically ECMO was initiated and maintained by cardiac surgeons, in recent times interventional cardiologists and intensive care specialists increasingly run ECMO systems independently with great success. Percutaneous ECMO circuits are usually set up in a dual cannulation mode, either as veno-venous or as veno-arterial configuration. A novel advanced strategy is the cannulation of three large vessels (triple cannulation), resulting in veno-veno-arterial or veno-arterio-venous cannulation. Both veno-venous and veno-arterio-venous cannulation may further be upgraded to veno-pulmonary-arterial or veno-arterial-pulmonary arterial cannulation, respectively. Triple cannulation expands the field of ECMO application but substantially increases the complexity of ECMO circuits. In this chapter, we review percutaneous dual and triple cannulation strategies, featuring a recently proposed unifying nomenclature. This unequivocal code universally applies to both dual and triple cannulation strategies (VV, VP<sub>a</sub>, VA, VVA, VAV, VAP<sub>a</sub>). The technical evolution of ECMO is growing fast, but it has to be noted that current knowledge of ECMO support is mainly based on observation. Thus controlled trials are urgently needed to prospectively evaluate different ECMO modes.

**Keywords:** cardiogenic shock, heart failure, ECMO, extracorporeal circulation, mechanical circulatory support, triple cannulation

---

## 1. Introduction

In 1972, the first report of successful extracorporeal membrane oxygenation (ECMO) was published [1]. Since then extracorporeal membrane oxygenation (ECMO) has emerged as a central method for supporting acute severe heart and lung failure. The current broad use of

---

ECMO was made possible by many technical improvements of tubings, surfaces, oxygenators, and other parts of the circuit. Recently, randomized and observational studies have demonstrated that the so far widely used intra-aortic balloon pumps are not as beneficial as expected in patients with shock [2, 3]. Thus, the frequency of use of ECMO will likely further increase in the future.

Strategy	Indication (example)	Principle	Exit	Reference
Bridge to recovery	Myocarditis	Replacement of organ function until recovery allows weaning of ECMO	ECMO removal	Asaumi et al. [29], Lorusso et al. [30]
	ARDS	Preoxygenation of venous blood to allow for lung-protective ventilator settings and pulmonary recovery	ECMO removal	Hoepfer et al. [18]
Bridge to transplantation	Respiratory failure from lung disease without prospect of recovery	Replacement of organ function until transplantation of the failing organ	Transplantation	Fuehner et al. [15], Schmidt et al. [17]
Bridge to destination	Terminal heart failure	Replacement of organ function until implantation of a permanent assist device	LVAD surgery	Haneya et al. [38]
Bridge to decision	Resuscitation	Replacement of organ function with the intention to gain time until decision on the final strategy can be made	Improve end organ function, assess neurological outcome on ECMO support, to evaluate the patient for a reasonable exit strategy (e.g., potential LVAD implantation)	Rousse et al. [39]
	Interhospital transfer of patients with ARDS or cardiogenic shock, refractory to medical therapy	ECMO implantation in the peripheral hospital, transfer of stabilized patient to tertiary cardiovascular center	Improve end organ function and complete diagnostics to determine exit strategy (recovery vs. permanent assist device)	Javidfar et al. [35]

ARDS, acute respiratory distress syndrome; LVAD, left ventricular assist device.

**Table 1.** Strategies of ECMO support for heart and/or lung failure.

The most common ECMO configuration is “dual-cannulation,” i.e., veno-venous (VV) or veno-arterial (VA) cannulation with two large-bore cannulae. VV-ECMO drains desaturated blood from the right atrium and returns it after oxygenation and decarboxylation again to the right atrium. By this, it works like an extracorporeal lung and is classically used in patients with severe acute respiratory distress syndrome (ARDS). In contrast, VA-ECMO drains blood from the right atrium and returns it after passing the ECMO device to the patient’s arterial system,

usually via the femoral artery toward the aorta. By this, VA-ECMO generates a large extracorporeal right-to-left shunt and primarily provides hemodynamic support, whereas the effect on oxygenation depends on several factors such as cannulation sites, the patient’s cardiac output, and respiratory function. Thus, considering the profound effects on hemodynamics and gas exchange, VA-ECMO is essentially different from VV-ECMO, and each has its own indications.

Regardless of the cannulation mode, ECMO can be used with different strategies (**Table 1**): *bridge-to-recovery*, *bridge-to-transplantation*, *bridge-to-destination*, or *bridge-to-decision*.

However, notwithstanding today’s very quick setup of the system due to major technical improvements, ECMO is an invasive life support system potentially leading to vascular complications, bleeding, thromboembolic events, and infection [4]. ECMO support can be easily initiated, but its termination in a *bridge-to-recovery* strategy requires careful weaning. Therefore, an experienced team of cardiologists, cardiac surgeons and intensive care specialists (and pulmonologists on the case of lung failure) should evaluate every patient before ECMO initiation, in order to reach consensus on the individualized therapeutic concept. Guidelines on indications, use, and weaning from ECMO support in children and adults are available from the Extracorporeal Life Support Organization (ELSO) [5]. In general and compared to other invasive therapies, the level of evidence is limited for ECMO. Large prospective trials are sparse, even if several smaller studies, case series, and registries are available. This is in part due to the acute lifesaving nature of the device, where the clinical need has passed the chance to conduct prospective studies.

Drainage	Return	Abbreviation	Figure	Draining cannula*	Supplying cannula*	Indication
V	V	VV	1	Inferior Vena cava	Superior Vena cava	ARDS
V	Pa	VPa	2	Right atrium	Pulmonary artery	Rightsided heart failure
V	A	VA	3	Right atrium	Common iliac artery	Post-cardiotomy cardiogenic shock Acute decompensated heart failure Cardiogenic shock during AMI or fulminant myocarditis Massive pulmonary embolism with shock High-Risk PCI support Extracorporeal resuscitation
V	A	VVA	4	Inferior Vena cava Superior Vena cava (or RV)	Common iliac artery	Insufficient unloading during VA-ECMO Left ventricular distension during VA-ECMO
V	A	VAV	5	Inferior Vena cava	Common iliac artery Superior Vena cava	Respiratory failure during VA-ECMO Cardiogenic shock during VV-ECMO
V	A	VAPa	6	Right atrium	Common iliac artery Pulmonary artery	Severe rightsided heart failure during VAV-ECMO Severe lung and rightsided heart failure during VA-ECMO

ARDS denotes acute respiratory distress syndrome

**Table 2.** ECMO cannulation modes.

The clinical need has also led to innovative applications for ECMO under special circumstances, beyond classical dual cannulation. The novel concept of triple cannulation addresses inadequate draining during veno-arterial ECMO and combined cardiopulmonary failure on

either veno-arterial or veno-venous ECMO. As triple cannulation resulted in a confusing use of multiple abbreviations during clinical routine, we have recently proposed a unifying terminology of ECMO cannulation modes [6].

In this chapter, we very briefly review the features of dual cannulation ECMO and then summarize current indications, pathophysiology, and strategies for percutaneous triple cannulation ECMO support. An overview on cannulation modes is given in **Table 2**. It should not remain unmentioned that other extracorporeal systems beyond ECMO are available, but these are off the focus of this chapter and are described elsewhere [7, 8].

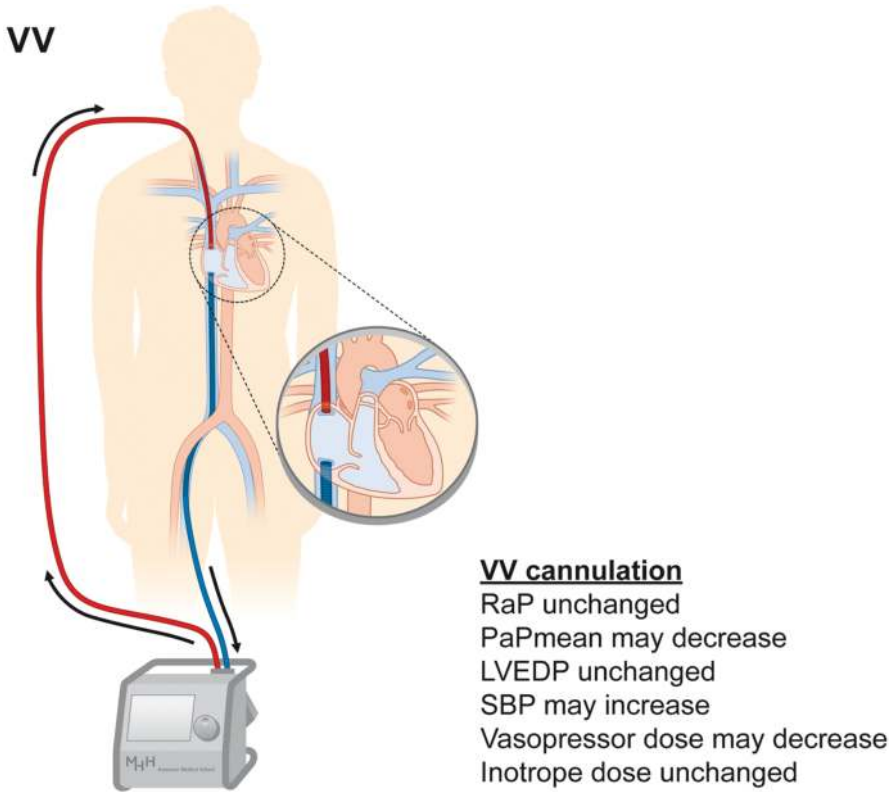
## 2. Dual cannulation ECMO

Dual cannulation ECMO may be instituted as veno-venous or veno-arterial ECMO. Both are essentially different in terms of setup, support, and monitoring.

### 2.1. Veno-venous cannulation (VV)

During VV-ECMO, deoxygenated blood is drained from the right atrium and returned after extracorporeal reoxygenation and decarboxylation again to the right atrium (**Figure 1**). ECMO-derived preoxygenated blood enters the pulmonary circuit and provides systemic oxygenation, thus allowing for establishing lung-protective respirator settings. The most common indication for VV-ECMO is ARDS [9–14]. In ARDS, ECMO is considered with a Horowitz index below 100 to 150 or uncompensated acidosis ( $\text{pH} < 7.2$ ) and has already been applied in awake patients [15–17] or even to fully avoid invasive ventilation [18]. Notwithstanding the need of prospective controlled trials, VV-ECMO has already entered center stage in severe ARDS in tertiary centers, which was further promoted by the recent H1N1 wave [19–22]. VV-ECMO should not be initiated in patients with terminal respiratory failure, when there is no perspective of organ recovery or lung transplantation.

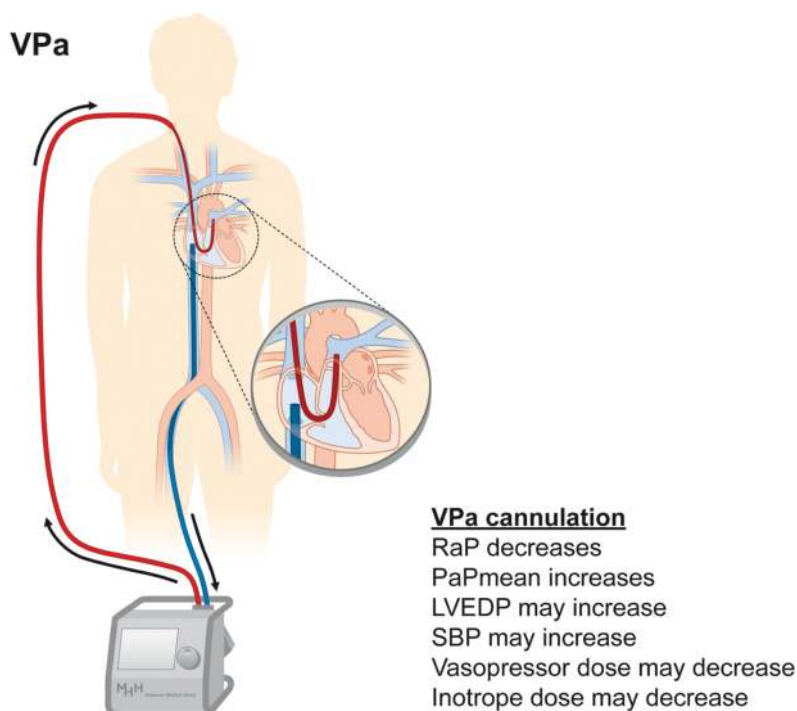
VV-ECMO cannulae are usually introduced via the femoral and jugular veins (**Figure 1**), with upper-body cannulation by using a bicaval dual lumen cannula [6, 23] only through the right-sided jugular vein as an elegant alternative. With femoral-jugular cannulation, it is essential to position the tips of both cannulae at the border between the right atrium and the caval veins (**Figure 1**) to minimize recirculation. On VV-ECMO, oxygen saturation in the central aorta results from a mixture of reoxygenation in the ECMO and remaining gas exchange in the lungs. Improvement of end organ supply often results in a reduction of vasopressors, but VV-ECMO does not influence hemodynamics *per se*, as equal blood volumes are drained from and supplied to the right atrium (**Table 1**). Right or left heart failure in patients on VV-ECMO is a potential indication for triple cannulation (see below), thus echocardiographic monitoring is very important during support.



**Figure 1.** Veno-venous ECMO (VV). VV-ECMO drains venous blood (blue) from the right atrium and the inferior vena cava and returns an equal volume after reoxygenation and decarboxylation (red) again to the right atrium. PaPmean denotes the mean pulmonary arterial pressure, LVEDP left-end diastolic pressure, RaP mean right atrial pressure, and SBP systemic blood pressure. Pressure and medication changes given in the figures are mainly derived from clinical experience and remain to be validated by dedicated studies. LVEDP denotes left ventricular end diastolic pressure, PaP pulmonary arterial pressure, RaP right atrial pressure, and SBP systolic blood pressure.

## 2.2. Veno-pulmonary-arterial cannulation (VPa)

This is a very recent modification of VV-ECMO, which has not been validated in studies and is just described here for the purpose of completeness. VPa cannulation intends to provide similar support as VV-ECMO, i.e., to drain venous blood from the right atrium and to supply reoxygenated and decarboxylated blood back toward the pulmonary circulation. The difference to VV-ECMO is that the supplying cannula does not end at the right atrium but is forwarded through the tricuspid valve, the right ventricle, and the pulmonary valve to the pulmonary artery (**Figure 2**). This has to be performed under angiographic (or transesophageal echocardiographic) guidance, and for this purpose a flexible 17-French cannula is necessary. Furthermore, the draining cannula tip should be positioned in the mid right atrium to facilitate homogenous drainage of the upper and lower body.



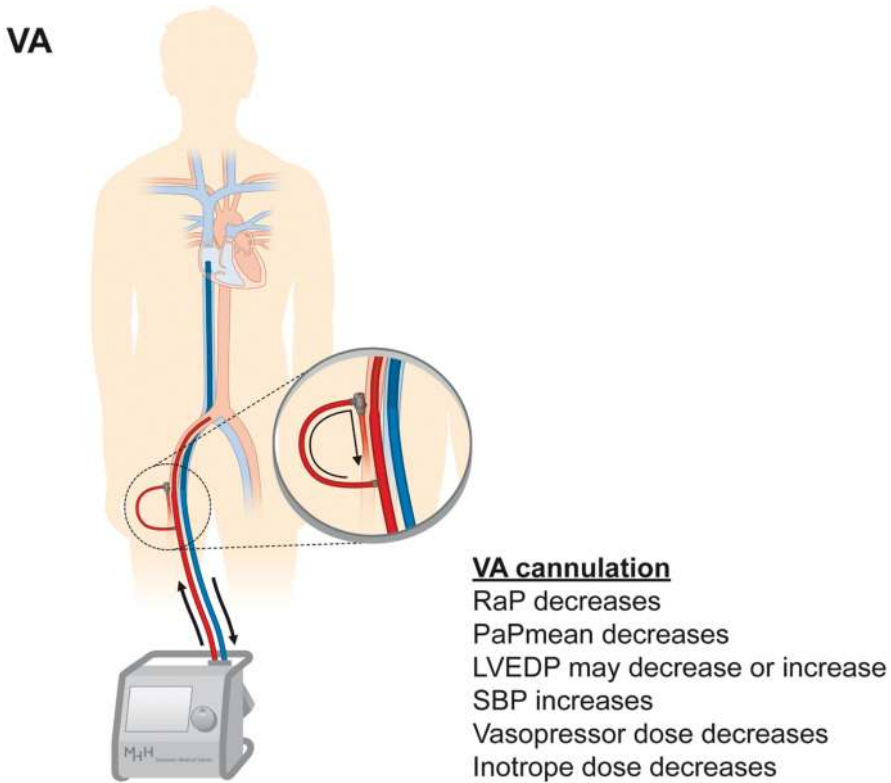
**Figure 2.** Veno-pulmonary-arterial ECMO (VPa). VPa-ECMO drains venous blood (blue) from the right atrium and returns an equal volume after reoxygenation and decarboxylation (red) to the pulmonary artery. Note the modified position of the draining venous cannula tip compared to VV-ECMO.

The main advantage of VPa cannulation is the bypass of the right ventricle, which in turn requires a competent pulmonary valve. As such, this type of cannulation may be used in patients with isolated right heart failure or with right heart failure while on VV-ECMO support. Again, it has to be noted that this type of ECMO is novel and has not been validated in clinical trials. It further requires sufficient left ventricular function, and left heart failure on VPa-ECMO may be an indication for triple cannulation (see below). In general, isolated right heart failure may also be bridged by a novel dedicated microaxial right heart assist device (Impella RP®, Abiomed) [24]. However, in contrast to VPa-ECMO, this approach provides mere hemodynamic assistance but no respiratory support by reoxygenation and decarboxylation of venous blood.

### 2.3. Veno-arterial cannulation (VA)

The second major indication for ECMO is hemodynamic support in severe heart failure, which has already been introduced to current guidelines [25]. For hemodynamic support, VA-cannulation is performed. Here blood is drained from the right atrium similar to VV-ECMO but returned to a large artery toward the aorta (**Figure 3**). This institutes an extracorporeal

right-to-left-shunt in order to reduce preload and to increase aortic blood flow for end organ perfusion (**Figure 3**). That leads to the stabilization of blood pressure in most cases, but this secondary effect depends on vascular resistance and filling. As such, vasopressor dosing and volume supplementation have to be carefully adjusted during VA-ECMO.



**Figure 3.** Veno-arterial ECMO (VA). VA-ECMO drains venous blood (blue) from the right atrium and returns an equal volume after reoxygenation and decarboxylation (red) to the iliac artery toward the aorta. Note the modified position of the draining venous cannula tip compared to VV-ECMO. Femoral arterial cannulation requires an extra sheath for antegrade perfusion of the leg (inset).

VA-ECMO has successfully been used in various conditions such as post-cardiotomy cardiogenic shock [26], shock caused by myocardial infarction [27], decompensated non-ischemic heart failure [28], fulminant myocarditis [29, 30], or pulmonary embolism prior to embolectomy [31, 32] in all of the aforementioned cases in a *bridge-to-recovery* strategy. As with VV-ECMO, VA-ECMO has successfully been used in awake patients avoiding mechanical ventilation [33]. VA-ECMO is further used in a *bridge-to-transplantation* strategy for right ventricular failure during decompensated pulmonary arterial hypertension before lung transplantation [34]. Transportable ECMO systems are available for the stabilization of



patients with cardiogenic shock in order to transfer them to a tertiary cardiovascular center [35]. While elective high-risk percutaneous coronary intervention has been successfully performed under VA-ECMO support [36], a percutaneous microaxial pump (Impella®) appears to be equally effective with lower procedural risk [37]. VA-ECMO can further be useful for preconditioning prior to implantation of a permanent left ventricular assist device (LVAD) in a *bridge-to-destination* strategy [38]. Regarding donor organ shortage, this approach will be increasingly important in the future compared to a *bridge-to-transplantation* strategy. A *bridge-to-decision* strategy [39] is followed in patients after resuscitation, with the intention to gain time, while end organ perfusion is improved until neurological outcome after resuscitation can be evaluated. The use of VA-ECMO is further beneficial during the early postoperative phase after lung transplantation, while the heart is not ready to manage reconstituted left ventricular preload [40]. As in recent years, efforts are made to improve the outcome after out-of-hospital resuscitation, and VA-ECMO will also play an important role here [41], since available outcome data suggest a benefit in this context [42, 43]. Notwithstanding the broad use of VA-ECMO, and promising results from smaller studies, large prospective studies are missing.

VA-ECMO cannulae are usually introduced via the femoral vein and artery (**Figure 3**), but the venous cannula may also drain blood via a jugular vein, especially when VV-ECMO with existing jugular access is switched to VA-ECMO. In contrast to VV-ECMO, the venous cannula tip should be placed in the mid right atrium (**Figure 3**) to enable homogenous drainage of the upper and lower body. Upper-body cannulation via the jugular vein and subclavian artery is also possible [6].

Arterial cannulation introduces several important differences to VV-ECMO, which have to be considered in both VA- and triple cannulation ECMO. One of the most important issues is the so-called watershed phenomenon, i.e., an artificial competition zone between antegrade blood flow from the heart and retrograde blood flow from the ECMO [6, 31, 44]. It is located at a region somewhere between the ascending aorta and the thoracic aorta at the diaphragm level in most cases, and varies over time [44] and between individual patients. As a result, the upper body including the brain is perfused with “heart blood” and the lower body with “ECMO blood.” Accordingly, lung failure during VA-ECMO may result in hypoxic damage to the heart and brain despite good perfusion pressure, because blood derived from the heart is incompletely saturated. This condition is a potential indication for triple cannulation ECMO (see below). Second, femoral arterial cannulation requires an additional sheath to ensure distal arterial perfusion (**Figure 3**, inset) [45], and arterial access may lead to substantial vascular complications [45]. Lastly, left ventricular distension and pulmonary congestion may emerge after the onset of VA-ECMO support, especially in cases of extremely low left ventricular output or aortic regurgitation. In such cases, triple cannulation for enhanced venous unloading can be helpful (see below) [5]. A novel promising solution to compensate for insufficient or missing antegrade flow across the aortic valve on VA-ECMO support is additional percutaneous left ventricular unloading by a microaxial pump (Impella®, Abiomed), which is described elsewhere [46–48].



The aspects described above (watershed, antegrade perfusion sheath, LV distension/pulmonary edema) have to be considered in all patients on femoral-arterial cannulation, however, do not apply to central and only in part to subclavian arterial cannulation.

### 3. Triple cannulation

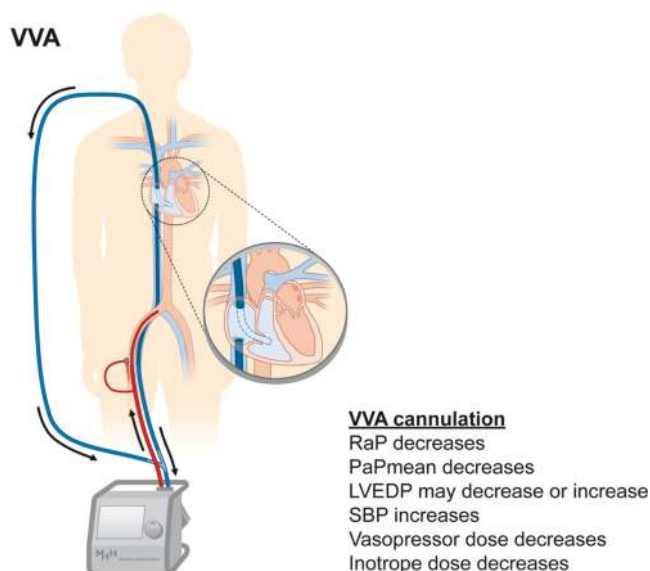
Triple cannulation ECMO is a novel and complex form of mechanical support. In most cases, it is instituted by adding a third cannula to an existing VV- or VA-ECMO circuit. The term “triple cannulation” primarily means the use of three cannulae; however, these may be used in a veno-veno-arterial (VVA) or veno-arterio-venous (VAV) mode. As VVA and VAV modes have strongly different effects on circulatory and respiratory support as well as associated ventilator and medical management, we here describe both configurations separately. In general, triple cannulation is a promising approach for selected patients, but evidence from the available literature is limited, and it should be used by experienced centers only.

#### 3.1. Veno-veno-arterial cannulation (VVA)

VVA-ECMO is a special variant of VA-ECMO, in order to improve drainage with a second venous cannula. In general, VA-ECMO intends to provide hemodynamic support and cardiac unloading during severe left-sided, right-sided, or biventricular heart failure. In this context, filling pressures, i.e., pulmonary arterial and capillary wedge pressures, serve as robust markers of VA-ECMO efficacy. However, in some patients, venous drainage is not sufficient, resulting in either reduced ECMO flow or upper body hypoxemia (also termed differential hypoxia or two-circulation syndrome) [49, 50]. This may occur by using insufficient cannula diameters or in very large patients. Then, the addition of a second draining cannula aims to improve venous drainage, resulting in triple cannulation (two for drainage and one for supply, **Figure 4**).

Unloading by standard VA-ECMO may further be insufficient in special situations, e.g., congenital heart defects or coexisting intracardiac shunts and pulmonary arterial hypertension. Then intracardiac right-to-left shunt may result in myocardial and cerebral hypoxia. A third cannula which drains blood from the right atrium or the right ventricle (**Figure 4**) is often sufficient to optimize unloading, increase upper body drainage, and reduce intracardiac shunts. Left ventricular distension during VA-ECMO represents another indication for enhanced drainage by VVA triple cannulation. Furthermore, in patients with insufficient flow through the draining cannula or hemolysis due to high flows, VVA may be helpful to enable high flows and reduce hemolysis [51, 52].

While standard VA-cannulation is often performed on the ward with post-hoc imaging to verify cannula position, the second venous draining cannula should always be placed under live imaging, such as fluoroscopy or transesophageal echocardiography. Flows from both venous cannulae are then merged with a Y-connector outside of the body to return to the ECMO unit via a single tubing (**Figure 4**). As VVA ECMO is a special form of VA-ECMO with enhanced drainage, hemodynamic consequences are comparable to VA cannulation (**Figure 4**).



**Figure 4.** Veno-veno-arterial ECMO (VVA). VVA-ECMO drains venous blood (blue) via the jugular and femoral vein from the right atrium and returns all drained blood after reoxygenation and decarboxylation (red) to the iliac artery toward the aorta. The draining flows from the two venous cannulae are merged by a Y-connector.

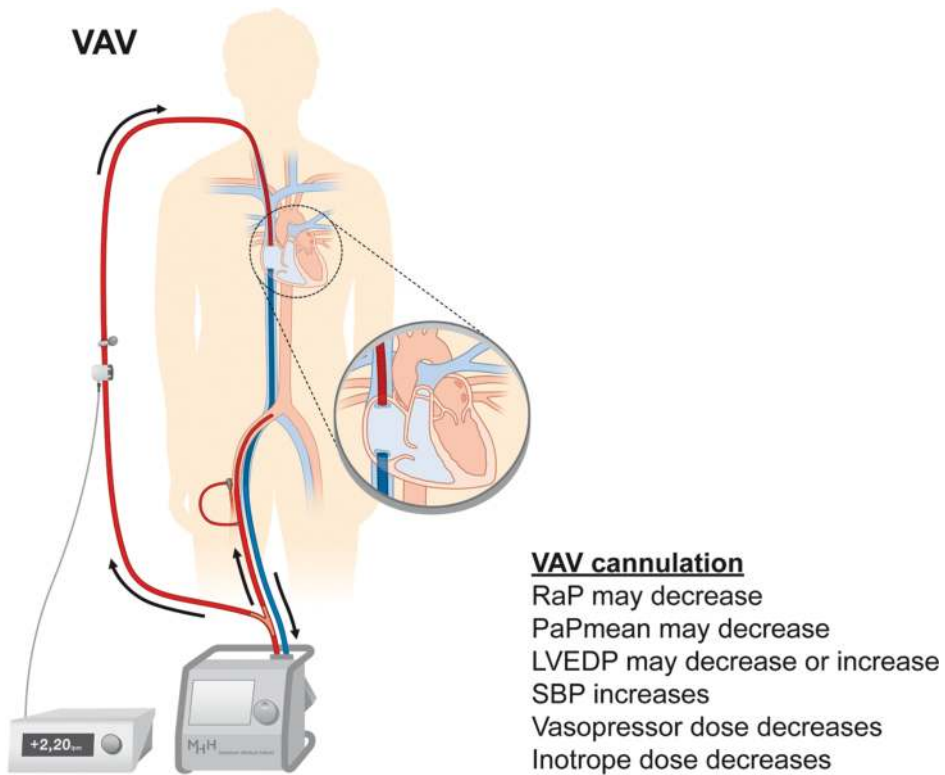
VVA-ECMO	N	Description	Outcomes
Ford and Atkinson 1992 [52]	1	Respiratory failure from congenital diaphragmal hernia in a 3000-g newborn. After 24 h, VA-ECMO performed, ECMO could be removed after support was insufficient due to limited drainage. After upgrade to VVA cannulation, central venous oxygen saturation improved, indicating improvement of drainage and subsequent supply	Surgery for repair of hernia was weaning. The child was discharged home after 31 days.
Hou et al. 2015 [50]	Sheep model	Animal study investigating the role of different locations of drainage during ECMO support. Acute respiratory failure was induced while VA-ECMO with inferior vena cava drainage was running. Severe upper body hypoxemia developed, with no significant effect on blood pressure. The venous drainage cannula was repositioned to the superior vena cava, and aortic oxygen saturation increased from 35 to 75%, by this reverting upper body hypoxemia. This proof-of-principle study demonstrates that bicaval drainage is sufficient to disrupt "two-circulation syndrome."	
ELSO [5]	Guideline	The ELSO guideline for ECMO support in adults describes the option to change VA-cannulation to VVA-cannulation for improving venous drainage	

**Table 3.** Publications on VVA ECMO support.

At present, VVA-ECMO has been used in selected cases only (**Table 3**), and robust study data do not exist.

### 3.2. Venous-arterio-venous cannulation (VAV)

This type of triple cannulation is probably one of the most promising steps forward in complex clinical situations. VAV-ECMO is used in patients with coexisting severe lung and heart failure. While the drainage cannula draws blood from the right atrium, the ECMO outflow is divided into two parts: One toward the aorta and one toward the right atrium (**Figure 5**). As such, VAV-ECMO represents a mixture of both VV- and VA-ECMO and provides hemodynamic and respiratory support at the same time. This approach is sufficient to rescue combined heart and lung failure in selected cases, such as severe left ventricular failure with secondary ARDS or right heart decompensation during ARDS.



**Figure 5.** Venous-arterio-venous ECMO (VAV). VAV-ECMO drains venous blood (blue) from the right atrium and returns balanced volumes blood after reoxygenation and decarboxylation (red) to the iliac artery toward the aorta and to the right atrium toward the pulmonary circulation. For this purpose, the ECMO outflow is divided by a Y-connector. Flow through the returning cannulae is balanced with an adjustable clamp and monitored with a separate flow sensor on the upper return cannula.

VAV-ECMO	N	Description	Outcomes
Madershahian et al. 2007 [58]	1	3 pts. with VA-ECMO for ARDS and polytrauma. In 1 pt., persistent upper body hypoxemia on VA-ECMO, conversion to VAV	Recovery, weaning from ECMO, discharge
Stöhr et al. 2011 [60]	11	30 pts. with ARDS. Of these 18 with VV, 9 with VA and 3 with primary VAV cannulation. 8 were upgraded from VV or VA to VAV, and 2 were switched from VV to VA. 11 pts. had subclavian arterial cannulation	Bleeding in 8 pts., hyperperfusion/leg ischemia/wound healing complications in 1 pt. each. 15 pts. died on ECMO, 1 pt. died after ECMO removal. Mortality was higher in the VV (63%) and the VA cohort (75%) than in the VAV cohort (27%). Overall, 30-day mortality was 53%. 1 pt. was bridged to lung transplantation. During a mean follow-up of 21 months, 3 pts. died
Kustermann et al. 2013 [53]	1	30-year-old pt. with pneumonia, ARDS, and severe septic cardiomyopathy. VA-ECMO was expanded to VAV cannulation due to persistently low Horovitz index on VA-ECMO	Recovery, weaning from ECMO and invasive ventilation
Moravec et al. 2014 [55]	143	74-year-old pt. with pulmonary hypertension and pulmonary fibrosis, pneumonia, sepsis, and shock. VA-ECMO was expanded to VAV-ECMO via a jugular Shaldon catheter for ARDS. 59-year-old obese pt. with cardiogenic shock, resuscitation during cardiac catheterization and IABP. VA-ECMO was expanded to VAV-ECMO via a jugular Shaldon catheter for ARDS. A third pt. received VAV-ECMO with standard ECMO cannulae.	Successful ECMO weaning in all patients. Pt. 1 died from lung fibrosis, shock. VA-ECMO was expanded to VAV-ECMO via a jugular Shaldon catheter for ARDS. 59-year-old obese pt. with cardiogenic shock, resuscitation during cardiac catheterization and IABP. VA-ECMO was expanded to VAV-ECMO via a jugular Shaldon catheter for ARDS. A third pt. received VAV-ECMO with standard ECMO cannulae. clinical result
Chung et al. 2014 [51]	Review	Excellent review on monitoring during ECMO support includes a description of the principle of VAV-ECMO	
Choi et al. 2014 [49]	1	39-year old pt. with acute myocardial infarction. VA-ECMO during resuscitation, after 5 days secondary respiratory failure and upper-body hypoxemia. Upgrade to VAV-ECMO	Successful ECMO and ventilator weaning, rehabilitation, uneventful recovery at 13 month follow-up
Kim et al. 2014 [57]	1	9 pts. with ECMO after resuscitation for near-drowning. 7 pts. with VA-ECMO, 1 was converted to VV. 1 pt. patient initially received VAV-ECMO	All pts. were successfully weaned from ECMO, 7 pts. survived with a favorable neurological outcome, 2 pts. had irreversible hypoxic brain damage and died. Outcome for the pt. with

VAV-ECMO	N	Description	Outcomes
			VAV-ECMO is not specifically provided.
Biscotti et al. 2014 [59]	21	21 pts. with VAV-ECMO. 11 with primary VAV, 8 with switching from VV to VAV, 1 had lung transplantation on VA-ECMO and received VAV-ECMO as a bridge to VV-ECMO. 1 had ARDS and upper body hypoxemia on VA-ECMO, which was subsequently expanded to VAV	8 pts. died on ECMO, 4 were weaned from ECMO but died before discharge, 9 survived to discharge. 4 of 11 on primary VAV-ECMO survived, 4 of 8 converted from VV to VAV survived, 1 of 2 converted from VA to VAV survived
Ius et al. 2015 [54]	10	9 pts. with VV- and 1 with VA-ECMO, for ARDS (right heart failure, pericardial tamponade or mitral regurgitation).	3 pts. were successfully bridged to lung transplantation, 2 of which survived to hospital discharge. 4 were successfully weaned off ECMO, 3 of which survived to discharge. 3 pts. died on ECMO
Lee et al. 2016 [61]	1	27-year-old pt. with ARDS from concurrent pneumonia and acute myocarditis. Primary VAV-ECMO for ARDS and cardiogenic shock	Successful ECMO and ventilator weaning, discharge
Jeon et al 2016 [62]	1	45-year old pt. with exacerbated asthma. VV-ECMO for hypoxia despite mechanical ventilation. Development of cardiogenic shock from Takotsubo syndrome, switch to VAV-ECMO, followed by reversion to VV-ECMO 3 days later	Successful ECMO and ventilator weaning, rehabilitation, discharge
ELSO [5]	Guideline	The ELSO guideline for ECMO support in adults describes to convert VA to VAV cannulation when severe respiratory failure occurs	

pt, patient, pts, patients.

**Table 4.** Publications on VAV-ECMO support.

VAV cannulation is in most cases initiated as an “upgrade” from VV or VA-ECMO, either when lung failure develops during heart failure on VA-ECMO or when heart failure develops during lung failure on VV-ECMO. In the former situation, e.g., when pulmonary edema, severe pneumonia, or ventilator-associated lung injury occur on VA-ECMO, myocardial and cerebral oxygenation may be severely compromised. This is a result from the watershed phenomenon, with cyanosis in the upper body and sufficient oxygenation in the lower body distal to the watershed. This has also been termed differential hypoxia or “two-circulation syndrome” [49, 50]. Then a third cannula can be introduced for supplying preoxygenated blood to the lungs, as such adding a VV-ECMO component to a running VA-ECMO.

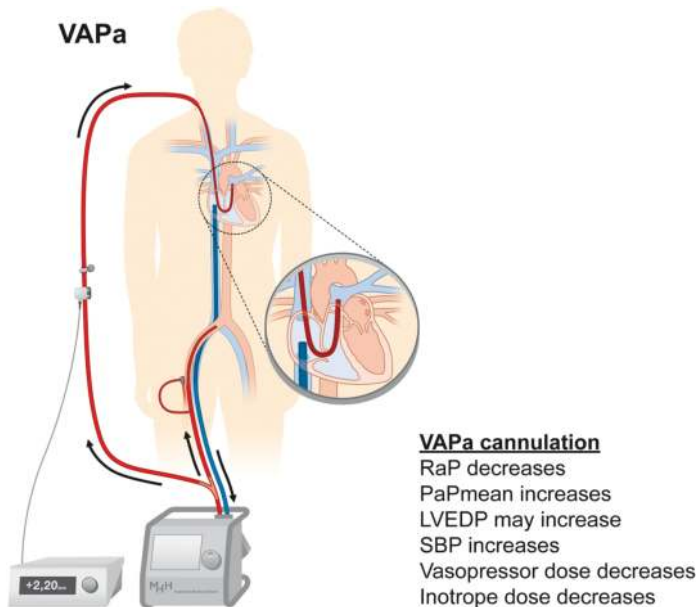
In the latter situation, preoxygenated blood enters the pulmonary circuit, since the patient is already on VV-ECMO. However, when left-sided heart failure develops, e.g., by septic cardiomyopathy or myocarditis, insufficient cardiac output will emerge as a major problem irrespective of good oxygenation of venous blood [53, 54]. In this case, a third cannula can be introduced to supply blood toward the aorta, with the intention to add a VA-ECMO component to the running VV-ECMO. Until now, some case series and small observational studies have demonstrated that VAV-ECMO may be used with well acceptable safety and convincing efficacy [49, 53–62] (**Table 4**); however, prospective or controlled data are still missing.

For VAV cannulation, usually the right jugular vein and the femoral vein and artery are used as vascular access. The venous cannula tips should be positioned at the border between the caval veins and the right atrium, comparable to VV-ECMO (**Figures 5** and **1**). VV-ECMO running with a bicaval dual-lumen cannula may also be upgraded to VAV cannulation, with the drainage lumen being connected to ECMO input and the return lumen to ECMO output. In principle, ECMO outflow is divided using a Y-connector, for one cannula returning blood toward the central aorta and one returning blood toward the right atrium (**Figure 5**). The flow in both cannulae, which of course also depends on cannula diameters, is balanced by using an adjustable clamp and monitored by a flow sensor (**Figure 5**). This is necessary, since the demand of arterialized blood flow on each return cannula varies from patient to patient and over time. Every change in flow balance will have an influence on preload, afterload, the watershed position, and oxygen saturations at the same time. Modifications of oxygenator and sweep gas settings will also influence oxygen saturation and carbon dioxide content in both reinfusion cannulae at the same time. Therefore, during VAV-ECMO support, repetitive echocardiography and continuous upper- and lower-body oxygenation surveillance are mandatory to assess right and left ventricular filling and function, respectively as well as tissue oxygenation. Respiratory support by VAV-cannulation is sufficient in most cases as it allows for lung protective ventilation, but hemodynamic support is lower compared to VA or VVA cannulation [54].

### 3.3. Venio-arterio-pulmonary-arterial cannulation (VAPa)

This is a special variant of VAV cannulation. It has not been validated in studies and is just described here for the purpose of completeness. While VAV-ECMO combines the features of VV and VA ECMO, VAPa ECMO intends to further support right heart failure during VAV-ECMO. For this purpose, the returning venous cannula is forwarded through the tricuspid valve, the right ventricle, and the pulmonary valve to the pulmonary artery (**Figure 6**). This has to be performed under angiographic (or transesophageal echocardiographic) guidance, and for this purpose a flexible 17 French cannula has to be used, as for VP<sub>a</sub> cannulation. The smaller inner diameter of that cannula intrinsically influences the flow balance of both return cannulae, which is further adjusted by a clamp and monitored by a flow sensor as with VAV-ECMO. Similar to VA and VP<sub>a</sub> cannulation, the draining cannula tip should be positioned in the mid right atrium to facilitate homogenous drainage of the upper and lower body.

By VAPa-ECMO, the right heart is bypassed, and as such right-sided heart failure on VAV-ECMO or left-sided heart failure on VPa-ECMO can be bridged but requires a competent pulmonary valve. Again, it has to be noted that this type of ECMO is novel, as such experimental and has not been validated in clinical trials. An existing transfemoral venous ECMO cannulation does not allow for additional implantation of a microaxial right heart-assist device (Impella RP®, Abiomed). Thus, the combination of VA-ECMO and Impella RP® is not an option, and in contrast to VPa-ECMO, this approach would not offer oxygenation and decarboxylation of pulmonary blood.



**Figure 6.** Venio-arterio-pulmonary arterial ECMO (VAPa). VAPa-ECMO drains venous blood (blue) from the right atrium and returns balanced volumes blood after reoxygenation and decarboxylation (red) to the iliac artery toward the aorta and to the pulmonary artery. For this purpose, the ECMO outflow is divided by a Y-connector. Flow through the returning cannulae is balanced with an adjustable clamp and monitored with a separate flow sensor on the upper return cannula.

#### 4. Summary

VV and VA cannulation are the most common configurations of percutaneous ECMO support, serving to bridge severe respiratory and cardiac failure, respectively. VPa cannulation is a novel modification of VV ECMO to support respiratory failure complicated by right heart failure. Recently, triple cannulation ECMO has been introduced, either VVA cannulation for improved drainage or VAV cannulation for combined lung and heart failure. VAV may further



be modified to VAPa cannulation, mainly for severe right heart failure during VAV-ECMO. Novel and triple cannulations expand the spectrum of ECMO in special clinical situations; however, such configurations are even more complex than standard ECMO and require most intense monitoring and awareness. Notwithstanding these promising developments, we need prospective controlled trials of standard and advanced ECMO configurations to unequivocally assess safety and efficacy and to identify predictors of initiation and weaning of mechanical support.

**Conflict of interest** LCN and JB report no conflicts of interest related to this work.

## Author details

L. Christian Napp\* and Johann Bauersachs

\*Address all correspondence to: [napp.christian@mh-hannover.de](mailto:napp.christian@mh-hannover.de)

Cardiac Arrest Center, Department of Cardiology and Angiology, Hannover Medical School, Hannover, Germany

## References

- [1] Hill JD, O'Brien TG, Murray JJ, Dontigny L, Bramson ML, Osborn JJ, et al. Prolonged extracorporeal oxygenation for acute post-traumatic respiratory failure (shock-lung syndrome). Use of the Bramson membrane lung. *N Engl J Med.* 1972;286(12):629–34.
- [2] Thiele H, Zeymer U, Neumann FJ, Ferenc M, Olbrich HG, Hausleiter J, et al. Intraaortic balloon support for myocardial infarction with cardiogenic shock. *N Engl J Med.* 2012;367(14):1287–96.
- [3] Zeymer U, Hochadel M, Hauptmann KE, Wiegand K, Schuhmacher B, Brachmann J, et al. Intra-aortic balloon pump in patients with acute myocardial infarction complicated by cardiogenic shock: results of the ALKK-PCI registry. *Clinical Res Cardiol.* 2013;102(3):223–7.
- [4] Zangrillo A, Landoni G, Biondi-Zoccai G, Greco M, Greco T, Frati G, et al. A meta-analysis of complications and mortality of extracorporeal membrane oxygenation. *Crit Care Resusc.* 2013;15(3):172–8.
- [5] Extracorporeal Life Support Organization: ELSO guidelines. Available from: <http://www.elseo.org/resources/guidelines>. Access Date: 27.08.2014.
- [6] Napp LC, Kühn C, Hoepfer MM, Vogel-Claussen J, Haverich A, Schäfer A, Bauersachs J. Cannulation strategies for percutaneous extracorporeal membrane oxygenation in adults. *Clin Res Cardiol.* 2016 Apr;105(4):283–96.

- [7] Werdan K, Gielen S, Ebelt H, Hochman JS. Mechanical circulatory support in cardiogenic shock. *Eur Heart J*. 2014;35(3):156–67.
- [8] Ferrari M, Kruzliak P, Spiliopoulos K. An insight into short- and long-term mechanical circulatory support systems. *Clin Res Cardiol*. 2015;104(2):95–111.
- [9] Brodie D, Bacchetta M. Extracorporeal membrane oxygenation for ARDS in adults. *N Engl J Med*. 2011;365(20):1905–14.
- [10] Morris AH, Wallace CJ, Menlove RL, Clemmer TP, Orme JF, Jr., Weaver LK, et al. Randomized clinical trial of pressure-controlled inverse ratio ventilation and extracorporeal CO<sub>2</sub> removal for adult respiratory distress syndrome. *Am J Respir Crit Care Med*. 1994;149(2 Pt 1):295–305.
- [11] Peek GJ, Mugford M, Tiruvoipati R, Wilson A, Allen E, Thalanany MM, et al. Efficacy and economic assessment of conventional ventilatory support versus extracorporeal membrane oxygenation for severe adult respiratory failure (CESAR): a multicentre randomised controlled trial. *Lancet*. 2009;374(9698):1351–63.
- [12] Sidebotham D. Extracorporeal membrane oxygenation—understanding the evidence: CESAR and beyond. *J Extra-corpor Technol*. 2011;43(1):P23–6.
- [13] Zapol WM, Snider MT, Hill JD, Fallat RJ, Bartlett RH, Edmunds LH, et al. Extracorporeal membrane oxygenation in severe acute respiratory failure. A randomized prospective study. *JAMA*. 1979;242(20):2193–6.
- [14] Brogan TV, Thiagarajan RR, Rycus PT, Bartlett RH, Bratton SL. Extracorporeal membrane oxygenation in adults with severe respiratory failure: a multi-center database. *Intensiv Care Med*. 2009;35(12):2105–14.
- [15] Fuehner T, Kuehn C, Hadem J, Wiesner O, Gottlieb J, Tudorache I, et al. Extracorporeal membrane oxygenation in awake patients as bridge to lung transplantation. *Am J Respir Crit Care Med*. 2012;185(7):763–8.
- [16] Wiesner O, Hadem J, Sommer W, Kuhn C, Welte T, Hoeper MM. Extracorporeal membrane oxygenation in a nonintubated patient with acute respiratory distress syndrome. *Eur Respir J*. 2012;40(5):1296–8.
- [17] Schmidt F, Sasse M, Boehne M, Mueller C, Bertram H, Kuehn C, et al. Concept of “awake venovenous extracorporeal membrane oxygenation” in pediatric patients awaiting lung transplantation. *Pediatr Transplant*. 2013;17(3):224–30.
- [18] Hoeper MM, Wiesner O, Hadem J, Wahl O, Suhling H, Duesberg C, et al. Extracorporeal membrane oxygenation instead of invasive mechanical ventilation in patients with acute respiratory distress syndrome. *Intensiv Care Med*. 2013;39(11):2056–7.
- [19] Pham T, Combes A, Roze H, Chevret S, Mercat A, Roch A, et al. Extracorporeal membrane oxygenation for pandemic influenza A(H1N1)-induced acute respiratory

- distress syndrome: a cohort study and propensity-matched analysis. *Am J Respir Crit Care Med.* 2013;187(3):276–85.
- [20] Australia, New Zealand Extracorporeal Membrane Oxygenation Influenza I, Davies A, Jones D, Bailey M, Beca J, et al. Extracorporeal membrane oxygenation for 2009 influenza A(H1N1) acute respiratory distress syndrome. *JAMA.* 2009;302(17):1888–95.
- [21] Kumar A, Zarychanski R, Pinto R, Cook DJ, Marshall J, Lacroix J, et al. Critically ill patients with 2009 influenza A(H1N1) infection in Canada. *JAMA.* 2009;302(17):1872–9.
- [22] Beutel G, Wiesner O, Eder M, Hafer C, Schneider AS, Kielstein JT, et al. Virus-associated hemophagocytic syndrome as a major contributor to death in patients with 2009 influenza A (H1N1) infection. *Crit Care.* 2011;15(2):R80.
- [23] Bermudez CA, Rocha RV, Sappington PL, Toyoda Y, Murray HN, Boujoukos AJ. Initial experience with single cannulation for venovenous extracorporeal oxygenation in adults. *Ann Thorac Surg.* 2010;90(3):991–5.
- [24] Anderson MB, Goldstein J, Milano C, Morris LD, Kormos RL, Bhamra J, et al. Benefits of a novel percutaneous ventricular assist device for right heart failure: the prospective RECOVER RIGHT study of the Impella RP device. *J Heart Lung Transplant.* 2015;34(12):1549–60.
- [25] McMurray JJ, Adamopoulos S, Anker SD, Auricchio A, Bohm M, Dickstein K, et al. ESC guidelines for the diagnosis and treatment of acute and chronic heart failure 2012: the task force for the diagnosis and treatment of acute and chronic heart failure 2012 of the European Society of Cardiology. Developed in collaboration with the Heart Failure Association (HFA) of the ESC. *Eur Heart J.* 2012;33(14):1787–847.
- [26] Maxwell BG, Powers AJ, Sheikh AY, Lee PH, Lobato RL, Wong JK. Resource use trends in extracorporeal membrane oxygenation in adults: an analysis of the Nationwide Inpatient Sample 1998–2009. *J Thorac Cardiovasc Surg.* 2014;148(2):416–21 e1.
- [27] Sheu JJ, Tsai TH, Lee FY, Fang HY, Sun CK, Leu S, et al. Early extracorporeal membrane oxygenator-assisted primary percutaneous coronary intervention improved 30-day clinical outcomes in patients with ST-segment elevation myocardial infarction complicated with profound cardiogenic shock. *Crit Care Med.* 2010;38(9):1810–7.
- [28] Guenther S, Theiss HD, Fischer M, Sattler S, Peterss S, Born F, et al. Percutaneous extracorporeal life support for patients in therapy refractory cardiogenic shock: initial results of an interdisciplinary team. *Interact Cardiovasc Thorac Surg.* 2014;18(3):283–91.
- [29] Asaumi Y, Yasuda S, Morii I, Kakuchi H, Otsuka Y, Kawamura A, et al. Favourable clinical outcome in patients with cardiogenic shock due to fulminant myocarditis supported by percutaneous extracorporeal membrane oxygenation. *Eur Heart J.* 2005;26(20):2185–92.

- [30] Lorusso R, Centofanti P, Gelsomino S, Barili F, Di Mauro M, Orlando P, et al. Venoarterial extracorporeal membrane oxygenation for acute fulminant myocarditis in adult patients: a 5-year multi-institutional experience. *Ann Thorac Surg*. 2016;101(3):919–26.
- [31] Hoeper MM, Tudorache I, Kuhn C, Marsch G, Hartung D, Wiesner O, et al. Extracorporeal membrane oxygenation watershed. *Circulation*. 2014;130(10):864–5.
- [32] Belohlavek J, Rohn V, Jansa P, Tosovsky J, Kunstyr J, Semrad M, et al. Veno-arterial ECMO in severe acute right ventricular failure with pulmonary obstructive hemodynamic pattern. *J Invasive Cardiol*. 2010;22(8):365–9.
- [33] Sommer W, Marsch G, Kaufeld T, Rontgen P, Beutel G, Tongers J, et al. Cardiac awake extracorporeal life support-bridge to decision? *Artif Organs*. 2015;39(5):400–8.
- [34] Olsson KM, Simon A, Strueber M, Hadem J, Wiesner O, Gottlieb J, et al. Extracorporeal membrane oxygenation in nonintubated patients as bridge to lung transplantation. *Am J Transplant*. 2010;10(9):2173–8.
- [35] Javidfar J, Brodie D, Takayama H, Mongero L, Zwischenberger J, Sonett J, et al. Safe transport of critically ill adult patients on extracorporeal membrane oxygenation support to a regional extracorporeal membrane oxygenation center. *ASAIO J*. 2011;57(5):421–5.
- [36] Spina R, Forrest AP, Adams MR, Wilson MK, Ng MK, Vallely MP. Veno-arterial extracorporeal membrane oxygenation for high-risk cardiac catheterisation procedures. *Heart Lung Circ*. 2010;19(12):736–41.
- [37] Iliodromitis KE, Kahlert P, Plicht B, Hoffmann AC, Eggebrecht H, Erbel R, et al. High-risk PCI in acute coronary syndromes with Impella LP 2.5 device support. *Int J Cardiol*. 2011;153(1):59–63.
- [38] Haneya A, Philipp A, Puehler T, Ried M, Hilker M, Zink W, et al. Ventricular assist device implantation in patients on percutaneous extracorporeal life support without switching to conventional cardiopulmonary bypass system. *Eur J Cardio-thorac Surg*. 2012;41(6):1366–70.
- [39] Rouse N, Juthier F, Pincon C, Hysi I, Banfi C, Robin E, et al. ECMO as a bridge to decision: recovery, VAD, or heart transplantation? *Int J Cardiol*. 2015;187:620–7.
- [40] Tudorache I, Sommer W, Kuhn C, Wiesner O, Hadem J, Fuhner T, et al. Lung transplantation for severe pulmonary hypertension—awake extracorporeal membrane oxygenation for postoperative left ventricular remodelling. *Transplantation*. 2015;99(2):451–8.
- [41] Jaski BE, Ortiz B, Alla KR, Smith SC, Jr., Glaser D, Walsh C, et al. A 20-year experience with urgent percutaneous cardiopulmonary bypass for salvage of potential survivors of refractory cardiovascular collapse. *J Thorac Cardiovasc Surg*. 2010;139(3):753–7 e1–2.

- [42] Jung C, Janssen K, Kaluza M, Fuernau G, Poerner TC, Fritzenwanger M, Pfeifer R, Thiele H, Figulla HR. Outcome predictors in cardiopulmonary resuscitation facilitated by extracorporeal membrane oxygenation. *Clin Res Cardiol*. 2016 Mar;105(3):196-205.
- [43] Kagawa E, Dote K, Kato M, Sasaki S, Nakano Y, Kajikawa M, et al. Should we emergently revascularize occluded coronaries for cardiac arrest? Rapid-response extracorporeal membrane oxygenation and intra-arrest percutaneous coronary intervention. *Circulation*. 2012;126(13):1605-13.
- [44] Napp LC, Brehm M, Kuhn C, Schafer A, Bauersachs J. Heart against veno-arterial ECMO: competition visualized. *Int J Cardiol*. 2015;187:164-5.
- [45] Bisdas T, Beutel G, Warnecke G, Hoepfer MM, Kuehn C, Haverich A, et al. Vascular complications in patients undergoing femoral cannulation for extracorporeal membrane oxygenation support. *Ann Thorac Surg*. 2011;92(2):626-31.
- [46] Cheng A, Swartz MF, Massey HT. Impella to unload the left ventricle during peripheral extracorporeal membrane oxygenation. *ASAIO J*. 2013;59(5):533-6.
- [47] Chaparro SV, Badheka A, Marzouka GR, Tanawuttiwat T, Ahmed F, Sacher V, et al. Combined use of Impella left ventricular assist device and extracorporeal membrane oxygenation as a bridge to recovery in fulminant myocarditis. *ASAIO J*. 2012;58(3):285-7.
- [48] Koeckert MS, Jorde UP, Naka Y, Moses JW, Takayama H. Impella LP 2.5 for left ventricular unloading during venoarterial extracorporeal membrane oxygenation support. *J Card Surg*. 2011;26(6):666-8.
- [49] Choi JH, Kim SW, Kim YU, Kim SY, Kim KS, Joo SJ, et al. Application of veno-arterial-venous extracorporeal membrane oxygenation in differential hypoxia. *Multidisciplin Respir Med*. 2014;9(1):55.
- [50] Hou X, Yang X, Du Z, Xing J, Li H, Jiang C, et al. Superior vena cava drainage improves upper body oxygenation during veno-arterial extracorporeal membrane oxygenation in sheep. *Crit Care*. 2015;19:68.
- [51] Chung M, Shiloh AL, Carlese A. Monitoring of the adult patient on venoarterial extracorporeal membrane oxygenation. *Sci World Jour*. 2014;2014:393258.
- [52] Ford EG, Atkinson JB. Augmented venous access in the problematic ECMO patient: a case report. *J Pediatr Surg*. 1992;27(4):527-8.
- [53] Kustermann J, Gehrman A, Kredel M, Wurmb T, Roewer N, Muellenbach RM. [Acute respiratory distress syndrome and septic cardiomyopathy: successful application of veno-venoarterial extracorporeal membrane oxygenation]. *Der Anaesthesist*. 2013;62(8):639-43.
- [54] Ius F, Sommer W, Tudorache I, Avsar M, Siemeni T, Salman J, et al. Veno-veno-arterial extracorporeal membrane oxygenation for respiratory failure with severe haemody-

- namic impairment: technique and early outcomes. *Interact Cardiovasc Thorac Surg.* 2015;20(6):761–7.
- [55] Moravec R, Neitzel T, Stiller M, Hofmann B, Metz D, Bucher M, et al. First experiences with a combined usage of veno-arterial and veno-venous ECMO in therapy-refractory cardiogenic shock patients with cerebral hypoxemia. *Perfusion.* 2014;29(3):200–9.
- [56] Chung JC, Tsai PR, Chou NK, Chi NH, Wang SS, Ko WJ. Extracorporeal membrane oxygenation bridge to adult heart transplantation. *Clin Transplant.* 2010;24(3):375–80.
- [57] Kim KI, Lee WY, Kim HS, Jeong JH, Ko HH. Extracorporeal membrane oxygenation in near-drowning patients with cardiac or pulmonary failure. *Scand J Trauma Resusc Emerg Med.* 2014;22:77.
- [58] Madershahian N, Wittwer T, Strauch J, Franke UF, Wippermann J, Kaluza M, et al. Application of ECMO in multitrauma patients with ARDS as rescue therapy. *J Card Surg.* 2007;22(3):180–4.
- [59] Biscotti M, Lee A, Basner RC, Agerstrand C, Abrams D, Brodie D, et al. Hybrid configurations via percutaneous access for extracorporeal membrane oxygenation: a single-center experience. *ASAIO J.* 2014;60(6):635–42.
- [60] Stohr F, Emmert MY, Lachat ML, Stocker R, Maggiorini M, Falk V, et al. Extracorporeal membrane oxygenation for acute respiratory distress syndrome: is the configuration mode an important predictor for the outcome? *Interact Cardiovasc Thorac Surg.* 2011;12(5):676–80.
- [61] Lee JH, Park JH, Min HK, Seo GW, Song PS, Her C, et al. Veno-veno-arterial ECMO support for acute myocarditis combined with ARDS: a case report. *Int J Artif Organs.* 2016;38(12):667–70.
- [62] Jeon YJ, Byun JH, Hwang SW, Park JH, Lee JH. Successful application of veno-venoarterial extracorporeal membrane oxygenation for acute exacerbation of asthma followed by stress cardiomyopathy. *Yonsei Med J.* 2016;57(2):536–7.

