

---

# Total Hip Replacement in Developmental Dysplasia

---

Maximilian F. Kasparek and Friedrich Boettner

Additional information is available at the end of the chapter

<http://dx.doi.org/10.5772/67480>

---

## Abstract

Total hip arthroplasty (THA) for osteoarthritis secondary to development dysplasia of the hip (DDH) is facing increasing levels of complexity with increasing grade of deformity. The dysplastic acetabulum is characterized by diminished bone stock with decreased lateral coverage. Therefore, it is challenging to restore the anatomic center of rotation and ensure adequate acetabular component fixation. Surgical strategies include a medialization of the acetabular component, a higher hip center, lateral structural bone grafting and the selection of smaller component sizes to improve native bone coverage. Excessive femoral anteversion is commonly encountered in patients with developmental dysplasia. Moreover, the intramedullary canal is narrow and the neck often aligned in valgus. Modular implants are helpful to address the altered femoral anatomy and also facilitate femoral shortening osteotomies in patients with high hip dislocation. Although clinical results are comparable to primary total hip replacement in primary osteoarthritis, the risk for revision surgery due to dislocation and loosening is increased. The current chapter reviews classification, preoperative planning, and surgical strategies for patients undergoing THA for osteoarthritis secondary to developmental dysplasia.

**Keywords:** developmental dysplasia, secondary osteoarthritis, primary total hip arthroplasty, bone grafting, femoral shortening osteotomy, complication

---

## 1. Introduction

Development dysplasia of the hip (DDH) is a common reason for primary total hip arthroplasty (THA) in young female adults. Surgical treatment is complicated by subluxation or dislocation of the femoral head out of the dysplastic acetabulum [1]. Complications occur more frequently due to the increased surgical complexity compared to THA in primary osteoarthritis. Understanding the underlying anatomical abnormalities in patients with DDH

---

is of paramount importance for successful surgical treatment. The complexity is related to a dysplastic acetabulum with decreased lateral bone stock and coverage. Femoral anteversion is common especially in patients with lower levels of dysplasia [2]. In addition, most patients have a valgus neck alignment and a narrow medullary canal [3, 4].

## 2. Classification

The etiology of DDH is multifactorial and DDH is associated with positive family history and female gender [5]. Classification systems are based on the amount of displacement of the femoral head in relationship to the teardrop and predict the complexity of surgery. With increasing grade of deformity the acetabular bone stock is diminished. The most commonly used classification system was described by Crowe et al. [6] and Hartofilakidis et al. [7].

### 2.1. Crowe classification

Crowe et al. [6] classified DDH based on the grade of proximal subluxation of the femoral head (**Table 1**). The subluxation is calculated on anterior-posterior radiographs by measuring the proximal subluxation distance between the inter-teardrop line and the transition point of the femoral head to the femoral neck (**Figures 1** and **2**). The grade of subluxation is defined as the proximal subluxation in relation to the undeformed femoral head diameter.

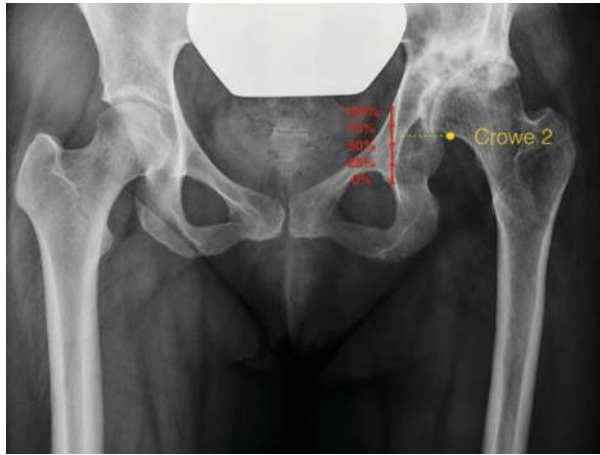In Crowe grade I, the proximal subluxation of the transition point is under <50% of the vertical femoral head diameter and in Crowe grade II between 50 and 74%. In grade III, proximal migration is about 75–100% and in grade IV more than 100% (**Table 1**).

If the femoral head is deformed, the vertical diameter of the femoral head is calculated as 20% of the height of the pelvis (distance between the iliac crest and the inferior margin of the ischial tuberosity).

The Crowe classification predicts the complexity of surgery and with increasing Crowe grade complications are more common [8]. Furthermore, it was reported that the Crowe classification correlates with grade of acetabular and femoral anteversion [2].

Grade	Crowe classification	Acetabular anteversion	Femoral anteversion
I	<50% subluxation	15°	42°
II	50–74% subluxation	10°	30°
III	75–100% subluxation	7°	43°
IV	>100% subluxation	4°	27°

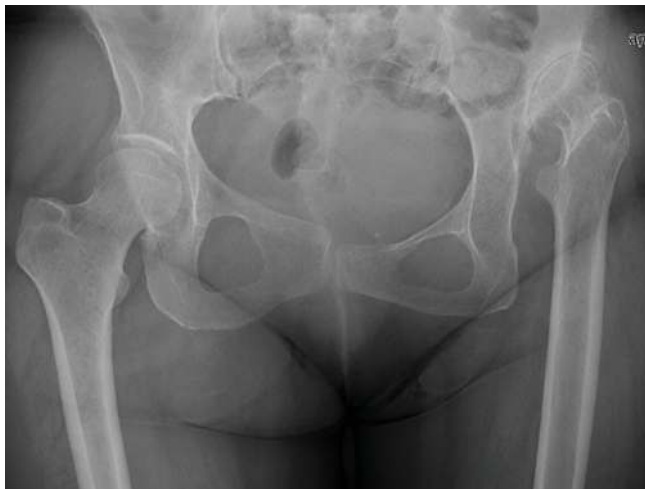**Table 1.** Crowe classification and relationship with acetabular and femoral anteversion [2, 6].



**Figure 1.** On the radiographs a Crowe grade II deformity is shown (50–74% subluxation). The subluxation is calculated by measuring the proximal migration between the teardrop line and the transition point of femoral head-neck.

## 2.2. Hartofilakidis classification

Hartofilakidis et al. [7] classified dysplastic hips in three overall categories based on radiographic appearance of the hip: in Type A the femoral head is articulating with the true acetabulum; in Type B the femoral head articulate with a false acetabulum and the false and true acetabulum are still connected; finally in a Type C the femoral head has migrated further proximal (**Table 2**) and therefore true and actual acetabulum are separated. This classification



**Figure 2.** Radiograph of a Crowe grade IV deformity.

<b>Hartofilakidis</b>		<b>Acetabular deficiency</b>
Type A	The femoral head is contained within the original acetabulum despite some degree of subluxation	<ol style="list-style-type: none"> <li>1. Superior segmental deficiency</li> <li>2. Secondary shallowing due to fossa-covering osteophyte</li> </ol>
Type B	The femoral head articulates with a false acetabulum that partially covers the true acetabulum	<ol style="list-style-type: none"> <li>1. Anterior and posterior segmental deficiency</li> <li>2. Narrow opening</li> <li>3. Inadequate depth</li> <li>4. Increased anteversion</li> </ol>
Type C	With high dislocation, the femoral head has migrated superiorly and posteriorly. The true acetabulum is inferior and anterior to the false acetabulum along the iliac wing	<ol style="list-style-type: none"> <li>1. Segmental deficiency of the entire acetabular rim</li> <li>2. Narrow opening</li> <li>3. Inadequate depth</li> <li>4. Excessive anteversion</li> <li>5. Abnormal distribution of bone stock, mainly superoposteriorly</li> </ol>

**Table 2.** Hartofilakidis classification [7].

system describes the anatomical deformity and predicts the complexity of acetabular reconstruction.

### 3. Preoperative planning

Standardized radiographs including calibrated anterior-posterior (AP) pelvis radiographs at the level of the anterior superior iliac spine and lateral hip views are required for templating. Standard AP pelvis radiographs including the iliac crest are necessary to grade the DDH using the Crowe classification. Computer tomography is useful for determining: (1) acetabular component position and bone stock, (2) the amount of femoral anteversion, and (3) the size of the femoral canal in order to determine if standard implants are feasible. Preoperative planning should incorporate planning of the center of rotation before and after surgery as well as the need for femoral shortening osteotomies. This is essential to restore adequate leg lengths. In addition, overall amount of lengthening should be determined to anticipate the risk of sciatic nerve palsy. Adequate sizing of the femoral canal is important in patients at risk for a shortening osteotomy (Crowe type 3 and 4) to assure adequate distal press fit.

### 4. Surgical approaches

Surgeons should use the surgical approach they are most comfortable with. Standard surgical approaches include the direct anterior, anterolateral, direct lateral, and posterior

approach. Advantages of the lateral and posterior approaches are a good view of the acetabulum. The posterior approach also facilitates the access to the femur for shortening osteotomies. While the posterior approach has advantages for patients with more deficient lateral bone stock and high hip dislocations, the direct anterior approach facilitates acetabular component reaming and placement due to intraoperative C-Arm imaging [9]. In addition, operating in a supine position facilitates restoration of leg length. Moreover, in cases with prior periacetabular osteotomies the surgeon can often utilize the same incision [10].

In patients with severe DDH that require shortening osteotomy, it is advantageous to start with femoral preparation since the shortening osteotomy itself often greatly facilitates acetabular exposure. Occasionally, a sliding trochanteric osteotomy can be required to improve abductor muscle tension [11]. Also the posterior capsule and external rotators should be preserved and repaired to reduce the risk of postoperative dislocation [12]. Postoperative weight bearing status is influenced by the type of surgical reconstruction and implant rather than the surgical approach. More advanced postoperative precautions are usually applied to patients undergoing a posterior and direct lateral approach.

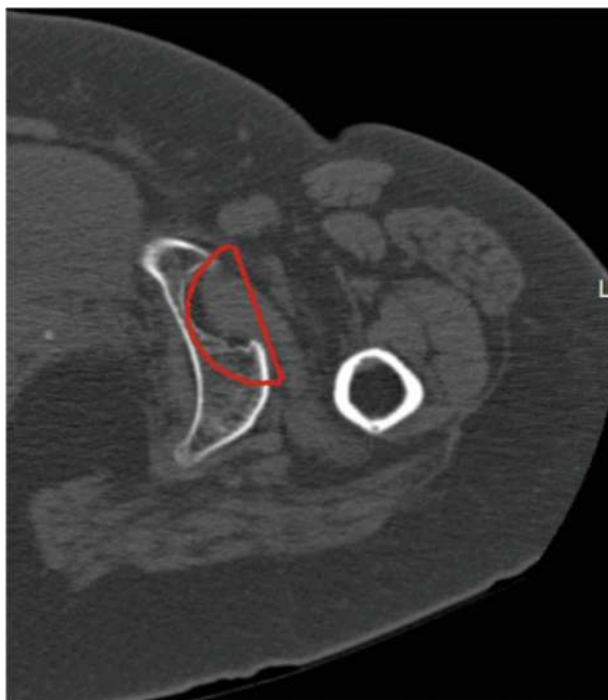
## 5. Acetabular component implantation

In DDH, the acetabulum is often shallow and oval. This results in altered anatomic landmarks and it can be challenging to identify the true acetabulum. Identifying the teardrop (junction of the ischium and pubis) either clinically or using intraoperative fluoroscopy is of absolute importance to locate the true acetabulum [13].

Finding the balance between restoration of the center of rotation and adequate lateral bone coverage requires careful preoperative templating and surgical experience. Lateral coverage can be improved by medialization of the cup and decreasing its size to improve coverage in case of lateral bone deficiency.

In most cases the center of rotation is slightly elevated to improve lateral coverage. This does impact on postoperative leg length and needs to be carefully considered when restoring postoperative leg lengths. Finding the right compromise is also important to avoid a high hip center that can affect postoperative function [1, 14, 15]. In addition, a high hip center increases the forces on the acetabulum and can increase the risk for cup loosening [16, 17]. Therefore, in general it is recommended to restore the center of rotation within 15 mm of the center of the true acetabulum or <35 mm superior to the interteardrop line [18].

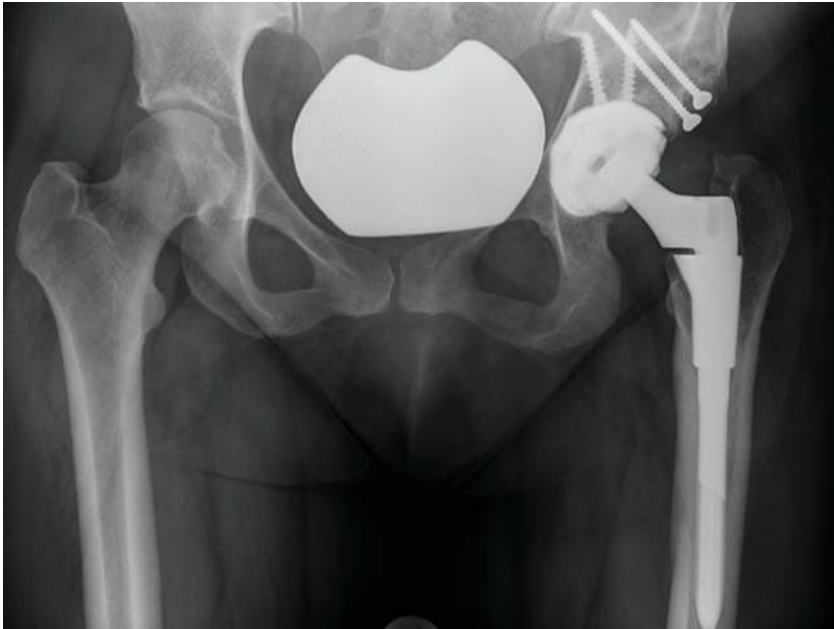A modern porous coated spherical cup, including smaller sizes (40–46 mm) should be available with maximal head size to improve stability. During acetabular reaming, the anterior wall should be protected, as it is often very thin and most of the bone stock is available posterior (**Figure 3**). Therefore, the authors recommend to ream preferentially



**Figure 3.** Computer tomography reveals that in the posterior part of the acetabulum there is more bone stock available. Reaming should be done more posteriorly to protect the anterior wall of the acetabulum.

posterior. While medialization is important, care should be taken to avoid over medialization with loss of medial bone fixation. The authors prefer reaching the inner table without penetrating it completely. Whenever the cup extends medially beyond Kohler's line medial bone grafting with graft from the reamer can help later restoration of the medial wall.

Lack of lateral coverage up to 17 mm of uncovered implant arc is acceptable for all implant sizes [19]. For larger acetabular components (52 and up) with less than 45 degree of cup inclination up to 25 mm of the cup can remain uncovered. If preoperative templating suggests that a larger area of the cup is not covered by bone than lateral bone grafting, utilizing the femoral head fixed with two screws (Harris plastic) is recommended [20] (**Figure 4**). Good long-term results with incorporation of the graft were reported for this technique [21, 22]. Metal augments can alternatively be utilized to improve lateral fixation [23], however, the authors prefer a biological restoration of bone stock using the Harris plastic. To facilitate the graft fixation and reaming, it is usually advised to make the decision to proceed with bone grafting early during the acetabular reaming. Modern robotic cup implantation using the Mako® system (Stryker, Kalamazoo, MI) allows for perfect reaming of the acetabulum



**Figure 4.** Postoperative radiographs after restoration of a Crowe grade III deformity. The anatomical hip center is restored with a femoral bone graft (Harris plastic).

according to the preoperative plan and is an appealing treatment option for patients undergoing THA for DDH.

### **5.1. Crowe classification: how it impacts acetabular fixation**

In Crowe grade 1 deformities acetabular component fixation is often not too difficult, because in most cases adequate bone stock is available. Therefore, good implant-bone coverage can be achieved almost always without bone grafting or excessive medialization.

Crowe grade II and III deformities are the most difficult defects to restore. In these deformities the femoral head is more subluxated, and significant parts of the lateral bone stock are missing. However, while most Crowe 2 and 3 can be managed similar to grade I by placing the cup proximal-medial and by using a smaller cup size, occasionally a Harris plastic is indicated.

Crowe grade IV deformities are easier to manage because the femoral head was dislocated from the acetabulum without continuous pressure on the lateral bone stock. In most cases the hip center can be restored with a smaller acetabular component in anatomic position. In these cases care should be taken not to over ream since the bone is often soft due to the lack of weight bearing. Restoration of the center of rotation in Crowe grade IV might require a femoral shortening osteotomy to facilitate reduction of the hip.

## 6. Femoral reconstruction

In comparison to patients with primary osteoarthritis, the dysplastic femur has a narrower and straighter intramedullary canal [24, 25]. In mildly dysplastic hips standard femoral stems can often be used. However, the proximal bone is often osteopenic and its valgus alignment can increase the risk of calcar fractures if broached implants are used. A femoral wire-cerclage of the proximal femur just above the lesser trochanter can be used prophylactically.

Modular implants (for instance S-Rom® system, DePuy, Warsaw, IN) allow the surgeon to use a standard implant for patients with small canal diameter and excessive anteversion while preserving the option to do a femoral shortening osteotomy [26]. The proximal modular sleeve can be selected according to the proximal metaphysis shape and size.

Modular implants also allow to correct excessive anteversion and adjust the medial spout according to the amount of valgus present [12]. Surgeons should be aware that excessive femoral anteversion is more common in patients with lower Crowe grades. Excessive femoral anteversion can also be corrected using derotation of the proximal fragment during a femoral shortening osteotomy [13].

In grade Crowe III and especially IV, subtrochanteric shortening osteotomies are often indicated [27]. Limb lengthening is generally possible between 2.5 and 4.5 cm [28]. If more lengthening is required, femoral shortening is recommended to avoid sciatic nerve palsy [29, 30]. Especially patients with prior surgeries are at increased risk for sciatic nerve palsy and less lengthening might be possible in these patients.

Preoperative planning is crucial to assess the location of the osteotomy, diameter of the stem as well as extend of lengthening. While a shortening osteotomy can be performed using a cemented stem, today, usually a modular uncemented femoral component is preferred. The removed bone segment can be split in coronal plane and utilized as bone graft by wiring the bone shells on each side of the osteotomy to improve rotational stability. Theoretically, an oblique osteotomy can improve rotational stability; today transverse osteotomies are usually preferred to facilitate derotation of the proximal fragment.

Alternatives to shortening osteotomies are swan neck prosthesis or two stage skeletal traction followed by THA [31–33].

To facilitate intraoperative reduction soft tissue releases including release of the gluteus maximus insertion on the proximal femur, elevation of the gluteus medius of its insertion on the ilium, release of the psoas off the lesser trochanter as well as releases of the anterior and posterior capsule might be necessary. In case of a severe adduction contracture, a postoperative percutaneous release of the adductor tendons can be considered. It is crucial to carefully balance the need for soft tissue releases to facilitate reduction and the need for stability of the hip to minimize postoperative dislocations.

Recommended bearing options in THA for DDH are metal or ceramic on highly crosslinked polyethylene-bearing combinations.



## 7. Hip resurfacing

In young male patients with Crowe grade I or II deformity, hip resurfacing can be a valuable treatment option with satisfactory results [34, 35]. However, hip resurfacing can face a number of challenges in patients with DDH: because of the valgus neck alignment restoration of hip offset is usually challenging; excessive femoral anteversion and leg shortening cannot be corrected using a hip resurfacing; finally, acetabular components rely on primary press fit and screw augmentation is not possible for most resurfacing components. If a limb-length discrepancy of more than 2 cm or a Crowe grade III or IV deformity is present, hip resurfacing is not recommended [36]. Advantages of hip resurfacing include preservation of bone stock, better range of motion, and stability as well as increased ability to participate in sport compared to conventional THA.

## 8. Postoperative mobilization

While early mobilization is encouraged in patients undergoing THA for DDH, patients requiring modular implants or more advanced bone grafting and shortening osteotomies often need to observe toe touch weight bearing on crutches for 4–6 weeks. Standard postoperative anti-thrombotic prophylaxis is recommended.

Shortening osteotomies might require additional abductor precautions during the first 4–6 weeks. Hip precautions are usually enforced for patients undergoing a posterior approach.

## 9. Complications

Complications are more common in patients undergoing THA for DDH [37]. A higher incidence of proximal femoral fractures is encountered due to the dysplastic narrow femoral canal.

The incidence of dislocations in dysplastic hips is increased and postoperative dislocation is the most common reason for revision surgeries within the first 6 months [38]. Dislocations are commonly anterior as a result of extensive combined anteversion and are not influenced by Crowe grade or the need for shortening osteotomies [39]. Moreover, smaller head diameters due to smaller acetabular component sizes and a decreased femoral offset are additional risk factors for dislocation. The medialization of the cup can result in a decreased femoral offset and bony impingement.

Increased polyethylene wear can occur because of the smaller component sizes with thinner polyethylene inserts, resulting in osteolysis and acetabular component loosening [40].

Also the risk for sciatic nerve palsy is increased and its risk is associated with surgical complexity and history of prior surgeries [41]. Nonunion or delayed union can be encountered in patients with femoral shortening osteotomies [42, 43].

A higher incidence of infections was reported for patients undergoing THA for DDH compared to osteoarthritis. This might be secondary to the increased surgical complexity, increased surgical time, as well as the need for extensive soft tissue releases and utilization of bone grafts [13].

## 10. Outcome

The functional outcome of THA in DDH is comparable to primary THA in osteoarthritis [44, 45]. However, the revision rate is higher compared to patients with osteoarthritis and increases with severity of the deformity [8, 37]. Increased revision rates in cemented components due to loosening and increased wear were reported in the past, but modern implants and surgical techniques have remarkably improved the long-term survival rates [46]. Even in cases with shortening osteotomies modern implants provide satisfactory mid- and long-term functional results [47, 48].

A proper restoration of hip mechanics and soft tissue balance is important to provide the best functional results after THA. An anatomical restoration of the hip center improves function and decreases acetabular component loosening [18]. Functional results in severe DDH are poor compared to primary osteoarthritis [42], which might be related to the accompanying soft tissue contractures and preoperative functional status. Patients may also have a limb after surgery due to muscle weakness of the abductors. However, in general THA in DDH provides significant increase in function and quality of life in the long-term follow up [49]. Prior pelvis osteotomies can increase the surgical complexity, but do not influence the complication rate or outcome [50, 51].

## 11. Conclusion

Preoperative planning is crucial in developmental dysplasia. With increasing grade of deformity, the surgeon should have special modular implants available and should be prepared to perform femoral shortening osteotomies as well as lateral acetabular bone grafting. Modern THA provides good long-term results, however, complication rates are increased compared to THA in primary osteoarthritis. It is important to communicate realistic expectations, discuss the increased risk of complications and alert the patient to the possible need for protected weight-bearing.

## Contribution statement

I attest to the fact that all authors have participated in the research, read the manuscript, attest to the validity and legitimacy of the data and its interpretation, and agree to its submission.

## Conflict of interest statement

We certify that we have not signed any agreement with commercial interest related to this book chapter, which would in any way limit publication of any and all data generated for the study or to delay publication for any reason.

Dr. Boettner reports personal fees from Smith & Nephew, personal fees from Ortho Development Corporation and personal fees from DePuy, outside the submitted work.

## Author details

Maximilian F. Kasparek and Friedrich Boettner\*

\*Address all correspondence to: [boettnerf@hss.edu](mailto:boettnerf@hss.edu)

Adult Reconstruction and Joint Replacement Division, Hospital for Special Surgery, New York, NY, USA

## References

- [1] Hartofilakidis G, Karachalios T. Total hip arthroplasty for congenital hip disease. *J Bone Joint Surg Am* 2004;86-a(2):242–50.
- [2] Bernasek TL, Haidukewych GJ, Gustke KA, Hill O, Levering M. Total hip arthroplasty requiring subtrochanteric osteotomy for developmental hip dysplasia: 5- to 14-year results. *J Arthroplasty* 2007;22(6 Suppl 2):145–50. doi:10.1016/j.arth.2007.05.014.
- [3] Argenson JN, Flecher X, Parratte S, Aubaniac JM. Anatomy of the dysplastic hip and consequences for total hip arthroplasty. *Clin Orthop Relat Res* 2007;465:40–5. doi:10.1097/BLO.0b013e3181576052.
- [4] Argenson JN, Ryembault E, Flecher X, Brassart N, Parratte S, Aubaniac JM. Three-dimensional anatomy of the hip in osteoarthritis after developmental dysplasia. *J Bone Joint Surg Br* 2005;87(9):1192–6. doi:10.1302/0301-620x.87b9.15928.
- [5] Hoaglund FT, Shiba R, Newberg AH, Leung KY. Diseases of the hip. A comparative study of Japanese Oriental and American white patients. *J Bone Joint Surg Am* 1985; 67(9):1376–83.
- [6] Crowe JF, Mani VJ, Ranawat CS. Total hip replacement in congenital dislocation and dysplasia of the hip. *J Bone Joint Surg Am* 1979;61(1):15–23.
- [7] Hartofilakidis G, Stamos K, Karachalios T, Ioannidis TT, Zacharakis N. Congenital hip disease in adults. Classification of acetabular deficiencies and operative treat-

- ment with acetabuloplasty combined with total hip arthroplasty. *J Bone Joint Surg Am* 1996;78(5):683–92.
- [8] Cameron HU, Botsford DJ, Park YS. Influence of the Crowe rating on the outcome of total hip arthroplasty in congenital hip dysplasia. *J Arthroplasty* 1996;11(5):582–7.
- [9] Gromov K, Greene ME, Huddleston JL, Emerson R, Gebuhr P, Malchau H et al. Acetabular dysplasia and surgical approaches other than direct anterior increases risk for malpositioning of the acetabular component in total hip arthroplasty. *J Arthroplasty* 2016;31(4):835–41. doi:10.1016/j.arth.2015.10.045.
- [10] Baque F, Brown A, Matta J. Total hip arthroplasty after periacetabular osteotomy. *Orthopedics* 2009;32(6):399. doi:10.3928/01477447-20090511-04.
- [11] Lakstein D, Backstein DJ, Safir O, Kosashvili Y, Gross AE. Modified trochanteric slide for complex hip arthroplasty: clinical outcomes and complication rates. *J Arthroplasty* 2010;25(3):363–8. doi:10.1016/j.arth.2009.02.017.
- [12] Sanchez-Sotelo J, Berry DJ, Trousdale RT, Cabanela ME. Surgical treatment of developmental dysplasia of the hip in adults: II. Arthroplasty options. *J Am Acad Orthop Surg* 2002;10(5):334–44.
- [13] Rogers BA, Garbedian S, Kuchinad RA, Backstein D, Safir O, Gross AE. Total hip arthroplasty for adult hip dysplasia. *J Bone Joint Surg Am* 2012;94(19):1809–21. doi:10.2106/jbjs.k.00779.
- [14] Doehring TC, Rubash HE, Shelley FJ, Schwendeman LJ, Donaldson TK, Navalgund YA. Effect of superior and superolateral relocations of the hip center on hip joint forces. An experimental and analytical analysis. *J Arthroplasty* 1996;11(6):693–703.
- [15] Delp SL, Wixson RL, Komattu AV, Kocmond JH. How superior placement of the joint center in hip arthroplasty affects the abductor muscles. *Clin Orthop Relat Res* 1996;(328):137–46.
- [16] Bicanic G, Delimar D, Delimar M, Pecina M. Influence of the acetabular cup position on hip load during arthroplasty in hip dysplasia. *Int Orthop* 2009;33(2):397–402. doi:10.1007/s00264-008-0683-z.
- [17] Stans AA, Pagnano MW, Shaughnessy WJ, Hanssen AD. Results of total hip arthroplasty for Crowe Type III developmental hip dysplasia. *Clin Orthop Relat Res* 1998;(348):149–57.
- [18] Watts CD, Abdel MP, Hanssen AD, Pagnano MW. Anatomic hip center decreases aseptic loosening rates after total hip arthroplasty with cement in patients with Crowe type-II dysplasia: a concise follow-up report at a mean of thirty-six years. *J Bone Joint Surg Am* 2016;98(11):910–5. doi:10.2106/jbjs.15.00902.
- [19] Li H, Mao Y, Oni JK, Dai K, Zhu Z. Total hip replacement for developmental dysplasia of the hip with more than 30% lateral uncoverage of uncemented acetabular components. *Bone Joint J* 2013;95-b(9):1178–83. doi:10.1302/0301-620x.95b9.31398.

- [20] Harris WH, Crothers O, Oh I. Total hip replacement and femoral-head bone-grafting for severe acetabular deficiency in adults. *J Bone Joint Surg Am* 1977;59(6):752–9.
- [21] Spangehl MJ, Berry DJ, Trousdale RT, Cabanela ME. Uncemented acetabular components with bulk femoral head autograft for acetabular reconstruction in developmental dysplasia of the hip: results at five to twelve years. *J Bone Joint Surg Am* 2001;83-a(10):1484–9.
- [22] Abdel MP, Stryker LS, Trousdale RT, Berry DJ, Cabanela ME. Uncemented acetabular components with femoral head autograft for acetabular reconstruction in developmental dysplasia of the hip: a concise follow-up report at a mean of twenty years. *J Bone Joint Surg Am* 2014;96(22):1878–82. doi:10.2106/jbjs.n.00061.
- [23] Bicanic G, Barbaric K, Bohacek I, Aljinovic A, Delimar D. Current concept in dysplastic hip arthroplasty: techniques for acetabular and femoral reconstruction. *World J Orthop* 2014;5(4):412–24. doi:10.5312/wjo.v5.i4.412.
- [24] Noble PC, Kamaric E, Sugano N, Matsubara M, Harada Y, Ohzono K et al. Three-dimensional shape of the dysplastic femur: implications for THR. *Clin Orthop Relat Res* 2003;(417):27–40. doi:10.1007/s11999-003-0000-0.
- [25] Robertson DD, Essinger JR, Imura S, Kuroki Y, Sakamaki T, Shimizu T et al. Femoral deformity in adults with developmental hip dysplasia. *Clin Orthop Relat Res* 1996;(327):196–206.
- [26] Tamegai H, Otani T, Fujii H, Kawaguchi Y, Hayama T, Marumo K. A modified S-ROM stem in primary total hip arthroplasty for developmental dysplasia of the hip. *J Arthroplasty* 2013;28(10):1741–5. doi:10.1016/j.arth.2013.04.041.
- [27] Gustke K. The dysplastic hip: not for the shallow surgeon. *Bone Joint J* 2013;95-b(11 Suppl A):31–6. doi:10.1302/0301-620x.95b11.32899.
- [28] Lewallen DG. Neurovascular injury associated with hip arthroplasty. *Instr Course Lect* 1998;47:275–83.
- [29] Sener N, Tozun IR, Asik M. Femoral shortening and cementless arthroplasty in high congenital dislocation of the hip. *J Arthroplasty* 2002;17(1):41–8.
- [30] Reikeraas O, Lereim P, Gabor I, Gunderson R, Bjerkreim I. Femoral shortening in total arthroplasty for completely dislocated hips: 3–7 year results in 25 cases. *Acta Orthop Scand* 1996;67(1):33–6.
- [31] Huo MH, Salvati EA, Lieberman JR, Burstein AH, Wilson PD, Jr. Custom-designed femoral prostheses in total hip arthroplasty done with cement for severe dysplasia of the hip. *J Bone Joint Surg Am* 1993;75(10):1497–504.
- [32] DiFazio F, Shon WY, Salvati EA, Wilson PD, Jr. Long-term results of total hip arthroplasty with a cemented custom-designed swan-neck femoral component for congenital dislocation or severe dysplasia: a follow-up note. *J Bone Joint Surg Am* 2002;84-a(2):204–7.

- [33] Yoon PW, Kim JI, Kim DO, Yu CH, Yoo JJ, Kim HJ et al. Cementless total hip arthroplasty for patients with Crowe type III or IV developmental dysplasia of the hip: two-stage total hip arthroplasty following skeletal traction after soft tissue release for irreducible hips. *Clin Orthop Surg* 2013;5(3):167–73. doi:10.4055/cios.2013.5.3.167.
- [34] Wang Q, Zhang XL, Chen YS, Shen H, Shao JJ. Resurfacing arthroplasty for hip dysplasia: a prospective randomised study. *J Bone Joint Surg Br* 2012;94(6):768–73. doi:10.1302/0301-620x.94b6.28522.
- [35] Amstutz HC, Le Duff MJ, Harvey N, Hoberg M. Improved survivorship of hybrid metal-on-metal hip resurfacing with second-generation techniques for Crowe-I and II developmental dysplasia of the hip. *J Bone Joint Surg Am* 2008;90 Suppl 3:12–20. doi:10.2106/jbjs.h.00711.
- [36] Amstutz HC, Beaulé PE, Dorey FJ, Le Duff MJ, Campbell PA, Gruen TA. Metal-on-metal hybrid surface arthroplasty. *Surgical Technique. J Bone Joint Surg Am* 2006;88 Suppl 1 Pt 2:234–49. doi:10.2106/jbjs.f.00273.
- [37] Krych AJ, Howard JL, Trousdale RT, Cabanela ME, Berry DJ. Total hip arthroplasty with shortening subtrochanteric osteotomy in Crowe type-IV developmental dysplasia. *J Bone Joint Surg Am* 2009;91(9):2213–21. doi:10.2106/jbjs.h.01024.
- [38] Thillemann TM, Pedersen AB, Johnsen SP, Soballe K. Implant survival after primary total hip arthroplasty due to childhood hip disorders: results from the Danish Hip Arthroplasty Registry. *Acta Orthop* 2008;79(6):769–76. doi:10.1080/17453670810016830.
- [39] Wang L, Trousdale RT, Ai S, An KN, Dai K, Morrey BF. Dislocation after total hip arthroplasty among patients with developmental dysplasia of the hip. *J Arthroplasty* 2012;27(5):764–9. doi:10.1016/j.arth.2011.08.021.
- [40] Murray PJ, Hwang KL, Imrie SN, Huddleston JI, 3rd, Goodman SB. Polyethylene wear and osteolysis is associated with high revision rate of a small sized porous coated THA in patients with hip dysplasia. *J Arthroplasty* 2014;29(7):1373–7. doi:10.1016/j.arth.2014.02.027.
- [41] Egli S, Hankemayer S, Muller ME. Nerve palsy after leg lengthening in total replacement arthroplasty for developmental dysplasia of the hip. *J Bone Joint Surg Br* 1999;81(5):843–5.
- [42] Yalcin N, Kilicarslan K, Karatas F, Mutlu T, Yildirim H. Cementless total hip arthroplasty with subtrochanteric transverse shortening osteotomy for severely dysplastic or dislocated hips. *Hip Int* 2010;20(1):87–93.
- [43] Hartofilakidis G, Babis GC, Georgiades G, Kourlaba G. Trochanteric osteotomy in total hip replacement for congenital hip disease. *J Bone Joint Surg Br* 2011;93(5):601–7. doi:10.1302/0301-620x.93b5.24780.
- [44] Boyle MJ, Frampton CM, Crawford HA. Early results of total hip arthroplasty in patients with developmental dysplasia of the hip compared with patients with osteoarthritis. *J Arthroplasty* 2012;27(3):386–90. doi:10.1016/j.arth.2011.06.024.

- [45] Engesaeter LB, Furnes O, Havelin LI. Developmental dysplasia of the hip—good results of later total hip arthroplasty: 7135 primary total hip arthroplasties after developmental dysplasia of the hip compared with 59774 total hip arthroplasties in idiopathic coxarthrosis followed for 0 to 15 years in the Norwegian Arthroplasty Register. *J Arthroplasty* 2008;23(2):235–40. doi:10.1016/j.arth.2007.03.023.
- [46] Perka C, Fischer U, Taylor WR, Matziolis G. Developmental hip dysplasia treated with total hip arthroplasty with a straight stem and a threaded cup. *J Bone Joint Surg Am* 2004;86-a(2):312–9.
- [47] Takao M, Ohzono K, Nishii T, Miki H, Nakamura N, Sugano N. Cementless modular total hip arthroplasty with subtrochanteric shortening osteotomy for hips with developmental dysplasia. *J Bone Joint Surg Am* 2011;93(6):548–55. doi:10.2106/jbjs.i.01619.
- [48] Park MS, Kim KH, Jeong WC. Transverse subtrochanteric shortening osteotomy in primary total hip arthroplasty for patients with severe hip developmental dysplasia. *J Arthroplasty* 2007;22(7):1031–6. doi:10.1016/j.arth.2007.05.011.
- [49] Roidis NT, Pollalis AP, Hartofilakidis GC. Total hip arthroplasty in young females with congenital dislocation of the hip, radically improves their long-term quality of life. *J Arthroplasty* 2013;28(7):1206–11. doi:10.1016/j.arth.2012.09.025.
- [50] Tokunaga K, Aslam N, Zdero R, Schemitsch EH, Waddell JP. Effect of prior Salter or Chiari osteotomy on THA with developmental hip dysplasia. *Clin Orthop Relat Res* 2011;469(1):237–43. doi:10.1007/s11999-010-1375-8.
- [51] Duncan S, Wingerter S, Keith A, Fowler SA, Clohisy J. Does previous osteotomy compromise total hip arthroplasty? A systematic review. *J Arthroplasty* 2015;30(1):79–85. doi:10.1016/j.arth.2014.08.030.

