

Chapter

Diagnosis and Management of Obstructive Sleep Apnea

Ho-Hyun (Brian) Sun and Sally Sun

Abstract

Obstructive sleep apnea (OSA) represents a major public health issue affecting over 10% of the general adult, more than 80% of the geriatric, and up to 11% of the pediatric populations. Numerous studies have demonstrated distinct associations between OSA and diabetes, daytime drowsiness, and cardiopulmonary compromise including myocardial infarction. Considering the estimated rate of underdiagnosis, OSA is expected to exert a significant unrealized toll on the global healthcare infrastructure with the number of diagnoses increasing each year. The diagnosis of OSA entails subjective and objective evaluations including sleep surveys and polysomnography. Accordingly, treatment of OSA also encompasses a large variety of conservative, pharmacologic, and surgical interventions. Treatment selection remains a difficult but critical part of intervention especially when multiple modalities are required. This chapter aims to describe not only the presentation of this head and neck airway pathology but the interprofessional management strategies employed.

Keywords: polysomnography, apnea, hypopnea, obstructive sleep apnea, obesity, continuous positive airway pressure, septoplasty, uvulopalatopharyngoplasty, hyoid suspension, genioglossus advancement, maxillomandibular advancement, hypoglossal nerve stimulation

1. Introduction

Obstructive sleep apnea (OSA) is a common disease of the head and neck respiratory tract with severe systemic ramifications [1, 2]. It is characterized by multiple episodes of apnea or hypopnea during sleep resulting from partial and/or complete collapse of the upper airway [3].

OSA affects 10% or more of the population with males at increasingly greater risk than females [4]. It contributes to chronic conditions such as obesity, diabetes, myocardial infarction, and daytime drowsiness that leads to frequent motor vehicle accidents [3]. Many surgical and non-surgical treatment modalities exist, including continuous positive air pressure (CPAP) devices that keep the patency of the airway via exerting a baseline artificial inspiratory pressure. When patients are unable or unwilling to tolerate these bulky fixtures, they often require surgery to mechanically increase their airway volume [5].

Studies have described factors associated with the presentation and severity of OSA. Conditions that narrow the upper airway are particularly injurious to the

at-risk patient. Physiologic features such as obesity (which increases the mass of the soft tissues around the neck), decreases in muscle or neural tone (which frequently results from sedation or old age), congenital gnathic hypoplasias (which may exist without other notable medical findings), and craniofacial syndromes (which could contribute to abnormal hypoplasia of multiple craniofacial features) have been implicated [6].

2. History

Ancient Greeks first noted OSA or OSA-like snoring conditions in their 4th century BC accounts of Dionysius, the tyrant of Heraclea who was said to be “obese beyond measure.” The first modern medical description is attributed to James Russell and his peers as a syndrome of obesity and daytime drowsiness. OSA was poetically if not erroneously named the “Pickwickian syndrome” after the snoring “fat boy Joe” in Charles Dickens’s novel “The Posthumous Papers of the Pickwick Club.” [7] Dickens’s tale would depict the life of an obese servant boy whose daytime activities were marred by debilitating drowsiness as often noted in modern OSA patients.

While clinicians and writers alike noted the distinct obesity of most OSA patients, obstruction was deemed inevitable until the development of the CPAP device in 1981 by Colin Sullivan and colleagues at the University of Sydney [8]. CPAP first saw use as a bulky nasal device that soon became the gold standard in OSA care.

3. Causes

OSA frequently co-presents with chronic conditions, the most prevalent of which is obesity. Obesity increases the mass and volume of parapharyngeal tissues, which can fall back in a supine position to cause respiratory obstruction during sleep. In fact, supine sleepers and patients with adeno-tonsillar enlargements experience OSA more frequently [9]. Metabolic conditions like hyperlipidemia and diabetes that may result from one or both of OSA and obesity [10].

Similarly, other pathoses leading to airway narrowing also predispose patients to OSA. Central and peripheral neural injuries that decrease the airway muscle tone have been shown to contribute to OSA in patients suffering from trauma [11]. Craniofacial syndromes like Down Syndrome that cause retrolingual hyperplasia and/or mandibular hypoplasia have been implicated in higher instances of OSA [6]. As such, OSA may also entail a genetic component with shared genes involving the formation of the nose, mouth, and throat likely predisposing certain families to higher rates of disease.

4. Signs and symptoms

As noted above, OSA has historically been defined by daytime drowsiness, loud snoring, and nighttime choking. This frequently leads to a higher incidence of automotive accidents and narcolepsy-like episodes [4]. Furthermore, implications in neurocognitive pathoses including impairments to attention, executive functioning, and long-term memory have been documented [12].

More recent studies indicate that OSA may also be an etiological factor behind diabetes, hypertension, coronary artery disease, and stroke. Appropriate treatment of OSA may reduce the risk of developing these conditions [10]. Obesity may also play a role as both a risk factor and a complication of OSA. Studies stipulate that alterations of molecular signaling pathways via repeated hypoxic episodes contribute to autonomic dysregulation, systemic inflammation, cardiopulmonary irregularities, and organic oxidation which predispose patients to metabolic diseases [13]. In fact, OSA has been linked to an increased risk of early death in patients under the age of 70 [2].

Studies of OSA in children are less common and may be confounded by the effects of puberty. They nonetheless indicate that while children with sleep-disordered breathing are at risk of attention and executive deficits like their adult counterparts, they show additional deficits in empathy, social behaviors, and phonological processing [12]. Children with OSA may also be predisposed to pulmonary hypertension and nocturnal enuresis [14].

5. Diagnosis

Today, polysomnography plays a central role in the diagnosis of both central and obstructive sleep apnea. A patient's apnea-hypopnea index (AHI) is taken along with the patient's brain (electroencephalography or EEG), eye (electrooculography or EOG), muscle (electromyography or EMG), and/or heart (electrocardiography or ECG) activities which enumerates the average number of apneic or hypopneic events per hour of physiologic sleep. An apneic event is defined as a 90% or more reduction of airflow lasting at least 10 seconds. An hypopneic event is defined as a 30–90% reduction of airflow lasting at least 10 seconds accompanied by a 3% or greater decrease in pulse oxygenation [15]. A diagnosis of mild OSA is made with an AHI of 5 to 15, moderate OSA with AHI of 15 to 30, and severe OSA with AHI of 30 or more events per hour (**Table 1**). Significant ECG abnormalities may also be present, which could indicate an increased severity of disease [13]. This scale is adjusted for the categorization of OSA in children. Pediatric OSA is classified as mild if AHI is between 1 to 5, moderate if between 5 to 10, and severe if greater than 10 events per hour.

Though less common, some literature instead utilize the respiratory disturbance index (RDI) to diagnose or monitor the progress of OSA. The RDI is determined as a sum of AHI and respiratory-effort related arousals (RERAs), which are characterized by increasing respiratory effort for 10 seconds or more leading to an arousal from sleep. Similarly to the AHI scale, the American Academy of Sleep Medicine regards RDI of 5 to 15 as mild, 15 to 30 as moderate, and more than 30 as severe [16].

Drug-induced sleep endoscopy (DISE) is another diagnostic modality for the detection of upper airway collapse during sleep. A sedative agent such as propofol,

AHI or RDI	OSA Severity
Less than 5	None
5 to 14	Mild
15 to 29	Moderate
More than 30	Severe

Table 1.
AHI and RDI scales [13, 15, 16].

How likely are you to doze off or fall asleep in the following scenarios?	
0 = Never	
1 = Slight chance of dozing off	
2 = Moderate chance of dozing off	
3 = High chance of dozing off	
Total Score – A score of greater than 10 denotes a higher risk of OSA	
0 – 5: Lower normal daytime sleepiness	
6 – 10: Higher normal daytime sleepiness	
11 – 12: Mild excessive daytime sleepiness	
13 – 15: Moderate excessive daytime sleepiness	
16 – 24: Severe excessive daytime sleepiness	
Scenario	Score
Sitting and reading	_____
Watching TV	_____
Sitting inactive in a public place (i.e. theater)	_____
As a passenger in a car for an hour	_____
Lying down to rest in the afternoon	_____
Sitting and talking to someone	_____
Sitting quietly after lunch without alcohol	_____
While stopped in traffic for a few minutes	_____

Table 2.
Epworth Sleepiness Scale [18].

Item 1: if “Yes,” a point is added.	
Item 2: if “c” or “d,” a point is added	
Item 3: if “a” or “b,” a point is added	
Item 4: if “a,” a point is added	
Item 5: if “a” or “b,” two points are added.	
Category 1 is “positive” if the total points above are 2 or higher.	
Item 6: if “a” or “b,” a point is added	
Item 7: if “a” or “b,” a point is added	
Item 8: if “a,” a point is added	
Category 2 is “positive” if the total points above are 2 or higher.	
Category 3 is “positive” if the answer to item 10 is “Yes” or if the patient BMI is greater than 30kg/m ²	
Patients are considered high risk of 2 or more categories are deemed positive.	
Item 1: Do you snore?	Item 6: How often do you feel tired or fatigued after sleep?
A. Yes	A. Nearly every day
B. No	B. 3-4 times per week
C. Do not know	C. 1-2 times per week
	D. 1-2 times per month
	E. Never or nearly never

Item 2: Your snoring is	Item 7: During your waking time, do you feel tired or fatigued?
A. Slightly louder than breathing.	A. Nearly every day
B. As loud as talking	B. 3-4 times per week
C. Louder than talking	C. 1-2 times per week
D. Can be heard in adjacent rooms	D. 1-2 times per month
E. I do not snore	E. Never or nearly never
Item 3: How often do you snore?	Item 8: Have you ever nodded off or fallen asleep while driving a vehicle?
A. Nearly every day	A. Yes
B. 3-4 times per week	B. No
C. 1-2 times per week	
D. 1-2 times per month	
E. Never or nearly never	
Item 4: Has your snoring ever bothered other people?	Item 9: How often do you nod off while driving?
A. Yes	A. Nearly every day
B. No	B. 3-4 times per week
C. Do not know	C. 1-2 times per week
	D. 1-2 times per month
	E. Never or nearly never
Item 5: Has anyone noticed that you stop breathing during sleep?	Item 10: Do you have high blood pressure?
A. Nearly every day	A. Yes
B. 3-4 times per week	B. No
C. 1-2 times per week	C. Do not know
D. 1-2 times per month	
E. Never or nearly never	

Table 3.
 Berlin Questionnaire [19].

midazolam, or dexmedetomidine is administered to create a somewhat artificial state of sleep, during which a flexible endoscope is utilized to view the nasopharyngeal and oropharyngeal airways to monitor areas of collapse. While DISE can be a useful modality in detecting the degree and pattern of obstruction, its use may be limited as a result of 1) unnatural sleep patterns as a result of drug-induced nature of the slumber, 2) difficulty of maintaining the appropriate degree of sedation without causing undue cessation of respiration, and 3) uncertain reproducibility when scoring the degree of obstruction across different observers [17]. The use of propofol and/or dexmedetomidine purportedly re-creates a more natural pattern of sleep when compared to other medications like benzodiazepines.

The clinical manifestation of daytime sleepiness can be monitored via several patient surveys such as the Berlin and Epworth Sleepiness questionnaires (Tables 2 and 3). Recent studies suggest that the STOP-BANG questionnaire (Table 4) as devised by researchers at the University of Toronto is particularly effective not only as a screening tool but also as an adjunct to clinical follow up after operative interventions [21, 22].

A point is added for each question that is answered with a “yes.”
Snoring: Do you snore loudly?
Tired: Do you often feel tired, fatigued, or sleepy during the daytime?
Observed choking: Has anyone observed you choking during sleep?
Pressure: Do you have or are being treated for high blood pressure?
Body mass index: Is your BMI more than 35kg/m ² ?
Age: Are you older than 50 years of age?
Neck size: Is your shirt collar size >17 in for males or >16 in for females?
Gender: Are you biologically male?
In general, patients with a score of 2 or below are considered low risk, 3 to 4 intermediate risk, and 5 or greater high risk.

Table 4.
STOP-BANG Questionnaire [20].

In general, patients with a score of 2 or below are considered low risk, 3 to 4 intermediate risk, and 5 or greater high risk.

6. Management

Treatment of OSA may frequently reverse its systemic consequences, though permanent brain alterations may occur that prevent complete recovery of deficits in psychomotor functioning [12]. However, most studies concur that metabolic consequences (including those associated with diabetes and obesity) improve after resolution or improvement of OSA [4, 6, 12].

An effective management of OSA can be categorized as either a “success” or a “cure.” In general, a successful treatment denotes a 50% or greater reduction in AHI such that it decreases to an AHI of 20 events per hour or less. The definition of a curative treatment is more stringent and requires the reduction of AHI to 5 events per hour or less [13]. Interventional success may also be defined as a 50% or greater reduction in RDI with a post-procedural RDI of 15 or less [23].

7. Conservative management

Conservative therapy remains the mainstay of OSA treatment because of their low risk and reversibility of treatment. Furthermore, pharmacologic and/or surgical interventions may require a stricter set of inclusion criteria and may not be appropriate for every patient [24].

Conservative therapy can be as non-invasive as a simple avoidance of certain substances or dietary patterns. As described previously, avoidance of obesity via healthy diet and possibly even exercise alone may improve symptoms of OSA [25]. Abstinence from sedating compounds and airway muscle relaxants – such as alcohol - is also beneficial [26]. Patients should cease exposure to airway irritants like tobacco smoke and partake in activities that encourage patency of the airway like sleeping in inclined or lateral positions and playing wind instruments [26–29].

CPAP devices are considered the gold standard of OSA therapy. They function by creating consistent air pressures in airways to keep them patent during sleep. CPAP has a long history of demonstrated efficacy, and its use has also been

associated with decreases in a number of associated conditions including cognitive impairment, daytime drowsiness, and cardiovascular disease [30–32]. CPAP machines are nonetheless bulky and uncomfortable to wear, leading to a high rate of noncompliance [33]. Modified equipment such as bilevel positive airway pressure (BiPAP) or automatically-titrated (APAP) devices, which monitors breathing to exert a higher pressure during inhalation and a lower pressure during exhalation, can reduce discomfort associated with their use [34].

Oral appliance therapy is also considered an acceptable, reversible therapy for OSA especially in cases of mild or moderate sleep apnea [35]. The devices typically function by inducing an anterior posture of the mandible that, in theory, helps increase the antero-posterior diameter of the retrolingual airway. While oral appliances are much more compact and often better tolerated, its efficacy remains controversial and long term use may be associated with dry mouth, dental trauma, and jaw pain [26, 36].

8. Pharmacologic interventions

In general, the evidence supporting pharmacotherapy remains insufficient. [24, 37] Antidepressants and serotonin-promoting compounds were studied because activation of serotonin 5-HT₂ receptors in the brainstem was shown to induce excitatory input to the hypoglossal neurons, which in turn incites an anterior advancement of the tongue [38]. Mirtazapine in particular was shown to reduce AHI in the short term, but its long-term administration is associated with sedation and weight gain, which are known adverse risk factors of worsening OSA [39]. Paroxetine was also studied but its effects were found not to be significant, [40] possibly because non-discriminatory activation of both peripheral 5-HT₃ and 5-HT₂ receptors has been associated with REM-associated apnea [41].

Parasympathomimetics like donepezil may modulate airway and/or tongue muscle contraction via cholinergic pathways. Its use was associated with a reduction in AHI by approximately 20%, [42] which would not meet the clinical definition of successful or curative treatment in all but mild cases. Respiratory smooth-muscle relaxants like theophylline were found to be either ineffective or to trigger counter-productive deteriorations in sleep quality because of their stimulatory properties [43].

Dronabinol and a combination of ondansetron and fluoxetine demonstrated some promise in controlling the rate of AHI in sleep apneic patients. While ondansetron or fluoxetine alone were ineffective, their combination showed more than a 40% reduction in AHI. Investigators stipulate that fluoxetine may stimulate central 5-HT₂ receptors while ondansetron suppresses the activation of their peripheral 5-HT₃ counterparts [44]. Dronabinol also incurred dose-dependent 40–50% reductions in AHI over a 6-week period of use. Cannabinoids like dronabinol activates cannabinoid type 1 (CB1) receptors, which in turn also antagonizes the actions of 5-HT₃ receptors [45]. However, neither the ondansetron-fluoxetine combination nor dronabinol showed clear clinical improvements in daytime drowsiness.

9. Sleep surgery

While conservative therapy is considered the first line intervention for OSA, surgery may be indicated in patients who are unable or unwilling to tolerate lifelong

conservative therapy [5]. A 2004 study of military veterans suggested that even singular surgical therapy may provide more than a 30% increase in overall survival benefit [46]. In fact, a combination of multiple surgical modalities may achieve a 60% reduction in AHI, which is comparable to that of CPAP which demonstrates between a 60 to 70% reduction [47, 48].

10. Tonsillectomy

Surgical intervention may encompass the soft and/or the hard tissues of the upper airway. Tonsillectomy is a soft tissue-oriented procedure that may be of benefit especially in children since their apneic episodes are predominantly caused by enlarged lymphoid tissues of the upper airway [3]. The long-term efficacy, however, is not yet well established [49]. In tonsillectomy, the lymphoid tissues and its capsular container are dissected wholly from its surrounding tissues. Sharp dissection with scalpel and electro- or diathermic-cautery may be used, followed by blunt dissection [50]. Notable vessels in the area are ligated using sutures which may be assisted by using topical thrombin. Post-operative bleeding may be significant which manifests in approximately 2% of patients and typically occurs approximately 1 to 2 weeks post-operatively [51].

11. Septoplasty with or without turbinate reduction

Septoplasty may also be conducted to address obstructions of the nasal passageway, which could worsen OSA symptoms. It is frequently conducted in patients with or without OSA to help relieve internal nasal valve obstruction. While nasal surgery alone may not significantly reduce AHI, it may be a viable adjunct therapy when utilized with another intervention [52]. Septoplasty with turbinate reduction has been associated with better tolerance of CPAP therapy [53].

To conduct septoplasty, an intranasal vertical incision is made through the septal mucosa and the perichondrium on the side of the obstruction (**Figure 1**). The approach is then taken posteriorly in a sub-perichondral fashion using a blunt instrument. The overlying soft tissues are carefully dissected from the obstructing spur or deviation to avoid tears. Vertical chondrotomies are made anterior and posterior to the obstruction so that the mucosa may be detached from the contralateral septal surface. A horizontal chondrotomy is made connecting the superior edges of the vertical chondrotomies. The horizontal chondrotomy is made at least 1 cm from the superior margin of the septum to preserve the structural integrity of the septum and prevent a saddle defect. The portion of cartilage containing the spur or deviation is then freed from the nasal spine and removed.

Adjunctive turbinate reduction may be accomplished via another vertical, full-thickness incision anterior to the inferior turbinate (or concha) at the attachment point to the lateral nasal wall (**Figure 2**). A subperiosteal plane is raised to expose the osseous turbinate. Forceps may then be introduced through the incision to remove the turbinate in small pieces. The overlying mucosa should also be reduced using a microdebrider without perforating through the soft tissue. Any remaining osseous portions may then be outfractured with a blunt instrument by applying lateral pressure.

The septal and/or turbinate mucosal incisions are sutured closed using a resorbable suture. Doyle splints or multiple interrupted transseptal sutures may be placed for five days to prevent the formation of a septal hematoma.

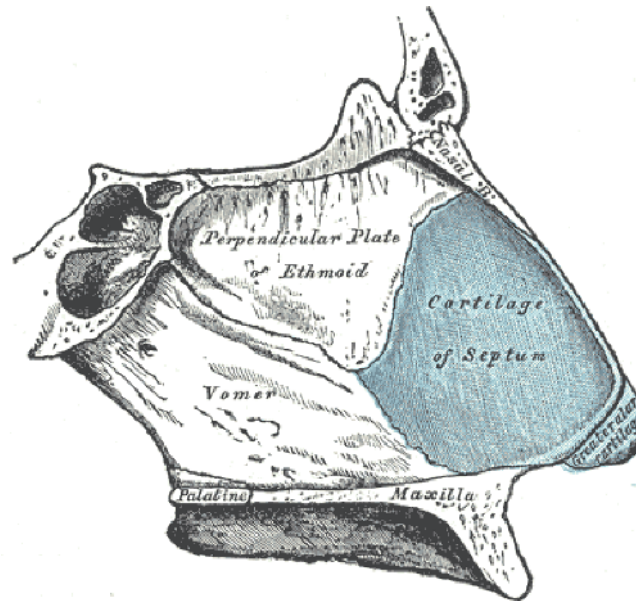


Figure 1.
The cartilaginous septum.

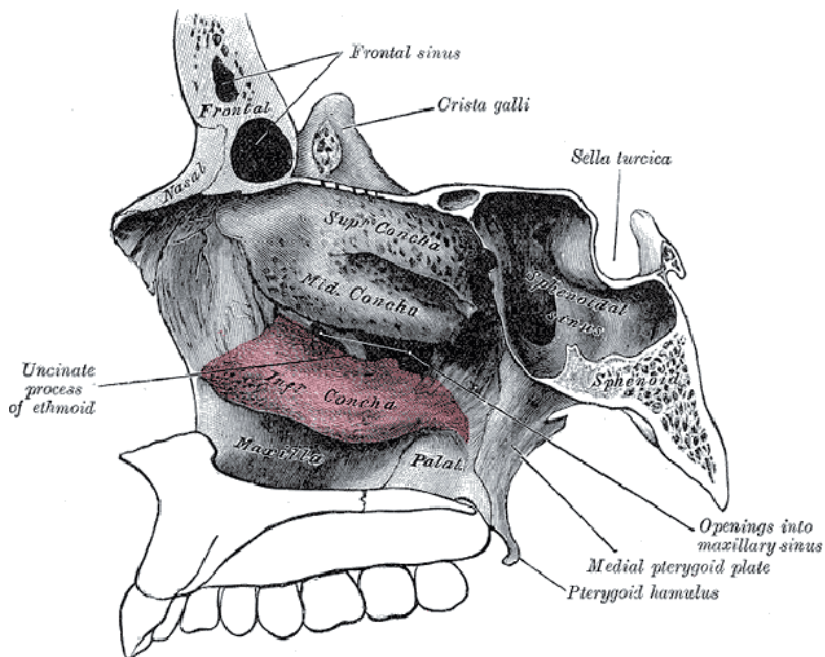


Figure 2.
Inferior turbinate position in the nasal cavity.

12. Uvulopalatopharyngoplasty

Uvulopalatopharyngoplasty (UPPP) is perhaps the most performed sleep surgery. While the large variety of OSA-associated factors make it difficult to gauge the exact success rate of UPPP, it appears to be more efficacious in patients without excessive neck size or BMI. UPPP is also notably less effective in those with multi-level obstructions beyond those of the retropalatal and retrolingual tissues [54].

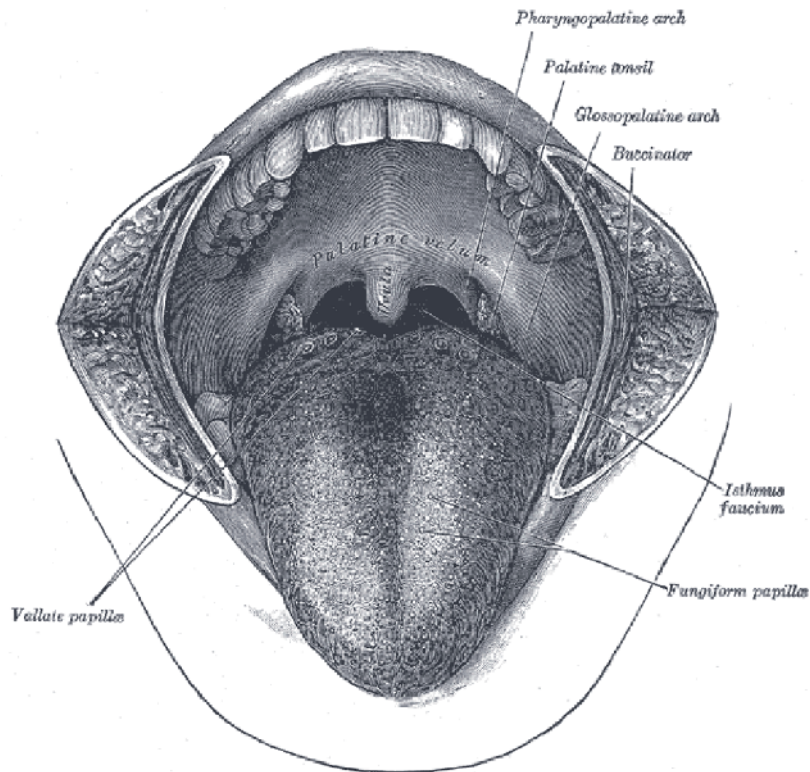


Figure 3.
An anatomic depiction of the uvula, tonsils, and their surrounding pillars.

In UPPP, the uvula, tonsils, and sometimes adenoids are first removed to remove the protrusive bulks of oropharyngeal tissue with particular attention towards preserving the posterior tonsillar pillars (**Figure 3**). The uvula may be excised with a wedge incision through its base to aid in closure.

The operator could then elect to further widen the lateral soft tissues of the oropharynx via lateral expansion pharyngoplasty. The bilateral palatopharyngeus muscles are located through the tonsillectomy incisions, dissected from the pharyngeal walls, then transected at a point approximately 2/3rds of the way from the palate to the tonsillar pillar base. The freed muscles may then be folded antero-superiorly through a tunnel deep to the palatal mucosa or through an incision placed through the palatal soft tissues. The previously transected edge of the palatopharyngeus is then sutured to the fixed aponeurotic tissues around the hamulus such that the action of the palatopharyngeus triggers a lateral expansion of the airway at the soft palate.

The posterior palatal pillars may then be suspended anteriorly via suturing the pillars to the pterygomandibular raphe. The incision sites for the uvula, tonsils, adenoids, and/or palatopharyngeus are sutured closed to create a smooth mucosal surface.

13. Hyoid suspension

Hyoid suspension (HS) is a relatively noninvasive surgical procedure that is commonly performed in conjunction with UPPP or genioglossus advancement. Like UPPP, HS is indicated for milder cases of OSA with retrolingual and hypopharyngeal (not retropalatal) obstructions [55]. HS alone may not provide significant

improvements to the AHI and is typically conducted as a component of comprehensive therapy [23]. In a study of female OSA patients, isolated HS consistently failed to achieve surgical success but obtained near-curative results when hyoid-mandibular suspension was conducted alongside UPPP [55].

HS functions via an artificial anteropositioning of the hyoid and thus increased anteroposterior dimensions of the airway [23]. The hyoid bone would traditionally be suspended to the lingual surface of the mandible, (**Figure 4**) though the need for an additional incision at the submental region as well as extensive dissection through the submental tissues have led to modified procedures that suspend the hyoid bone to the thyroid cartilage instead [55].

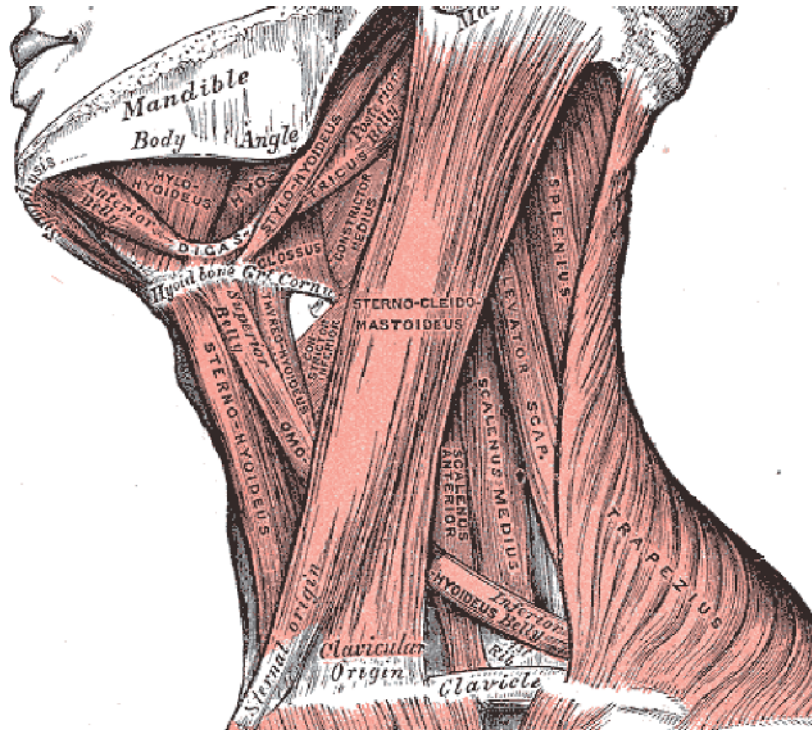


Figure 4.
 Position of the hyoid bone.

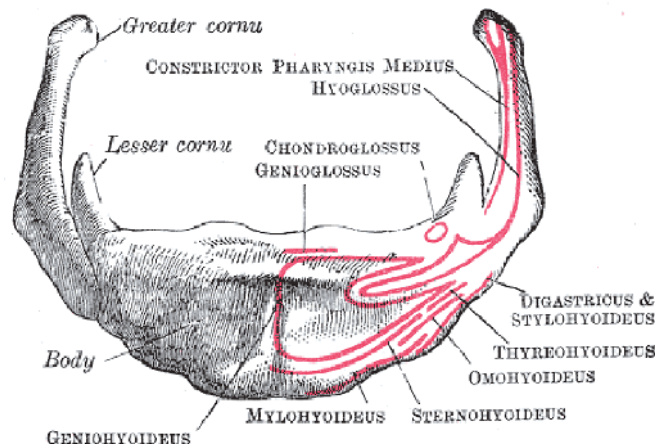


Figure 5.
 The muscular and ligamentous attachment sites of the hyoid bone.

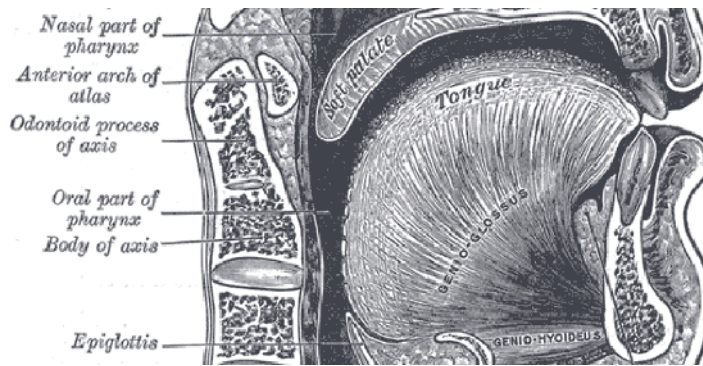


Figure 6.
Depiction of the genioglossus and its attachment site.

In both surgical variants, the hyoid bone is first approached via a direct incision. The infra-hyoid muscles are dissected from the bony surface and the stylohyoid ligaments are sectioned from the lesser cornu (**Figure 5**). In cases of hyoid suspension to the mandible, the submental region is then approached via sharp and/or blunt dissection to the lingual surface of the mandible. The digastric and mylohyoid muscles are separated laterally to avoid complete dissection from the mandible.

Two or more bony anchors are placed near the attachment site of the genioglossus (**Figure 6**). Non-resorbable sutures or wires may be wrapped around the body of the hyoid then passed through the bony anchors (in the case of hyo-mandibular suspension) or the thyroid cartilage (in the case of hyo-thyroid suspension) to advance the hyoid bone approximately 3 cm, inducing tension in its muscular attachments [23, 55]. A drain may left in place for 2 to 3 days to help reduce the risk of seroma or hematoma.

14. Genioglossus advancement

Genioglossus advancement (GA) is another surgical procedure commonly conducted in combination with HS or maxillomandibular advancement. The genioglossus muscle - and therefore, the base of the tongue - is advanced anteriorly to increase the anteroposterior diameter of the retrolingual airway [56]. While its rate of success as a standalone treatment remains at approximately 50%, this rate may increase greatly when conducted in conjunction with maxillomandibular advancement [57]. As expected, GA is not effective in treating obstructions at the palate.

GA may be performed as an anterior mandibular osteotomy to advance the genioglossus muscle without altering the external appearance of the chin. A pre-operative CT scan is utilized to locate the anterior attachment site of the genioglossus at the mental spine of the mandible (**Figure 7**). An osteotomy guide - frequently made as an occlusal-based appliance to fit over the mandibular dentition - is then created to separate this site from the rest of the mandible via a rectangular bicortical osteotomy approached from the buccal side of the mandible [56].

An intraoral incision is made through the anterior mandibular buccal vestibule to reach the osteotomy site at the symphysis. The subperiosteal dissection should be extended down to the inferior border of the mandible and laterally to the regions of the bilateral canines. Once the osteotomy is conducted, the freed segment of mandibular bone is typically advanced such that the lingual cortex of the freed segment is at or anterior to the buccal cortex of the surrounding mandible. The buccal cortex and the cancellous portions of the freed segment may be trimmed away to minimize

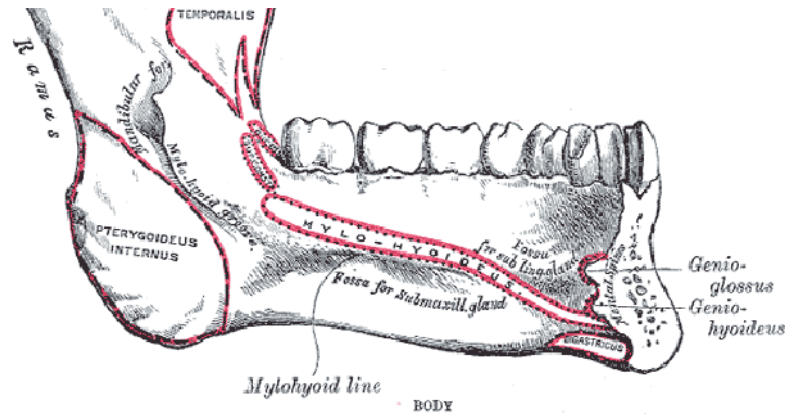


Figure 7.
Mental spine and the attachment sites of the genioglossus muscle.

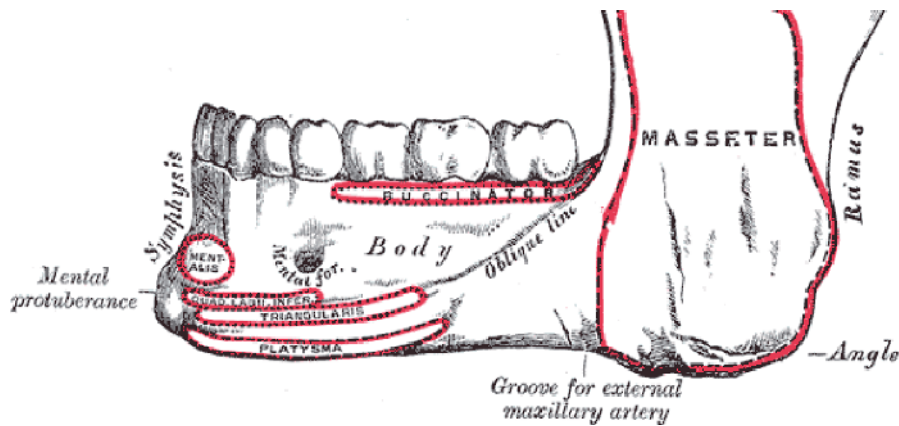


Figure 8.
Mental protuberance at the inferior aspect of the mandibular symphysis.

bony protrusion at the chin. The freed segment is fixated in place using titanium plates, which may be custom-made for convenience.

GA may also be performed as a part of cosmetically driven genioplasty in individuals with retrognathia. A large portion of the mental protuberance is advanced in addition to the segment of bone attached to the genioglossus muscle, which increases chin volume and esthetic outcome [57]. Instead of osteotomizing just the attachment site of the genioglossus, the operators would utilize an osteotomy guide that also encompasses a bulk of the mental protuberance (**Figure 8**).

15. Maxillomandibular advancement

Maxillomandibular advancement (MMA) is considered an effective surgical modality for patients affected by nasopharyngeal, retropalatal and/or retrolingual obstructions [5, 58, 59]. A recent meta-analysis suggests that MMA has greater than a 98% rate of clinical improvement, 85% rate of treatment success, and approximately 40% rate of a complete cure [59]. A potential downside of MMA treatment includes its invasiveness and applicability only in individuals who are esthetically amenable to an increasing prominence of the bimaxillary complex. Conversely, an MMA may be especially well suited for patients with hypoplastic dentofacial deformities who require such bony changes [60].

Like GA, MMA requires pre-operative planning frequently aided by CT scans. The radiographs may then be supplemented by stone models or optical scans of the patient's dentition to increase the accuracy in virtual surgical planning (VSP). Occlusal dental splints are produced which help execute the planned bony movements. MMA also frequently requires that approximately 1 year of pre-operative orthodontics be conducted to create a stable occlusion that is not only esthetic but is amenable to intermaxillary fixation (IMF).

To conduct MMA, a LeFort 1 osteotomy and a bilateral sagittal splint osteotomy (BSSO) are conducted to advance the palatal-alveolar complex and the body of the mandible, respectively (**Figure 9**). These horizontal advancements may be conducted in conjunction with a counterclockwise rotation of the maxillomandibular

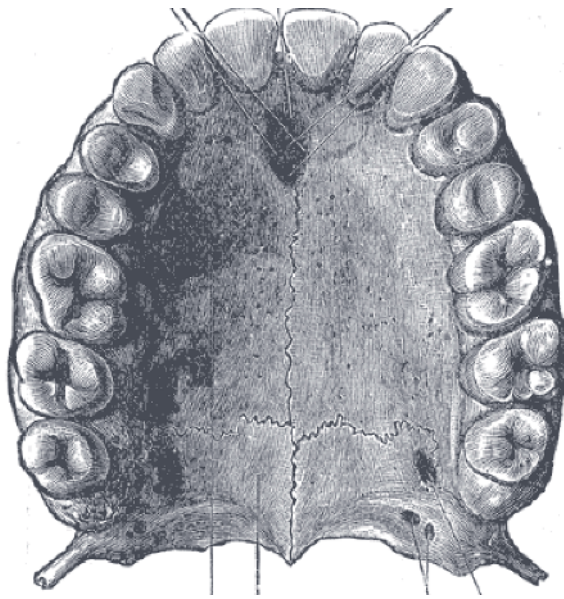


Figure 9.
The palatal-alveolar complex of the maxilla.

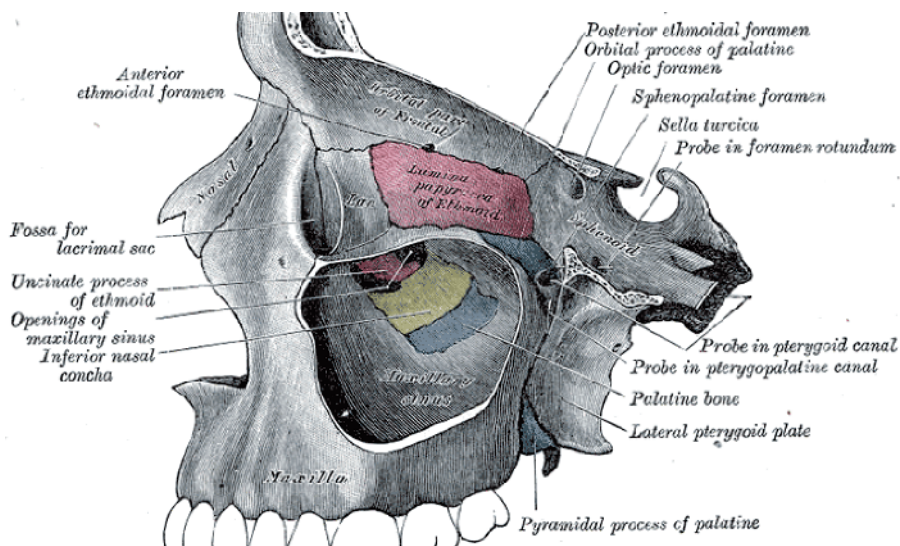


Figure 10.
The anterior, medial, lateral, and posterior walls of the maxillary sinus and their relationships to the lateral pterygoid plate.

complex (when viewed in a right lateral position) to accomplish a total advancement of the mandibular symphysis by at least 10 mm from its native position [57, 60].

Typically, the LeFort 1 osteotomy is conducted first to establish a stable upper dental position. The anterior and lateral walls of the maxilla are exposed via an incision through the maxillary buccal vestibule. A subperiosteal dissection is conducted, after which a saw osteotomy is made through the anterior and anterolateral walls of the maxillary sinuses (**Figure 10**). The osteotomies are continued posteriorly through the medial and lateral walls of the sinuses using osteotomes. The lateral pterygoid plates are also detached from the maxilla proper using a curved osteotome. The operator may elect to make a lateral approach to the pterygoid plates by gently “walking” the osteotome posteriorly along the lateral and posterior walls of the maxillary sinuses until the tip of the osteotome makes contact with a slight concavity at the pterygomaxillary junction. Gentle mallet impacts are then utilized to accomplish the detachment.

The nasal mucosae are also bluntly dissected from its attachments to the inferior and lateral walls of the nasal cavity. At this point, the posterior walls of the maxillary sinuses are the only osseous connections between the palatal-alveolar and the midface segments of the maxilla (**Figure 11**). A gentle downward pressure is applied at the anterior maxillary dentition to cause a controlled, horizontal fracture across the posterior walls of the maxillary sinuses. The soft tissue attachments to the palatal-alveolar segment are then stretched in preparation for its anterior movement.

The freed palatal-alveolar segment is then advanced approximately 10 mm via the use of preformed “intermediate” dental occlusal splints, which engages the mandibular dentition to hold the maxillary teeth approximately 10 mm anteriorly from their original positions. IMF is conducted with the splint in place (either with arch bars, pre-existing orthodontia, or intermaxillary screws) to stabilize the palatal-alveolar segment to the mandible. This allows the surgeons to trim and apply plate fixation to the palatal-alveolar segment in its new position relative to the rest of the maxilla.

The BSSO is performed next, although some providers may elect to perform the BSSO first followed by the LeFort 1 osteotomy. IMF is released and incisions are made through the bilateral buccal vestibules of the mandible to reveal the lateral

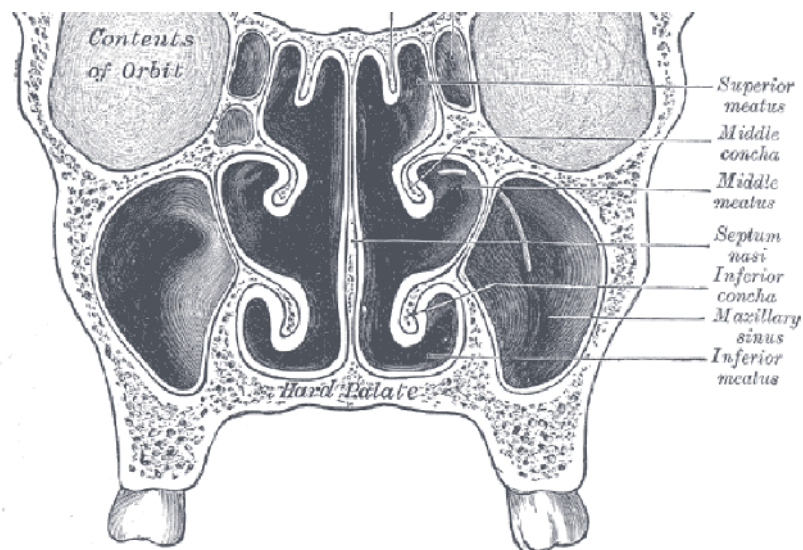


Figure 11.
A coronal section demonstrating the darkened, intact posterior walls of the maxillary sinuses.

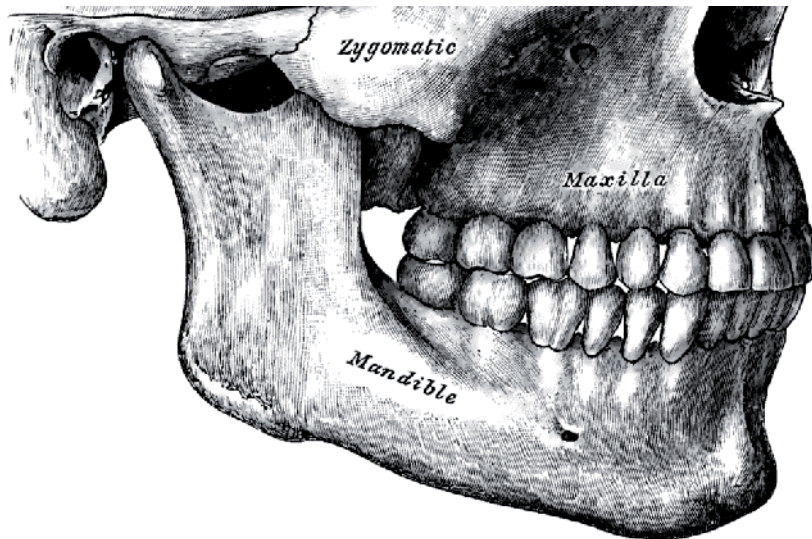


Figure 12.
The maxillomandibular complex. BSSO are conducted through the superolateral cortex of the mandibular body just medial to the ramus and just lateral to the posterior dentition.

cortex of the mandibular body as well as the antero-medial surfaces of the ramus. A monocortical saw osteotomy is then started from a point just superior to the lingula and continued downwards along the superolateral cortex of the mandibular body until it reaches the cortex just lateral to the first molar (**Figure 12**). The positioning of this osteotomy reduces the risk of injury to the inferior alveolar neurovascular bundle at its entrance and through its canal. Gentle osteotome pressure is applied through the osteotomies to propagate controlled fractures at the posterior wall of each ramus and the inferior wall of each mandibular body.

Once the body of the mandible is freed from its bilateral ramus-condyle segments, preformed “final’ dental occlusal splint may be used to advance the mandibular body segment. The splint engages the now-stable maxillary dentition to hold the mandibular teeth approximately 10 mm anteriorly from their original positions. IMF is again conducted with the new splint in place. The mandibular segment may be fixated in its new position (using orthopedic plates) relative to the bilateral ramus-condyle segments. After releasing the IMF and confirming correct occlusion, the patient should be re-placed in IMF for approximately two weeks followed by four additional weeks of non-chew diet.

The BSSO should be conducted first in cases where the pre-operative CT scans were taken without the condylar heads seated in the temporal fossa. The condyles may be seated after a proper mandibular advancement, and the new mandibular dental occlusion may then be used as the reference against which the palatal-alveolar segment is advanced.

16. Hypoglossal nerve stimulator

The hypoglossal nerve stimulator (HGNS) is a newly developed device that activates the hypoglossal nerve upon detection of an apneic episode. It includes a sensing and a stimulating electrode, which detects then mitigates apnea, respectively. HGNS is particularly effective in individuals with non-concentric, antero-posterior collapse of the retrolingual airway on DISE. It demonstrated a median AHI improvement of 68% in individuals with BMIs under 32 kg/m² [61]. After implantation, the HGNS impulses may be adjusted according to the patient’s post-operative AHI and/or RDI

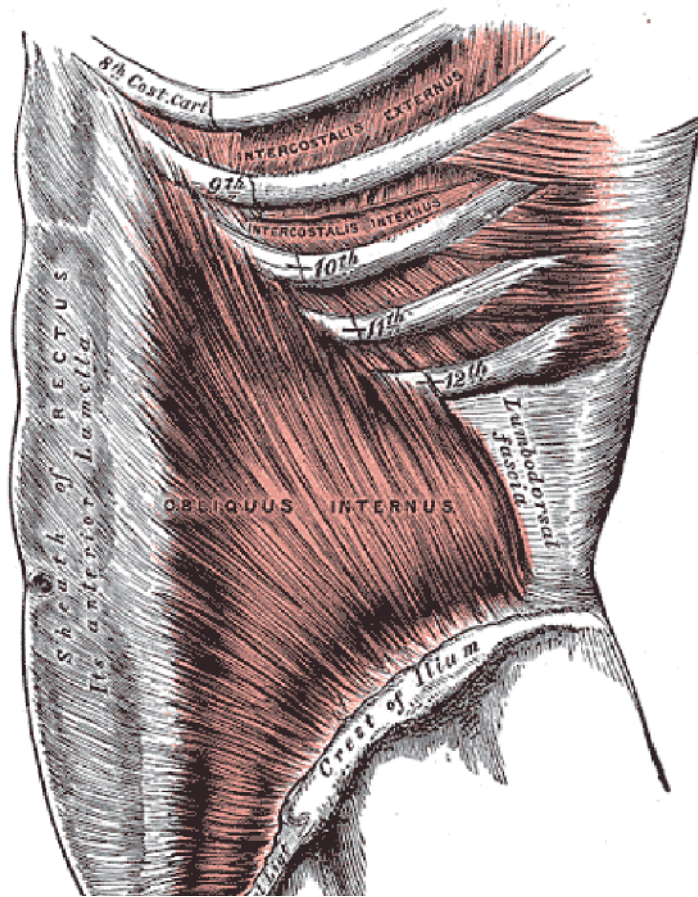


Figure 14.
The external and internal intercostal muscles.

The sensing electrode wires are tunneled subcutaneously from the lateral chest site to the pulse generator at the upper chest site. Similarly, the stimulating electrode wires are also tunneled in a sub-platysmal plane from the neck site to the pulse generator. The pulse generator is sutured in place at the upper chest pocket and connected to the respective electrode wires. The generator's power supply should be replaced approximately every ten years.

16.1 Tracheostomy

Tracheostomy is perhaps the oldest and the most definitive intervention for OSA. An incision is made through the anterior neck to insert a semi-permanent airway, bypassing both the naso- and oropharynx. Though it is typically performed to establish an emergency airway and/or to create a long-term ventilation port, it may be performed in cases of severe obstructive sleep apnea that is otherwise refractory to other treatment modalities. Tracheostomy is considered a treatment of last resort owing to its invasive nature and a relatively high rate of complications such as hemorrhage, tracheal stenosis, tracheoesophageal or tracheocutaneous fistula, and bronchospasm regardless of the approach taken [62, 63]. A recent systematic review indicated that percutaneous dilatational tracheostomy carries an overall mortality rate of approximately 1 in 600 [64]. It also requires dedicated maintenance including frequent suctioning and regular replacement of its parts.

Elective tracheostomy for OSA should be conducted in a sterile fashion in the operating room. A horizontal incision is made approximately 2 cm superior to the

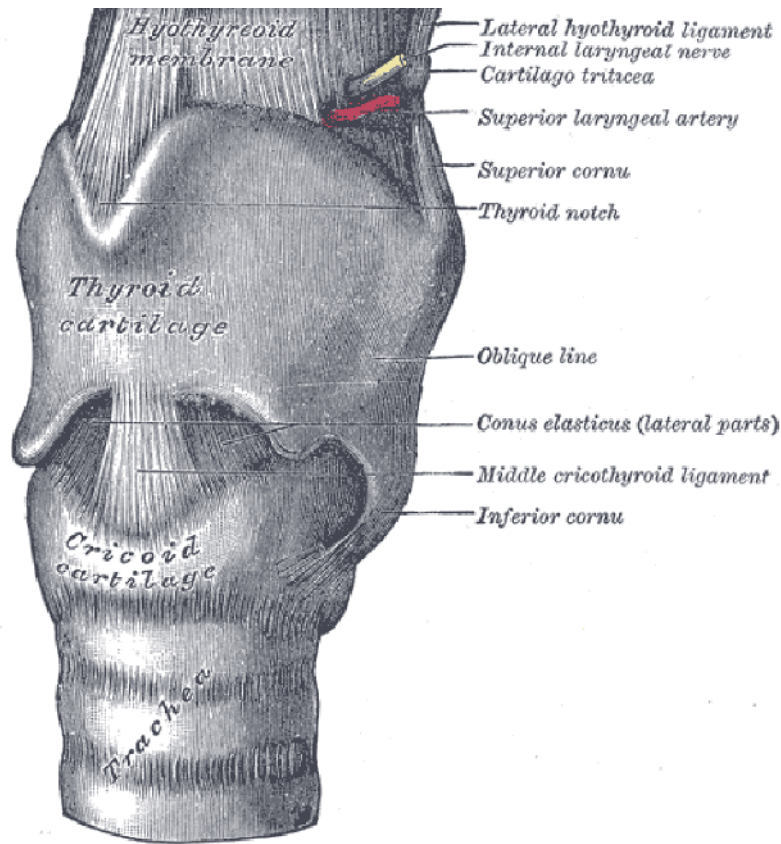


Figure 15.
The anatomy of the thyroid, cricoid, and tracheal cartilages.

suprasternal notch then dissected through the subcutaneous and platysmal layers. The subsequent fascia and strap muscles are divided along a vertical line until the thyroid gland or the pretracheal fascia are encountered. Any thyroid tissues encountered may be retracted superiorly, and the pretracheal fascia bluntly dissected away from the airway.

At this point, the patient's FiO₂ should be lowered and the endotracheal tube advanced further to avoid the risk of fire and cuff puncture, respectively. A horizontal incision is first made between the tracheal rings (**Figure 15**). This is connected to a vertical, downward incision through the tracheal ring just below from each end of the horizontal incision to raise a Bjork flap. Resorbable sutures are passed under the cartilagenous ring to fixate the flap to the overlying skin. An appropriately sized tracheostomy tube is inserted atraumatically then stabilized to the neck using a trap. The endotracheal tube may be removed, and the tracheostomy tube cuff inflated.

17. Pediatric OSA

In general, both the prevalence and treatment threshold for OSA in children is lower [65]. Children with AHI greater than 5 should undergo treatment to help normalize breathing. For patients with AHI ranging from 1 to 5, treatment should be considered if OSA-related comorbidities such as obesity, hyperactive behaviors, lymphoid hyperplasia, enuresis, and/or increased inflammatory markers are present [65, 66]. Non-invasive measures like weight loss and avoidance of irritants like tobacco smoking are universally helpful [65].

Most literature indicate an OSA incidence of 1 to 4% [67]. This occurrence peaks between the ages of 2 to 8, which roughly coincides with the peak instances of lymphoid hyperplasia. Traditional treatment therefore consists of tonsillectomy with or without adenoidectomy. However, the success rate may range as low as 27% even though delaying correction of disordered breathing can lead to gnathic or craniofacial anomalies [66]. While removal of tonsillar or adenoidal tissues can be conducted at any age, other surgical interventions may incur a greater rate of complications (in non-syndromic patients) if conducted prior to age 3 or in individuals weighing less than 15 kg [65, 68].

Alternative surgical modalities include septoplasty and UPPP. Osseous surgeries should be reserved for those with craniofacial deficits as extensive osteotomies frequently disrupt the rate and pattern of skeletal growth. Maxillary and/or mandibular distraction may be employed early to utilize the rapid healing potential in children with severe micrognathia [65].

Unlike in adults, CPAP should be reserved for moderate or severe cases of pediatric OSA that cannot be treated surgically [69]. CPAP compliance rate is even lower in children, and a lack of appropriate pediatric CPAP appliances as well as long sleeping hours exacerbate this issue [70]. CPAP can also trigger nasal symptoms such as congestion, epistaxis, and midface retrusion [65]. Patients who cannot tolerate or are refractory to surgery and CPAP should undergo treatment via tracheostomy [69].

18. Surveillance

Post-intervention polysomnography or DISE may be conducted at least 3 months after therapy to reduce confounding effects of post-operative edema. STOP-BANG, Epworth, and/or Berlin questionnaires should also be utilized to ensure improvements in the patient's quality of life.

The Stanford Protocol is a predictable and effective protocol outlining the proper elevation of care in cases of OSA relapse [71]. Surgical management of OSA should begin with the phase 1 treatments consisting of septoplasty, UPPP, then GA. Phase 2 treatment is MMA and may be conducted in case of relapse after phase 1. While phase 2 treatment appears sufficient for most patients, a recent update to the Protocol showed that HGNS could be conducted in cases of phase 2 treatment failure [72]. MMA may prevent lateral pharyngeal wall components of airway collapse, thereby increasing the efficacy of HGNS which best addresses antero-posterior obstructions.

19. Conclusions

Obstructive sleep apnea is a complex disease of numerous significant ramifications which require careful diagnosis and management. As with many chronic conditions, OSA should be first approached via conservative treatment which often remains equally or more effective as their invasive counterparts. Once the reversible conservative modalities are exhausted, the more invasive therapies should be approached with caution. Modern interventional protocols like the Stanford Protocol may provide guidance based on the successes of large volume surgical cohorts.

Acknowledgements

The anatomic figures in this chapter (**Figures 1** through **13**) have been obtained from the work of Drs. Henry Gray and Henry Vandyke Carter within the public domain of the United States of America.

Conflict of interest

The authors declare no conflicts of interest.

Author details

Ho-Hyun (Brian) Sun^{1*} and Sally Sun²

1 University of California, San Francisco – Highland Hospital, Kaiser Permanente Oakland Medical Center, Western University of Health Sciences, College of Dental Medicine, Dublin, California, USA

2 University of the Pacific, Thomas J. Long School of Pharmacy, Kaiser Permanente Dublin Medical Offices and Cancer Center, Dublin, California, USA

*Address all correspondence to: hsun@westernu.edu

IntechOpen

© 2020 The Author(s). Licensee IntechOpen. This chapter is distributed under the terms of the Creative Commons Attribution License (<http://creativecommons.org/licenses/by/3.0>), which permits unrestricted use, distribution, and reproduction in any medium, provided the original work is properly cited. 

References

- [1] Senaratna C V, Perret JL, Lodge CJ, Lowe AJ, Campbell BE, Matheson MC, et al. Prevalence of obstructive sleep apnea in the general population : A systematic review. *Sleep Medicine Reviews*. 2020;34(2017):70-81.
- [2] Franklin KA, Lindberg E. Obstructive sleep apnea is a common disorder in the population-A review on the epidemiology of sleep apnea. Vol. 7, *Journal of Thoracic Disease*. 2015. p. 1311-22.
- [3] Schwab RJ, Kim C, Bagchi S, Keenan BT, Comyn FL, Wang S, et al. Understanding the anatomic basis for obstructive sleep apnea syndrome in adolescents. *American Journal of Respiratory and Critical Care Medicine*. 2015;191(11):1295-309.
- [4] Caporale M, Palmeri R, Corallo F, Muscarà N, Romeo L, Bramanti A, et al. Cognitive impairment in obstructive sleep apnea syndrome: a descriptive review. *Sleep and Breathing*. 2020;
- [5] Pirklbauer K, Russmueller G, Stiebellehner L, Nell C, Sinko K, Millesi G, et al. Maxillomandibular advancement for treatment of obstructive sleep apnea syndrome: A systematic review. *Journal of Oral and Maxillofacial Surgery*. 2011;69(6):e165-76.
- [6] De Miguel-Díez J, Villa-Asensi JR, Álvarez-Sala JL. Prevalence of sleep-disordered breathing in children with down syndrome: Polygraphic findings in 108 children. *Sleep*. 2003;26(8):1006-9.
- [7] Bray GA. What's in a Name? Mr. Dickens' "Pickwickian" Fat Boy Syndrome. *Obesity Research*. 1994;2(4):380-3.
- [8] Sullivan C, Berthon-Jones M, Issa F, Eves L. Reversal of Obstructive Sleep Apnoea by Continuous Positive Airway Pressure Applied Through the Nares. *The Lancet*. 1981;317(8225):862-5.
- [9] Goyal A, Pakhare AP, Bhatt GC, Choudhary B, Patil R. Association of pediatric obstructive sleep apnea with poor academic performance: A school-based study from India. *Lung India : official organ of Indian Chest Society*. 2018;35(2):132-6.
- [10] McNicholas WT. Diagnosis of obstructive sleep apnea in adults. *Proceedings of the American Thoracic Society*. 2008 Feb;5(2):154-60.
- [11] Saboisky JP, Butler JE, Gandevia SC, Eckert DJ. Functional role of neural injury in obstructive sleep apnea. *Frontiers in Neurology*. 2012;JUN (June):1-12.
- [12] Krysta K, Bratek A, Zawada K, Stepańczyk R. Cognitive deficits in adults with obstructive sleep apnea compared to children and adolescents. *Journal of Neural Transmission*. 2017;124:187-201.
- [13] Foldvary-Schaefer NR, Waters TE. Sleep-Disordered Breathing. *CONTINUUM: Lifelong Learning in Neurology*. 2017;23(4).
- [14] Dehlink E, Tan H-L. Update on paediatric obstructive sleep apnoea. *Journal of thoracic disease*. 2016 Feb;8(2):224-35.
- [15] Sleep-Related Breathing Disorders in Adults: Recommendations for Syndrome Definition and Measurement Techniques in Clinical Research. *Sleep*. 1999 Aug 1;22(5):667-89.
- [16] Kapur VK, Auckley DH, Chowdhuri S, Kuhlmann DC, Mehra R, Ramar K, et al. Clinical Practice Guideline for Diagnostic Testing for Adult Obstructive Sleep Apnea. *Journal of Clinical Sleep Medicine*. 2017;13(3):479-504.

- [17] Kotecha B, De Vito A. Drug induced sleep endoscopy: Its role in evaluation of the upper airway obstruction and patient selection for surgical and nonsurgical treatment. *Journal of Thoracic Disease*. 2018;10(1):S40-7.
- [18] Johns MW. A new method for measuring daytime sleepiness: The Epworth sleepiness scale. *Sleep*. 1991;14(6):540-5.
- [19] Netzer NC, Stoohs RA, Netzer CM, Clark K, Strohl KP. Using the Berlin Questionnaire To Identify Patients at Risk for the Sleep Apnea Syndrome. *Annals of Internal Medicine*. 1999 Oct 5;131(7):485-91.
- [20] Vasu TS, Doghramji K, Cavallazzi R, Grewal R, Hirani A, Leiby B, et al. Obstructive Sleep Apnea Syndrome and Postoperative Complications: Clinical Use of the STOP-BANG Questionnaire. *Archives of Otolaryngology–Head & Neck Surgery*. 2010 Oct 18;136(10):1020-4.
- [21] Chiu HY, Chen PY, Chuang LP, Chen NH, Tu YK, Hsieh YJ, et al. Diagnostic accuracy of the Berlin questionnaire, STOP-BANG, STOP, and Epworth sleepiness scale in detecting obstructive sleep apnea: A bivariate meta-analysis. *Sleep Medicine Reviews*. 2017;36(2017):57-70.
- [22] Amra B, Javani M, Soltaninejad F, Penzel T, Fietze I, Schoebel C, et al. Comparison of Berlin Questionnaire, STOP-Bang, and Epworth Sleepiness Scale for Diagnosing Obstructive Sleep Apnea in Persian Patients. *International journal of preventive medicine*. 2018 Mar 9;9:28.
- [23] Stuck BA, Neff W, Hörmann K, Verse T, Bran G, Baisch A, et al. Anatomic changes after hyoid suspension for obstructive sleep apnea: An MRI study. *Otolaryngology - Head and Neck Surgery*. 2005;133(3):397-402.
- [24] Qaseem A, Holty J-EC, Owens DK, Dallas P, Starkey M, Shekelle P. Management of Obstructive Sleep Apnea in Adults: A Clinical Practice Guideline From the American College of Physicians. *Annals of Internal Medicine*. 2013 Oct 1;159(7):471-83.
- [25] Iftikhar IH, Kline CE, Youngstedt SD. Effects of exercise training on sleep apnea: A meta-analysis. *Lung*. 2014;192(1):175-84.
- [26] Azagra-Calero E, Espinar-Escalona E, Barrera-Mora JM, Llamas-Carreras JM, Solano-Reina E. Obstructive sleep apnea syndrome (OSAS). Review of the literature. *Medicina Oral, Patología Oral y Cirugía Bucal*. 2012;17(6).
- [27] Neill AMK, Angus SM, Sajkov D, McEvoy RD. Effects of sleep posture on upper airway stability in patients with obstructive sleep apnea. *American Journal of Respiratory and Critical Care Medicine*. 1997;155(1):199-204.
- [28] Nakano H, Ikeda T, Hayashi M, Ohshima E, Onizuka A. Effects of body position on snoring in apneic and nonapneic snorers. *Sleep*. 2003;26(2):169-72.
- [29] Ward CP, York KM, McCoy JG. Risk of obstructive sleep apnea lower in double reed wind musicians. *Journal of Clinical Sleep Medicine*. 2012;8(3):251-5.
- [30] BUCKS RS, OLAITHE M, EASTWOOD P. Neurocognitive function in obstructive sleep apnoea: A meta-review. *Respirology*. 2013 Jan 1;18(1):61-70.
- [31] Jackson ML, McEvoy RD, Banks S, Barnes M. Neurobehavioral impairment and CPAP treatment response in mild-moderate obstructive sleep apnea. *Journal of Clinical Sleep Medicine*. 2018;14(1):47-56.

- [32] Drager LF, Togeiro SM, Polotsky VY, Lorenzi-Filho G. Obstructive sleep apnea: A cardiometabolic risk in obesity and the metabolic syndrome. *Journal of the American College of Cardiology*. 2013;62(7):569-76.
- [33] Zozula R, Rosen R. Compliance with continuous positive airway pressure therapy: assessing and improving treatment outcomes. *Current opinion in pulmonary medicine*. 2001 Nov;7(6):391-8.
- [34] Morgenthaler TI, Aurora RN, Brown T, Zak R, Alessi C, Boehlecke B, et al. Practice parameters for the use of autotitrating continuous positive airway pressure devices for titrating pressures and treating adult patients with obstructive sleep apnea syndrome: An update for 2007 - An American Academy of Sleep Medicine Report. *Sleep*. 2008;31(1):141-7.
- [35] Ramar K, Dort LC, Katz SG, Lettieri CJ, Harrod CG, Thomas SM, et al. Clinical Practice Guideline for the Treatment of Obstructive Sleep Apnea and Snoring with Oral Appliance Therapy: An Update for 2015. *Journal of clinical sleep medicine : JCSM : official publication of the American Academy of Sleep Medicine*. 2015 Jul 15;11(7):773-827.
- [36] Pantin CC, Hillman DR, Tennant M. Dental side effects of an oral device to treat snoring and obstructive sleep apnea. *Sleep*. 1999;22(2):237-40.
- [37] Gaisl T, Haile SR, Thiel S, Osswald M, Kohler M. Efficacy of pharmacotherapy for OSA in adults: A systematic review and network meta-analysis. *Sleep Medicine Reviews*. 2019;46(2019):74-86.
- [38] Fenik P, Veasey SC. Pharmacological characterization of serotonergic receptor activity in the hypoglossal nucleus. *American journal of respiratory and critical care medicine*. 2003;167(4):563-9.
- [39] Carley DW, Olopade C, Ruigt GS, Radulovacki M. Efficacy of mirtazapine in obstructive sleep apnea syndrome. *Sleep*. 2007;30(1):35-41.
- [40] Kraiczi H, Hedner J, Dahlöf P, Ejnell H, Carlson J. Effect of serotonin uptake inhibition on breathing during sleep and daytime symptoms in obstructive sleep apnea. *Sleep*. 1999;22(1):61-7.
- [41] Carley DW, Radulovacki M. Role of Peripheral Serotonin in the Regulation of Central Sleep Apneas in Rats. *Chest*. 1999;115(5):1397-401.
- [42] Sukys-Claudino L, Moraes W, Guilleminault C, Tufik S, Poyares D. Beneficial effect of donepezil on obstructive sleep apnea: A double-blind, placebo-controlled clinical trial. *Sleep Medicine*. 2012;13(3):290-6.
- [43] Hein H, Behnke G, Jörres RA, Magnussen H. The therapeutic effect of theophylline in mild obstructive sleep Apnea/Hypopnea syndrome: results of repeated measurements with portable recording devices at home. *European journal of medical research*. 2000 Sep;5(9):391-9.
- [44] Prasad B, Radulovacki M, Olopade C, Herdegen JJ, Logan T, Carley DW. Prospective trial of efficacy and safety of ondansetron and fluoxetine in patients with obstructive sleep apnea syndrome. *Sleep*. 2010;33(7):982-9.
- [45] Carley DW, Prasad B, Reid KJ, Malkani R, Attarian H, Abbott SM, et al. Pharmacotherapy of apnea by cannabimimetic enhancement, the PACE clinical trial: Effects of dronabinol in obstructive sleep apnea. *Sleep*. 2018;41(1).
- [46] Weaver EM, Maynard C, Yueh B. Survival of Veterans With Sleep Apnea: Continuous Positive Airway Pressure Versus Surgery. *Otolaryngology-Head*

and Neck Surgery. 2004 Jun 1;130(6):659-65.

[47] Lin H-C, Friedman M, Chang H-W, Gurpinar B. The Efficacy of Multilevel Surgery of the Upper Airway in Adults With Obstructive Sleep Apnea/Hypopnea Syndrome. *The Laryngoscope*. 2008 May 1;118(5):902-8.

[48] Stuck BA, Leitzbach S, Maurer JT. Effects of continuous positive airway pressure on apnea-hypopnea index in obstructive sleep apnea based on long-term compliance. *Sleep and Breathing*. 2012;16(2):467-71.

[49] Venekamp RP, Hearne BJ, Chandrasekharan D, Blackshaw H, Lim J, Schilder AG. Tonsillectomy or adenotonsillectomy versus non-surgical management for obstructive sleep-disordered breathing in children (Review) SUMMARY OF FINDINGS FOR THE MAIN COMPARISON. *The Cochrane Library*. 2015;(10):CD011165.

[50] Pinder DK, Wilson H, Hilton MP. Dissection versus diathermy for tonsillectomy. *Cochrane Database of Systematic Reviews*. 2011;

[51] Windfuhr JP, Chen YS, Remmert S. Hemorrhage following tonsillectomy and adenoidectomy in 15,218 patients. *Otolaryngology-Head and Neck Surgery*. 2005 Feb 1;132(2):281-6.

[52] Li H-Y, Wang P-C, Chen Y-P, Lee L-A, Fang T-J, Lin H-C. Critical Appraisal and Meta-Analysis of Nasal Surgery for Obstructive Sleep Apnea. *American Journal of Rhinology & Allergy*. 2011 Jan 1;25(1):45-9.

[53] Mickelson SA. Nasal Surgery for Obstructive Sleep Apnea Syndrome. *Otolaryngologic Clinics of North America*. 2016;49(6):1373-81.

[54] Yousuf A, Beigh Z, Khursheed RS, Jallu AS, Pampoori RA.

Clinical predictors for successful uvulopalatopharyngoplasty in the management of obstructive sleep apnea. *International journal of otolaryngology*. 2013/09/19. 2013;2013:290265.

[55] Mickelson SA. Hyoid advancement to the mandible (hyo-mandibular advancement). *Operative Techniques in Otolaryngology - Head and Neck Surgery*. 2012;23(1):56-9.

[56] Cheng A. Genioglossus and Genioplasty Advancement. *Atlas of the Oral and Maxillofacial Surgery Clinics of North America*. 2019;27(1):23-8.

[57] Liao YF, Chiu YT, Lin CH, Chen YA, Chen NH, Chen YR. Modified maxillomandibular advancement for obstructive sleep apnoea: Towards a better outcome for Asians. *International Journal of Oral and Maxillofacial Surgery*. 2015;44(2):189-94.

[58] PRINSELL JR. Maxillomandibular advancement surgery for obstructive sleep apnea syndrome. *The Journal of the American Dental Association*. 2002 Nov 1;133(11):1489-97.

[59] Zaghi S, Holty JEC, Certal V, Abdullatif J, Guilleminault C, Powell NB, et al. Maxillomandibular advancement for treatment of obstructive sleep apnea ameta-analysis. *JAMA Otolaryngology - Head and Neck Surgery*. 2016;142(1):58-66.

[60] Liu SYC, Awad M, Riley RW. Maxillomandibular Advancement: Contemporary Approach at Stanford. *Atlas of the Oral and Maxillofacial Surgery Clinics of North America*. 2019;27(1):29-36.

[61] Strollo PJ, Soose RJ, Maurer JT, De Vries N, Cornelius J, Froymovich O, et al. Upper-airway stimulation for obstructive sleep apnea. *New England Journal of Medicine*. 2014;370(2):139-49.

- [62] Ferlito A, Rinaldo A, Shaha AR, Bradley PJ. Percutaneous Tracheotomy. *Acta Oto-Laryngologica*. 2003 Sep 1;123(9):1008-12.
- [63] Klemm E, Nowak AK. Tracheotomy-related deaths-a systematic review. *Deutsches Arzteblatt International*. 2017;114(16).
- [64] Simon M, Metschke M, Braune SA, Püschel K, Kluge S. Death after percutaneous dilatational tracheostomy: A systematic review and analysis of risk factors. *Critical Care*. 2013;17(5).
- [65] Ahn YM. Treatment of obstructive sleep apnea in children. *Korean Journal of Pediatrics*. 2010;53(10):872-9.
- [66] Guilleminault C, Lee JH, Chan A. Pediatric Obstructive Sleep Apnea Syndrome. *Archives of Pediatrics & Adolescent Medicine*. 2005 Aug 1;159(8):775-85.
- [67] Marcus CL, Chapman D, Ward SD, McColley SA, Herrerias CT, Stillwell PC, et al. Clinical practice guideline: Diagnosis and management of childhood obstructive sleep apnea syndrome. *Pediatrics*. 2002;109(4):704-12.
- [68] Katz ES, D'Ambrosio CM. Pathophysiology of pediatric obstructive sleep apnea. *Proceedings of the American Thoracic Society*. 2008;5(2):253-62.
- [69] Powell S, Kubba H, O'Brien C, Tremlett M. Paediatric obstructive sleep apnoea. *BMJ (Online)*. 2010;340(7754):1018-23.
- [70] Marcus CL, Rosen G, Davidson Ward SL, Halbower AC, Sterni L, Lutz J, et al. Adherence to and effectiveness of positive airway pressure therapy in children with obstructive sleep apnea. *Pediatrics*. 2006;117(3).
- [71] Holty JEC, Guilleminault C. Maxillomandibular advancement for the treatment of obstructive sleep apnea: A systematic review and meta-analysis. *Sleep Medicine Reviews*. 2010;14(5):287-97.
- [72] Liu SY, Riley RW. Continuing the Original Stanford Sleep Surgery Protocol From Upper Airway Reconstruction to Upper Airway Stimulation: Our First Successful Case. *Journal of Oral and Maxillofacial Surgery*. 2017;75(7):1514-8.