
Effects of Posture and Gravity on Pelvic Organ Prolapse

Marwa Abdulaziz, Lynn Stothers and
Andrew Macnab

Additional information is available at the end of the chapter

<http://dx.doi.org/10.5772/intechopen.77040>

Abstract

Female pelvic floor dysfunction occurs when the integrity of the pelvic floor muscles is compromised and impacts the position and function of the pelvic organs. Physicians use international guidelines to evaluate and treat women for POP taking into account that posture and gravity impact pelvic organ position, and degree of prolapse. Our clinical focuses on the description of surface anatomy. This examination alone is insufficient. Although imaging is recommended, the modalities currently available are recognized to have flaws. MRI is performed in the supine position regardless the effect of posture and gravity on POP. A literature search was performed using databases, searching MEDLINE and PubMed using the key terms ultrasound, MRI, and CT. We describe use of a new protocol and advanced technique to evaluate the changes of POP in different positions using open MRI (MRO). POP patients underwent MRO imaging of the pelvic floor using a 0.5 T MRO scanner. The extent of displacement of prolapsed organs was determined using validated reference lines drawn on the mid-sagittal images. Manual segmentation and surface modeling were used to construct the 3D models. MRO offers new levels of anatomic detail; 3D sequences based on 2D images are an additional refinement.

Keywords: magnetic resonance imaging, upright open MRI, ultrasound, CT scan, 3D computer generated image

1. Introduction

Female pelvic floor dysfunction is a widespread condition where the associated symptoms of urinary and fecal incontinence negatively impact the quality of life of many women. The life time risk of surgery for pelvic organ prolapse (POP) in women is estimated as 10–20%.

Despite the pervasiveness, our information about the etiology and pathophysiology of female pelvic floor dysfunction is limited, as evaluation is primarily based on physical examination using international guidelines [1]. Imaging is recommended in addition, but current methods are not able to assess the effects of posture and gravity, factors recognized to impact pelvic organ position, pelvic floor muscle integrity, degree of prolapse, and symptom severity. Importantly, the degree of prolapse may be worse after a lengthy time in the upright position and better when gravity is not a factor, e.g., when lying in the supine position.

The first imaging of pelvic floor dysfunction was done in the 1920s [2]. Radiological techniques were first used to show bladder manifestations and subsequently for central and posterior compartment prolapse [3]. The advent of B-mode real-time ultrasound presented a technique that allowed for a clear image by the transperineal or the vaginal route [4, 5]. Later, magnetic resonance imaging (MRI) emerged as an option. Although MRI provided imaging of ligamentous and muscular pelvic floor structures in fine detail, the cost of imaging, access problems, and restriction to imaging patients in the supine position have obstructed its general acceptance [6].

Most recently, upright open MRI has become available, which allows the patient to be imaged when sitting or standing as well as supine [7]. We have conducted research literature search that has allowed a protocol to be developed for using upright open MRI to more comprehensively evaluate patients with POP and demonstrate where posture and gravity have impact on organ positions and symptom severity.

2. Pelvic organ prolapse

Pelvic organ prolapse (POP) is a prevalent condition affecting up to 50% of parous women; it most often presents with symptoms of urinary incontinence [8]. Traditionally, gynecologists identify prolapse by using a simple clinical staging system (stages 0 to III or IV), with 0 indicating normal conditions and III or IV denoting full organ prolapse or vaginal eversion (POP-Q staging for POP (POP-Q)).

The accuracy of staging is important, as the treatment or surgery recommended to the patient is based on the staging of their POP. However, surgical repair of prolapse has a failure rate as high as 30%, and this is probably due to current pre-surgical evaluation providing incomplete assessment of the extent of the underlying structural changes causing the prolapse, resulting in incomplete repair. For instance, the levator ani muscle complex plays an important role in pelvic organ support. Evaluation of the integrity of this element of the pelvic structures is particularly difficult, and clinical examination alone is often insufficient [9].

Physicians assess patients using guidelines from organizations such as the International Urogynecological Association (IUGA) and International Continence Society (ICS) to evaluate women for POP and define treatment options to address the associated urinary and fecal incontinence.

The guidelines recommend steps for physical examination of symptomatic women which recognize that whether the patient is standing, sitting, or lying affects the position of the pelvic organs and the type, occurrence, and severity of symptoms. Hence, examination is done with

the woman's bladder (and preferably rectum) empty, using the left lateral (Sims), or supine, standing, or lithotomy position, depending on which best demonstrates POP in that patient, and which the patient confirms is the maximal extent she has perceived. Forced expiration against a closed glottis (Valsalva) increases the accuracy of diagnosis CHANGE REFERENCE to a recent one/update the reference [10].

However, problematically, not all women can Valsalva effectively or tolerate examination when upright, and the guidelines acknowledge that "the more complicated the history and the more extensive and/or invasive the proposed therapy, the more complete the examination needs to be" [11]. Hence, further evaluation using imaging modalities is recommended when the appropriate indication(s) are present, with imaging highly recommended in specific situations. (IUGA) Imaging modalities employed currently include 2D and 3D ultrasound (US), computed tomography (CT), and magnetic resonance imaging (MRI).

Current research on the association between childbirth-related pelvic floor muscle trauma and female POP provides an example of how imaging can aid better understanding of the pathophysiology of pelvic floor dysfunction [12–15], allowing primary (inflatable balloon device) [16] and secondary (surgical repair) prevention trials, and if all goes well resulting in efficient treatment based on translational research [17, 18].

Clinical examination focuses primarily on surface anatomy, which alone is not able to fully detect the extent of the underlying structural abnormalities. For example, prolapse of the posterior vagina, which is most prevalent in women with symptoms of prolapse and obstructed defecation is called "rectocele", and it occurs in at least five distinct anatomical forms that are hard to define without imaging [19]. Improved imaging of the pelvic floor to quantify and determine pelvic floor support has been identified as an important method to improve our understanding of POP, aid our ability to perform surgical repair, and to define the causes for surgical failure [20]. However, the position of the levator ani within the pelvic cavity, encircled as this structure is by the bony pelvis, and its shape, make direct imaging complex.

The differences between cystocele, enterocele, and rectocele are also difficult to determine with physical examination and are much better evaluated with imaging. Imaging also can discover unsuspected defects like enteroceles and sigmoidoceles [21]. The discovery rate of enteroceles is less with physical examination than with imaging; this is because of the misdiagnosis of enteroceles as rectoceles [22].

The role of imaging is to identify clinically suspected problems, discriminate between different anatomic defects, and define unsuspected problems in pelvic floor support. In patients with non-specific clinical findings, MRI can provide additional information to assess the need for surgical repair of the pelvic floor [21].

3. Patient positioning

The relevance of posture on the extent of POP and severity of associated symptoms is well recognized. However, investigation of the influence of the body posture on pelvic floor pathologies and defecation has been done in only a few studies. Dynamic pelvic floor imaging is performed in

the supine position with patients lying in a closed-configuration MR scanner [23]. The principal reason for this is the limitation on imaging to the supine position. Lying supine is also comfortable for most patients, and this technique has been simple to standardize. However, in POP, posture and gravity impact pelvic organ position, pelvic floor muscle integrity, degree of prolapse, and symptom severity. Indeed, the degree of prolapse may be worse after a lengthy time in the upright position and better when gravity is not a factor, e.g., when lying in the supine position [10]. Hence, one could question if measurement in the lying position is valid for assessment of muscle function or the evaluation of patients who are symptomatic in the standing position [24].

Additionally, gravity and body weight contribute to pelvic organ muscle contractile features when standing [25]. It is likely that complex factors related to upright posture that produce more contractility over pre-loaded and/or pre-activated muscles come into play, as the weight of pelvic organs and gravity are contributing forces affecting the pelvic floor. This may explain why digital muscle testing and squeeze-pressure readings can be lower in the standing position. However, it is not known exactly which components of pelvic organ muscle activation — squeeze or lift — are influenced by alterations in posture.

Hypothetically speaking, the dynamics of the whole pelvic floor may be modified (or the squeeze and the elevation components might be influenced variously) owing to different effects such as descent of the pelvic organs when standing, different tensions on fascia and ligaments, alteration in resting length and tone of the contractile elements, and other factors.

It is well known that being upright results in a displacement of the pelvic organs and the pelvic organs muscle as compared with being supine [24, 26]. The full bladder is less mobile than the empty organ this factor may prohibit complete pelvic organ prolapse. In the standing orientation, the bladder is situated lower at rest but descends about as far in a lying patient on a Valsalva maneuver [27]. Dietz and Clarke [27] in their population of 132 patients with pelvic floor dysfunction found a 5-mm difference in the resting level of the bladder neck between supine and standing as measured by transperineal ultrasound. The only study comparing MRI in sitting and lying positions found that they were equally efficient in recognizing clinically relevant problems of the pelvic floor [28].

The position and eventual prolapse of pelvic organs is best visualized on MRI in the midsagittal plane. The imaging technique for the pelvic floor involves imaging several pelvic floor positions. Firstly, the position of the pelvic organs is assessed at rest. Then, the pelvic floor muscles images are recorded during squeezing to view the contractility and the strength of contraction of the pelvic floor. In the third phase, pelvic floor pathologies are assessed during straining and evacuation. In a recent study to view the full extent of pelvic floor pathologies, imaging was done during evacuation of a contrast agent; a number of pathologic conditions would have been missed if these defecation phase images had not been acquired [29].

4. Current imaging techniques

Evaluation using imaging modalities is recommended in international guidelines when the appropriate indication(s) are present, and imaging is highly recommended in specific

situations [10]. Imaging modalities employed currently include 2D and 3D ultrasound, computed tomography, and magnetic resonance imaging.

4.1. Ultrasound

Imaging the pelvic floor in cases of dysfunction dates back to the 1920s [2]. Radiological techniques were used first to show changes in the bladder's location within the pelvis and subsequently to demonstrate central and posterior compartment prolapse. During the 1980s the advent of B-mode real-time ultrasound allowed a clear image to be obtained by the transperineal or the vaginal route [19].

Translabial ultrasound can define uterovaginal prolapse [30]. The inferior border of the symphysis pubis works as a line of reference against which the higher descent of bladder, uterus, culde sac, and rectal ampulla on Valsalva maneuver can be measured [30]. Ultrasound imaging for prolapse quantification is especially helpful in outcome evaluation after pelvic reconstructive surgery, both clinically and in a research context, and it has also led to a re-appraisal of what is meant by prolapse.

The structures used for evaluation of the three compartments are (a) the bladder neck or the leading edge of a cystocele for the anterior vaginal wall, (b) the cervix (or, within certain limitations, the pouch of Douglas) for the central compartment, and (c) the rectal ampulla for the posterior compartment. All these structures are imaged in real time in the mid-sagittal plane. An exception is a high undescended uterus that may be hidden by a rectocele [10]. Because of its non-invasive nature, ready availability, and lack of distortion, perineal or translabial ultrasound is now commonly applied in clinical practice [30], and almost all gynecologists and urologists are trained in its use [19].

Current developments such as the evaluation of levator ani muscle activity and prolapse and the use of color Doppler to define urine leakage are further promoting the clinical utility of ultrasound. Hopefully, improved standardization of parameters will facilitate the ability of clinicians and researchers to compare data [30].

Regardless of which technique is used to define descent of the pelvic organs, it is obvious that there is a large difference in pelvic organ mobility even in young nulliparous women. This difference may be partially genetic in origin. Ultrasound imaging permits quantification of the wide variation in pelvic organ mobility, which will make it easier to use molecular and population genetic approaches to assess the etiology of pelvic floor and bladder dysfunction [30].

It seems to be irrelevant with chapter title Ultrasound imaging of the pelvic floor is safer, lower in cost, and better at providing visualization of the pelvic floor structures in real time than MRI. This includes evaluation of levator function and dynamic changes during contraction and Valsalva [20]. As yet, there are no comparisons of pre- and postnatal results gained with MRI, possibly because of cost and logistic problems. However, such a comparison is available for many hundreds of women studied by 4D translabial ultrasound [2].

Disadvantages of ultrasound include that a large bowel-filled prolapse, i.e., an enterocele or rectocele, may cause incomplete imaging of the cervix and vault if these structures remain

high. In addition, variable transducer pressure can result in an underestimation of severe prolapse. Procidentia or complete vaginal eversion prevents translabial imaging, and sometimes what appears to be anterior vaginal wall prolapse will turn out to be due to a urethral diverticulum [31, 32].

4.2. CT scan

CT is not usually recommended for imaging the pelvic floor because of the level of radiation required. However, this modality can offer accurate visualization of the pelvic soft tissue and bony structures and has been used to increase the diagnostic accuracy of pelvic floor anatomical disorders [1]. Although the soft tissue contrast with CT is inferior to that of MRI, the bladder, uterus, small bowel, peritoneal fat, and rectum are readily identified, and changes in position with the patient straining can be visualized. Additionally, the contour of the levator ani muscles can be evaluated effectively, and images of pelvic anatomy can be produced in multiple planes. Therefore, in patients who cannot tolerate MRI and in whom rapid noninvasive multiplanar assessment of the pelvis is desired, CT has a potential role. With recent scanners, tube output can be modified depending on the patient's body thickness, and this may help to decrease the radiation dose given. The pelvic floor and viscera can be visualized, and the addition of dynamic imaging can be applied to determine prolapse [33].

4.3. MRI

Techniques associated with urology have developed over the last 30 years. In the 1990s MR techniques were improved with rapid and strong gradients and higher readout bandwidth. The first study depicting the using of MR for imaging pelvic organ prolapse was by Yang et al.

The increasing availability of MRI has added the benefit of this form of diagnostic imaging to evaluation in urogynecology and female urology, with more studies being done every year [30]. With the option of cross-sectional imaging methods, MRI has emerged as an alternate method to fluoroscopy for assessing patients with pelvic organ prolapse [34].

Benefits of MRI include multiplanar imaging and superior soft tissue contrast, permitting evaluation of the pelvic floor levator ani muscle in detail. The anatomy of the levator ani is now known to be complex; it has been shown not to be a single muscle, being composed of two functional components that differ in thickness and function [20]. In addition, where there is organ prolapse, enhanced visualization of the rectovaginal space improves diagnosis of peritoneoceles and enteroceles and of the cervix clarifies cervical descent [33]. This allows demonstration of enterocele-type defects or peritoneoceles where there is just herniation of peritoneal fat and not bowel, comprehensive evaluation of the levator ani muscle, and visualization of the uterus.

The position and relationship of the pelvic organs are best visualized on MRI in the midsagittal plane. The imaging technique for the pelvic floor involves imaging in various pelvic floor positions. Firstly, the position of the pelvic organs is assessed at rest. Then, the pelvic floor muscles images are recorded during squeezing to view the contractility and the strength of contraction of the pelvic floor. In the third phase, pelvic floor pathologies are assessed during

straining and evacuation. In a recent study to view the full extent of pelvic floor pathologies imaging was done during evacuation of a contrast agent; a number of pathologic conditions would have been missed if these defecation phase images had not been acquired [29].

Dynamic MRI techniques have been shown to be more sensitive than pelvic examination in evaluating and grading pelvic floor displacement in supine women and also for diagnosis of rectoceles [35, 42]. In the case of an anorectal problem, MR defecography can identify several components of pelvic floor dysfunction, including rectal descent, enterocele, anterior proctocoele, and internal rectal prolapse [36].

The short acquisition time is relevant because patients do not need to keep on straining for more than 1 to 3 s. Patients are instructed in the Valsalva maneuver before the start of the examination, and instructions are repeated frequently during the imaging sequence [37, 38]. Dynamic sequences that permit the acquisition of images in 1 to 10 s are helpful to obtain maximal strain [39].

Sometimes, patients cannot tolerate MRI due to claustrophobia, general weakness, or the presence of medical equipment [33]. Positive elements of MRI include the fact that filling the bladder, the vagina, or the rectum does not seem to be a fundamental requirement because of the high resolution of MRI, which prevents distorting the anatomy of the pelvic organs [40]. Also, in a research context, MRI is acceptable to asymptomatic volunteers [40].

The expense of MRI imaging and limited access to scanning facilities has impacted widespread application of this technology. Additionally, because of the dynamic nature of pelvic floor pathology, it is controversial whether even fast MRI imaging can capture reproducible results owing to the dissimilarity of Valsalva maneuvers between studies and possible variations in levator activity [10].

The physical features of MRI systems make it complicated for the operator to ensure efficient conduct of the required maneuvers by patients; over 50% of women do not achieve a proper pelvic floor contraction during examination, and a Valsalva is very often confounded by associated levator ani activation [41]. Without real-time imaging, these confounders cannot be controlled for [2] upright open MRI.

Importantly this provides the ability to replicate normal functional posture and enables the effects of gravity on prolapse to be evaluated for the first time [7]. In POP, posture and gravity impact pelvic organ position, pelvic floor muscle integrity, degree of prolapse, and symptom severity, and the degree of prolapse may be worse after time in the upright position and better when gravity is not a factor, e.g., when lying in the supine position [1]. Near-real-time sequences allow images to be obtained every 1.5 s. These can be stored and displayed on video, enabling a dynamic assessment of the pelvic floor from the resting position through straining and contraction [40]. The gynecologic literature proposes that straining in the lying position does not give sufficient deformity of the pelvic floor for accurate delineation of prolapse.

Upright open MRI allows visualization of all the pelvic organs and the pelvic floor support structures; obviously the technique combines the advance of allowing sitting and standing imaging with the known benefits of conventional MRI. We believe that the importance of this

technique is that it enables comprehensive definition of the full extent of organ prolapse due to the effects of posture and gravity [40].

Upright open MRI is currently only available as a research entity. A new clinical protocol for MRO image capture of the female pelvis has been created and introduced into clinical practice. This provides enhanced anatomic definition and allows more comprehensive evaluation and staging.

5. Reference lines

Image interpretation from conventional and upright open MRI evaluates the three compartments of the pelvic floor [43]. The three compartments are evaluated for morphologic changes such as POP at various pelvic floor positions. To define the existence and descent of POP, the use of a point of reference is beneficial. Several points and lines of reference for measuring POP have been reported [44]. The more commonly used lines are the pubococcygeal line (PCL) and the mid-pubic line (MPL), both applied on midsagittal images. The PCL is the line drawn from the inferior part of the symphysis pubis to the last coccygeal joint. Extending the posterior portion of the PCL to the sacrococcygeal joint also has been proposed because there is movability of the coccyx with straining [21]. The MPL is a line extending along the long axis of the symphysis pubis. The PCL represents the levator plate, while the MPL correlates with the level of the hymen, which is the landmark applied for clinical staging [45]. To measure pelvic organ prolapse a perpendicular line is drawn from the reference line (PCL or MPL) to the bladder base (anterior compartment), the cervix or vaginal vault (middle compartment), and the anal rectal junction (ARJ) (posterior compartment) [23].

Another classification system, H line, M line, organ prolapse (HMO), has been proposed for measuring prolapse [35]. The H line is drawn from the pubis to the posterior anorectal junction and measures the levator hiatus width. Organ prolapse is measured relative to that line. The M line measures the descent of the levator plate from the pubococcygeal line. The angle of the levator plate relative to the pubococcygeal line and the width and part of the pelvic hiatus on axial images can be measured as well [22].

The choice of which reference line is used is mostly made by the radiologist and/or the referring clinician, as neither of the two lines has shown distinct superiority [44]. The PCL, however, is the most-used reference line, particularly by surgeons and gastroenterologists. The MPL is better known among urogynecologists, as it is compatible with their clinical staging system. Both reference lines display only moderate to poor agreement with clinical staging of pelvic organ prolapse [38]. This might be partly because anatomical landmarks used for MR measurements and for clinical examination differed in most of the studies [23]. Standards exist for diagnosing prolapse on physical examination [1]. Congruity between this clinical standard and MRI imaging analysis should be used to document the utility of MRI and the success of treatment [22].

However, different criteria are currently used for diagnosing prolapse on MRI. Most research that reported using the bony reference lines uses one of the following criteria: (a) descent of the bladder base more than 1 cm inferior to the pubococcygeal line, (b) position of the cervix or vaginal vault less than 1 cm over the PCL or below it, and (c) descent of the posterior compartment more than 2.5 cm below the PCL (International Urogynecological Association and International Continence Society) [1]. There are also other minor differences in the diagnostic criteria applied for prolapse; cystocele has been defined as when the bladder descends to any area below the PCL, and uterocervical prolapse and enterocele are when the cervix or small bowel are below the PCL .

6. Proposed protocol for upright open MRI evaluation of POP

Based on our literature search research, the protocol we propose for upright open MRI evaluation of women with prolapse and stress urinary incontinence is as follows. (1) All women complete a history that includes validated symptom scores for bladder, bowel, and prolapse-related symptoms. (2) Patients have a physical examination that follows IUGA/ICS guidelines [10]; this examination includes POPQ staging. (3) Patients complete a screening assessment tool to ensure there are no contraindications for magnetic resonance imaging. Some metals and surgical hardware are ferromagnetic and, therefore, are not acceptable with MRI. (4). Imaging is then conducted.

Our images are obtained currently using a 0.5 T scanner located at a dedicated research facility at the Centre for Hip Health at the University of British Columbia, Canada. Each patient's preparation includes ensuring a full bladder; hence, they are asked to refrain from voiding for 2 h before imaging. For standing images, intermittent pneumatic compression devices are applied to the legs. A T2-weighted sagittal image of the midline structures, including the symphysis, urethra, and coccyx, is acquired. Women then empty the bladder, and images in the supine, seated, and upright position are obtained. Current settings based on pilot studies indicate successful imaging is obtained with the following: TR/effective TE, 2500/16; echo train length, 32; bandwidth, 32 kHz; excitation, one; matrix size, 256 × 160; field of view, 0.5 (24 cm); section thickness, 5 mm, slice gap, 1. Sagittal images for mobility of the bladder neck and urethra can be obtained during straining [46].

7. Proposed clinical scenario for imaging

As an example of the benefits of this protocol, a 60-year-old multiparous woman presented with increasing urinary incontinence, constipation, a sensation of incomplete emptying, pelvic pressure, and pain. On pelvic examination (supine and inclined, at rest, and with Valsalva), no organ descent was detected. Conventional supine magnetic resonance imaging (MRI) did not identify pelvic organ prolapse (POP), but evaluation using upright open MRI diagnosed that organ prolapse involving the bladder occurred when standing. In **Figure 1** an example of anterior views of sagittal images showing gravity-induced quantification prolapse can be

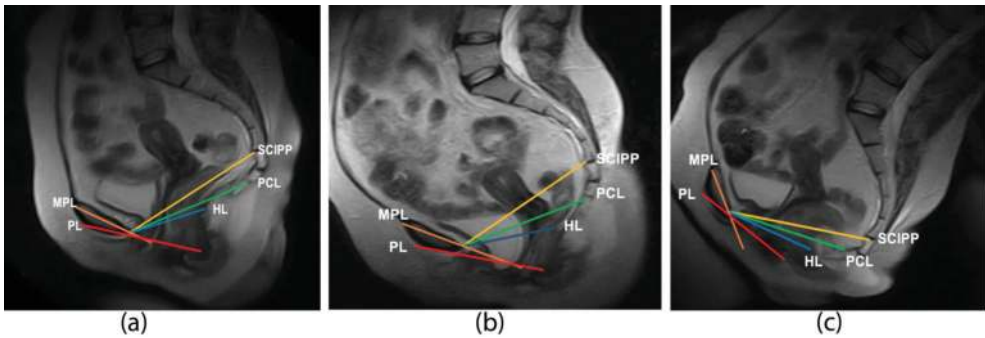


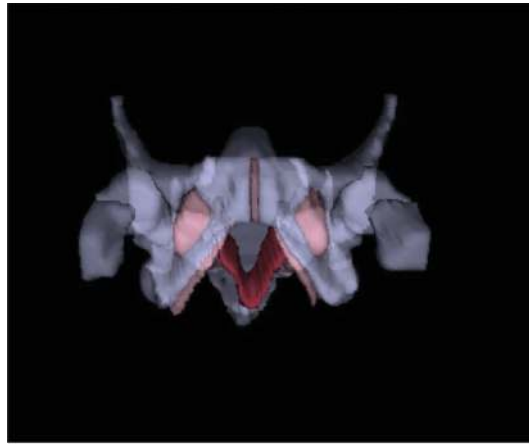
Figure 1. Anterior views of sagittal images show gravity-induced quantification prolapse. When a supine midsagittal single-shot fast SE image obtained at 0.5 T (panel A) and the corresponding image in standing (panel B) T2-weighted sagittal images of the female midline pelvic floor structures are compared, elongation of the bladder below the pubococcygeal reference line identifies significant prolapse when this patient is standing. A) Sagittal MRI image of female pelvis in the supine position, B) Sagittal MRI image of female pelvis in the standing position, C) Sagittal MRI image of female pelvis in the sitting position.

seen. When a supine midsagittal single-shot fast SE image obtained at 0.5 T (Panel A) and the corresponding image in standing (Panel B) also the corresponding image in sitting position (Panel C) T2-weighted sagittal images of the female midline pelvic floor structures are compared, elongation of the bladder below the pubococcygeal reference line identifies significant prolapse when this patient is standing.

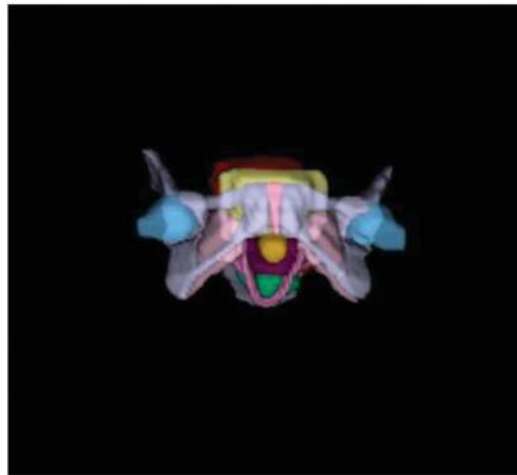
8. 3D computer-generated images

An additional component for more comprehensive evaluation of POP is to generate 3D images. After mid-sagittal pelvic MRI scans are complete, the images are transmitted to a workstation for processing to generate 3D models. On average, 40 axial images were combined to generate each 3D model. The data were first segmented to anatomically major components, including bladder, urethra, vagina, uterus, rectum, obturator internus, and all three components of the levator ani (puborectalis, iliococcygeus, and coccygeus) using manual editing. Old reference 3D reconstruction is labor intensive and hence costly. However, the resulting images yield a huge amount of detailed information that simply cannot be obtained from 2D images. Moreover, use of mathematical modeling will be helpful in the future to assist in defining the relationships of organs and quantifying mobility and pressure gradients to resolve questions of continence and pelvic floor prolapse [47]. Further, advantages of 3D reconstruction include the additional data provided for patient–clinician interaction to enhance understanding, more comprehensive surgical planning, and to advance medical research, and education [46]. A three-dimensional model of the levator can be produced for living individuals and muscle volume calculated old reference.

The limitations include high cost and relative complexity of acquiring the initial images and the requirement for computer hardware and dedicated software [46]. Examples of the 3D imaging of the female pelvic floor can be seen in **Figure 2**.



(A)



(B)

Figure 2. Three-dimensional imaging of the female pelvic floor: (A) anterior view of 3D pelvic floor model: (gray, pelvic bones), (pink, obturator internus m, piriformis m), (red, levator ani m). (B) Anterior view of 3D reconstruction of the whole female pelvis: (yellow, bladder, urethra), (red, uterus), (pink, vagina), (blue, rectum) as segmented from MRI images. A) Anterior view of 3D pelvic floor model as segmented from MRI images. B) Anterior view of 3D computer model of the whole female pelvis including supporting structures and organs.

9. Conclusions

Physicians should be aware that as upright open MRI becomes available this form of imaging will offer new levels of anatomic details relevant to a more accurate staging of POP and improved allocation to medical or surgical treatment. In POP, posture and gravity impact

pelvic organ position, pelvic floor muscle integrity, degree of prolapse, and symptom severity. Importantly, while guidelines for clinical evaluation include recognition of the effects of posture, current imaging modalities are not always able to capture this aspect of prolapse. Ultrasound is a practical and widely available imaging modality. In patients who cannot bear MRI, CT may be beneficial as an alternate diagnostic process, but radiation is high. MRI provides multiplanar imaging and superior soft tissue contrast, permitting evaluation of the pelvic floor levator ani muscle in detail, but current imaging is limited to the supine position.

Reference lines related to bony anatomical landmarks allow prolapse to be quantified. 3D image reconstruction from 2D MRI images provides information beyond that acquired from 2D studies. Our upright open MRI imaging and 3D protocol makes comprehensive diagnostic imaging available that improves the accuracy of diagnosis and staging of POP.

Author details

Marwa Abdulaziz^{1*}, Lynn Stothers² and Andrew Macnab²

*Address all correspondence to: sonah_2008@hotmail.com

1 Department of Experimental Medicine, University of British Columbia, Vancouver, Canada

2 Department of Urological Sciences, University of British Columbia, Vancouver, Canada

References

- [1] Haylen BT, Maher CF, Barber MD, Camargo S, Dandolu V, et al. An international urogynecological association (IUGA)/international continence society (ICS) joint report on the terminology for female pelvic organ prolapse (POP). *International Urogynecology Journal*. 2016;**27**(4):655-684
- [2] Dietz HP. Pelvic floor ultrasound in prolapse: What's in it for the surgeon? *International Urogynecology Journal*. 2011;**22**(10):1221-1232
- [3] Jeffcoate TN, Roberts H. Observations on stress incontinence of urine. *American Journal of Obstetrics and Gynecology*. 1952;**64**(4):721-738
- [4] Kohorn EI, Scioscia AL, Jeanty P, Hobbins JC. Ultrasound cystourethrography by perineal scanning for the assessment of female stress urinary incontinence. *Obstetrics and Gynecology*. 1986;**68**(2):269-272
- [5] Grischke EM, Dietz HP, Jeanty P, Schmidt W. A new study method: The perineal scan in obstetrics and gynecology. *Ultraschall in der Medizin*. 1986;**7**(4):154-161
- [6] Dohke M, Mitchell DG, Vasavada SP. Fast magnetic resonance imaging of pelvic organ prolapse. *Techniques in Urology*. 2001;**7**(2):133-138

- [7] Friedman B, Stothers L, Lazare D, Macnab A. Positional pelvic organ prolapse (POP) evaluation using open, weight-bearing magnetic resonance imaging (MRI). *Canadian Urological Association Journal*. 2015;**9**(5-6):197-200
- [8] Nygaard I, Barber MD, Burgio KL, Kenton K, Meikle S, et al. Prevalence of symptomatic pelvic floor disorders in US women. *JAMA*. 2008;**300**(11):1311-1316. DOI: 10.1001/jama.300.11.1311
- [9] Bo K, Finckenhagen HB. Vaginal palpation of pelvic floor muscle strength: Inter-test reproducibility and comparison between palpation and vaginal squeeze pressure. *Acta Obstetrica et Gynecologica Scandinavica*. 2001;**80**(10):883-887
- [10] Barasinski C, Vendittelli F. Effect of the type of maternal pushing during the second stage of labour on obstetric and neonatal outcome: A multicentre randomised trial—The EOLE study protocol. *BMJ Open* 2016;**6**:e012290. DOI: 10.1136/bmjopen-2016-012290
- [11] Abrams P, Andersson KE, Birder L, Brubaker L, Cardozo L, et al. Fourth international consultation on incontinence recommendations of the international scientific committee: Evaluation and treatment of urinary incontinence, pelvic organ prolapse, and fecal incontinence. *Neurourology and Urodynamics*. 2010;**29**(1):213-240
- [12] Dietz HP, Lanzarone V. Levator trauma after vaginal delivery. *Obstetrics and Gynecology*. 2005;**106**(4):707-712
- [13] Dietz HP, Steensma AB. The prevalence of major abnormalities of the levator ani in urogynaecological patients. *BJOG : An International Journal of Obstetrics and Gynaecology*. 2006;**113**(2):225-230
- [14] DeLancey JOL, Morgan DM, Fenner DE, Kearney R, Guire K, et al. Comparison of levator ani muscle defects and function in women with and without pelvic organ prolapse. *Obstetrics and Gynecology*. 2007;**109**(2 Pt 1):295-302
- [15] Shek KL, Dietz HP. Intrapartum risk factors for levator trauma. *BJOG : An International Journal of Obstetrics and Gynaecology*. 2010;**117**(12):1485-1492
- [16] Shek KL, Chantarasorn V, Langer S, Phipps H, Dietz HP. Does the Epi-no birth trainer reduce levator trauma? A randomised controlled trial. *International Urogynecology Journal*. 2011;**22**(12):1521-1528
- [17] Dietz HP, Gillespie AV, Phadke P. Avulsion of the pubovisceral muscle associated with large vaginal tear after normal vaginal delivery at term. *The Australian & New Zealand Journal of Obstetrics & Gynaecology*. 2007;**47**(4):341-344
- [18] Dietz HP, Shek KL, Daly O, Korda A. Can levator avulsion be repaired surgically? A prospective surgical pilot study. *International Urogynecology Journal*. 2013;**24**(6): 1011-1015
- [19] Dietz HP. Pelvic floor ultrasound: A review. *American Journal of Obstetrics and Gynecology*. 2010;**202**(4):321-334

- [20] Athanasiou S, Chaliha C, Tooze-Hobson P, Salvatore S, Khullar V, Cardozo L. Direct imaging of the pelvic floor muscles using two-dimensional ultrasound: A comparison of women with urogenital prolapse versus controls. *BJOG: An International Journal of Obstetrics and Gynaecology*. 2007;**114**(7):882-888
- [21] Tunn R, Paris S, Taupitz M, Hamm B, Fischer W. MR imaging in posthysterectomy vaginal prolapse. *International Urogynecology Journal and Pelvic Floor Dysfunction*. 2000; **11**(2):87-92
- [22] Pannu HK. Magnetic resonance imaging of pelvic organ prolapse. *Abdominal Imaging*. 2002;**27**(6):660-673
- [23] Reiner CS, Weishaupt D. Dynamic pelvic floor imaging: MRI techniques and imaging parameters. *Abdominal Imaging*. 2013;**38**(5):903-911
- [24] Bo K, Finckenhagen HB. Is there any difference in measurement of pelvic floor muscle strength in supine and standing position? *Acta Obstetrica et Gynecologica Scandinavica*. 2003;**82**(12):1120-1124
- [25] Parkkinen A, Karjalainen E, Vartiainen M, Penttinen J. Physiotherapy for female stress urinary incontinence: Individual therapy at the outpatient clinic versus home-based pelvic floor training: A 5-year follow-up study. *Neurourology and Urodynamics*. 2004; **23**(7):643-648
- [26] Hendrix SL, Clark A, Nygaard I, Aragaki A, Barnabei V, McTiernan A. Pelvic organ prolapse in the Women's Health Initiative: Gravity and gravidity. *American Journal of Obstetrics and Gynecology*. 2002;**186**(6):1160-1166
- [27] Dietz HP, Clarke B. The influence of posture on perineal ultrasound imaging parameters. *International Urogynecology Journal and Pelvic Floor Dysfunction*. 2001;**12**(2):104-106
- [28] Bertschinger KM, Hetzer FH, Roos JE, Treiber K, Marincek B, Hilfiker PR. Dynamic MR imaging of the pelvic floor performed with patient sitting in an open-magnet unit versus with patient supine in a closed-magnet unit. *Radiology*. 2002;**223**(2):501-508
- [29] Flusberg M, Sahni VA, Erturk SM, Mortele KJ. Dynamic MR defecography: Assessment of the usefulness of the defecation phase. *AJR. American Journal of Roentgenology*. 2011; **196**(4):W394-W399
- [30] Dietz HP. Ultrasound imaging of the pelvic floor. Part I: Two-dimensional aspects. *Ultrasound in Obstetrics & Gynecology*. 2004;**23**(1):80-92
- [31] Mouritsen L, Bernstein I. Vaginal ultrasonography: A diagnostic tool for urethral diverticulum. *Acta Obstetrica et Gynecologica Scandinavica*. 1996;**75**(2):188-190
- [32] Siegel CL, Middleton WD, Teefey SA, Wainstein MA, McDougall EM, Klutke CG. Sonography of the female urethra. *AJR. American Journal of Roentgenology*. 1998; **170**(5):1269-1274
- [33] Pannu HK, Genadry R, Kaufman HS, Fishman EK. Computed tomography evaluation of pelvic organ prolapse. Techniques and applications. *Journal of Computer Assisted Tomography*. 2003;**27**(5):779-785

- [34] Kaufman HS, Buller JL, Thimpson RJ, Pannu HK, DeMeester SL, et al. Dynamic pelvic magnetic resonance imaging and cystocolpoproctography alter surgical management of pelvic floor disorders. *Diseases of the Colon and Rectum*. 2001;**44**(11):1575-1583. discussion 1583-4
- [35] Comiter CV, Vasavada SP, Barbaric ZL, Gousse AE, Raz S. Grading pelvic prolapse and pelvic floor relaxation using dynamic magnetic resonance imaging. *Urology*. 1999; **54**(3):454-457
- [36] Pizzoferrato AC, Nyangoh Timoh K, Fritel X, Zareski E, Bader G, Fauconnier A. Dynamic magnetic resonance imaging and pelvic floor disorders: How and when? *European Journal of Obstetrics, Gynecology, and Reproductive Biology*. 2014;**181**:259-266
- [37] Fauconnier A, Zareski E, Abichedid J, Bader G, Falissard B, Fritel X. Dynamic magnetic resonance imaging for grading pelvic organ prolapse according to the international continence society classification: Which line should be used? *Neurourology and Urodynamics*. 2008;**27**(3):191-197
- [38] Woodfield CA, Hampton BS, Sung V, Brody JM. Magnetic resonance imaging of pelvic organ prolapse: Comparing pubococcygeal and midpubic lines with clinical staging. *International Urogynecology Journal and Pelvic Floor Dysfunction*. 2009;**20**(6):695-701
- [39] Fritel X, Fauconnier A, Bader G, Cosson M, Debodinance P, et al. Diagnosis and management of adult female stress urinary incontinence: Guidelines for clinical practice from the French College of Gynaecologists and Obstetricians. *European Journal of Obstetrics, Gynecology, and Reproductive Biology*. 2010;**151**(1):14-19
- [40] Law PA, Danin JC, Lamb GM, Regan L, Darzi A, Gedroyc WM. Dynamic imaging of the pelvic floor using an open-configuration magnetic resonance scanner. *Journal of Magnetic Resonance Imaging*. 2001;**13**(6):923-929
- [41] Orno AK, Dietz HP. Levator co-activation is a significant confounder of pelvic organ descent on Valsalva maneuver. *Ultrasound in Obstetrics & Gynecology*. 2007;**30**(3):346-350
- [42] Dvorkin LS, Hetzer F, Scott SM, Williams NS, Gedroyc W, Lunniss PJ. Open-magnet MR defaecography compared with evacuation proctography in the diagnosis and management of patients with rectal intussusception. *Colorectal Disease*. 2004;**6**(1):45-53
- [43] Roos JE, Weishaupt D, Wildermuth S, Willmann JK, Marincek B, Hilfiker PR. Experience of 4 years with open MR defecography: Pictorial review of anorectal anatomy and disease. *Radiographics*. 2002;**22**(4):817-832
- [44] Broekhuis SR, Fütterer JJ, Barentsz JO, Vierhout ME, Kluivers KB. A systematic review of clinical studies on dynamic magnetic resonance imaging of pelvic organ prolapse: The use of reference lines and anatomical landmarks. *International Urogynecology Journal and Pelvic Floor Dysfunction*. 2009;**20**(6):721-729
- [45] Singh K, Reid WM, Berger LA. Assessment and grading of pelvic organ prolapse by use of dynamic magnetic resonance imaging. *American Journal of Obstetrics and Gynecology*. 2001;**185**(1):71-77

- [46] Abdulaziz M, Deegan EG, Kavanagh A, Stothers L, Pugash D, Macnab A. Advances in basic science methodologies for clinical diagnosis in female stress urinary incontinence. *Canadian Urological Association Journal*. 2017;**11**(6Suppl2):S117-S120
- [47] Otcenasek M, Krofta L, Baca V, Grill R, Kucera E, et al. Bilateral avulsion of the puborectal muscle: Magnetic resonance imaging-based three-dimensional reconstruction and comparison with a model of a healthy nulliparous woman. *Ultrasound in Obstetrics & Gynecology*. 2007;**29**(6):692-696