

Poster N° P-SU-084

IMPLANT THERAPY
OUTCOMES; SURGICAL
ASPECTS

Use of a new hd-PTFE membrane in alveolar socket preservation (Permamem®): a case series

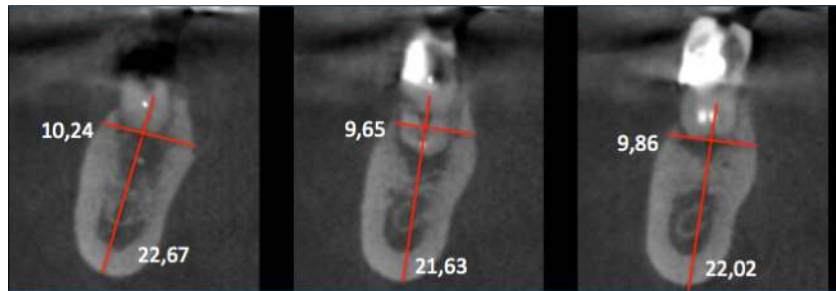


Jean Michel HEURTEBISE²
Séverine VINCENT-BUGNAS^{1,2,3}

¹Université Côte d'Azur, UFR Odontologie, Département de Parodontologie, 24 Avenue des diables bleus, 06300 Nice
²Centre Hospitalier Universitaire de Nice, Pôle d'Odontologie, 5 Rue Pierre Dévoluy, 06000 Nice
³Université Côte d'Azur, Laboratoire MICORALIS EA7534, 24 Avenue des diables bleus, 06300 Nice, France

Abstract

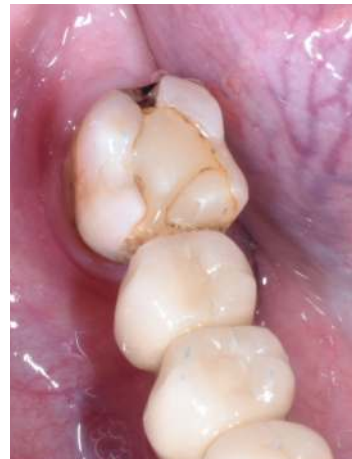Following a tooth extraction there is a post-extractional bone resorption. This is why alveolar socket preservation technique is recommended to limit this pattern and to ensure the bone volume for an eventually implant prosthetic restoration. We want to check if an alveolar socket preservation is possible with no attempt of primary wound closure using a high density PTFE membrane (Permamem®) exposed to the oral environment. Five patients aged from 23 to 61 who needed an extraction of a molar were chosen. In all cases a CBCT scanner was done before the extraction. Once the atraumatic extraction was completed, the alveolar socket was filled with a xenogenic bone graft (BioOss, Geistlich) and covered with a high density PTFE membrane. There was no attempt of fully coverage of the membrane. Three months later another CBCT scanner was realised. No infection was registered for any of the patients and we obtained a total average of horizontal bone loss of 0.42mm and 0.55mm of vertical bone increase. These results might indicate that this high density PTFE membrane is secure in an exposed alveolar socket preservation technique.



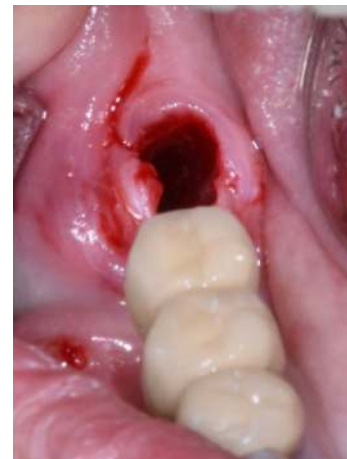CBCT Scanner. Initial situation.

Methods and Materials

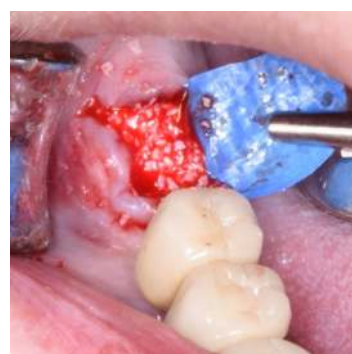
Our case series include five patients aged from 23 to 61, non smokers and with no particular health issue, requiring the extraction of at least one molar. We made an alveolar socket preservation using a xenogenic bone graft (BioOss, Geistlich) and covered with a high density PTFE membrane (Permamem, Botiss Dental) and with no attempt to achieve a gingival cover of it. So, after the atraumatic extraction and after cleaning the socket thoroughly, we adapted the shape of the membrane to the socket. We created buccal and lingual full thickness pockets with an elevator without vertical incisions to slide the membrane in. Then we stabilized it. Once the socket was filled with the bone graft, we covered it completely with the hd PTFE membrane and made a vestibular-lingual cross mattress suture. We left the membrane exposed to oral environment. Patients were followed 1, 2 and 4 weeks after the grafting and during this last visit, the membrane was removed with a pair of tweezers. CBCT was done 3 months later.



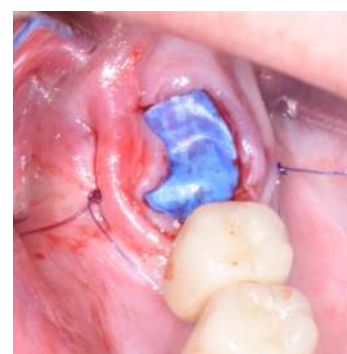
Initial situation.



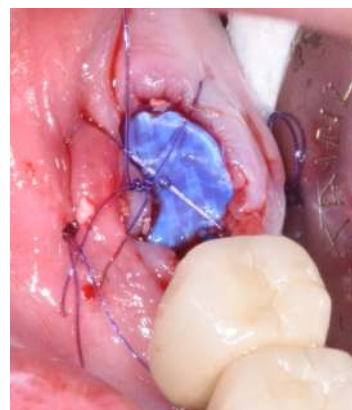
Post-extractional alveolar socket.



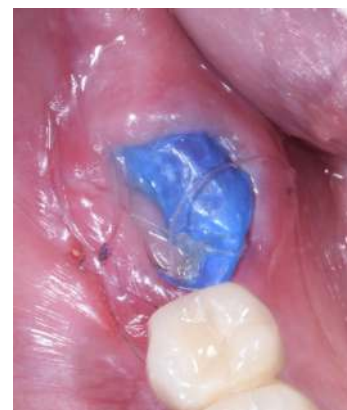Alveolar socket filled.



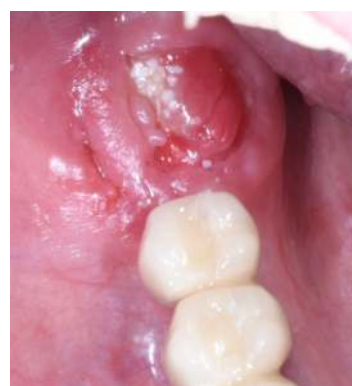Bone graft coverage and membrane stabilization.



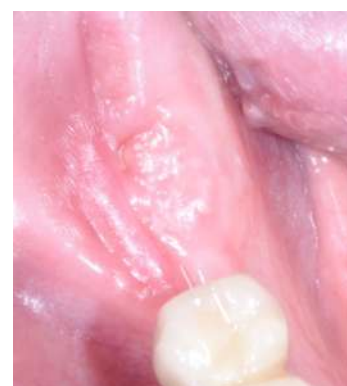Cross mattress suture.



One month post-surgical.



One month post-surgical. Membrane removal.



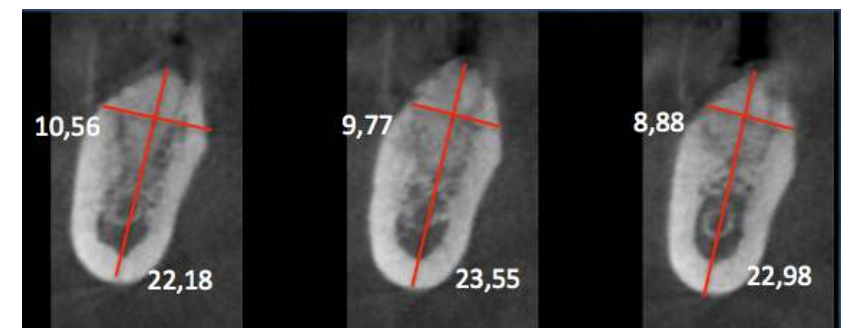Three months post-surgical.

Results

For all five patients, no infection has been revealed during the whole surveillance period, specially during the first month when the membrane remained in place. At the membrane removal, we observed the presence of the osteoid tissue indicating the beginning of the new bone formation. Two months after grafting, we already saw an epithelized gingival tissue covering the extraction site. The mucogingival level remained stable during the whole treatment time. The dimensional comparison between initial and final CBCT scanners in Buccal-Lingual aspects (Δ BL) and Corono-Apical (Δ CA) are shown as follows:

	Δ BL	Δ CA
Case 1	-0.73mm	+1.16mm
Case 2	-0.88mm	-1.33mm
Case 3	-0.18mm	+0.79mm
Case 4	+0.86mm	+0.05mm
Case 5	-1.17mm	+2.12mm

That means that we obtained a total average of horizontal bone loss of 0.42mm and 0.55mm of vertical bone increase.



CBCT Scanner. Three months post-surgical.

Background and Aim

In order to limit post-extractional bone resorption, the alveolar socket preservation is preconised. The use of different types of bone grafts (autogenous, allogenic, xenogenic or synthetic) and membranes (resorbable or non resorbable) compels us to a primary wound closure in most of the cases to protect it from the bacterial contamination. To do so, a coronally advanced flap might be necessary, which leads to a decrease of keratinised tissue height and higher morbidity for the patient.

The aim of this case series is to evaluate the results at 3 months postoperatively of alveolar bone preservation and soft tissue healing using a high-density polytetrafluoroethylene (hd-PTFE) membrane named Permamem® (Botiss Dental) and a xenogenic bone graft.

Conclusion

It seems that this new hd-PTFE membrane is usefull in alveolar socket preservation situations thanks to its non bacterial permeability which enables a non wound primary closure. Keratinised tissue remains in place, there are no particular postoperative complaints in term of pain and swelling and most of all the alveolar socket dimensions are preserved. That means that we will be able to put an implant prosthetic restorations in optimal conditions.

References

- Cheon GB, Kang KL, Yoo MK, Yu JA, Lee DW Alveolar ridge preservation using allografts and dense polytetrafluoroethylene membranes with open membrane technique in unhealthy extraction socket J Oral Implantol. 2017 Aug;43(4)
- Arbab H, Greenwell H, Hill M, Morton D, Vidal R, Shumway B, Allan ND Ridge Preservation comparing a nonresorbable PTFE membrane to a resorbable collagen membrane: a clinical and histologic study in humans Implant Dent. 2016 Feb (1)
- Walker CJ, Prihoda TJ, Mealey BL, Lasho DJ, Noujeim M, Huynh-Ba G Evaluation of healing at molar extraction sites with and without ridge preservation: A randomized controlled clinical trial J Periodontol. 2017 Mar;88(3)
- Sun DJ, Lim HC, Lee DW Alveolar ridge preservation using an open membrane approach for sockets with bone deficiency: A randomized controlled clinical trial Clin Implant Dent Relat

Presented at

EAO
CONGRESS
EUROPEAN ASSOCIATION FOR OSSEointegration

Lisbon
2019