
Central Venous Catheter-Induced Cardiac Arrhythmias in Neonates

Lakshmi Prabha, Anwar Khan, Mahmoudh Galal,
Yaser El Saba and Karnika Senthilkumar

Additional information is available at the end of the chapter

<http://dx.doi.org/10.5772/intechopen.74559>

Abstract

Central venous catheter (CVC) placement or peripherally inserted central catheters are a common bedside procedure, which is frequently performed in critically ill neonates. Even though it is a routine procedure in the neonatal critical care unit, it is not uncommon to have complications related to it. Due to the smaller size of the heart in neonates and premature infants, the usual anatomic landmark and distance from the insertion site may not be accurate. As they are commonly performed at bedside, fluoroscopic guidance would not be possible. In this chapter, we describe common cardiac arrhythmias induced by these CVC lines and practical tips to avoid these complications. Proper measurement with correct technique, proper fixation and vigilant watching for migration will reduce the incidence of these complications. It is mandatory that all bedside intensivists should think of central line induced arrhythmias in an ICU settings and should identify and treat it appropriately.

Keywords: central venous catheter, PICC line, UVC, cardiac arrhythmia, atrial flutter, SVT, adenosine

1. Introduction

Central venous catheter (CVC) placement or peripherally inserted central catheters (PICC) are a very common bedside procedure in the neonatal intensive care unit (NICU). It forms the vital part of the ongoing management of preterm and sick term neonates. Though this has many advantages, it is not uncommon to encounter complications associated with the central lines. The main advantages of PICC lines include attainment of minimal handling, a long-term intravenous

access for parenteral nutrition, the ability to transfuse hyperosmolar fluids, the opportunity to inject important drugs with PH less than 6 (e.g., vancomycin) or more than 8 (e.g., phenytoin) and continuous infusions like prostaglandins, irritants (calcium gluconate) and extended antibiotic therapy [1, 2, 11, 12]. These PICC lines are made of silicone or polyurethane. The preferred site of insertion is from the antecubital vein, cephalic vein, basilic vein or the long saphenous vein. The goal is to place the catheter tip at the level of superior vena cava (SVC) or inferior vena cava (IVC). The optimal placement of PICC lines in SVC should be 0.5–1 cm away from the cardiac silhouette in preterm and 1–2 cm away from the cardiac silhouette in term neonates [1]. This could help us in reducing the dreadful cardiac complications induced by PICC lines. All neonatal intensivists involved in taking decisions for insertion of central venous catheterization such as PICC or umbilical venous catheterization (UVC) should be aware of potential risk factors for complications. This helps to prevent or minimize the complication rate.

The aim of the chapter is to describe the common complications of central venous catheter with focus on arrhythmic complications. The timing and proposed mechanisms of malpositioned intracardiac catheter-induced arrhythmias are also explained. Common types of arrhythmias (atrial flutter and supraventricular tachycardia) secondary to the intracardiac catheters are explained with an outline of its basic management. Finally, practical tips are discussed to minimize the arrhythmic complications of central venous catheters.

2. Complications of centrally placed venous catheters

Any venous catheters tip placed in the lower half or lower one-third of SVC/at or above the level of the diaphragm in IVC is called as centrally placed venous catheters, which commonly includes PICC line/umbilical venous catheter.

Above are the X-rays showing PICC line in an accepted position (**Figure 1**), PICC line in the right atrium (**Figure 2**), and PICC line looping within the cardiac chamber (**Figure 3**).

Although it is a common procedure in the neonatal critical care unit, it is not uncommon to have complications related to it. Due to the smaller size of the heart in neonates and premature infants, the usual anatomic landmark and distance from the insertion site may not be accurate. As they are commonly performed at bedside, fluoroscopic guidance would not be possible.

There are only a few randomized control clinical trials for PICC line use in neonates. The precise rate of complications of central venous catheters in neonates is unclear due to underreporting [5]. The reported incidence of PICC line induced complications from a compilation of various case reports varies from 0 to 33% [3]. Complications can be due to mechanical, vascular, cardiac and/or miscellaneous reasons. The most common mechanical complications are occlusion (reported as 30%), which can be minimized by inserting the smallest catheters into the larger veins. Vascular complications include phlebitis, bleeding from the insertion site, extravasation, and catheter-related venous thrombosis. It can be reduced through the atraumatic catheter insertion technique (slow and controlled technique), good compression immediately after insertion and accurate placement of the catheter in the vena cava [3, 5]. Migration

of a properly placed catheter is not unusual to encounter and it may precipitate significant arrhythmias. A prospective study of 100 PICCs where catheter tip was evaluated at 24 h of post insertion revealed that 32.6% of catheters are migrated toward the heart and migration is more common in upper extremity PICC lines (47%) [4]. Peripheral dislodgement of catheters, catheter damage, catheter leakage/breakage and catheter fractures can occur. The above complications can be decreased with proper, transparent fixation of catheter end and more importantly fixation of its extension set [3]. Cardiac tamponade, myocardial perforation, and valve injury are commonly associated with curved or kinked intracardiac placement of centrally placed catheters. These complications can be minimized by making sure that the catheter tip is straight before insertion and most importantly adjusting the catheter position outside the

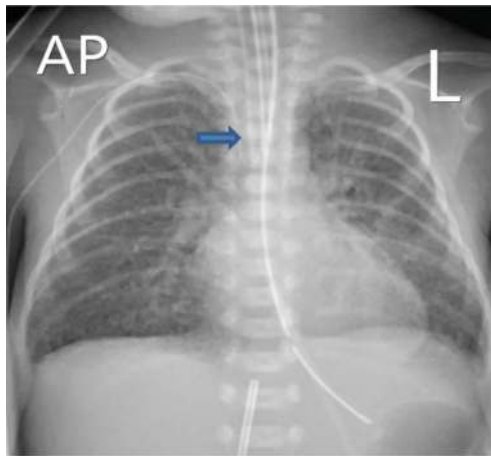


Figure 1. PICC line—optimal position. Chest X-ray showing right PICC line in SVC—0.5 cm away from the cardiac silhouette an optimal position.

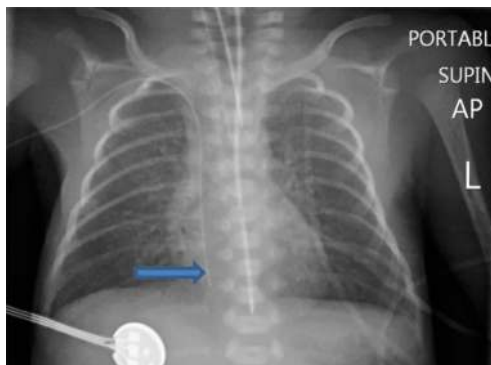


Figure 2. PICC line in the right atrium. Chest X-ray showing right PICC line in the right atrium.

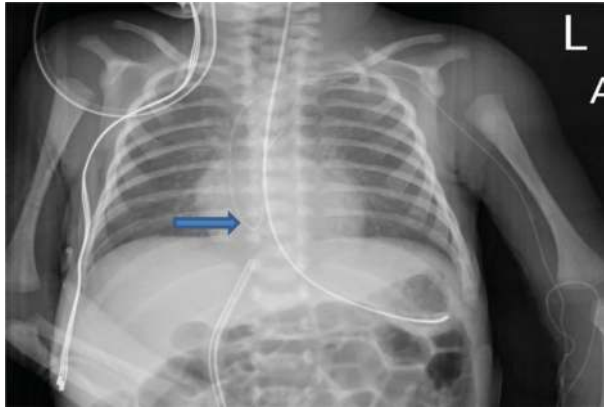


Figure 3. PICC line with intracardiac looping. Chest X-ray shows left PICC line passed superior vena cava, got looped in right atrium.

cardiac shadow immediately after taking X-ray. After adjustment of the catheter tip, confirmatory X-ray is mandatory. Massive pleural effusion and pericardial effusion has been reported following an inappropriately placed PICC lines [1, 14].

3. Arrhythmic complications of PICC line

The innate properties of neonatal myocardium predispose to different types of arrhythmia. Cardiac arrhythmias are rare but potentially life-threatening. Hence, should be identified and intervened immediately by the bedside neonatologist, especially when it occurs with an indwelling central venous catheter. Even though many neonatal literature mentions about the risk of arrhythmias with centrally placed catheters in neonates, the incidence is less known. Until now 16 cases of central venous catheter-induced arrhythmias are reported, with tachyarrhythmias being the commonest form. The most common arrhythmias reported so far are atrial flutter (8/16) and supraventricular tachycardia (7/16) [6, 7].

3.1. The timing of arrhythmias with the central line

Arrhythmias may occur anytime, from the time of insertion of central catheters till the time of withdrawal (Table 1).

1. Procedural phase: due to advancement beyond SVC. It commonly happens due to improper measurement. Willful over advancement of the catheter into the intracardiac chamber with the hope to withdraw the catheter after radiographic confirmation is one of the common practices which should be forbidden.
2. Securing phase—migration to the intracardiac chamber can occur due to handling during the time of fixation.

3. Anytime at the indwelling phase due to migration/dislodgement of central venous catheters.

Cases were documented from within few minutes after insertion till 47 days post insertion of central venous catheter (CVC) [16, 17].

3.2. Proposed mechanism of arrhythmia induction

Typically the etiology lies on inappropriately placed intracardiac catheters in all the cases.

The possible mechanisms are

1. **Direct contact of the catheter with SA node/atrial musculature:** direct contact may induce a triggered activity or increased automaticity. For example, direct contact with the endocardium may induce few premature atrial beats, which in the presence of an accessory pathway or dual AV node pathway may trigger a SVT.
2. **Mechanical irritation of intracardiac chambers (especially atria) during the passage:** this will predispose to the development of an accessory or re-entrant pathway [6].
3. **Subsequent edema and inflammation**—would prolong the duration of arrhythmia which may explain the presence of arrhythmia for few days even after withdrawal of catheter away from the heart.

3.3. Types of cardiac arrhythmias induced by intracardiac central venous catheter

Malpositioned, migrated or inappropriately placed central venous catheter can cause a wide range of arrhythmias ranging from tachyarrhythmias to bradyarrhythmias as mentioned in **Figure 4**.

3.3.1. Tachyarrhythmia

Tachyarrhythmias are abnormal fast rhythms originating from atria or from ventricles of the heart. With intracardiac indwelling catheters, tachyarrhythmias are more common than bradyarrhythmias. Recognition of tachyarrhythmia is crucial for any intensivist. If not identified in time, it may end up with congestive cardiac failure due to significantly compromised cardiac output due to incessant tachycardia. Cardiogenic shock may happen due to

Serial number	Time phase	Possible reason
1	Procedural phase	1.Improper measurement 2.Willful over advancement
2	Secure phase	Migration of catheters can happen due to handling at the time of fixation
3	Indwelling phase	Migration and dislodgement

Table 1. Timing of development of arrhythmias with central line.

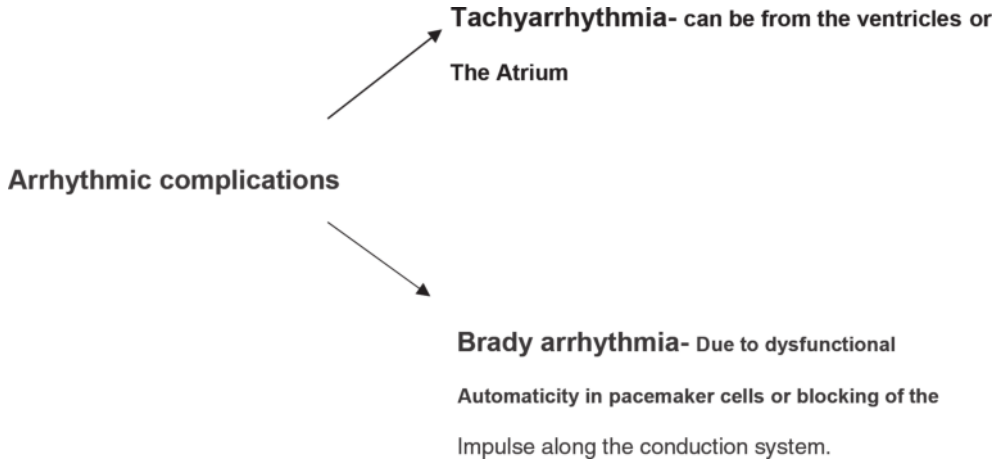


Figure 4. Types of Cardiac arrhythmias induced by centra lines.

Age	Awake rate (bpm)	Mean	Sleeping rate
Newborn to 3 months	85–205	140	80–160

Table 2. Normal heart rate variations in neonates.

prolonged myocardial hypoxia. It manifests as effortless tachypnoea, tachycardia (earliest sign), poor perfusion, prolonged capillary refill time, bilateral crepitations and hypotension (late sign).

Knowledge of normal heart rate is essential before diagnosing any tachyarrhythmia. Normal heart rate varies in newborn widely (**Table 2**).

Normal sinus rhythm: normal heart rate for a newborn varies from 120 to 205 in an awake state. Normal sinus rhythm is characterized by upright P wave in lead I and a VF which is followed by narrow QRS complexes.

3.4. Classification of tachyarrhythmia

Tachyarrhythmia is classified into supraventricular tachycardia/atrial tachyarrhythmia, junctional tachycardia and ventricular tachycardia depending on where the arrhythmic impulses emanate from (**Figure 5**). Any of the mentioned tachyarrhythmia depicted in **Figure 5** can occur due to above-mentioned mechanisms.

For clinical purpose, tachyarrhythmias are classified based on QRS complex in the ECG (**Table 3**).

The essential part of treating any tachyarrhythmia is based on differentiating different types of tachyarrhythmia like sinus tachycardia, supraventricular tachycardia, atrial flutter and

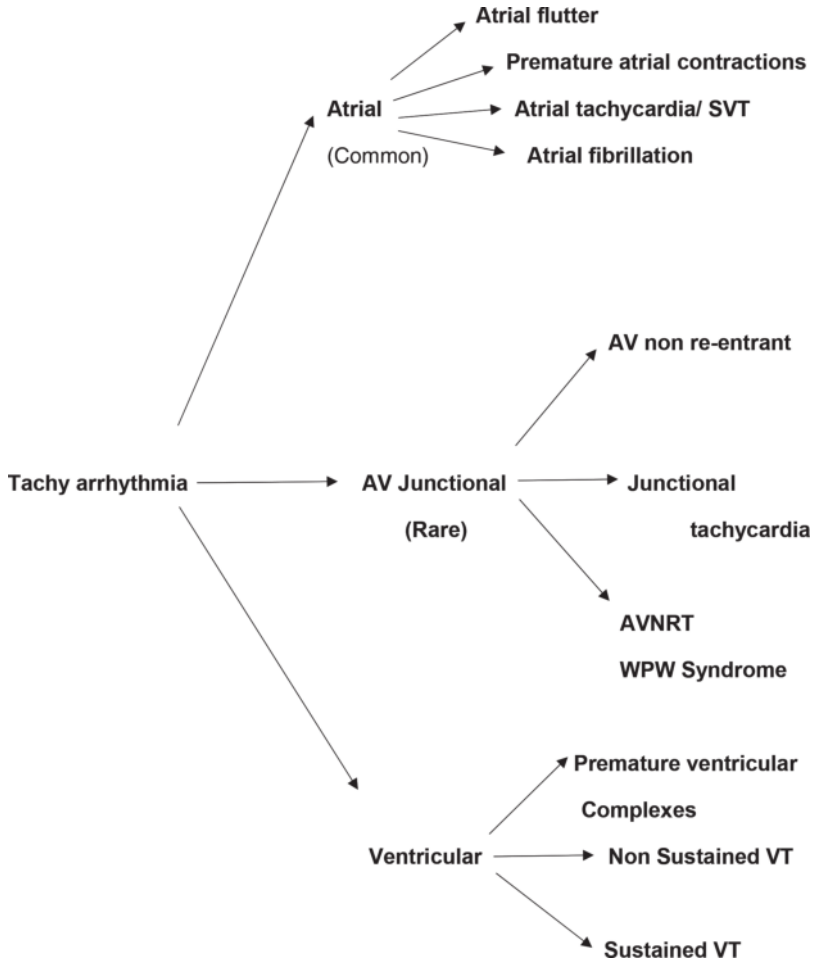


Figure 5. Types of Tachyarrhythmias.

Narrow QRS complex (≤ 80 ms)	Wide QRS complex (> 80 ms)
1. Sinus tachycardia	1. Ventricular tachycardia
2. Atrial flutter	2. Supraventricular tachycardia with aberrant conduction
3. Supraventricular tachycardia	

Table 3. Clinical classification of tachyarrhythmias.

ventricular tachycardia. The management is different for each type of tachyarrhythmia. Important arrhythmias induced by central lines are described here, explaining other rare forms are out of the scope of this chapter.

3.4.1. Sinus tachycardia

Sinus tachycardia can arise at the rate of 180–220 bpm. It arises due to stimulation of SA node typically due to body's response to the need of increased cardiac output. It can arise in response to any stress, pain, hyperthermia, anemia, commonly used drugs like caffeine and more. It must be differentiated from other pathological causes by means of Normal P waves, variable R-R interval, constant PR interval, precipitating factors like fever, sepsis, and failure to respond with vagal maneuvers.

3.4.2. Atrial tachycardia

Atrial tachycardia arises when the impulses emanate from the atrium, specifically the right atrium. Atrial excitations have a very low threshold potential in preterm infants. Thereby whenever irritated by any mechanical stimuli, for example, a central venous catheter, atrial tachyarrhythmia occurs more often. The true two forms of atrial tachycardia are atrial flutter and atrial ectopy.

3.4.2.1. Atrial flutter

Atrial flutter is the common rhythm induced by the intracardiac position of PICC line and an awareness of this pattern is crucial for a neonatologist. Atrial flutter is best described by regular rapid atrial rates of 240–360 beats/min. The electrocardiogram (ECG) will show a regular rhythm with a sawtooth pattern of P waves otherwise known as the typical flutter waves. It is best seen in lead II, lead III and aVF leads with a long strip ECG. The QRS complex will be narrow if there is no aberrant pathway (**Figure 6**).

In neonates, atrial flutter commonly causes 2:1 AV conduction block. It may also cause various degrees of AV block. Atrial flutter in a non-catheter related context is less common than SVT. So it is potentially prone to under-recognition. A 12-h time of incessant tachycardia is enough to decompensate the hemodynamic status of a neonate. The chances of developing cardiac failure depend on the duration of arrhythmia, structural nature of the heart and gestational age rather than the rate alone. One has to quickly recognize atrial flutter and able to differentiate from SVT as the treatment option varies for both, with synchronized cardioversion for atrial flutter and adenosine for SVT [7, 8, 17].

Management depends on proper identification of atrial flutter, assessing the hemodynamic status of the neonate and recognition of treatable causes. As the arrhythmia occurred

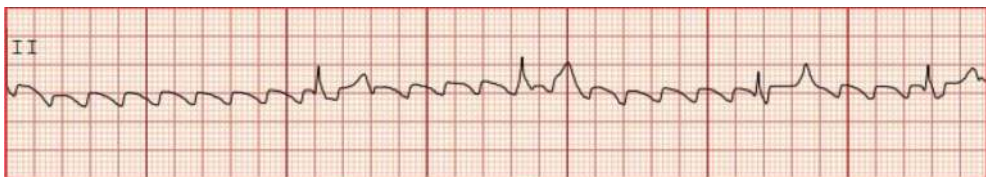

Figure 6. Atrial flutter. Lead II ECG: sawtooth flutter waves.

secondary to the malposition of the catheter, the first step of management should be to pull back or even remove the catheter. If the neonate is hemodynamically unstable, the best treatment option will be synchronized cardioversion with a dose of 0.5 J/kg. If the neonate is hemodynamically stable, digoxin therapy can be used as a first line management. The response rate for digoxin is roughly around 33%. Many times atrial flutter needs permanent reversion to DC cardioversion. Intravenous adenosine can be used to terminate the arrhythmia which uncovers a flutter in SVT. Occasionally esophageal overdrive pacing may be required [7, 8, 17].

3.4.2.2. Supraventricular tachycardia (SVT)

Narrow complex SVT is the most common type of hemodynamically significant arrhythmia in neonates. With better modes of detection and high index of suspicion, the incidence of SVT is now estimated to be 1 in 200–250 neonates. In SVT the impulses are originating proximal to the bundle of His. The typical infant who has SVT has a regular R-R interval, with rates often greater than 230 beats/min and commonly 260–300 beats/min. The atrial and ventricular rates are equal. They are further sub-classified by the inducing mechanisms into either automatic or re-entry. Most SVTs are re-entry type atrioventricular SVTs utilizing an accessory pathway. Commonly the impulses travel down the AV node and retrogradely up the accessory pathway (**Figure 7**) [15, 16].

Management depends on the hemodynamic status of the neonate. As the arrhythmia occurred secondary to the malposition of the catheter, the first step of management should be to pull back or even remove the catheter. If the neonate is relatively stable, the next step is to stop the re-entry loop (as most of the neonates with SVT have atrioventricular re-entry tachycardia) by inducing vagal maneuvers. One can perform vagal maneuvers like keeping crushed ice inside two plastic bags and place the ice pack over the face carefully for few minutes. Oropharyngeal suction can be used to stimulate the vagus. The use of vagal maneuvers in neonates are controversial, but still one can use for buying time of adenosine preparation. Pressure on eyeballs and carotid sinus massage should not be attempted in neonates, as this may cause retinal detachment and cerebral ischemia [6, 15, 16]. If tachycardia persists, the initial step of management is stabilizing the neonate (intubation/assisted ventilation/check the blood pressure and do ABG) followed by administration of intravenous adenosine. Adenosine can be given in a starting dose of 0.05 mg/kg and can be increased by 0.05 mg/kg up to 0.25 mg/kg. The dosage can be increased up to 0.3 mg/kg for recalcitrant cases with a cardiologist approval. Recent literature suggests the starting dose of adenosine as 0.1 mg/kg with the maximum of 0.5 mg/kg [8, 9].

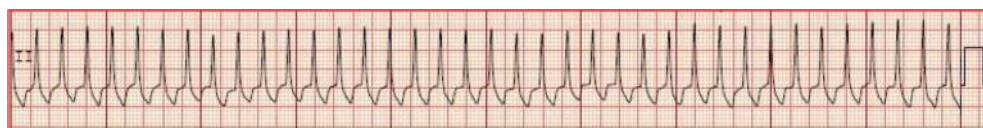

Figure 7. Supra ventricular tachycardia. Lead II ECG: absent P wave, narrow QRS complex and constant R-R interval.

3.4.2.3. Relevant facts about adenosine

1. Adenosine is an endogenously available purine nucleoside.
2. It is a rapidly acting (onset within 20 s) drug with a short half-life of less than 10 s as it is metabolized rapidly by adenosine deaminase.
3. It slows the conduction through atrioventricular node and thereby interrupts AV re-entry pathways and restores normal sinus rhythm within 20 s of its administration.
4. Before giving adenosine place the neonate in mild reverse Trendelenburg position with continuous ECG monitoring.
5. Adenosine must be given as a rapid injection (within 3 s) by peripheral intravenous route directly to the vein. Select the vein which is more proximal to the patient. Injection should be followed by rapid normal saline flush (5 ml or more).
6. After conversion of sinus rhythm by adenosine, always save and check the ECG strip for concealed pre-excitation.
7. If the correct technique is followed, adenosine will terminate 85–93% of SVTs caused by a re-entry mechanism.
8. Adenosine is a safe and effective drug with minimal transient side effects. The side effects include flushing (18%), changes in respiration, rarely short bradycardia, hypotension, and sweating may occur. Very rarely, short complete AV block can occur.
9. Adenosine will not terminate the atrial tachycardia. However, it produces transient AV block which may help to detect atrial flutter (**Table 4**) [8, 9].

3.5. Bradyarrhythmia

As depicted in **Figure 8**, bradyarrhythmias may occur either due to contact/injury to the sinoatrial node (SA node) or the atrioventricular node (AV node). So far bradyarrhythmias as complications of central venous catheters are not reported but can happen.

3.5.1. SA node

Bradyarrhythmia can occur as a result of SA node dysfunction due to direct injury by the catheter and it can cause complications ranging from first-degree block to sinus arrest.

Fetal period	SVT and atrial flutter
Neonatal period (generally, they are benign)	Premature atrial complexes (PAC)
Neonatal period (pathological cause)	Narrow complex SVT
Indwelling catheter in situ	Atrial flutter

Table 4. Commonly encountered tachyarrhythmia in fetal/neonatal period.

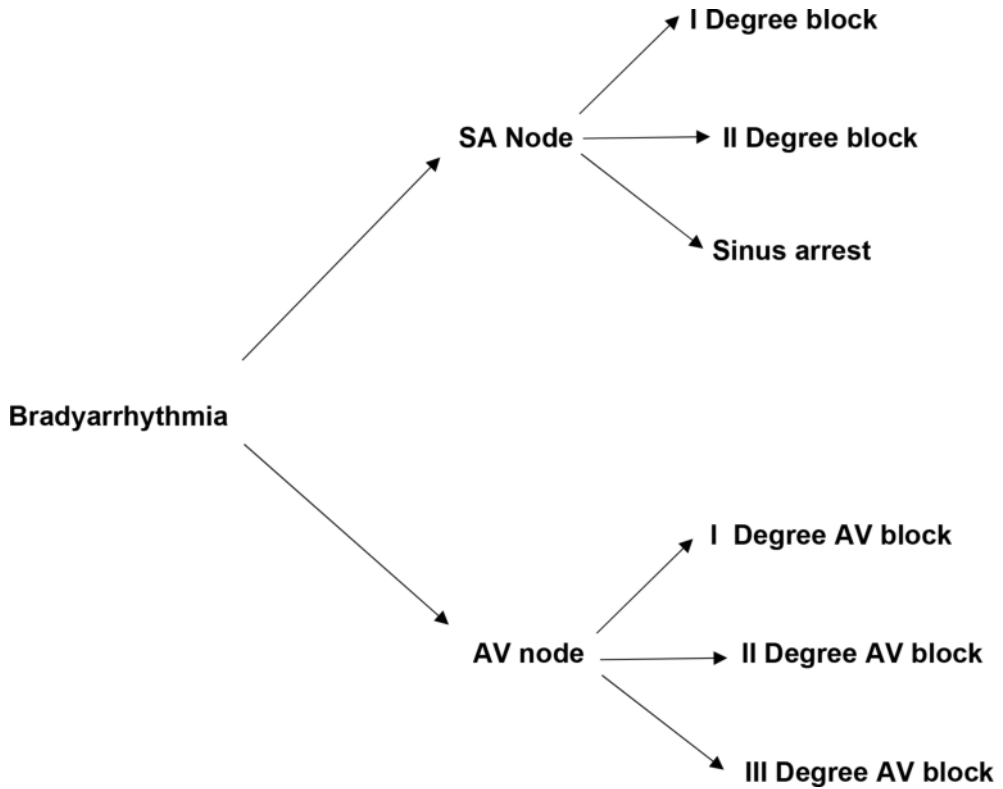


Figure 8. Types of Bradyarrhythmias.

Bradyarrhythmias can be benign but however, acutely unstable bradycardia can lead to cardiac arrest. Management includes identification and correction of reversible causes, pharmacotherapy, and rarely cardiac pacing.

3.5.2. AV node

AV nodal conduction disturbances can occur due to endocardial irritation by the catheters. It can lead to bradycardia ranging from first degree to third degree AV block.

4. Practical tips to minimize the arrhythmic complications

1. Measure the length of intravascular placement of a catheter for each neonate and document it properly in the case record. If possible, double check it with another physician.
2. Traditional measurements for PICC line insertion length are based on straight line measurements with bony points using inch tape. These measurements are commonly overestimated,

which leads to more advancement of PICC line. This can be avoided by using rope method of measurements (can use a nasogastric tube or any flexible tubes) along the course of veins applicable to lower and upper extremity veins.

3. Before insertion, make sure the catheter tip is not bent or curved, which is proposed to cause more damage to the vessel wall and vascular erosion. If the catheter is inappropriately placed in the intracardiac position, it can cause pericardial tamponade and pleural effusion secondary to the curved catheter.
4. Central venous catheter insertion should be done under strict cardiac monitoring with properly placed ECG leads. Performing physician should monitor the ECG wave patterns carefully especially while introducing the catheter beyond brachiocephalic vein. If any mild changes are observed in the ECG, the catheter should be withdrawn immediately.
5. If the introducer feels the cardiac pulsations in the catheter or the slightest resistance during the pathway, the catheter should be withdrawn immediately.
6. Fix the catheter with the exact measurement. One should avoid increasing 1 or 2 cm more, assuming that can later withdraw it after confirming the position with X-ray.
7. Confirmation of catheter positioning with radiography should be done immediately after the insertion of catheters. Optimizing a good position of the neonate is mandatory (Table 5).

The interaction between the neonatal posture, and radiological catheter position is well explained in advances in neonatal care.

8. Always aim to place the catheter in an optimal position. The ideal position is 0.5–1 cm away from the cardiac outline in preterm and 1–2 cm away from the cardiac outline in term neonates. Confirmation by ultrasound is upcoming and it is welcoming advancement in neonatal care [15]. Real-time ultrasound has been shown to have good diagnostic utility in comparison with X-ray with sensitivity of 95–96.5% and specificity of 100% in neonates [18–20].
9. Know the catheter tip position. Identify it in each X-ray and if it needs adjustments, perform the amendments. Do not ever forget to document it.
10. Prevention of catheter migration is at most important by application of the secure transparent dressing. Secure it with proper measurement and document the external catheter length. External length needs to be verified in each shift. Proper hand over by the concerned staff nurse is mandatory to notify the migration early. Repeated pump occlusion alarms could be a sign of migration [13].
11. Arrhythmic complications can occur anytime from the time of insertion to the time of removal of catheters. Any neonate with the catheter in situ developed arrhythmia could

Upper extremity X-ray	Keep both arms and forearms straight	Over the sides of the neonate
Lower extremity X-ray	Keep both legs straight	

Table 5. Ideal positions for X-rays pertaining to different sites of PICC line [10].

be due to the migration of catheter until proved otherwise. So check for migration, verify the external length and immediately withdraw the catheter. Confirm the position with an X-ray, check for kinking, curving and looping which is potentially dangerous as it can induce pericardial tamponade.

12. Vigilantly look for catheter migration whenever the critical neonates are on high-frequency ventilation.
13. Take precautions while handling for ultrasonography, daily weight check, the neonatal transfer for any cause, pre and post-operative periods and any invasive procedures which need more manipulation of neonates.
14. Ultrasound-guided insertion of central lines (PICC or UVC) is more reliable, safe and effective when compared with the blind procedure.
15. While inserting the PICC line turn the head of the neonate toward the ipsilateral side of insertion as it prevents the entry of PICC line into the jugular veins.

5. Conclusion

Central line insertion is a very common bedside procedure in NICU setup, it is not uncommon to encounter complications. Although there are various complications related to PICC line insertion, arrhythmic complications are preventable by exact measurements along the venous course, avoidance of willful over advancement of the catheter, prevention of migration and early detection of migration and adjusting the catheter tip properly. Ultrasound-guided insertion of catheter and placement of catheter tip using real-time ultrasonography is a welcoming advancement to minimize arrhythmic complications. Worldwide, the reported incidence of arrhythmic complications published in the literatures are few.

Abbreviations

CVC	central venous catheter
PICC	peripherally inserted central catheter
UVC	umbilical venous catheter
AF	atrial flutter
SVT	supraventricular tachycardia
NICU	neonatal intensive care unit
IVC	inferior vena cava
SVC	superior vena cava

PAC	premature atrial complexes
SA node	sinoatrial node
AV node	atrioventricular node
ECG	electrocardiogram

Author details

Lakshmi Prabha^{1*}, Anwar Khan¹, Mahmoudh Galal¹, Yaser El Saba¹ and Karnika Senthilkumar²

*Address all correspondence to: meenu9298@yahoo.co.in

1 Department of Paediatrics, Level 3 West, NICU, Dubai Hospital, Dubai Health Authority, Dubai, UAE

2 CIS, Dubai, UAE

References

- [1] Nowlen TT, Rosenthal GL, Johnson GL, Tom DJ, Vargo TA. Pericardial effusion and tamponade in infants with central catheters. *Pediatrics*. 2002;**110**:137-142
- [2] Infusion Nurses Society. Position paper: Peripherally inserted central catheters (PICCs). *J Intraven Nurs*. 1997;**20**:172-174
- [3] Racadio JM, Johnson ND, Doellman, DA. Peripherally inserted central venous catheters: success of scalp-vein access in infants and newborns. *Radiology*. 1999;**210**:858-860
- [4] Srinivasan HB, Tjin-A-Tam A, Galang R, Hecht A, Srinivasan G. Migration patterns of peripherally inserted central venous catheters at 24 hours post insertion in neonates. *American Journal of Perinatology*. 2013;**30**:871-874
- [5] Janes M, Kalyn A, Pinelli J, Paes B. A randomized trial comparing peripherally inserted central venous catheters and peripheral intravenous catheters in infants with very low birth weight. *Journal of Pediatric Surgery*. 2000;**35**(10):1040-1044
- [6] da Silva PSL, Waisberg J. Induction of life-threatening supraventricular tachycardia during central venous catheter placement: An unusual complication. *Journal of Pediatric Surgery*. 2010;**45**(8):E13-E16
- [7] de Almeida MM, Tavares WG, Furtado MM, Fontenele MM. Neonatal atrial flutter after the insertion of an intracardiac umbilical venous catheter. *Revista Paulista de Pediatria (English Edition)*. 2016;**34**(1):132-135
- [8] Wren C. Cardiac arrhythmias in the fetus and newborn. *Seminars in Fetal & Neonatal Medicine*. 2006;**11**:182-190. [PubMed: 16530495]

- [9] Dixon J, Foster K, Wyllie J, et al. Guidelines and adenosine dosing in supraventricular tachycardia. *Archives of Disease in Childhood*. 2005;**90**:1190-1191. [PMCID: PMC1720194] [PubMed: 16243875]
- [10] McDonald MG, Ramasethu J. *Atlas of Procedures in Neonatology*, 4th Ed. Lippincott Williams and Wilkin. 2007
- [11] Kelly RE, Croitoru DP, Nuss D, Flemmer LS, Bass WT. Choosing venous access in the extremely low birth weight (ELBW) infant: Percutaneous central venous lines and peripherally inserted catheters. *Neonatal Intensive Care*. 1997;**10**:15
- [12] Franck LS, Hummel D, Connell K, Quinn D, Montgomery J. The safety and efficacy of peripheral intravenous catheters in ill neonates. *Neonatal Network*. 2001;**20**(5):33-38
- [13] Hadaway LC. Thrombotic and nonthrombotic complications: Loss of patency. *Journal of Intravenous Nursing*. 1998;**21**(suppl):S143-S160
- [14] McGettigan MC, Goldsmith JP. Pleural effusion caused by intrathoracic central venous hyperalimentation. *Journal of Perinatology*. 1996;**16**(52):147-150
- [15] Verheij G, Smits-Wintjens V, Rozendaal L, Blom N, Walther F, Lopriore E. Cardiac arrhythmias associated with umbilical venous catheterisation in neonates. *BMJ Case Reports*. 2009;**2009**. pii: bcr04.2009.1778. DOI: 10.1136/bcr.04.2009.1778. [Epub 2009 Jun 21]
- [16] Daniels SR, Hannon DW, Meyer RA, Kaplan S. Paroxysmal supraventricular tachycardia. A complication of jugular central venous catheters in neonates. *American Journal of Diseases of Children*. 1984;**138**(5):474-475
- [17] Obidi E, Toubas P, Sharma J. Atrial flutter in a premature infant with a structurally normal heart. *The Journal of Maternal-Fetal & Neonatal Medicine*. 2006;**19**(2):113-114
- [18] Katheria AC, Fleming SE, Kim JH. A randomized controlled trial of ultrasound-guided peripherally inserted central catheters compared with standard radiograph in neonates. *Journal of Perinatology*. 2013;**33**:791-794
- [19] Abdeyazdan Z, Sheikhan-Sudani E, Sadeghnia A, Talakoub S. Effect of using static ultrasound technique on peripherally inserted central catheters' insertion success rate in neonates in a neonatal intensive care unit. *Iranian Journal of Nursing and Midwifery Research*. 2014;**19**:643-646
- [20] Telang N, Sharma D, Pratap OT, Kandraju H, Murki S. Use of real-time ultrasound for locating tip position in neonates undergoing peripherally inserted central catheter insertion: A pilot study. *The Indian Journal of Medical Research*. March 2017;**145**:373-376

