

---

# Triple-Negative Breast Cancer: Expression of Hypoxia-Inducible Factor 1 $\alpha$ in Triple-Negative Breast Cancer with Metastasis to Lymph Nodes

---

Anna Maria Badowska-Kozakiewicz and  
Michał Piotr Budzik

Additional information is available at the end of the chapter

<http://dx.doi.org/10.5772/intechopen.75354>

---

## Abstract

A great number of scientific studies have shown that the development of different TNBC forms is closely associated with the induction of various signaling pathways and that TNBC cells show greater sensitivity to different drugs. Recent studies showed hypoxia-inducible factor-1 $\alpha$  (HIF-1 $\alpha$ ) was strongly correlated to clinicopathological features in many types of cancers. This molecule seems to play a significant role in the development of different tumors and breast cancer among them. The aim of this study was to evaluate the relationship between immunohistochemical expression of novel prognostic marker—HIF-1 $\alpha$ —and clinicopathological features for patients with triple-negative breast cancer. Among 162 breast cancer patients, we identified 111 (68.5%) subjects with triple-negative breast cancer. In our study, TNBC was most commonly assessed as G2 and G3 (52.2%; 45.1%), pT1 and pT2 (34.2%; 62.1%), and pN1 and pN2 (45%; 41.4%). TNBC more often presented HIF-1 $\alpha$  expression (43.2%) than non-TNBC (35.2%). TNBC subgroup demonstrated significant correlation between HIF-1 $\alpha$  expression and tumor size (pT1–pT4) ( $p = 0.021$ ), which may suggest that HIF-1 alpha expression in this group of patients may be an additional and significant marker in the evaluation of the advance of the disease, affecting therapeutic decisions.

**Keywords:** triple-negative breast cancer, hypoxia, immunohistochemistry

---

## 1. Introduction

Breast cancer is the most common cancer in women [1], and it comprises heterogeneous tumors with different biological features, clinical course, prognosis, and response to treatment [2].

---

With modern techniques, we can distinguish many molecular forms of breast cancer [3], which is important because the molecular classification of breast cancer enables effective, individualized treatment [4]. Based on cDNA microarray and immunohistochemical analysis, five basic molecular subtypes of breast cancer have been distinguished:

- luminal subtype A (ER+ and/or PR+, HER2-, CK5/6-)
- luminal subtype B (ER+ and/or PR+, HER2+, CK5/6-)
- basal-like subtype (ER-, PR-, HER2-, CK5/6+)
- subtype with overexpression of the *HER2* gene (ER-, PR-, HER2+, CK5/6-)
- subtype with expression of genes typical for cells of the normal mammary gland (normal breast-like)
- subtype with a decreased expression of genes coding proteins responsible for intercellular junctions and adhesion of epithelial cells (claudin and cadherin E) [5, 6]

On routine histology, breast cancer is defined based on immunohistochemical detection of three receptor proteins: estrogen receptor (ER), progesterone receptor (PR), and HER2 receptor with additional gene status analysis of the *HER2* gene (*in situ* hybridization). This immunohistochemical profiling shows that 25% of breast cancers consist of type A luminal cells; 32%, of type B/HER2- cells; 18.5%, of luminal B/HER+ cells; and 7%, of cells that express solely the HER2 protein [7]. Cancers of the luminal subtype A and B express genes characteristic for glandular cells, which form the inner layer of normal ducts and lobules of the breast. Moreover, the luminal subtypes of breast cancer express cytokeratins typical for glandular cells, such as cytokeratins 8, 18, and 19, as well as  $\alpha$  6 integrins and Bcl-2, Ep-CAM, and MUC1 proteins. The luminal subtype A is characterized by a high expression of genes for estrogen receptors and progesterone receptors and genes regulating the function of these receptors, i.e., *FOX1*, *GATA3*, *LIV-1*, and *XBP1*. The luminal subtype A breast cancer typically occurs in young patients; in contrast to the luminal subtype B, the luminal subtype A breast cancer has a good prognosis [8–10]. In recent years, among all the molecular subtypes of breast cancer, the triple-negative breast cancer (TNBC) has been studied most extensively.

## 2. Characterization of the triple-negative breast cancer

The TNBC is a subtype of breast cancer that lacks steroid receptors, i.e., estrogen and progesterone receptors, and does not overexpress the *HER2* gene. Eighty percent of patients with the TNBC have the basal type of breast cancer, according to the molecular classification [1, 3, 8]. About 15–20% of all patients with breast cancer have the TNBC, which is more common in patients younger than 50 years. The risk factors for the TNBC are as follows:

- young age at menarche
- obesity in the menopausal age
- family history of breast cancer

The TNBC has an aggressive course, grows fast, and metastasizes early, usually to the brain and lungs, and less commonly to the bones and liver. Compared with other breast cancers, the TNBC is poorly differentiated (G3) in the Bloom-Richardson classification [5, 6, 9]. In 2010, studies among 15,240 women with breast cancer, including 2500 with the TNBC, showed that patients with the TNBC had a worse prognosis than other patients [5, 6, 8–10].

The TNBC is also characterized by early recurrence, usually within 1–3 years after diagnosis [8]. Most patients with TNBCs have a poor prognosis because adjuvant therapy rarely leads to remission, and the presence of metastases is associated with a high resistance to chemotherapy and short survival [9]. Not all patients with TNBC, however, have a poor prognosis [6, 7, 9]. Numerous studies showed that the TNBC is related to the dysfunction of the *BRCA* genes and their protein products [9, 10]. According to Atchley et al. [10], TNBCs occur in 57% of patients with breast cancer and *BRCA1* mutations. Moreover, more than a half of TNBCs overexpress the MGFR receptor (c-Met growth factor receptor), which is associated with the signaling pathway initiating the epithelial-mesenchymal transformation [8, 9]. The TNBC is often associated with *P53* mutations, *PTEN* loss, activation of the PI3K/AKT signaling pathway, and loss of heterozygosity of the loci 4p14, 4p15.3, 5q11.1, 5q14, and 18q22–23 [11].

Although TNBC was initially detected in basal-like carcinoma, these two types of breast cancer are different from each other [12]. The basal-like carcinoma is diagnosed based on the immunohistochemical status of steroid receptors (ER, PR) and the HER2 receptor [4, 7, 9].

Molecularly, the TNBC comprises a heterogeneous group of tumors. Lehmann et al. [13] distinguished six types of the TNBC:

- basal-like 1 and basal-like 2 (BL1 and BL2)
- immunomodulatory (IM)
- mesenchymal (M)
- mesenchymal stem-like (MSL)
- luminal androgen receptor (LAR)
- unstable

Of all these TNBC subtypes, only the LAR TNBC does not express basal cytokeratins, such as CK5, CK6A, CK6B, CK14, CK16, CK17, CK23, and CK81, and it does not express proteins such as EGFR, p53, smooth muscle actin, P-cadherin, and c-Kit receptor [10, 11]. In contrast, the LAR TNBC expresses CK7, CK8, CK18, CK19, and the androgen receptor [12]. Moreover, the LAR TNBC expresses genes whose protein products regulate hormonal pathways and the gene for the androgen receptor and its co-activators [12, 13].

The BL1 TNBC expresses genes whose protein products are associated with cell cycle regulation, cell proliferation, repair process, and DNA replication [12].

The BL2 TNBC expresses genes whose protein products are involved in the signal transduction in the cell, through growth factors such as EGF, NGF, MET, Wnt/ $\beta$ -catenin, and IGF1R [12].

The IM TNBC is characterized by the expression of genes whose protein products are involved in immune reactions, such as signal transduction in Th1 and Th2 cells, natural killer cells, and dendritic cells [10, 12].

The M TNBC is characterized by the expression of genes whose protein products regulate cell mobility, interaction of cells with the extracellular matrix, and cell differentiation and growth [12].

The MSL TNBC expresses genes whose protein products are involved in angiogenesis and the signaling pathways of the ABC transporters [12, 13].

Most subtypes of the TNBC have the molecular profile typical for the basilar subtype of breast cancer, which lacks expression of ER, PR, and HER2 [8, 9, 12]. This molecular profile is observed mainly in subtypes BL1 (85%) and BL2 (31%), and subtypes IM (58%) and M (47%) [8, 12].

Usually, the LAR TNBC is a luminal A or B breast cancer (82%) [12–14]. Based on immunohistochemical studies, 50–80% of TNBCs are basal-like cancers, and conversely, 77–80% of basal-like breast cancers are TNBCs [9, 10, 12]. Molecular analyses indicate that TNBCs and the basal subtype of breast cancer are different cancers [13–15].

All the above-mentioned subtypes of the TNBC incur different prognoses; the longest recurrence-free survival is found in patients with the MSL TNBC, and the shortest recurrence-free survival, in patients with the LAR TNBC [15].

Histologically, the majority of TNBCs are luminal cancers (invasive carcinoma of no special type—IDC—NST) [15]. The TNBC occurs more commonly in patients with specific histological types of breast cancer, including the medullary breast cancer, metaplastic breast cancer, apocrine breast cancer, salivary gland-like breast cancer, secretory breast carcinoma, breast cancer derived from lipid-laded cells, and lobular breast carcinoma [16]. In patients with TNBCs, it is the histological type of the tumor that determines its biological properties; thus, patients with TNBCs do not always have rapid disease progression and poor prognosis [17, 18].

To identify a homogenous group of patients, Eiermann et al. [19] suggested that the tumors that become triple-negative after neoadjuvant treatment, and were not triple-negative before this treatment, should not be classified as TNBC. However, if the disease recurs as triple-negative metastases, the tumor should be considered as triple-negative although the primary tumor was not triple-negative [19]. According to these investigators, also rare histological subtypes of the TNBC, such as apocrine, glandular, or low-differentiated cancers, should be excluded from the group of triple-negative cancers [18, 20].

### 3. Treatment of patients with TNBC

Patients with the TNBC do not benefit from hormonal treatment or treatment with anti-HER2 antibodies (trastuzumab) because their tumors do not express the ER, PR, and HER2 receptors. Therefore, surgery, radiation therapy, and chemotherapy, used alone or in various combinations, are currently the only reliable therapeutic options for patients with TNBCs. However, recent research on TNBC has identified many receptors that could be used as future therapeutic

targets. Until this is achieved, chemotherapy remains the mainstay of systemic treatment for patients with stage I to stage III TNBC. Currently, none of the standard chemotherapy regimens is considered superior for patients with TNBCs, and treatment of these patients is based on the same principles as that in patients with other subtypes of breast cancer. Most guidelines recommend a regimen based on the combination of an anthracycline with a taxane.

The therapeutic strategies for the management of TNBC are targeting the DNA repair complex (platinum compounds and taxanes), P53 (taxanes), and cell proliferation (anthracycline-containing regimens) [21]. Despite the aggressive clinical course, the TNBC's response to chemotherapy is good. However, despite achieving high rates of pathological complete response (pCR) with conventional chemotherapy, the TNBC phenotype is associated with higher recurrence rates than the ER+ and HER2+ breast cancers. This is known as the triple-negative paradox [22].

Since the first application of taxanes, used in adjuvant therapy for over 20 years, relatively few new treatments have appeared in recent years for patients with the TNBC. New therapeutic methods are still lacking despite numerous ongoing clinical trials. Many retrospective studies have demonstrated that tumor infiltrating lymphocytes (TILs) are of prognostic importance in patients with early-stage TNBC. Increased TIL numbers within the neoplastic milieu correlate with a better response to the standard treatment regimen with anthracyclines in neoadjuvant therapy [23].

However, it has still not been shown whether the presence of TILs identifies tumors that are more susceptible to treatment, or whether the presence of lymphocytes itself increases the effectiveness of treatment [23]. There are numerous reports on the benefits of using platinum derivatives in chemotherapy, in particular in cancers with the *BRCA1* mutation, which is much more frequent in TNBCs (about 30%) than in other cancers. Nearly 80% of tumors that develop in carriers of the *BRCA1* mutation are triple-negative. The *BRCA* mutation status is increasingly therapeutically relevant beyond consideration of prophylactic mastectomy/oophorectomy and surveillance. A recent randomized phase III trial demonstrated that in unselected patients with the metastatic TNBC, carboplatin and docetaxel were equal in efficacy as first-line treatments [24].

However, in the *BRCA* mutation-associated TNBC, carboplatin yielded a superior response rate and progression-free survival compared with docetaxel. The improvement in pCR attained with the addition of carboplatin to anthracycline/taxane chemotherapy comes at the cost of increased toxicity. Because of the molecular variability of TNBCs, the platinum derivatives improve prognosis only in some patients. Therefore, it is very important to identify those patients with TNBC who will have the greatest benefit [25]. The current highest pCR rates, about 40–45%, are achieved by taxane/anthracycline sequential chemotherapy regimens and inclusion of platinum drugs with the taxane component. Inclusion or substitution of other chemotherapy drugs (capecitabine, gemcitabine, vinorelbine, or ixabepilone) resulted in little or no improvement in pCR rates [26, 27]. To date, all clinical trials showed that the neoadjuvant chemotherapy was the preferred option for patients with TNBC who required systemic therapy. Neoadjuvant chemotherapy studies have consistently reported higher response rates in TNBC than in non-TNBC, and pCR has been shown to predict improved long-term

outcomes for patients with TNBC. The specific adjuvant regimens that may be effective for TNBC are still being determined. Many large randomized trials have established the benefit of adjuvant anthracyclines and taxanes in breast cancer [28].

The evidence consistently shows that 10–20% of patients with TNBC who would not experience pCR following treatment with a current third-generation taxane and anthracycline will achieve pCR when a platinum drug is added to the regimen. However, because of the substantial added toxicity and predicted modest overall survival benefit across patient subgroups, carboplatin and cisplatin have not been routinely incorporated into neoadjuvant treatment [29].

The principles of local treatment in breast cancer, i.e., surgery and radiotherapy, are the same for the TNBC and all other types of breast cancer. Over the last several years, the percentage of patients operated on for breast cancer has increased; this trend has also been observed in patients with TNBC.

In patients with the TNBC, radiation therapy is given as in other types of breast cancer, i.e., after mastectomy or breast-conserving surgery. However, this approach to radiation therapy remains controversial because more and more patients have TNBCs, which has a fast local growth. The general rule that breast-conserving surgery followed by radiation therapy in early stage cancers ( $T_{1-2} N_0$ ) is the equivalent of mastectomy, in this case, has many limitations. Also the general consensus that post-mastectomy radiation therapy is not indicated for patients with node-negative tumors less than 5 cm in diameter should not be oversimplified in patients with triple-negative tumors [28].

## 4. Targeted therapy in TNBC

Although chemotherapy can be effective in patients with TNBCs, molecular studies could still improve treatment outcomes by giving new treatment targets. The molecular heterogeneity of TNBCs means that patients with TNBCs need personalized treatment because currently 60–70% of patients with TNBC do not respond fully to chemotherapy. Genomic analyses of the TNBC revealed large-scale transcriptional, mutational, and copy number heterogeneity, without any frequently recurrent mutations, other than *TP53*. Consistent with this molecular heterogeneity, most targeted agents, so far, have a very low activity in unselected TNBC, but important “basket” trials are ongoing. Therefore, there are promising opportunities for studying targeted therapy in appropriately selected patients with residual disease after neoadjuvant chemotherapy. Several ongoing phase I/II studies are investigating phosphatidylinositol-3-kinase (PI3K) inhibitors in advanced TNBC, and early-phase studies are also assessing Janus kinase 2 and cyclin-dependent kinase inhibitors in hormone-negative breast cancer [29].

At least some important discoveries made in recent years seem to be worth emphasizing in this textbook. The molecular pathways and receptors mentioned below might become new treatment targets for patients with the TNBC.

### 4.1. Anti-angiogenic factors

Blockage of angiogenesis has been one of the ways to treat patients with breast cancer. In patients with the TNBC, bevacizumab, among the drugs that interfere with angiogenesis, has

been studied most extensively. In 2008, the Food and Drug Administration (FDA) approved bevacizumab in combination with a taxane (paclitaxel) as first-line therapy for metastatic HER2-negative breast cancer, including the TNBC [30]. A meta-analysis of phase III studies with bevacizumab showed an improvement in progression-free survival but not in overall survival in these patients. However, the addition of bevacizumab considerably increased treatment toxicity [31].

Based on these data, in 2011, the FDA withdrew bevacizumab as the treatment for metastatic breast cancer.

#### **4.2. Immune checkpoint inhibitors**

Because we know more and more about the interaction of inflammatory cells with cancer cells, in future, immunotherapy might be introduced for the treatment of breast cancer. Cancer cells use many mechanisms to avoid immune responses. For instance, in the TNBC, cancer cells express the PD-1 antigen and its ligands on cell surface. These proteins induce T lymphocyte tolerance. Preclinical studies showed that blocking the activity of the PD-1/PD-L1 might be used as treatment for TNBC. Both anti PD-1 antibodies (pembrolizumab and nivolumab) and an anti-PD-L1 antibody (atezolizumab) showed promise in preclinical studies [32].

#### **4.3. PARPi**

Poly-ADP-ribose polymerases (PARPs) are enzymes that are essential for cell survival. Cell damage activates PARPs, which, in turn, induces cell repair systems that maintain genome stability and regulation of transcription. Preclinical studies showed that PARPs are inhibited in cancer cells with pre-existing DNA repair defects, e.g. with the *BRCA1* mutations. The FDA has recently approved monotherapy with olaparib, a PARPi, as a first-in-class drug to treat germline *BRCA* mutation-associated advanced refractory breast cancer. Several ongoing studies are assessing the activity of PARPi alone or in combination with chemotherapy for germline *BRCA*-associated metastatic and early-stage breast cancers. Because a substantial proportion of TNBCs are thought to harbor DNA repair defects, it might be possible to extend the observation of PARPi sensitivity of germline *BRCA*-associated tumors to *BRCA* wild-type TNBCs that harbor a BRCAness phenotype. Accordingly, PARPi are being explored in the general population of patients with the TNBC [33].

#### **4.4. PI3K/AKT/mTOR pathway inhibitors**

The high frequency (about 50%) of PI3K pathway alterations in the TNBC makes this pathway a promising target for therapeutics, and inhibitors of PI3K, AKT, and/or mTOR are in clinical development. PI3K blockade promotes HR deficiency by downregulating *BRCA1/2* and thus sensitizing *BRCA*-proficient tumors to PARP inhibition [34].

#### **4.5. Histone deacetylase inhibitors**

These drugs modulate gene expression through epigenetic regulation and can induce cell cycle arrest, differentiation, and apoptosis. Panobinostat is a potent pan-histone deacetylase inhibitor with preclinical activity in the TNBC. Several histone deacetylase inhibitors are

currently being tested as treatment for metastatic TNBC in combination with chemotherapy or with immune checkpoint inhibitors [35].

#### 4.6. Androgen-targeted therapy

TNBCs expressing the androgen receptor (AR-positive) account for about 10% of all TNBCs and are characterized by a more benign course [13]. These tumors express the AR, which can be detected by immunohistochemistry or the analysis of AR gene expression. AR-positive TNBCs have several common features with ER-positive breast tumors, including the expression of several estrogen-dependent genes and the frequent presence of PIK3CA mutations. Anti-androgens have been studied as potential drugs for these cancers. Few TNBCs express AR, and patients with AR-positive tumors were qualified for clinical trials with anti-androgens. Many molecules have been studied, but data on bicalutamide and enzalutamide are most extensive. Unfortunately, few patients responded to the treatment with these agents. Nonetheless, 20–35% of patients achieved disease stabilization [36]. It remains unclear whether these findings reflect the relatively mild nature of AR-positive TNBCs or whether they reflect the actual, but limited, activity of anti-androgens.

#### 4.7. Other agents

New treatment targets for patients with cancer are being studied. These include, among others, reparixin (inhibitor of interleukin-8 activation of CXCR1/CXCR2 chemokine receptors), CXCR1/2 (stem cell pathway), cyclin-dependent kinases, c-Met pathway, aurora kinase inhibitor, death receptors, and CSF1 inhibitor (*colony stimulating factor 1*).

After over 20 years with relatively few new treatments for the TNBC, recent years have seen a growing interest in the TNBC among researchers. This is because more and more people with breast cancer have the TNBC, which is aggressive and tends to metastasize. Currently, studies are assessing different chemotherapy regimens and are testing the usefulness of new targeted therapies. In the early stages of the TNBC, standard neoadjuvant chemotherapy might save patients' lives; patients who receive standard neoadjuvant therapy can later receive adjuvant chemotherapy or be included in clinical trials if there is extensive residual cancer after neoadjuvant therapy. Growing evidence supports the benefit of adding cisplatin to the chemotherapy with taxanes/anthracyclines in patients with *BRCA* mutations [37].

Because many new targeted therapies for the TNBC are assessed in ongoing trials, we hope that the treatment of TNBC will soon be improved.

### 5. Hypoxia in TNBC

A great number of scientific studies have shown that the development of different TNBC forms is closely associated with the induction of various signaling pathways and that TNBC cells show greater sensitivity to different drugs. Recent studies showed hypoxia-inducible



factor-1 $\alpha$  (HIF-1 $\alpha$ ) was strongly correlated to clinicopathological features in many types of cancers. This molecule seems to play a significant role in the development of different tumors and breast cancer among them.

HIF-1 $\alpha$  is responsible mainly for cellular adaptation to hypoxic conditions; therefore, genes triggered by this factor are responsible mainly for the improvement in oxygen supply (by increasing angiogenesis, broadening the lumen of existing vessels, increased erythropoiesis or increased iron consumption), adaptation of cells to anaerobic metabolism conditions as well as for other changes facilitating cell survival in insufficient oxygen availability and modifying the main metabolic pattern. Stimulation of angiogenesis promotes the increased risk of distant metastases. Better accessibility of blood vessels increases the chance of tumor cells finding their way into the bloodstream and being transported to niches allowing settlement and formation of a metastatic lesion [38].

Hypoxia-inducible factor 1 is a master transcriptional regulator of genes regulating oxygen homeostasis. The HIF-1 protein is composed of two HIF-1 $\alpha$  and HIF-1 $\beta$ /aryl hydrocarbon receptor nuclear translocator subunits. The prognostic relevance of HIF-1 $\alpha$  protein overexpression has been shown in breast cancer. The impact of HIF-1 $\alpha$  alternative splice variant expression on breast cancer prognosis in terms of metastasis risk is not well known.

Therefore, Dales et al. [39] investigated the prognostic value of different HIF-1 $\alpha$  transcript expression levels in breast cancer and found a significant relationship between either clinicopathological characteristics or patient metastasis-free survival. They proved mRNA expression of a *HIF-1 $\alpha$ <sup>TAC</sup>* splice variant reflects a stage of breast cancer progression and is associated with a worse prognosis [39].

Due to the fact that TNBC frequently shows morphologic evidence of hypoxia (central fibrosis and necrosis) [40, 41] an augmented expression of HIF-1 $\alpha$  in tumors with a triple-negative phenotype should be anticipated. In fact, this had been elegantly demonstrated through the preferential expression of HIF-1 $\alpha$  in peri-necrotic tumor cells in TNBC and BRCA1 mutated breast cancers [42].

In contrast, Tan et al. [43] and Choi et al. [44] demonstrated in TNBC an increase of carbonic anhydrase IX, a downstream product of the hypoxic pathway, rather than an increase in HIF-1 $\alpha$  per se. The authors did not dispute the likely contribution of hypoxia to the tumors' aggressive phenotype.

HIF-1 $\alpha$  overexpression is an indicator of poor prognosis and significant survival time reduction in patients suffering from breast cancer [45]. HIF-1 upregulates transcription of angiogenic genes like erythropoietin (EPO) and vascular endothelial growth factor (VEGF), which induce sprouting of new vessels and in result they increase the risk of metastasis because they boost surface of contact between tumor cells and vasculature. HIF-1 induces transcription of cytoprotective proteins in malignant cells in hypoxic conditions. HIF-1 $\alpha$  predicts poor prognosis breast cancer [46, 47].

The relationship between inflammation and tumor progression is widely accepted. This phenomenon is also well known in breast cancer, and is mediated by numerous interleukins.

Besides playing a central role in the induction of inflammatory processes, interleukin 1 $\beta$  (IL-1 $\beta$ ) was also identified as a factor important for progression of the tumor and stimulation of angiogenesis as well as being responsible for the increase in the invasiveness of cancer lesions. Recently, there has been considerable interest in understanding the non-hypoxic upregulation of the hypoxia-inducible factor HIF-1 $\alpha$  by IL-1 in neoplastic cells since aberrant expression of HIF-1 $\alpha$  correlates with tumor progression. Naldini et al. [48] studied the effect of IL-1 $\beta$  on cell migration and HIF-1 $\alpha$  accumulation in the human invasive breast cancer cell line MDA-MB-231.

It was found that hypoxia-independent induction of HIF-1 $\alpha$  by IL-1 $\beta$  was associated with an increase in cell migration and a simultaneous increase in the activity of phosphorylated p38 MAPK and CXCR1 expression. Inhibition of HIF-1 $\alpha$  by siRNA led to a significant reduction in CXCR1 expression and cell migration, confirming the role of HIF-1 $\alpha$  in hypoxia-independent, IL-1 $\beta$ -induced migration of the MDA-MB-231 line cells. The results of the studies present a new role of IL-1 in breast cancer. The therapeutic approach focused on inhibition of IL-1 $\beta$  activity appears to be a new target for the research aimed at the development of novel methods to treat invasive breast cancer [48].

## 6. Aim

The first aim of our study was to evaluate the expression of ER, PR and HER2 in order to extract a group of TNBC and non-TNBC. The second aim of this study was to evaluate the relationship between immunohistochemical expression of novel prognostic marker—HIF-1 $\alpha$ —and clinicopathological features for patients with triple-negative breast cancer.

## 7. Materials and methods

Studies were conducted in a group of 162 patients with breast carcinoma with lymph node metastasis (111 triple-negative breast cancer and 51 non-triple-negative breast cancer) in the Department of Pathology, Military Medical Institute in Warsaw. Material for the study came from biopsies, excisional biopsies and modified radical mastectomies. Tumor samples were fixed in 10% buffered formalin phosphate. After 24-h fixation, material was dehydrated using alcohol in gradually increasing concentrations and embedded in paraffin. Paraffin blocks were cut into serial sections 4  $\mu$ m in thickness. They were then stained using standard methods. The tumors were classified and graded according to the WHO and the Nottingham modification of the Scarff-Bloom-Richardson systems. In the sections stained with routine H&E method, the following determinations were carried out: type of neoplasm (WHO classification), tumor grade including tubule formation, and intensity of division as well as the degree of neoplastic cell differentiation and mitotic index as a mean number of mitotic figures in neoplastic cells counted in 10 fields of vision at a 400 $\times$  magnification (surface field 0.17 mm<sup>2</sup>).

Paraffin sections on the slides covered with 2% saline solution in acetone at temperature of 42°C were used for immunohistochemical examination.

Routine tests were performed in order to determine immunohistochemical expression of basic profile of diagnostic markers, such as estrogen receptor (ER), progesterone receptor (PR) and HER2. Monoclonal antibodies against receptors for estrogen (Monoclonal Mouse Anti-Human Estrogen Receptor alpha, 1:50 dilution, Clone: 1D5, Code: IR654, DAKO) and progesterone (Monoclonal Mouse Anti-Human Progesteron Receptor, 1:400 dilution, Clone: PR636, Code: IR068, DAKO) were used in order to determine the expression of steroid receptors. Evaluation of the immunohistochemical markers was performed by two pathologists as follows: ER and PR were categorized as negative—(0%), low positive—(1–10%); nuclear staining in >10% of tumor cells was considered positive for ER and PR.

The study was conducted as follows: sections were incubated at 60°C overnight and subsequently dewaxed. The next step involved revealing the epitope by heating the slides in a buffer for 40 min. Subsequently, preparations were left at room temperature for 20 min. Preparations were rinsed in buffer and endogenous peroxidase was blocked by washing in 3% H<sub>2</sub>O<sub>2</sub> for 10 min. In the next step, preparations were incubated with an appropriate antibody for 30 min. After incubation, preparations were rinsed in buffer for 10 min, and then incubated with the reagent (Visualization Reagent) for 30 min. After incubation with the reagent, preparations were washed in TBS (Tris-Buffered Saline, Code: S1968) with pH 7.6 for 10 min, and then incubated with 3,3'-diaminobenzidine (DAB) (Substrate—Chromogen Solution) for 10 min to visualize the color of the reaction. At the end of the procedure, preparations were stained with hematoxylin.

HER2 expression was determined using HerceptTest™ DAKO test (Code: K5204). It enabled detection of HER2 expression using a polyclonal antibody against this protein (Rb A—Hu HER2—Rabbit Anti-Human HER2 Protein). Antigen retrieval for HER2 using HerceptTest was performed by immersing and incubating the slides in 10-mmol/L citrate buffer in a calibrated water bath (95–99°C) for 40 min ( $\pm$ 1 min). After decanting the epitope-retrieving solution, sections were rinsed in the wash buffer and later, soaked in the buffer for 5–20 min before staining. The slides were loaded onto the autostainer using the HercepTest program, as described in the manufacturer's insert. In the autostainer, the slides were rinsed, placed in 200  $\mu$ L of peroxidase-blocking reagent for 5 min, rinsed, placed in 200  $\mu$ L of primary anti-HER2 protein (or negative control reagent) for 30 min, rinsed twice and immersed in 200  $\mu$ L of substrate chromogen solution – DAB for 10 min. The slides were counterstained with hematoxylin and finally coverslipped. HER2 results were determined based on the maximum area of staining intensity according to the instruction in the package insert and the ASCO/CAP guidelines as follows: strong, circumferential membranous, staining in >30% of invasive carcinoma cell was scored 3+, moderate, circumferential, membranous staining in  $\geq$ 10% of invasive tumor cells or 3+ staining in  $\leq$ 30% of cells was designated as 2+ staining, weak and incomplete membranous staining in invasive tumor cells was scored 1+ and no staining was scored 0. Tumors with 0 and 1+ staining were considered negative.

A total of 162 cases of breast cancer with metastasis to lymph nodes were assessed for expression of HIF-1 $\alpha$  (Monoclonal Mouse Anti-Human HIF-1 $\alpha$  1:50 dilution, Clone:28b, Santa Cruz Biotechnology®, Inc.). A visualization system ImmunoCruz™ Mouse ABC Staining System (Santa Cruz Biotechnology®, Inc.) was subsequently applied; tumor-cell immunoreactivity was scored according to both the extent of nuclear staining—relative number of HIF-1 $\alpha$

positive cells, and the intensity of the reaction: [-] not detected; [+] <1% positive cells; [+] 1–10% weakly to moderately stained cells; [++] 1–10% intensively stained cells or 10–50% weakly stained cells; [+++] 10–50% positive cells with moderate to marked staining; [++++] >50% positive cells [49]. Positive controls were HIF-1 $\alpha$  immunoreactive breast cancer tissues. Negative controls were prepared with omission of primary antibodies.

## 8. Statistical analysis

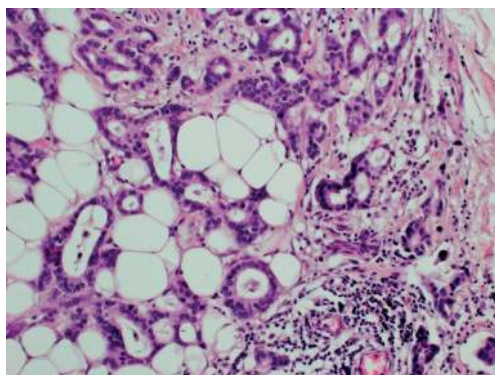
All statistical analyses were performed with SPSS software v12.0. The Chi-square ( $\chi^2$ ) was used to assess the relationship between HIF-1 $\alpha$  and degree of histological malignancy and clinical staging. The Fisher exact test was used when the expected cell counts were less than 5. The results were considered as statistically significant if the  $p$  value was less than 0.05 ( $p < 0.05$ ).

## 9. Results

Histopathological examination was performed in tumors obtained from 162 patients suffering from breast cancer. Among 162 breast cancer patients we identified 111 (68.5%) subjects with triple-negative breast cancer (TNBC was identified as ER-negative, PR-negative, and HER2-negative) and 51 (31.5%) subjects with non-triple-negative breast cancer. Mean age of patients with TNBC was 47.8 and of patients with non-TNBC 60.4 years.

Histopathological subtyping of the 111 triple-negative breast cancers identified 89.1% invasive ductal carcinomas of no special type (IDC-NST) (**Figure 1**) and 10.9% other special types of cancers: invasive lobular carcinomas, mixed ductal and lobular types, metaplastic carcinomas (**Table 1**).

All cases of triple-negative breast cancer were grouped according to histological grading: 3 (2.7%) cases were grade 1 (G1), 58 (52.2%) cases were identified as grade 2 (G2) and 50 (45.1%)



**Figure 1.** Triple negative breast cancer (TNBC) H&E.

Immunohistochemistry	Frequency n = 162	Prognostic parameters					
		Tumor necrosis			Histological type of invasive breast cancer		
		positive	negative	p-value	IDC-NST	other types	p-value
TNBC	111 (100%)	40 (36.0)	71 (64.0)	0.036*	99 (89.1)	12 (10.9)	0.858
non-TNBC	51 (100%)	10 (19.6)	41 (80.4)		45 (88.2)	6 (11.8)	

**Table 1.** Relationship between immunohistochemical profile (TNBC/non-TNBC) and prognostic parameters invasive breast cancer with metastasis to lymph nodes (\*statistically significant results  $p < 0.05$ ).

cases—grade 3 (G3). Given the histological grade of malignancy, G2 and G3 tumors comprised the largest group of triple-negative breast cancers.

In our study TNBC were most commonly assessed as G2 and G3 (52.2%; 45.1%), pT1 and pT2 (34.2%; 62.1%), and pN1, pN2 (45%; 41.4%). Respectively non-TNBC were most commonly assessed as G2 and G3 (47%; 47%), pT1 and pT2 (39.2%; 47%) and pN1 (52.9%). In our study a statistically significant association was found only between TNBC and non-TNBC tumor size (pT) ( $p = 0.0011$ ). Furthermore in TNBC more commonly than in non-TNBC the presence of necrosis in the tumor mass was observed (36%; 19.6%) and statistically significant correlation between TNBC and non-TNBC in the presence of necrosis was demonstrated ( $p = 0.036$ ) (**Table 1**).

In all examined breast cancers we also assessed the expression of HIF-1 $\alpha$  but not statistically significant relationship between TNBC and non-TNBC was revealed. TNBC more often presented HIF-1 $\alpha$  expression (43.2%) than non-TNBC (35.2%). In both groups we investigated correlation between the HIF-1 $\alpha$  expression and features such as: tumor size (pT), histological grade (G1–G3) and the presence of lymph node metastasis (pN1–pN3). While TNBC subgroup demonstrated significant correlation between HIF-1 $\alpha$  expression and tumor size (pT1–pT4) ( $p = 0.021$ ). Detailed data and relationships between different parameters are presented in **Tables 2** and **3**.

Immunohistochemistry – basal panel for diagnosis of breast cancer	Frequency n = 162	HIF-1 $\alpha$ expression		
		Negative (<10%)	Positive (>10%)	p-value
TNBC (ER-/PR-/HER2-)	111 (100%)	63 (56.8)	48 (43.2)	0.339
non-TNBC (ER+/PR+/HER2+)	51 (100%)	33 (64.8)	18 (35.2)	

**Table 2.** Relationship between basic immunohistochemical profile (ER, PR, HER2) and expression HIF-1 $\alpha$  in invasive breast cancer with metastasis to lymph nodes (\*statistically significant result  $p < 0.05$ ).

Clinicopathological features of TNBC		HIF-1 $\alpha$ expression		
		Negative ( $<10\%$ )	Positive ( $>10\%$ )	p-value
Histological grade	G1	0	3	0.134
	G2	35	23	
	G3	28	22	
Tumor stage	pT1	16	22	0.021*
	pT2	46	23	
	pT3	1	2	
	pT4	0	1	
Nodal stage	pN1	30	20	0.821
	pN2	25	21	
	pN3	8	7	

**Table 3.** Clinicopathological features of TNBC and their relationship to expression of novel breast cancer marker - HIF-1 $\alpha$  (\*statistically significant result  $p < 0.05$ ).

## 10. Discussion

A group of patients without the expression of any of the receptors qualifying for hormone therapy or targeted therapy against HER2 constitutes an important clinical problem in breast cancer treatment. Therefore, it seems important to undertake studies aimed at determining histopathological and immunohistochemical characteristics of this invasive group of triple-negative breast cancer (TNBC). Triple-negative breast cancer is most commonly found in patients less than 50 years of age [49, 50]. Our study also found that TNBC is most common among women before 50 years of age (mean age 47.8).

In our study, histopathological subtyping of 111 patients with identified TNBC yielded the following results: 89.1% of IDC-NST and 10.9% of other special types of cancers. Infiltrating ductal carcinoma of no special type (IDC-NST) was the predominant histopathological type. Similar results were obtained by other researchers, e.g., Nofech-Mozes et al. [51], Williams et al. [52], Atik et al. [53], Rao et al. [54], Osman et al. [55], Sood et al. [56] and Tawfik et al. [57] (92%, 91%, 27%, 88%, 85.7%, 80.56% and 81.9%), who found that IDC-NST is the dominant histological type in a group of triple-negative breast cancers. Given the histological grade of malignancy, the largest group of triple-negative breast cancers encompassed tumors given G2 and G3 grade. Statistical analysis showed no significant correlation between histological grade (G1–G3) and triple-negative tumor morphology ( $p > 0.05$ ). The following authors obtained similar results: Atik et al. [53] assessing 75% of cancers in TNBC group as G3, Carey et al. [58], who found that in the TNBC group most cases are G3 cancers (26%). In a study on 16 cases

of TNBC, Dabbs et al. [59] found that all tested tumors showed high degree of histological malignancy. Choi et al. [60] obtained similar results, stating that in a group of triple-negative cancers 63.1% were G3 tumors. Research by Zhou et al. [61] also showed that triple-negative G2 (51.6%) and G3 (45.2%) cancers were most numerous. Osman et al. [55] confirmed in their study that G3 carcinomas (61.9%) comprised the largest group of triple-negative tumors, while Sood et al. [56] pointed to G2 (47.22%) and G3 (38.89%) as most common tumors.

There are conflicting reports on the prevalence of lymph node metastases at the time of diagnosis among patients with TNBC. In our study we found that women without metastases to regional lymph nodes (pN0) comprised the largest group of all investigated patients with invasive triple-negative breast cancer (56.7%); no statistically significant relationship between lymph node status and histological type of TNBC-IC ( $p > 0.05$ ) was noted. Lymph node status among patients with TNBC was reported as follows: 19.81%—N1, 19.81%—N2, 3.6%—N3. The study also showed no association between tumor size and presence of lymph node metastasis in patients with TNBC, which stood in contradiction to the findings of Thike et al. [62] who had demonstrated a relationship between tumor size and presence of nodal metastases. In studies by Rao et al. [54] lymph node metastases were found in 37 of 50 patients with TNBC (74% of cases), and TNBC was associated with higher rates of node-positive cases, which was in agreement with the findings of Carey Rakha et al. [58] and Rakha et al. [63].

In our study 30.9% of all tumors showed central necrosis. In TNBC more commonly than in non-TNBC the presence of necrosis was observed (36%; 19.6%). Yehia et al. [64] in their study divided breast cancers into three subgroups (TNBC, HER2+ and ER+/PR+). 15.3% of all tumors showed central fibrosis and tumor necrosis, which differed significantly among the three groups ( $p = 0.019$ ). TNBC had the highest values among all groups even after adjusting the results for age. Respectively necrosis was observed in 25.8% TNBC, 9.4% HER2+ and 10.9% ER+/PR+ of cancers [64]. 62 TNBC, 64 HER2+, and 64 hormone-receptors positive breast cancers were evaluated also for HIF-1 $\alpha$  expression. HIF-1 $\alpha$  was expressed in 35.5% TNBC, 45.3% HER2+ and 25.0% ER+/PR+ ( $p = 0.055$ ). In our study HIF-1 $\alpha$  expression was observed in 43.2% TNBC and 35.3% non-TNBC.

Due to the fact that TNBC subtype frequently show morphologic evidence of hypoxia (central fibrosis and necrosis) [40, 41] an augmented expression of HIF-1 $\alpha$  in tumors with a triple-negative phenotype was anticipated. In fact, this had been elegantly demonstrated through the preferential expression of HIF-1 $\alpha$  in peri-necrotic tumor cells in TNBC and BRCA1 mutated breast cancers [42].

HIF-1 $\alpha$  overexpression is an indicator of poor prognosis and significant survival time reduction in patients suffering from breast cancer [45]. HIF-1 upregulates transcription of angiogenic genes like EPO and vascular endothelial growth factor (VEGF), which induce sprouting of new vessels and in result they increase the risk of metastasis because they boost surface of contact between tumor cells and vasculature. HIF-1 induces transcription of cytoprotective proteins in malignant cells in hypoxic conditions. HIF-1 $\alpha$  predicts poor prognosis breast cancer [46, 47].

## 11. Conclusions

Demonstration of statistically significant relationship between HIF-1  $\alpha$  expression and tumor size (pT) in patients diagnosed with triple-negative breast cancer with lymph node metastases, may suggest that HIF-1  $\alpha$  expression in this group of patients may be an additional and significant marker in the evaluation of advance of the disease, affecting therapeutic decisions.

## Conflict of interests

The authors declare that there is no conflict of interests regarding the publication of this paper.

## Author details

Anna Maria Badowska-Kozakiewicz\* and Michał Piotr Budzik

\*Address all correspondence to: [abadowska@wum.edu.pl](mailto:abadowska@wum.edu.pl)

Department of Biophysics and Human Physiology, Medical University of Warsaw, Warsaw, Poland

## References

- [1] Adkins FC, Gonzalez-Angulo AM, Lei X, et al. Triple-negative breast cancer is not a contraindication for breast conservation. *Annals of Surgical Oncology*. 2011;**18**:3164-3173
- [2] Brenton JD, Carey LA, Ahmed AA, et al. Molecular classification and molecular forecasting of breast cancer: Ready for clinical application? *Journal of Clinical Oncology*. 2005;**23**:7350-7360
- [3] Ogawa Y, Moriya T, Kato Y, et al. Immunohistochemical assessment for estrogen receptor and progesterone receptor status in breast cancer: Analysis for a cut-off point as the predictor for endocrine therapy. *Breast Cancer*. 2004;**11**:267-275
- [4] Goldhirsch A, Wood WC, Coates AS, et al. Strategies for subtypes dealing with the diversity of breast cancer highlights of the St.Gallen International Expert Consensus on the Primary Therapy of Early Breast Cancer 2011. *Annals of Oncology*. 2011;**22**:1736-1747
- [5] Perou CM, Sørliet T, Eisen MB, et al. Molecular portraits of human breast tumours. *Nature*. 2000;**406**:746-752
- [6] Prat A, Adamo B, Cheang MC, et al. Molecular characterization of basal-like and non-basal-like triple-negative breast cancer. *The Oncologist*. 2013;**18**:123-133
- [7] Howland NK, Driver TD, Sedrak MP, et al. Lymph node involvement in immunohistochemistry-based molecular classification of breast cancer. *The Journal of Surgical Research*. 2013;**185**:697-703



- [8] Montagna E, Maisonneuve P, Rotmensz N, et al. Heterogeneity of triple-negative breast cancer: Histologic subtyping to inform the outcome. *Clinical Breast Cancer*. 2013;**13**:31-39
- [9] Somali I, Ustaoglu BY, Tarhan MO, et al. Clinicopathologic and demographic evaluation of triple-negative breast cancer patients among a Turkish patient population: A single center experience. *Asian Pacific Journal of Cancer Prevention*. 2013;**14**:6013-6017
- [10] Atchley D, Albarracin C, Lopez A, et al. Clinical and pathologic characteristics of patients with BRCA-positive and BRCA-negative breast cancer. *Journal of Clinical Oncology*. 2008;**26**:4282-4288
- [11] Bertucci F, Finetti P, Birnbaum D. Basal breast cancer: A complex and deadly molecular subtype. *Current Molecular Medicine*. 2012;**12**:96-110
- [12] Rastelli F, Biancanelli S, Falzetta A, et al. Triple-negative breast cancer: Current state of the art. *Tumori*. 2010;**96**:875-888
- [13] Lehmann BD, Bauer JA, Chen X, et al. Identification of human triple-negative breast cancer subtypes and preclinical models for selection of targeted therapies. *The Journal of Clinical Investigation*. 2011;**121**:2750-2767
- [14] den Hollander P, Savage MI, Brown PH. Targeted therapy for breast cancer prevention. *Frontiers in Oncology*. 2013;**3**:250
- [15] Lakhani SR, Ellis IO, Schnitt SJ, et al. editors. WHO Classification of Tumours of the Breast, Lyon. IARC; 2012
- [16] Criscitiello C, Azim HA Jr, Schouten PC, et al. Understanding the biology of triple-negative breast cancer. *Annals of Oncology*. 2012;**23**(Suppl 6):vi13-vi18
- [17] Rosen PP, Hoda SA. Breast Pathology. Diagnosis by Needle Core Biopsy. 3rd ed. Philadelphia: Wolters Kluwer, Lippincott Williams & Wilkins; 2010
- [18] Ridolfi RL, Rosen PP, Port A, et al. Medullary carcinoma of the breast: A clinicopathologic study with 10 year follow-up. *Cancer*. 1977;**40**:1365-1385
- [19] Eiermann W, Bergh J, Cardoso F, et al. Triple negative breast cancer: Proposals for a pragmatic definition and implications for patient management and trial design. *Breast*. 2012;**21**:20-26
- [20] Arpino G, Clark GM, Mohsin S, et al. Adenoid cystic carcinoma of the breast: Molecular markers, treatment, and clinical outcome. *Cancer*. 2002;**94**:2119-2127
- [21] Sharma P. Biology and management of patients with triple-negative breast cancer. *The Oncologist*. 2016;**21**:1050-1062
- [22] Carey LA, Dees EC, Sawyer L, et al. The triple negative paradox: Primary tumor chemosensitivity of breast cancer subtypes. *Clinical Cancer Research*. 2007;**13**:2329-2334
- [23] Dieci MV, Criscitiello C, Goubar A, et al. Prognostic value of tumor-infiltrating lymphocytes on residual disease after primary chemotherapy for triple-negative breast cancer: A retrospective multicenter study. *Annals of Oncology*. 2015;**26**:1518

- [24] Tutt A, Ellis P, Kilburn L, et al. The TNT trial: A randomized phase III trial of carboplatin (C) compared with docetaxel (D) for patients with metastatic or recurrent locally advanced triple negative or BRCA1/2 breast cancer (CRUK/07/012). *Cancer Research*. 2015;**75**:S3-S01
- [25] Byrski T, Huzarski T, Dent R, et al. Pathologic complete response to neoadjuvant cisplatin in BRCA1-positive breast cancer patients. *Breast Cancer Research and Treatment*. 2014;**147**:401-405
- [26] Medioni J, Huchon C, Le Frere-Belda MA, et al. Neoadjuvant dose-dense gemcitabine plus docetaxel and vinorelbine plus epirubicin for operable breast cancer: Improved prognosis in triple-negative tumors. *Drugs in R&D*. 2011;**11**:147-157
- [27] Wahba HA, El-Hadaad HA. Current approaches in treatment of triple-negative breast cancer. *Cancer Biology & Medicine*. 2015;**12**:106-116
- [28] Székely B, Silber AL, Pusztai L. New therapeutic strategies for triple-negative breast cancer. *Oncology (Williston Park, N.Y.)*. 2017;**31**:130-137
- [29] Gradishar WJ, Anderson BO, Balassanian R, et al. Invasive breast cancer version 1.2016, NCCN clinical practice guidelines in oncology. *Journal of the National Comprehensive Cancer Network*. 2016;**14**:324-354
- [30] Miller K, Wang M, Gralow J, et al. Paclitaxel plus bevacizumab versus paclitaxel alone for metastatic breast cancer. *The New England Journal of Medicine*. 2007;**357**:2666-2676
- [31] Rossari JR, Metzger-Filho O, Paesmans M, et al. Bevacizumab and breast cancer: A meta-analysis of first-line phase III studies and a critical reappraisal of available evidence. *Journal of Oncology*. 2012;**2012**:417673
- [32] Soliman H, Khalil F, Antonia S. PD-L1 expression is increased in a subset of basal type breast cancer cells. *PLoS One*. 2014;**9**:e88557
- [33] Meehan RS, Chen AP. New treatment option for ovarian cancer: PARP inhibitors. *Gynecologic Oncology Research and Practice*. 2016;**3**:3
- [34] Juvekar A, Burga LN, Hu H, et al. Combining a PI3K inhibitor with a PARP inhibitor provides an effective therapy for BRCA1-related breast cancer. *Cancer Discovery*. 2012;**2**:1048-1063
- [35] Garmpis N, Christos D, Garmpi A, et al. Histone deacetylases as new therapeutic targets in triple-negative breast cancer: Progress and promises. *Cancer Genomics and Proteomics*. 2017;**14**:299-313
- [36] Traina TA, Miller K, Yardley DA, et al. Results from a phase 2 study of enzalutamide (ENZA), an androgen receptor (AR) inhibitor, in advanced AR+ triple-negative breast cancer (TNBC). *Journal of Clinical Oncology*. 2015;**33**(suppl):abstr 1003

- [37] Masoud V, Pagès G. Targeted therapies in breast cancer: New challenges to fight against resistance. *World Journal of Clinical Oncology*. 2017;**8**:120-134
- [38] Xin L, Yibin K. Hypoxia and hypoxia-inducible factors: Master regulators of metastasis. *Clinical Cancer Research*. 2010;**16**:5928-5935
- [39] Dales JP, Beaufile N, Silvy M, et al. Hypoxia inducible factor 1 $\alpha$  gene (HIF-1 $\alpha$ ) splice variants: Potential prognostic biomarkers in breast cancer. *BMC Medicine*. 2010;**8**:44
- [40] Livasy CA, Karaca G, Nanda R, et al. Phenotypic evaluation of the basal-like subtype of invasive breast carcinoma. *Modern Pathology*. 2006;**19**:264-271
- [41] Fulford LG, Easton DF, Reis-Filho JS, et al. Specific morphological features predictive for the basal phenotype in grade 3 invasive ductal carcinoma of breast. *Histopathology*. 2006;**49**:22-34
- [42] Yan M, Rayoo M, Takano EA, et al. BRCA1 tumors correlate with a HIF-1 $\alpha$  phenotype and have a poor prognosis through modulation of hydroxylase enzyme profile expression. *British Journal of Cancer*. 2009;**101**:1168-1174
- [43] Tan EY, Yan M, Campo L, et al. The key hypoxia regulated gene CAIX is upregulated in basal-like breast tumors and is associated with resistance to chemotherapy. *British Journal of Cancer*. 2009;**100**:405-411
- [44] Choi J, Jung WH, Koo JS. Metabolism-related proteins are differentially expressed according to the molecular subtype of invasive breast cancer defined by surrogate immunohistochemistry. *Pathobiology*. 2013;**80**:41-52
- [45] Schindl M, Schoppmann SF, Samonigg H, et al. Overexpression of hypoxia-inducible factor 1 $\alpha$  is associated with an unfavorable prognosis in lymph node-positive breast cancer. *Clinical Cancer Research*. 2002;**8**:1831-1837
- [46] Dales JP, Garcia S, Meunier-Carpentier S, et al. Overexpression of hypoxia-inducible factor HIF-1 $\alpha$  predicts early relapse in breast cancer: Retrospective study in a series of 745 patients. *International Journal of Cancer*. 2005;**116**:734-739
- [47] Kronblad A, Jirstrom K, Ryden L, et al. Hypoxia inducible factor-1 $\alpha$  is a prognostic marker in premenopausal patients with intermediate to highly differentiated breast cancer but not a predictive marker for tamoxifen response. *International Journal of Cancer*. 2006;**118**:2609-2616
- [48] Naldini A, Filippi I, Miglietta D, et al. Interleukin-1 $\beta$  regulates the migratory potential of MDAMB231 breast cancer cells through the hypoxia-inducible factor-1 $\alpha$ . *European Journal of Cancer*. 2010;**46**:3400-3408
- [49] Seow A, Koh WP, Chia KS, et al. Trends in cancer incidence in Singapore 1968-2002. *Singapore Cancer Registry Report*. 2004:6

- [50] Thike AA, Cheok PY, Jara-Lazaro AR, et al. Triple-negative breast cancer: Clinicopathological characteristics and relationship with basal-like breast cancer. *Modern Pathology*. 2010;**23**:123-133
- [51] Nofech-Mozes S, Trudeau M, Kahn HK, et al. Patterns of recurrence in the basal and non-basal subtypes of triple-Negative breast cancers. *Breast Cancer Research and Treatment*. 2009;**118**:131-137
- [52] Williams DJ, Cohen J, To TV, et al. Triple negative breast carcinoma in women from Vietnam and United States: Characterization of differential markers expression by tissue microarray. *Human Pathology*. 2009;**40**:1176-1181
- [53] Atik E, Guray M, Ozgur T, et al. Characterization of immunohistochemical markers in triple negative breast carcinomas. *JBUON*. 2013;**18**:886-890
- [54] Rao C, Shetty J, Krishan Prasad HL. Immunohistochemical profile and morphology in triple-negative breast cancers. *Journal of Clinical and Diagnostic Research*. 2013; **7**:1361-1365
- [55] Osman NM, Chalabi N, Raboh NMA. Triple negative breast cancer: MRI features in comparison to other breast cancer subtypes with correlation to prognostic pathologic factors. *Egyptian Journal of Radiology and Nuclear Medicine*. 2014;**45**:1309-1316
- [56] Sood N, Nigam JS. Correlation of CK5 and EGFR with clinicopathological profile of triple negative breast cancer. *Pathology Research International*. 2014; 6 p. Article ID: 141864. <http://dx.doi.org/10.1155/2014/141864>
- [57] Tawfik O, Davis K, Kimler BF, et al. Clinicopathological characteristics of triple negative invasive mammary carcinomas in African-American versus Caucasian women. *Annals of Clinical and Laboratory Science*. 2010;**40**:315-323
- [58] Carey LA, Perou CM, Livasy CA, et al. Race, breast cancer subtypes, and survival in the Carolina breast cancer study. *Journal of the American Medical Association*. 2006;**295**:2492-2502
- [59] Dabbs DJ, Chivukula M, Carter G, et al. Basal phenotype of ductal carcinoma in situ: Recognition and immunohistologic profile. *Modern Pathology*. 2006;**19**:1506-1511
- [60] Choi J, Jubg WH, Koo JS. Clinicopathologic features of molecular subtypes of triple negative breast cancer based on immunohistochemical markers. *Histology and Histopathology*. 2012;**27**:1481-1493
- [61] Zhou L, Li K, Luo Y, et al. Novel prognostic markers for patients with triple – Negative breast cancer. *Human Pathology*. 2013;**44**:2180-2187
- [62] Thike AA, Iqbal J, Cheok PY, et al. Triple negative breast cancer: Outcome correlation with immunohistochemical detection of basal markers. *American Journal of Surgical Pathology*. 2010;**34**:956-964

- [63] Rakha EA, El-Sayed ME, Green AR, et al. Prognostic markers in triple-negative breast cancer. *Cancer*. 2007;**109**:25-32
- [64] Yehia L, Boulos F, Jabbour M, et al. Expression of HIF-1 $\alpha$  and markers of angiogenesis are not significantly different in triple negative breast cancer compared to other breast cancer molecular subtypes: Implications for future therapy. *PLoS One*. 2015;**10**:e0129356. DOI: 10.1371/journal.pone.0129356

