

---

# Cruciate-Retaining Total Knee Arthroplasty

---

Vittorio Calvisi, Alessandro Paglia,  
Norman Ciprietti and Remo Goderecci

Additional information is available at the end of the chapter

<http://dx.doi.org/10.5772/intechopen.74024>

---

## Abstract

The debate over the relative merits of substituting or retaining the posterior cruciate ligament (PCL) in total knee arthroplasty is still ongoing. The potential advantages of PCL preservation are a more natural femoral rollback, the presence of a structure critical for the proprioception, the maintenance of a native central stabilizer of the joint, and low shear stress on the bone-cement interface of the tibial component. Numerous retrospective studies of cruciate-retaining (CR) total knee arthroplasties have demonstrated consistently good clinical results and excellent intermediate and long-term survival. The main criticisms of the surgical technique are that the distal attachment of the PCL is vulnerable to injury and that balancing the PCL can be difficult; based on our experience, surgical tricks will be described to avoid the avulsion of the ligament and they will be discussed the main points to consider when you can find a discrepancy between flexion and extension stability. Based on the current evidence, we conclude that with a standardized technique, this type of implant should be preferred even in those cases where the sacrifice of the cruciate ligament seems to be the easiest way.

**Keywords:** total knee arthroplasty, cruciate-retaining, posterior cruciate ligament, surgical technique, balancing, advantages

---

## 1. Introduction

The main goal of a prosthetic implant is to restore joint function and to eliminate pain. Given the exponential increase in the number of knee arthroplasties, both due to an increase in the average life expectancy and to changes in lifestyle of patients (that maintain a high level of physical activity even at an advanced age), development of prosthetic implants that could reproduce as better as possible the normal knee kinematic and could endure for a long time

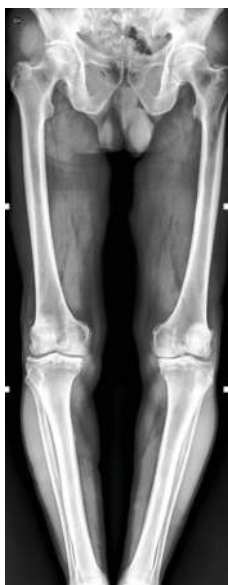is the main goal of the developers of these devices; cruciate-retaining total knee replacement (CR-TKR) was introduced to try to achieve these results.

The many reasons for retaining the posterior cruciate ligament (PCL) during total knee replacement (TKR) include improved stability, reduced shear stresses at the fixation interface, improved proprioception, and more efficient gait patterns during level walking and stair climbing; moreover, one of the most commonly cited motives for retaining the PCL is to preserve femoral rollback, which improves extensor efficiency by lengthening the moment arm and improves the range of flexion by minimizing the potential for impingement of the femur on the tibial component, reducing loosening and excessive polyethylene wear.

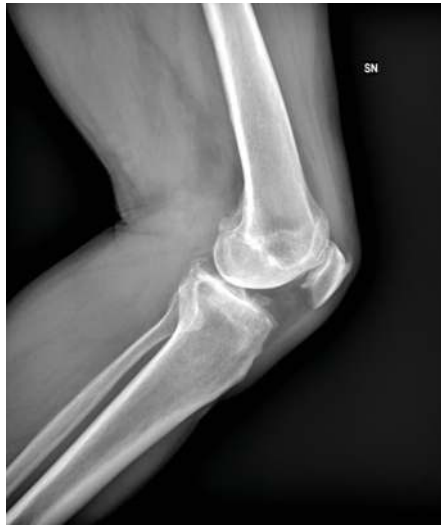## 2. Indications

The classic indications for a PCL retaining total knee arthroplasty (TKA) are fixed flexion of less than  $30^\circ$ , varus less than  $20^\circ$ , and valgus less than  $25^\circ$ ; joint subluxation of no more than 1 cm; structurally intact PCL (**Figures 1 and 2**); and technical ability of the surgeon [1].

In our experience, we also use this type of implant even in the revision of a unicompartmental knee replacement caused by an aseptic loosening of the tibial component: with the use of a tibial stem, associated if necessary with an augment, we spare the PCL avoiding the



**Figure 1.** Anteroposterior view of full-length lower extremity radiographs of a patient suitable for a CR-TKR.



**Figure 2.** Lateral view of knee radiographs of a patient suitable for a CR-TKR.

intercondylar notch cut: the aim to preserve more bone as possible taking into account that in the vast majorities of cases, these are young patients that will have the risk to require a further revision in the future.

### 3. Clinical outcomes

Numerous retrospective studies of CR TKAs have demonstrated consistently good clinical results and excellent intermediate and long-term survival [2–5].

While first studies about old generation of CR systems showed systemically a survivorship of 90% at 10 years, new type of implant demonstrated an improved longevity to 96–100% after 10 years. National joint registries are very useful instrument to understand this phenomenon: 14th Annual report of National Joint Registry for England, Wales, Northern Ireland and the Isle of Man updated to December 31, 2016 recounts that from 2003 “More than half of all operations (56.6%) were total knee replacements which were all cemented, unconstrained and fixed, followed by 20.7% which were all cemented, posterior stabilised and fixed... Two-thirds (66.6%) of cemented implants are unconstrained (cruciate-retaining) and have a fixed bearing... The main decline in the type of primary knee surgery carried out has been in the use of all uncemented and hybrid total knee replacements over time...” (less than a third of those figures reported for the year 2003). Analyzing the risk of revisions after primary knee surgery by fixation method and constraint, it reveals how “...Cemented unconstrained, fixed bearing total knee replacement results in lower chances of revision overall compared to other combinations of constraint

and bearing used in a cemented fixation of the joint with modular tibial components” and “... Uncemented/hybrid total knee replacements with posterior stabilised constraint and fixed bearings fare worse than their unconstrained bearing equivalents” [6]. Similar results were carried out by the Australian Orthopaedic Association National Joint Replacement Registry (AOANJRR) 2017 Annual Report: it describes as “...the use of minimally stabilised prostheses has remained relatively constant over the last 10 years. In 2016, these accounted for 67.4% of the three prosthesis types. The use of posterior stabilised prostheses has declined from 32.9% in 2008 to 25.6% in 2016.” It also reports that “...Posterior stabilised and medial pivot prostheses have a higher rate of revision compared to minimally stabilised” stating that “...Posterior stabilised prostheses have a higher cumulative incidence of infection...” and “also have a higher cumulative incidence of loosening compared to minimally stabilised prostheses” [7].

Focusing on the differences in clinical outcomes between TKRs with retention versus sacrifice of the PCL, a Cochrane Review published in 2013 by Verra et al. found 17 randomized controlled trials that lead to following conclusion: “... With respect to range of motion, pain, clinical, and radiological outcomes, no clinically relevant differences were found between total knee arthroplasty with retention or sacrifice of the posterior cruciate ligament. Two statistically significant differences were found; range of motion was 2.4° higher in the posterior cruciate ligament sacrificing group, however results were heterogeneous; and the mean functional Knee Society Score was 2.3 points higher in the posterior cruciate ligament sacrificing group...” but “...These differences are clinically not relevant” [8].

More recent meta-analysis obtained the same clinical conclusion [9, 10].

#### 4. Kinematic

Numerous prostheses have been developed to improve the durability and function of TKR and kinematic principles that have been the focus of current implant designs, have been to replicate the native knee’s femoral rollback during flexion and the external rotation of the femoral component relative to the tibial component.

In the normal knee, a rolling motion predominates for the first 20° of flexion, which produces a posterior translation of the femoral contact position on the tibia. After 30° flexion, sliding becomes predominant but the net motion remains in the posterior direction [11] and the PCL performs several functions: It guides the rollback of the femoral condyles on the tibial plates during flexion, thus allowing the back portion of the condyles to clear the posterior surface of the tibia at high bending degrees and improving the mechanical efficiency of extensor apparatus; from the point of view of stability, it prevents the posterior subluxation of the tibia on the femur during flexion, with a critical secondary role in stability in varus and valgus with knee flexion [12].

Several studies about CR-TKR evaluated in the past the kinematic of this type of implant: Stiehl et al. in a fluoroscopic analysis showed that CR-TKR “...did not reproduce normal knee Kinematics in any case, but showed a starting point posterior to the tibial midline which translated anteriorly with flexion...” and “...Physiological roll-back has not been demonstrated

and its absence is likely to reflect anterior cruciate deficiency, alteration of the normal joint line, or other subtle changes which modify kinematics..." [11]. Similar results were obtained by Dennis et al. in 1998: they found that "...a lack of customary posterior femoral rollback in posterior cruciate-retaining designs, and conversely showing an average anterior femoral translation with knee flexion. Posterior femoral rollback, less than in normal knees, routinely was observed in posterior cruciate substituting total knee arthroplasty, attributed to engagement of the femoral component cam with the tibial post" [13]. However, the same author in a study of 2002, using a standardized technique and a specific new generation implant, found that "the subjects...experienced consistent posterior femoral rollback of the posterior cruciate-retaining total knee arthroplasty" and concluded that "having asymmetric femoral condyles may lead to PFR with increasing knee flexion" [14].

A more recent study by Banks et al. also demonstrated that "...greater axial rotations were associated with complete preservation of the PCL insertion." Definitely, in this study, it was shown a normal axial rotation and a normal condylar translation in CR group, while "cruciate-substituting or post/cam substitution of PCL... exhibited lower ranges of axial rotation and condylar translation than the implant was designed to accommodate."

The key point is that the joint surfaces should be designed to be compatible with normal femoral rollback. Components with different curvature radius of the two condyles allow the femoral component to roll back much more laterally than medially, as on the normal knee. On the tibial side, a slightly flattened design in the sagittal plane makes the best use of the PCL preservation, allowing the femur to roll backward and rotate in a relatively normal way. At the same time, a significant congruity in the frontal plane helps to minimize stress on polyethylene, thus reducing long-term wear [12].

## 5. Posterior tibial slope

As widely explained by Sierra and Berry when performing a CR-TKR, modest posterior slope (matching patient's native slope between 3 and 7°) may help reduce tension on the PCL and facilitate knee flexion [15]. Posterior tibial slope (PTS) opens the flexion space, and this helps to obtain flexion without PCL recession. However, excessive slope may lead to compromise the insertion point of the PCL into the tibia, which can lead to flexion instability and to reduced or paradoxical femoral rollback reported more frequently in CR than in PS TKR.

One of the last biomechanical discoveries showed as an "increased PTS was associated with biomechanical effects leading to reductions in quadriceps force, contact stress on PF joint, and force on PCL. However, excessive PTS should be avoided to prevent progressive loosening of the TF joint gap due to the reduction of collateral ligament tension during flexion" [16].

A reduced slope can generally lead to lift-off positive test in flexion whose treatment will be extensively described in the technique paragraph.

In conclusion, evaluating the tibial slope is a crucial phase in CR-TKR, since as recently explained by Dae Kyung Bae et al. the steepness of the PTS is one of the main factors that requires the conversion to PS from a CR-type prosthesis [17].

## 6. Midflexion stability

For a successful TKR, the wide range of movement is not the only objective to achieve, but also joint stability plays a crucial role. During most activities of daily living, the knee is loaded not only in full extension but also in midflexion, and therefore, stability throughout flexion should be considered an important outcome measure. As the PCL is thought to serve as a secondary stabilizer of the knee during varus and valgus stresses, it is likely that the presence of this ligament has some effects on midflexion stability.

In a cadaveric study of 1999, Mihalko observed "...that a major result of posterior cruciate ligament sacrifice is the creation of a larger flexion gap. This result provides insight into relative joint line changes that can occur after posterior cruciate ligament sacrifice....," suggesting... "the need for greater attention to flexion stability when sacrificing the posterior cruciate ligament" [18]. In a 2008 study, Tsuneizumi et al. similarly concluded that "...the PCL kept the knee stable against distal traction force in the flexion position, and sacrifice of this ligament caused joint laxity in different ranges. The increases in the flexion gap after resection of the PCL varied among individuals" [19].

In 2013, Hino et al. focused on stability through the range of movement pinpointing the exact degrees that make differences between CR and PS TKRs stability: "Specifically, CR knees had significantly less laxity in the flexion range of 10 to 30° than PS knees..." demonstrating "...a significant decrease in joint laxity at 120° of flexion for CR-TKRs and in contrast PS TKRs had an increase in joint laxity between 10 and 20° of flexion post-operatively. Overall, CR knees demonstrated less joint laxity than PS knees throughout the whole range of movement." They concluded that "CR knees have less post-operative laxity, especially in deep flexion..." and "...this may be associated with the lower flexion range that could be seen in CR knees" [20].

## 7. Joint line position

Since restoration of joint line can be difficult in severe osteoarthritic knee with coronal and sagittal plane deformities, many surgeons prefer the use of a PS TKR, which is less sensitive to changes in joint line position: in fact, the level of the reconstructed joint line is one of the main factors that affects the tension of the retained PCL [21]. As reported by Emodi et al. in a cadaveric study "As the joint line was elevated, PCL strain increased at all measured flexion angles above 30°..." and "...the centre of tibio-femoral contact did not change at the flexion angles of 15 and 30°..." but "...at 60, 90 and 105° the tibio-femoral contact centre moved posteriorly with each successive elevation of the joint line." This author also confirmed what already reported in literature that "...Significant decreases in flexion were observed with as little as 2 mm of elevation. Flexion was limited further as the joint line

was elevated 4 and 6 mm, and was partially restored following cruciate excision..." and "... The effect of joint line elevation on normalized quadriceps load and patella-femoral contact pressures was observed only at higher flexion angles..." [22].

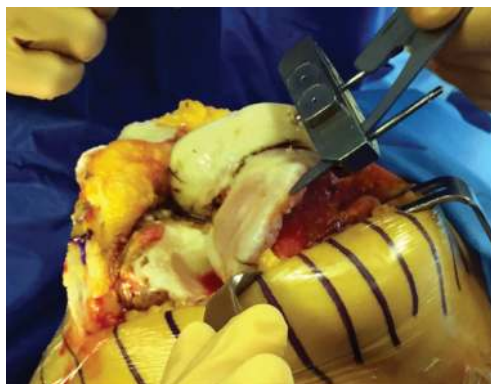## 8. Authors' preferred surgical technique

A standard midline longitudinal approach is performed with medial parapatellar arthrotomy and lateral patellar dislocation; the knee joint is exposed and the Whiteside line and the transepicondylar axis are marked (they are used as femoral rotational landmarks); the intramedullary femoral guide is drilled into the femur; a 9-mm distal femoral bone resection is performed with a valgus angle preoperatively planned (**Figure 3**).

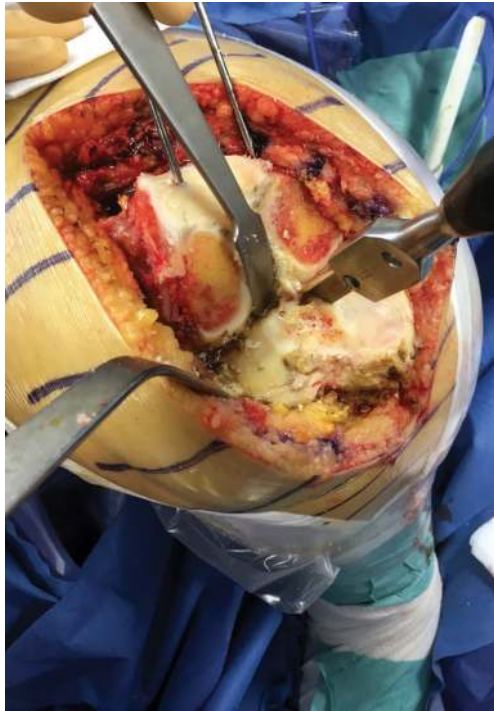For the tibial side, Hohmann retractors are employed to protect lateral and medial soft tissues (critical structures for a correct balancing); the tibial spine is removed using a surgical saw.

Then through the use of an osteotome, a bone island really closer to the distal insertion of PCL is circumscribed (**Figures 4 and 5**). A pin is placed in front of the PCL defining the anterior side of the island (**Figure 6**); we make use of the extramedullary tibial resection guide to align the tibial mechanical axis; an amount of resection equal to the thickness of the tibial arthroplasty component is measured on the less osteoarthritic plateau and tibial resection is performed beware not to get across the lateral and medial sides of marked bone island. The employment of the osteotome is an essential step: it allows to incise the posterior cortex avoiding during the tibial plateau excision the risk of avulsion and subsequent detachment of the PCL.

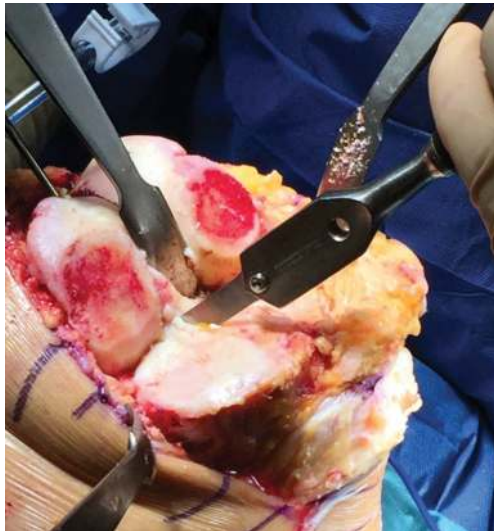
With these precautions, the tibial plateau is removed (**Figures 7–9**) and the bone island can be carefully shaped through a nibbler to permit the placement of the posterior side of the tibial component (**Figures 10 and 11**).



**Figure 3.** Distal femur cut: with the angel wing, you can appreciate the minimal resection in order to maintain the level of the joint line position.

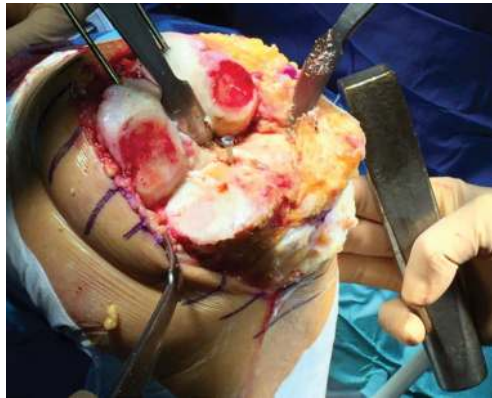


**Figure 4.** Through the use of an osteotome, a bone island is circumscribed.

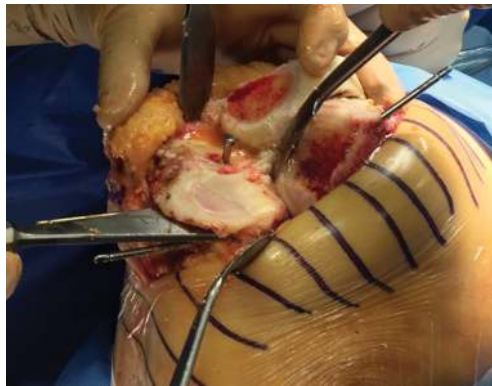


**Figure 5.** The incision of the posterior cortex necessary to avoid a posterior avulsion.

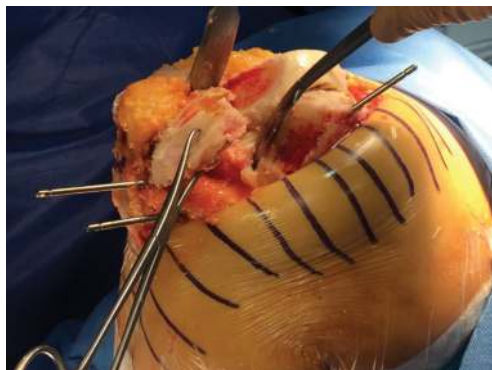



**Figure 6.** A pin is placed in front of the PCL defining the anterior side of the island.



**Figure 7.** The tibial plateau is detached.



**Figure 8.** The tibial plateau is removed.

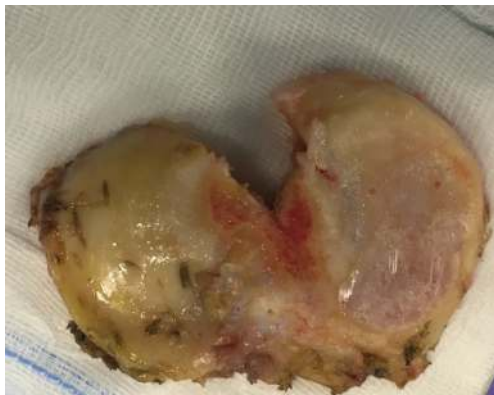

Figure 9. Superior view of the removed plateau.

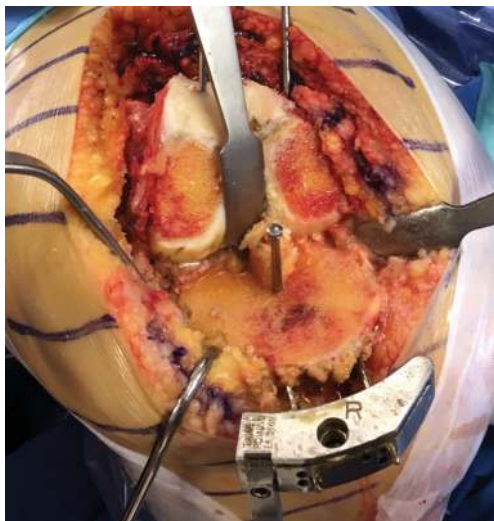
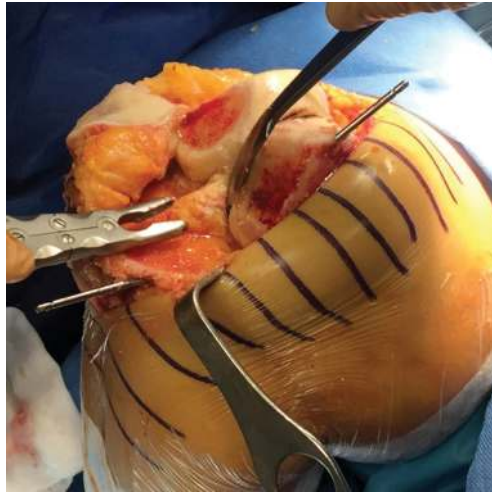


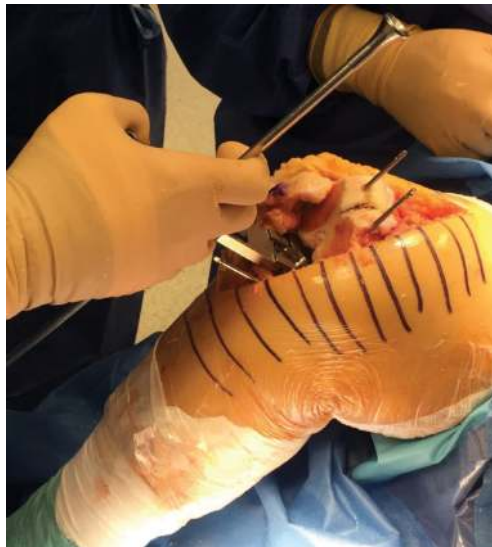Figure 10. The aspect of the tibial side after the cut with the preservation of the PCL.

The following step, with knee flexed at 90°, is defining the size and the position of the femoral component; we utilize an asymmetric spacer (flexion spacer by Biomet) (**Figure 12**) to perform a posterior condylar femoral resection perpendicular to the Whiteside line and in order to obtain equal medial and lateral gaps and to achieve the same space both in flexion and extension. By posterior referencing, 4-in-1 cutting block (set for the measured implant size and the rotational alignment previously evaluated) is placed and the anterior, posterior, anterior chamfer, and posterior chamfer cuts are performed.



**Figure 11.** The bone island can be shaped through a nibbler or a Luer.

Through the use of a gap spacer, the alignment and varus or valgus ligamentous balance are always tested both in extension and in flexion. The space between the femoral and the tibial cut surfaces should be within 1–2 mm of each other both in flexion and extension [23].



**Figure 12.** Balancing the space in flexion through the flexion spacer by Biomet.

When the desired balancing and gaps are achieved, the femoral, tibial, and insert trial components of the correct size are inserted; we check the maximum extension and flexion and then stability and the patellar tracking in the full range of movement; usually, we do not perform patellar resurfacing [24] but just remove osteophytes.

Once the tibial stem hole is created and the preparation procedure is completed, we perform a wash of the joint and then insert definitive cemented components and the polyethylene bearing of the previously evaluated size.

## 9. Consideration about surgical technique

We think that to improve an already successful procedure, as TKR was well demonstrated to be, we need to look at small details.

In the debate between PS versus CR-TKR, the main reason in favor of PCL sacrifice is that balancing a joint with an intact PCL could be very difficult, especially in case of drastic deformities as severe fixed flexion, varus or valgus angulations more than 20° or considerable joint subluxation: but in these cases, we think that probably PS implant is not the solution since should be preferable the use of a more constrained implant.

We think that the ability of the surgeon is critical to obtain a good CR replacement; technical difficulties lead to a longer learning curve, but using some tips and having cleared all basic science considerations explored in the previous paragraphs, you can achieve good results even in the most difficult cases.

Taking these points into account, the first element to consider is that the goal of the procedure is both to place the TKA in neutral mechanical alignment and to obtain a knee stable in all range of movement. In CR-TKR, the main criticism of the process is the preservation of the PCL and consequent balance of the spaces.

Performing a CR-TKR, the main criticism of the surgical technique is that the distal attachment of the PCL is vulnerable to injury during the tibial resection; the distal attachment of the PCL is located posterior and distal to the tibial plateau, so the application of a protective device on the front is really useful to safeguard it; however, excessive bone resection from the proximal tibia (i.e., greater than 1 cm) or a large posteriorly sloped cut may anyway jeopardize the tibial attachment of the PCL and it has been demonstrated that a pin of minimum 1.7 mm of length ensures a larger margin of safety [25]. In addition, the creation of a bone island with the incision of the posterior cortex is really useful to avoid the avulsion of the ligament during the removal of the plateau.

The second element is that in order to accurately balance the joint, the surgeon can remove less bone from the distal femur (typically matching the thickness of the femoral implant which should be chosen to reproduce the A-P size of the back of native femoral condyles) in comparison to what would be done for a PS TKR (**Figure 7**); due to the retention of the PCL in a CR-TKR, the flexion gap will remain smaller (in a range of 1.8–4.8 mm) than what would be created for a PS implant; therefore, the goal is to keep the extension gap small as well [15].

The third element is about the slope of the tibial cut: posterior slope opens the flexion space and this helps to obtain flexion without PCL recession. Therefore, a modest posterior slope (typically matching the patient's native slope within the range of 3–7°) may help to reduce tension on the PCL and this may facilitate knee flexion. If the extension gap is asymmetrical, it is necessary to perform a ligamentous release in order to obtain a symmetric space, and the gap size finally should be verified with a spacer block. Reflecting on the solution to achieve a symmetrical space in the flexion gap, it is really important to consider what type of instrument we are using: if we get the restoration of a neutral mechanical alignment in extension through the use of an intramedullary device for the femur and an external guide for the tibia, in our experience, the best instrument that helps us to get the correct rotation of femur in flexion is the flexion spacer by Biomet; in fact, it is always referred to the tibial osteotomy (that regardless of surgeon accuracy should be 1° or 2° in valgus or varus deviation) and allows us to reach a parallel cut even in case of a severe lateral condyle hypoplasia thanks to its multiple choice in asymmetrical components (1°, 3°, 4°, 5°, 6°, 8°). Once rotation is obtained, the following step is to determine the depth of the flexion gap. Not only does the flexion gap need to be rectangular (indication of rotation), but it also needs to obtain the same size of the extension gap. Through the use of the flexion spacer, the normal posterior condyle offset is recreated. Then, the depth of the anterior cut is not measured directly but rather determined by the size of the 4-in-1 cutting jig; it may be too shallow (this will cause overstuffing of the patellofemoral joint) or it may be too deep (this will cause notching) [26].

Nevertheless, problems can occur once that bone cuts are performed and trial components are inserted.

A slightly lax PCL is preferable to one that is excessively tight, but an overly lax PCL can result in functional disability secondary to flexion instability. Balance of the PCL should be assessed after correction of any varus or valgus ligamentous imbalance. An excessively tight PCL will result in anterior translation of the tibia from beneath the femur, anterior lift-off of the trial polyethylene from the tibia tray in flexion, and/or displacement of the femoral component in flexion. A useful test of the relative balance of the PCL is the so-called POLO (for PullOut, LiftOff) test introduced by Dr. Richard Scott. In this test, a trial reduction is done with a stemless tibial trial and a curved tibial insert. The PullOut portion of the test is done at 90° of flexion and confirms that the PCL is not too loose if the tibial insert cannot be subluxed (pulled out) anteriorly from beneath the femur. The LiftOff portion is done while putting the knee through a range of motion up to 120° and ensuring that the tibial insert does not look open (lift-off) in flexion, indicating that the PCL is too tight. Scott postulates that if the PCL is not too loose and not too tight, then it must be just right [1].

If the PCL is excessively tight, the tension can be decreased by several techniques. Increased tibial bone resection is only appropriate if the knee is tight in both flexion and extension. If the knee is tight only in flexion, increasing tibial bone resection will leave the knee lax in extension, resulting in symptomatic instability due to hyperextension or excessive varus-valgus play. If the knee is tight only in flexion, the posterior slope of the tibial cut should be assessed. The tibia normally has a 3 to 7° degree posterior slope. The amount of posterior slope cut on the tibia will be dependent on the prosthetic design. Some implants have an inherent posterior slope in the articular geometry and will require less posterior slope than knees with a flat

geometry in the sagittal plane. Increasing posterior slope for the tibial resection will relax the PCL. Posterior tibial slope typically should not exceed  $10^\circ$  to avoid risk of injury to the tibial attachment of the PCL. Posterior cruciate recession consists of selective release of the anterior fibers of the PCL from their tibial attachment. Release of the anterior 10–20% of the PCL can often help achieve the correct soft tissue balance. If greater than 75% of the PCL is released, some feel a PCL-substituting prosthesis should be considered. The concern in those cases is that the remaining 25% of the PCL fibers may rupture later with activity, leading to flexion instability. If the PCL is released or absent, the tibial tray should be more conforming because rollback does not occur. Hence, the surgeon should match the constraints of the soft tissue with the inherent constraints of the knee system being used [1].

A knee that is tighter in flexion requires one or a combination of maneuvers that include PCL release, downsloping the tibial resection, downsizing the femoral component, or additional tibial resection with distal advancement of the femoral component. A knee that is tighter in extension is usually corrected merely by added distal femoral resection [1].

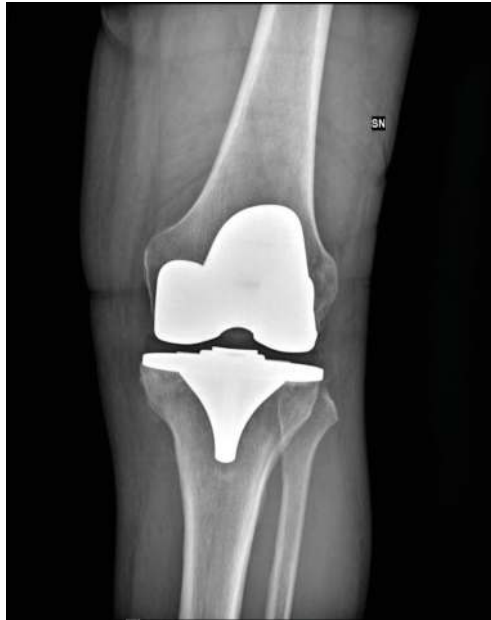## 10. Conclusion

The most recent literature and National Joint registries confirm that CR-TKR has good clinical results and excellent intermediate and long-term survival.

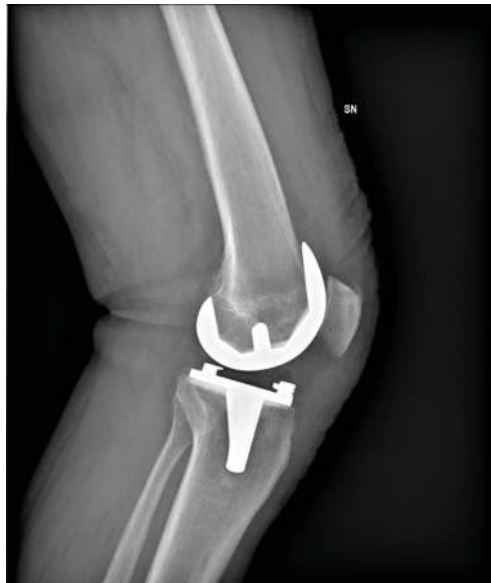If in the past many studies argued that CR implant lead to paradoxical kinematic, more recent and relevant studies demonstrated that with new design components and well-standardized technique, the native femoral rollback is better restored with a CR-TKR than with a PS implant. International studies also confirm that the stability in all range of movement can successfully be achieved, and care must be paid to joint line position and posterior tibial slope when performing a CR replacement; in fact, they are two of the main factors that affect the tension of the retained PCL. Less femoral distal cut as possible should be executed to not compromise gap balances between extension and flexion: in fact, the retention of the PCL lead to a smaller space in flexion than what obtained with PCL recession, but if more space is needed in flexion (caused by a too thigh PCL), creating a more sloped tibial cut may help to reduce tension on the PCL-facilitating knee flexion.

The main criticism of the surgical technique is that the distal attachment of the PCL is vulnerable to injury during the tibial resection and the creation of a bone island through the use of an osteotome and a pin in front of the ligament can protect it from a damage that could seriously cause difficulties in balancing; balancing a PCL, especially in case of severe deformities, can be difficult but many tests and solution have been successfully proposed to understand and solve different complex combinations (**Figures 13 and 14**).

We think that performing a CR-TKR is difficult and requires a long learning curve, but at the same time with a standardized technique, it is always possible to prefer this type of implant even in those case wherein many surgeon would prefer a PS implant: considering that more and more young high-demanding patients are subjected to this procedure you should preserve



**Figure 13.** Anteroposterior view of knee radiographs showing successful case of a CR implant.



**Figure 14.** Lateral view of knee radiographs showing successful case of a CR implant.

as much as possible the ligamentous structures for their physiological function and avoid bone cuts as much as possible (in the CR designs, the creation of the intercondylar notch resection is not required) in the perspective of a possible revision in the future.

Finally, for severe deformities associated with ligamentous laxity, the debate about preserve or resect the PCL is out of place: in these cases, the solution should be finding in a CR or PS TKR but in a more constrained implant.

## Author details

Vittorio Calvisi, Alessandro Paglia, Norman Ciprietti and Remo Goderecci\*

\*Address all correspondence to: [remogoderecci@gmail.com](mailto:remogoderecci@gmail.com)

MESVA Department, University of L'Aquila, L'Aquila, Italy

## References

- [1] Morrey BF, Berry DJ, An K-N, Kitaoka HB, Pagnano MW. Joint Replacement Arthroplasty. 4th centennial ed. Vol. II. Philadelphia: Lippincott Williams & Wilkins, a Wolters Kluwer business; 2011
- [2] Buehler KO, EricVenn-Watson, D'Lima DD, Colwell CW Jr. The press-fit condylar total knee system: 8- to 10-year results with a posterior cruciate-retaining design. *The Journal of Arthroplasty*. September 2000;**15**(6):698-701. DOI: 10.1054/arth.2000.8189
- [3] Fetzer GB, Callaghan JJ, Templeton JE, Goetz DD, Sullivan PM, Kelley SS. Posterior cruciate-retaining modular total knee arthroplasty: A 9- to 12-year follow-up investigation. *The Journal of Arthroplasty*. December 2002;**17**(8):961-966. DOI: 10.1054/arth.2002.34824
- [4] Barrington John W, Alexander S, Henrik M, Burke Dennis W. Contemporary cruciate-retaining total knee arthroplasty with a pegged tibial baseplate: Results at a minimum of ten years. *JBJS*. April 1, 2009;**91**(4):874-878. DOI: 10.2106/JBJS.G.01609
- [5] Berger Richard A, Rosenberg Aaron G, Barden Regina M, Sheinkop Mitchell B, Jacobs Joshua J, Galante Jorge O. Long-term followup of the Miller-Galante total knee replacement. *Clinical Orthopaedics and Related Research*. July 2001;**388**:58-67
- [6] 14th Annual report of National Joint Registry for England, Wales, Northern Ireland and the Isle of Man. Prepared by The NJR Editorial Board; Mr Martyn Porter (Chairman, Editorial Board). Available from: <http://www.njrreports.org.uk>
- [7] Association National Joint Replacement Registry (AOANJRR) 2017 Annual Report. David Hale Chairperson. Available from: <https://aoanjrr.sahmri.com/annual-reports-2017>



- [8] Verra WC, van den Boom LGH, Jacobs W, Clement DJ, Wymenga AAB, Nelissen RGHH. Retention versus sacrifice of the posterior cruciate ligament in total knee arthroplasty for treating osteoarthritis. *Cochrane Database of Systematic Reviews*. 2013;(10. Art. No.: CD004803.). DOI: 10.1002/14651858.CD004803.pub3
- [9] Li N, Tan Y, Deng Y, et al. Posterior cruciate-retaining versus posterior stabilized total knee arthroplasty: A meta-analysis of randomized controlled trials. *Knee Surgery, Sports Traumatology, Arthroscopy*. 2014;**22**:556. DOI: 10.1007/s00167-012-2275-0
- [10] Bercik Michael J et al. Posterior cruciate-retaining versus posterior-stabilized total knee arthroplasty. *The Journal of Arthroplasty*;**28**(3):439-444. DOI: 10.1016/j.arth.2012.08.008
- [11] Stiehl JB, Komistek RD, Dennis DA, Paxson RD, Hoff WA. Fluoroscopic analysis of kinematics after posterior-cruciate-retaining knee arthroplasty. *Journal of Bone and Joint Surgery (British)*. 1995;**77-B**:884-889
- [12] Insall & Scott—Surgery of the Knee, 5th Edition. Edited by W. Norman Scott. Published with permission of Elsevier Inc.; 2015 Verduci Editore - Roma
- [13] Dennis DA, Komistek Richard D, Colwell Clifford E, Ranawat Chitranjan S, Scott Richard D, Thornhill Thomas S, Lapp Mark A. In vivo anteroposterior femorotibial translation of total knee arthroplasty: A multicenter analysis. *Clinical Orthopaedics and Related Research*. November 1998;**356**:47-57 Symposium: The Papers Presented at the Knee Society Meeting 1998
- [14] Bertin KC, Komistek RD, Dennis DA, Hoff WA, Anderson DT, Langer T. In vivo determination of posterior femoral rollback for subjects having a NexGen posterior cruciate-retaining total knee arthroplasty. *The Journal of Arthroplasty*. 2002;**17**(8):1040-1048
- [15] Sierra RJ, Berry DJ. Surgical technique differences between posterior-substituting and cruciate-retaining total knee arthroplasty. *The Journal of Arthroplasty*. 2008;**23**(7 Suppl):1
- [16] Kang K-T, Koh Y-G, Son J, Kwon O-R, Lee J-S, Kwon S-K. Influence of increased posterior tibial slope in total knee arthroplasty on knee joint biomechanics: A computational simulation study. *The Journal of Arthroplasty*. 2018 Feb;**33**(2):572-579. DOI: 10.1016/j.arth.2017.09.025
- [17] Bae DK, Song SJ, Kim KI, et al. Intraoperative factors affecting conversion from cruciate retaining to cruciate substituting in total knee arthroplasty. *Knee Surgery, Sports Traumatology, Arthroscopy*. 2016;**24**:3247. DOI: 10.1007/s00167-015-3971-3
- [18] Mihalko WM, Krackow Kenneth A. Posterior cruciate ligament effects on the flexion space in total knee arthroplasty. *Clinical Orthopaedics and Related Research*. March 1999;**360**:243-250
- [19] Tsuneizumi Y, Suzuki M, Miyagi J, Tamai H, Tsukeoka T, Moriya H, Takahashi K. Evaluation of joint laxity against distal traction force upon flexion in cruciate-retaining and posterior-stabilized total knee arthroplasty. *Journal of Orthopaedic Science*. 2008; **13**:504-509. DOI: 10.1007/S00776-008-1269-8

- [20] Hino K, Ishimaru M, Iseki Y, Watanabe S, Onishi Y, Miura H. Mid-flexion laxity is greater after posterior-stabilised total knee replacement than with cruciate-retaining procedures. A computer navigation study. *The Bone & Joint Journal*. 2013;**95-B**:493-497. DOI: 10.1302/0301-620x.95b4
- [21] Ji SJ, Zhou YX, Jiang X, Cheng ZY, Wang GZ, Ding H, Yang ML, Zhu ZL. Effect of joint line elevation after posterior-stabilized and cruciate-retaining total knee arthroplasty on clinical function and kinematics. *Chinese Medical Journal*. 2015;**128**:2866-2872. DOI: 10.4103/0366-6999.168043
- [22] Emodi GJ, Callaghan JJ, Pedersen DR, Brown TD. Posterior cruciate ligament function following total knee arthroplasty: The effect of joint line elevation. *The Iowa Orthopaedic Journal*. 1999;**19**:82-92
- [23] Castelli CC, Falvo DA, Iapicca ML, Gotti V. Rotational alignment of the femoral component in total knee arthroplasty. *Annals of Translational Medicine*. 2016 Jan;**4**(1):4
- [24] Calvisi V, Camillieri G, Lupporelli S. Resurfacing versus nonresurfacing the patella in total knee arthroplasty: A critical appraisal of the available evidence. *Archives of Orthopaedic and Trauma Surgery*. 2009;**129**:1261. DOI: 10.1007/s00402-008-0801-9
- [25] Wood AR, Rabbani TA, Sheffer B, Wagner RA, Sanchez HB. Protecting the PCL during total knee arthroplasty using a bone island technique. *The Journal of Arthroplasty*. 2017:1-5
- [26] Parcels B. Managing Editor. TKA bone cuts. In: *Hip and Knee Book*. Arthroplasty Education Foundation. February 2017