
The Impact of the Eye in Dementia: The Eye and its Role in Diagnosis and Follow-up

Elena Salobarar-García, Ana I. Ramírez, Rosa de Hoz,
Pilar Rojas, Juan J. Salazar, Blanca Rojas,
Raquel Yubero, Pedro Gil, Alberto Triviño and
José M. Ramírez

Additional information is available at the end of the chapter

<http://dx.doi.org/10.5772/64490>

Abstract

Over the last few decades, the importance of ophthalmic examination in neurodegenerative diseases of the CNS has reportedly increased. The retina is an extension of the CNS and thus should not be surprising to find abnormal results in both the test exploring visual processing and those examining the retina of patients with CNS degeneration. Current *in vivo* imaging techniques are allowing ophthalmologists to detect and quantify data consistent with the histopathological findings described in the retinas of Alzheimer's disease (AD) patients and may help to reveal unsuspected retinal and optic-nerve repercussions of other CNS diseases. In this chapter, we perform an analysis of the physiological changes in ocular and cerebral ageing. We analyse the ocular manifestations in CNS disorders such as stroke, AD and Parkinson's disease. In addition, the pathophysiology of both the eye and the visual pathway in AD are described. The value of the visual psychophysical tests in AD diagnosis is reviewed as well as the main findings of the optical coherence tomography as a contribution to the diagnosis and monitoring of the disease. Finally, we examine the association of two neurodegenerative diseases, AD and glaucoma, as mere coincidence or possible role in the progression of the neurodegeneration.

Keywords: neurodegenerative disease, Alzheimer, optical coherence tomography, contrast sensitivity test

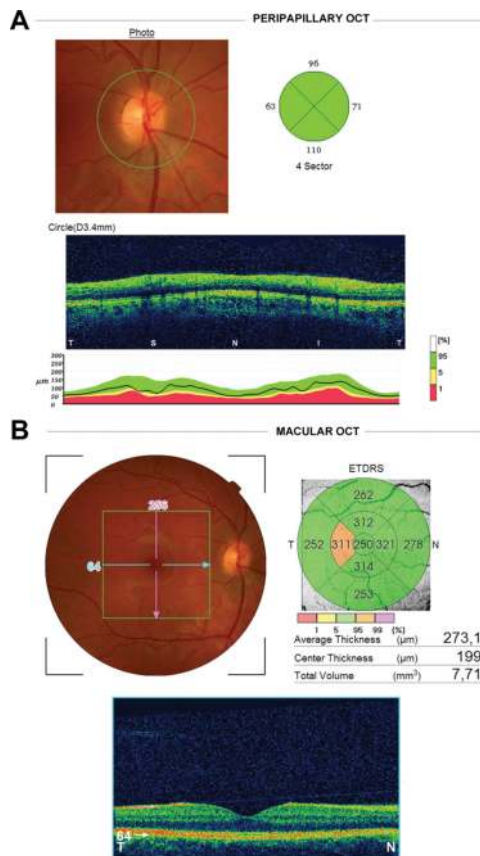
1. Introduction

The eye is a special sensory organ, as the retina is an extension of the brain. Both brain and retina derive from the neural tube and consist of neurons and glial cells. As with the CNS, any insult to the retina and optic nerve cause anterograde and retrograde axon degeneration, myelin destruction, and scar formation. Chronic progressive retinal neurodegeneration is involved in the pathophysiology of ocular diseases [1] such as glaucoma, age-related macular degeneration (ARMD) and diabetic retinopathy (DR).

In the brain, neurodegeneration is a key event in disorders such as Parkinson's disease (PD) and Alzheimer's disease (AD). PD is a neurodegenerative disease of middle and old age; the origin of defect lies in the basal ganglia and it is characterised by deficiency of dopamine in the mid-brain area.

AD, the most common cause of dementia, afflicts 67 in 1000 people over the age of 65 and more than 26 million people worldwide, its prevalence and incidence increasing exponentially with age [2, 3]. In 2006, the worldwide prevalence of Alzheimer's was 26.6 million, and by 2050, the prevalence is expected to quadruple [3]. A chronic progressive degenerative neurological disorder affecting cognition and memory [4], AD is characterised by the formation of extracellular amyloid beta ($A\beta$) plaques and intracellular neurofibrillary tangles (made of hyperphosphorylated tau), primarily in the cerebral cortex [5, 6]. Currently, there is no definitive antemortem diagnosis for AD, and therefore new biomarkers for diagnosis are needed. It can be argued that improved methods of screening and early detection are essential to identify patients without cognitive impairment but with a high risk of developing AD. Thus, protocols for early treatment could be established to help slow the disease progression [7]. Over the last few decades, the importance of ophthalmic examination in neurodegenerative diseases of the CNS has reportedly increased. As mentioned above, the retina is an extension of the CNS and thus the impairment of ocular function in patients with CNS degeneration should not be surprising. In fact, both the test exploring visual processing/visual pathways and those examining the retina of such patients display abnormal results. Current in vivo imaging techniques are allowing ophthalmologists to detect and quantify data consistent with the histopathological findings described in the retinas of AD patients years ago [8] and may help to reveal unsuspected retinal and optic-nerve repercussions of other CNS diseases. Specifically, over the last decades, accurate tools for analysing the eye fundus such as optical coherence tomography (OCT) and laser polarimetry have been developed, opening new ways of examining the retina in vivo. The retinal nerve-fibre layer (RNFL) is composed of retinal ganglion-cell axons, which form the optic nerve. Decreased thickness of the RNFL can reflect retinal neuronal ganglion-cell death and axonal loss in the optic nerve [9, 10], and RNFL reportedly thins with ageing [11, 12]. Notably, some studies have shown that AD patients show greater RNFL thinning than is normal for their age [9, 10, 13–20]. In this context, Hinton et al. [8] were the first to show histopathological evidence of retinal ganglion-cell loss and optic-nerve degeneration in AD patients. These findings were later confirmed in several follow-up studies [21–24]. Indeed, axonal degeneration of the large M-cells in AD has been documented [22, 25, 26]. Nevertheless, other histopathological studies [27–33] have failed to confirm these

findings, suggesting that methodological differences were responsible for the different results. In addition to the anatomical findings in AD, this disease can exert an impact on most aspects of visual processing, such as visual-field abnormalities [34–36], colour-perception deficits [37–40], pattern electroretinogram changes [26, 41, 42] and reduced contrast sensitivity (CS) [43–46]. Psychophysical investigations of CS in AD patients have demonstrated results consistent with the neuropathological evidence [47]. However, studies of CS in patients with AD have reported no AD-related deficits in spatial CS [48, 49], while others have found deficits at all spatial frequencies tested [40, 50].



Diagnosis and follow-up of AD, especially the early-onset cases, become difficult, due to imprecise neuropsychological testing, sophisticated but expensive neuroimaging techniques, and invasive sampling of cerebrospinal fluid [31, 32]. OCT is a reliable noninvasive technique, routinely used in ophthalmology to visualise and quantify the layers of the retina. This technique enables quantitative cross-sectional imaging of the RNFL and macular volume. As a measure of neuronal degeneration, changes in longitudinal OCT measurements of the RNFL can act as a surrogate marker of axonal health. Thus, OCT could become an invaluable tool for measuring axonal loss, as a biomarker, in different neurological conditions [33, 51–61] (**Figure 1**).

In a review of a meta-analysis which investigates the role of OCT in detecting RNFL thinning in AD patients, it was found that the OCT is a well-suited paraclinical methodology to assess RNFL thickness in both AD and mild cognitive impairment (MCI) disorders [19]. Macular studies in AD using OCT have recently reported that mild AD patients with a high average score (23.3 ± 3.1) on the Mini-Mental State Examination (MMSE) had significantly reduced macular nerve-fibre-layer thickness with or without significant peripapillary involvement [19, 40, 62, 63]. OCT thus offers the clinician a fast, reliable, reproducible, noninvasive method to evaluate and monitor several neurological diseases [64].

2. Search strategy and selection criteria

A literature search was performed up to April 2016 using the MEDLINE database, PubMed and Google Scholar search services with the following key words and word combinations: dementia, Alzheimer's disease, ageing, vision, eye, physiopathology, visual pathway, visual psychophysical test, optical coherence tomography, glaucoma.

After filtering by author criteria, English or Spanish language, and the condition that they all addressed dementia and vision as the main theme, 325 articles were included after a full text review. All the abstracts were then carefully divided into subcategories covering topics including ageing and vision, visual pathway, physiopathology, visual psychophysical test, Alzheimer's and glaucoma.

This review covers systematic reviews, original articles and letters to the editor. We did not contact other authors for further articles inclusion.

3. Ageing and vision

The term 'ageing' refers to the process of morphofunctional changes that organisms experience as time goes by. That process can be analysed from two main perspectives. On the one hand, there is the view that takes into account the physiological changes that happen to any individual, regardless of life experiences. On the other hand, there is the perspective referring to pathological changes, unique in each individual and related to alterations on the organic

balance [65]. The eye is not an exception to this process, and indeed the eye is one of the organs most affected by ageing.

3.1. Theories on ageing

Many theories and classifications have been proposed to explain human ageing, although a combination of several of them may explain the process. In 2013, in a review called 'The hallmarks of ageing' [66], the current theories were widely discussed and nine fundamental traits of ageing were described: genomic instability, telomere shortening, epigenetic changes, loss of proteostasis, deregulation of the detection of nutrients, mitochondrial dysfunction, cell ageing, depletion of stem cells, and altered intercellular communication. Additionally, it is clear that there are other environmental and behavioural factors that can contribute to this degradation process, such as, for instance, smoking and regular exposure to UV light.

3.2. The ageing eye

As the eye ages, some morphological, structural, and functional changes take place in both the eye itself and other extraocular structures. This process is generically referred to as 'eye ageing'.

3.2.1. Structural changes in the ageing eye

In the orbit and the adjacent tissue, there is a reduction of the adipose tissue with relative preservation of the nasal fat pad [67]. This generates eyeball sinking (enophthalmos).

The eyelids progressively lose their elastic properties, with an increase in palpebral skin laxity [68].

In the lacrimal gland, there is a proliferation of connective tissue and an atrophy of glandular elements resulting in a decrease in lacrimal tear production [69]. The lacrimal pathology in elderly patients involves different situations ranging from 'dry eye' to profuse lacrimation or epiphora. The result is an alteration in the lacrimal film with its corresponding discomfort and decline in visual acuity (VA).

The conjunctiva undergoes a decrease in density of dendritic cells due to ageing, as well as the degeneration of the subepithelial structures. There is an increase in conjunctival microcysts, indicating that the Goblet cell function is failing, since it has been demonstrated that the Goblet cell population does not decrease in number [70].

The ageing sclera shows hyaline plaques, fat deposits, and loss of aqueous content, hence provoking biomechanical changes due to greater rigidity [71, 72].

Refractively, the ageing cornea suffers a change in keratometry resulting in against-the-rule astigmatism. Ageing results in corneal degeneration with a progressive deposit of lipid material that provokes gerontoxon or arcus senilis. Some calcifications appear in the Bowman's membrane periphery while Descemet's membrane thickens. The cornea becomes more rigid and edematous, with a tendency to opacity, causing a sensitivity loss [72, 73]. There is also a reduction in the number of corneal endothelial cells, and hence the development of Fuchs

endothelial dystrophy is common. This endothelial loss provokes a dysregulation in corneal homeostasis, which diminishes VA and even leads to blindness [72, 74].

The trabecular meshwork alters its shape due to the ageing process, changing from a wedge-shaped structure into a more rhomboidal one [72, 75]. The trabeculae thicken and an ultra-structural examination shows a change in the appearance of the extracellular materials [75]. There is a lower number of endothelial trabecular cells as well as of giant vacuoles and intracellular pores in Schelmm's canal [72]. Gonioscopy shows an increase in the trabecular meshwork pigmentation. All of these factors could result in greater resistance to the aqueous outflow, which may favour the onset of glaucoma [76].

The pupil tends to become smaller and the iris is less reactive. There are also more difficulties in terms of pharmacologic dilation of the pupil. Iris pigment is lost with ageing, resulting in iris transillumination in the slit-lamp examination, especially in the pupillary margin.

The changes in size and tone of the ciliary body, together with the loss of elasticity of the lens capsule and a packing in its fibres, weaken accommodative capacity, causing presbyopia [77].

With age, the lens tends to absorb more blue light (410 nm) due to the accumulation of yellow pigment caused by the oxidation of lens proteins [72]. This is called 'blue blindness' in the cataractogenic processes.

Clinical data from studies on the choroid, using OCT, show an inverse correlation between age and choroid volume [78]. Some histopathological studies have shown a negative correlation between age and choriocapillaris density [79]. Bruch's membrane is the structure that presents the most changes due to ageing, becoming thicker, with changes in the elastic fibres (calcification among others) and collagen [72]. The major proportion of thickening appears to be due to the deposits of lipids [80] and fibrillar and amorphous material [81]. The basal laminar deposits, material that accumulates between the Bruch's membrane and the retinal pigment epithelium (RPE), are located mainly in the macular area and occasionally appear as drusen [76, 82]. The aforementioned changes in Bruch's membrane lead to the appearance of waste accumulation in the overlying retina. The retinal pigment epithelium, which is vital for the integrity of the rods and cones, shows greater pleomorphism, a lower number of epithelial cells in the posterior pole, a loss of melanin content, an increase in lipofuscin, and a reduction of the cytoplasmic volume [72, 76, 82]. With age, photoreceptor density reduces in the retina [86]. An age-related loss of rods in the macula occurs with a decline in scotopic sensitivity [72]. In the astroglial plexus of the ganglion-cell layer and RNFL, the number of astrocytes significantly drops. These cells show stronger GFAP immunoreactivity, more cytoplasmic organelles, glial filaments and lipofuscin deposits [82]. As a result of the ageing process, the retinal-blood flow diminishes and macular microcirculation diminishes by an estimated 20% [83]. The number of retinal capillaries around the fovea falls and arteriosclerotic changes occur in retinal vessels [72].

In the optic nerve (ON), the number of ON axons reportedly declines [72, 84]. The connective tissue within the fibrovascular pial septae becomes more abundant. As a result, the exchange of nutrients between the capillaries and the nerve fibres is impaired [72]. With ageing, Corpora

amyloids may be seen in the ON, appearing as accumulations of intracellular organelles (neurotubules, dense bodies, and mitochondria) in the axons [72].

In the vitreous humour, changes appear in the components of the collagen fibres and hyaluronic acid, causing vitreous floaters [85]. As a result of ageing, the vitreous attachment to the retina weakens, provoking posterior vitreous detachment. This may trigger a contraction at its base, leading to traction on the peripheral retina, which may result in retinal tears [72].

3.2.2. Functional changes in the ageing eye

Normal ageing implies changes in the functionality of the visual system, since there is less light transmission and scattering inside the eye. Also efficiency in phototransduction and photopigment regeneration declines. The quality of transmission and its synaptic processing in the retina and in the entire visual pathway diminishes [86]. Due to all these changes, vision is affected in different ways. The elderly population experiences significant refractive changes with age. Usually, a change of against-the-rule astigmatism takes place as a result of corneal flattening. Moreover, the spherical component becomes more hyperopic due to sclera rigidity, senile myosis and changes in the ageing lens, the latter resulting in a loss of the refractive capacity. The prevalence of oblique astigmatism and anisometropia also increase with age [87].

Visual acuity (VA) worsens with age for many reasons, the standard being a vision of 0.8. Regarding the ageing process, this reduction in near VA may be due to presbyopia or physiological loss of accommodation because of ciliary muscle-tone loss. Likewise, the changes in the lens can cause alterations in VA: late-onset myopia can appear, owing to the rigidity in the lens nucleus that is related to the senile cataract; also, early nuclear sclerosis can cause eye glare.

Contrast sensitivity (CS) undergoes small changes starting in childhood up until the age of 65. After that, the decline is more pronounced, especially in medium and high spatial frequencies. This decline in CS is due partially to the opacity in the media of the eye, which decreases depth perception [87, 88].

With age, the normal visual field (VF) is impaired due to a retraction. The blind spot size enlarges. Additionally, the reduction in the number of cones in the fovea causes a general decline in colour vision [76].

Old people experience trouble with light and dark adaptation and they are incapable of tolerating glare [76].

There are also age-related binocular problems that affect the neuromuscular mechanisms and the structures of the tissues adjacent to the eye. Patients suffer from accommodation-convergence problems and thus, they show greater exophoria in near vision. Vertical deviations and poor stereopsis are very frequent with ageing [89].

3.3. Brain ageing

The nervous system is particularly vulnerable to ageing due to the main cellular elements of this tissue are post-mitotic cells and thus their regeneration capacity is limited.

Age-related worsening of cognitive functions occurs both in humans and in animals. This is especially true for the functions related to executive capacities, attention processes, and the learning and storage of new information. Also, the senescent brain is capable of using functional strategies to compensate for functional and/or structural deficiencies. This brain plasticity observed in senescence can decrease or mask the clinical expression of brain ageing [90].

3.3.1. *Structural changes in the brain*

Research conducted a few years ago on anatomical brain changes seems to demonstrate a clear reduction in brain volume due to neuronal death [91]. The greatest part of this volume loss is the reduction of synaptic density [92] and volume of white matter in the frontal lobes [93]. Even so, the most recent studies indicate that age-related changes do not affect the brain globally. On the contrary, these changes would be highly limited to the dorsolateral prefrontal cortex and, to a lesser extent, to some subdivisions within the medial temporal lobe, such as the subiculum and the dentate gyrus [94]. It is believed that the age-related drop in cognitive skills is the consequence of a selective alteration in the corticocortical pathways that connect the temporal and frontal association areas to the corticostriatal pathways [93, 94].

Age-related microscopic changes include regional brain atrophy [93], axonal cortical dystrophy [95], lipofuscin accumulation [96], astrogliosis [91], neurofibrillary degeneration, senile plaques [97, 98] and scattered vascular or dystrophic focal changes in the white matter [99]. Many of these changes cannot be regarded as being specific to ageing. For instance, most cases of cortical atrophy could indicate an underlying degenerative brain [100] or vascular [101] disease. Changes in the periventricular white matter (leukoaraiosis or subcortical leukoencephalopathy) occur in patients with vascular risk factors, reflecting an insufficiency of the deep vessels of the brain secondary to a hypertensive, diabetic or multifactorial degenerative arteriopathy [102]. Perhaps the only brain change attributable to the passage of time is lipofuscin accumulation; this indicates oxidative stress and lipid peroxidation [96], as well as local synaptic loss [93, 94].

The vascular volume in the brain decreases, specifically the surface of the capillaries [103]. The blood-brain barrier is selective place for the exchange of nutrients between the blood and the brain parenchyma. With ageing, the molecular transport systems operating at this level are reduced. This has some metabolic consequences for the normal functioning of the nervous system [104].

One of the least known aspects in the ageing process is the role of the brain glial cells [105]. The glia is a group of CNS cells whose main function is to maintain the homeostasis of the neural environment (astrocytes), immunosurveillance (microglia) and the formation of myelin (oligodendrocytes).

It has been demonstrated that, in the ageing brain of experimental animals as well as humans, there is a proliferation of astrocytes which is called reactive gliosis. Its purpose is to mitigate the effects of the physiological age-related neuronal degeneration [106].

3.3.2. Cognitive functional changes

Age-related neuromorphological changes trigger cognitive alterations. Cognition is the set of brain activities that enable humans to be aware of themselves, of the others, and of the environment [107]. One of the most important features of cognitive ageing is memory loss. Learning and memory have their neurobiological origin in the hippocampus. The hippocampus is composed of a series of cell populations that establish certain very precise and well-organised synaptic pathways. The information received is processed and sent to the brain cortex for storage and for use in the long-term memory [108, 109]. Learning processes are based on neuroplasticity, whose neurophysiological basis is long-term potentiation. This is achieved by a proliferation of AMPA glutamate receptors as well as an increase in dendritic spine density in hippocampal postsynaptic neurons [110]. During the ageing process, a reduction may occur in the neural capacity to synthesise neurotransmitters involved in synapses [111]. The most common neurotransmitters are glutamate, GABA, acetylcholine and dopamine. Changes in the homeostatic levels of these neurotransmitters cause different pathologies that are accentuated during ageing [112]. For instance, the lowering of acetylcholine levels is one of the most striking features of AD [113].

4. The eye as an extension of the central nervous system

Given that the eye is an extension of the CNS, evidence is being sought to determine whether the retina is a window to the brain and whether eye research could improve our understanding of CNS disorders [114]. The retina is made up of specialised neuron layers that are interconnected via synapses. The light that enters the eye is captured by the photoreceptor cells in the outer retina, initiating a cascade of neural signals that finally reach the retinal ganglion cells (RGCs), whose axons form the ON. These axons project to the lateral geniculate nucleus (LGN) in the thalamus and to the superior colliculus (SC) in the midbrain, whose information is then transmitted to more specialised visual processing centres that provide a perception of the world [114, 115].

Most of the RGC axons come together to form the ON. After passing through the lamina cribrosa of the eye the ON is covered by a myelin sheath produced by the oligodendrocytes and surrounded by the three meningeal layers. As in the CNS, ON injury may result in anterograde and retrograde degeneration of the damaged axons, scarring, myelin destruction and creation of a neurotoxic environment involving oxidative stress, deprivation of neurotrophic factors, raised levels of excitotoxic neurotransmitters and abnormal aggregation of proteins and waste products. Such a hostile environment often provokes the death of the initially undamaged neighbouring neurons in a process called secondary degeneration [116–121].

Axonal regeneration after injury is limited both in the CNS and ON. In fact, most of our knowledge on axonal response to traumatic brain injury stems from studies of the ON [122–128]. The factors responsible for creating an environment that is non-permissive for axonal growth are the same by CNS and ON. The first discoveries of CNS axon regeneration in the

presence of peripheral nerve grafts were performed in experimental models of ON transection and of spinal-cord injury [122, 123, 129]. We should underline that there are similar restrictive growth conditions in these two structures of the nervous system.

The eye, and especially the retina as a part of the CNS, must maintain regulated interactions with the immune system. In fact, the retina occupies a special immune site. The eyeball is made up of some unique physical structures and contains a set of surface molecules and cytokines responsible of some specialised immune responses, similar to those observed in the brain and the spinal cord [130, 131]. The eye possesses the blood-retinal barrier, whose structure, characteristics and mechanisms are similar to those of the blood-brain barrier. The anterior chamber of the eye contains the aqueous humour, a fluid with anti-inflammatory and immunoregulatory mediators. This fluid resembles the cerebrospinal fluid circulating around the brain and the spinal cord parenchyma [132, 133]. Besides the similarities with the CNS, the ocular immunoprivilege involves a unique phenomenon called 'anterior chamber associated immune deviation' (ACAID), wherein the antigen-presenting cells entering the anterior chamber capture the antigen and then migrate to the spleen. There the effector leukocytes become regulatory leukocytes. This process establishes a tightly regulated immune response towards ocular antigens [130]. The combination of the aforementioned mechanisms allows the eye to benefit from the immune defence machinery that would eliminate the risk of tissue damage due to uncontrolled inflammation [114].

4.1. Visual pathway

The visual information collected by the photoreceptors (rods, sensitive to contrast; and cones, sensitive to colour) goes through the inner plexiform layer of the retina (bipolar, horizontal and amacrine cells) to the RGC layer (midget, parasol and bistratified cells) [134]. The layout of these three different RGC types forms different receptive fields, which help in segregating and coding visual information [135]. Then, the RGC are projected through different pathways (parvocellular (P), magnocellular (M) and koniocellular (K)) to the sub-cortical region of the LGN and to the V1 cortical area [135–137]. The P-pathway receives colour and shape information from the midget cells. The K-pathway receives some blue-on/yellow-off opponent colour information from the bistratified cells. Finally, the M-pathway carries the luminance and motion data from the parasol cells. Thus, the visual information segregated in the V1 region is projected into the V2 region for processing [135, 138, 139]. The information about colour, orientation and spatial frequency continues ventrally through V2 and V4. This route continues to the infero-temporal cortex, where more-complex aspects of the visual processing of objects are carried out, such as face perception. Motion and location follow the dorsal pathway through V2 and V3. The V3 dorsal area seems to be specialised in the detection of global motion [140, 141]. The V5 is specialised in local movement [142]. The dorsal pathway continues to the posterior parietal cortex, where the complex aspects of spatial perception, e.g. details within a scene as an integrated perception are processed [141].

4.2. Ocular manifestations of CNS disorders

As mentioned above, the eye is an extension of the brain, and therefore it seems reasonable to look for some ocular manifestations of brain pathologies. In fact, in patients with CNS pathologies such as EP, multiple sclerosis (MS), amyotrophic lateral sclerosis, and AD, ophthalmological changes have been observed. Notably, many of these changes are not exclusive to a certain disease, highlighting the relationship between the retina and the brain. Likewise, in many of these CNS disorders the ocular symptoms precede the cerebral symptoms. Therefore, eye examinations could help in the early diagnosis of these CNS diseases.

4.2.1. *Stroke*

Prospective studies have shown that retinal microvascular abnormalities (formation of arteriovenous crossings, bleeding, and arteriolar narrowing) could predict the risk of cerebral ischemic changes and stroke [143–145]. In addition, the presence of a retinopathy with arteriovenous crossings has been linked to an increased risk of stroke, especially when these retinal abnormalities were associated with lesions in the cerebral white matter, a feature which is usually indicative of stroke [143, 145, 146]. Beyond these prospective studies, other research on the eyes in some animal models have shown that stroke is associated with functional impairment of the retina, including thinning of the retinal layers, reactive gliosis, increased expression of genes associated with cell damage, restricted oxygen supply, DNA fragmentation and ON neurodegeneration [147].

Ocular manifestations are to be expected in stroke, because the small vessels of the retina and the brain have similar embryological origins, anatomical characteristics and physiological properties [148, 149]. Some dysfunctions in the blood-brain and the blood-retinal barriers are suspected of playing a central role in the development of brain and retinal microangiopathy, respectively [131, 150, 151].

4.2.2. *Multiple sclerosis (MS)*

Visual impairment in MS is a major cause of disability. Visual loss is a symptom that occurs in up to 50% of patients with MS, resulting in some degree of visual impairment throughout the course of the disease for most cases [152–154].

It is not surprising that MS is related to eye disease, since the myelin components, which are essential in both the brain and the visual pathway, are the major autoimmune targets in MS. Visual defects are usually the result of axonal demyelination along the visual pathway [155]. It has been found that some internal areas of the retina, which are not associated with myelin, are also affected in MS. This suggests that the autoimmune response is also directed against other antigens in the eye [156].

Retrobulbar optic neuritis is an inflammatory optic neuropathy associated with demyelination and degeneration of the RGC. Diagnosed in 75% of patients with MS, this is often the first symptom of the disease [154, 155, 157]. It is important to highlight that visual deficits in MS also occur in patients without an optic neuritis diagnosis. Several studies have shown that,

although the VA is not affected [158–160], there is a decrease in CS [158–160] and the RNFL thickness in MS patients in comparison with healthy individuals [160, 161]. RNFL thickening occurs in both the peripapillary [60, 160, 162, 163] and the macular area [54, 60]. Furthermore, RNFL thinning in MS patients directly correlates with the progression of neurological impairment and disease duration [160].

4.2.3. *Parkinson's disease (PD)*

PD is a chronic neurodegenerative disorder that is associated mainly with motor dysfunction, although it can also involve some non-motor symptoms, including visual deficits. These deficiencies may manifest as decreased CS [59, 163], impaired colour vision (the tritan axis is altered first) [57], and abnormal electrophysiological responses [57, 164]. The retinas of PD patients show photoreceptor and RGC dysfunction, morphological deterioration of the perifoveal dopaminergic plexus [165], and thinning of the RNFL [52, 53, 164, 166, 167]. According to the hypothesis that the disease results from a dopamine imbalance, it seems that visual deficits in PD could also be caused by dopamine depletion. In fact, some of the visual deficits experienced by PD patients can be improved by levodopa treatment [168].

4.2.4. *Alzheimer's disease (AD)*

The first abnormalities in the visual system for AD, observed in the 1970s, were regarded strictly as a dysfunction at the cortical level. Subsequent studies over the past 25 years have revealed that all parts of the visual system, including the ON and the retina, may be affected in AD. Some aspects of this involvement are still not well understood and are still the subject of recent research. Anatomical changes along the visual pathways and their corresponding functional changes have been detected and analysed by psychophysical procedures. AD can affect different aspects of the visual processing in line with the impact of the disease in the dorsal and ventral regions of the brain. Patients with dorsal-region damage suffer alterations in functions such as discrimination and angular-motion perception [169–172]. Those with damage in the ventral region show difficulty in discriminating faces, colours, and shapes [37, 173, 174].

5. Physiopathology of AD manifestations in the eye and the visual pathway

Changes in the visual system associated with AD have been the focus of the scientific community over many years, with some extensive reviews focus on different aspects of the problem [7, 47, 175–188]. All this evidence emphasises that visual changes may in medical practice help in the assessment of these patients and may even provide a predictive value potentially useful in diagnosis.

5.1. The lens

β -Amyloid deposits in the brain are a pathologic marker for AD. Amyloid β -peptides A β 1–42 and A β 1–40 have been identified in the human lens. A β 1–40 was found in the aqueous humour,

and its concentration is comparable to that found in the cerebral cortex and in the cerebrospinal fluid of AD patients [189]. On the one hand, it was recently discovered that there is an increase in β -amyloid deposits in the supranuclear lens fibres, which may be linked to the equatorial supranuclear cataracts more frequently found in these patients [1]. On the other hand, the study by Bei et al. determined that the measuring of the lens opacity was unlikely to provide a noninvasive measure of the risk of developing AD [190].

5.2. Retina

5.2.1. Retinal ganglion cells (RGCs)

The first histopathological studies on human-donor retinas of AD patients were made in the 1980s. Hinton et al. [8] examined four eyes from AD patients, finding a loss on the number of RGC, but a shortcoming of the study was that they did not provide numerical values in their results. However, Curcio et al. [27] found no significant difference in the number of RGC between the AD group and the age-matched controls. In the mid-1990s, Blanks et al. [23, 24] confirmed the initial observations of Hinton et al. These researchers compared the postmortem number of RGC from 12 retinas of nine patients with severe AD and 15 retinas from 12 age-matched controls. These studies found a 25% decrease in the number of RGC ($p < 0.001$) and an 82% increase in the astrocyte ratio per neuron in the retina ($p < 0.001$). However, a study with AD transgenic mice did not show a significant difference in the number of CGR compared to controls [191].

All the histopathological studies carried out so far involve a relatively small number of subjects. Therefore, it would be advisable to undertake more studies with larger numbers of subjects in order to verify the RGC decline in AD.

5.2.2. Vascularisation and retinal blood flow

Recent data suggest the vascular involvement of the retina in AD patients. Vascular changes in the retina are thought to share similar pathogenic mechanisms with cerebral vasculature [15, 192]. In fact, it is known that cerebral vascular insufficiency is one of the earliest pathological signs in the development of AD [193, 194].

Currently, there are few studies on vascularisation and retinal blood flow in AD. In 2007, Berisha et al. [15] studied the retinal vascularisation and blood flow in patients with AD. These researchers used Doppler laser in nine patients with probable mild ($n = 6$) and moderate AD ($n = 3$) plus eight age-matched controls. They detected a significant narrowing in the diameter of the retinal veins and decreased blood flow in AD patients, compared with controls. Mroczkowska et al. analysed the dynamic retinal vascularisation, noting that there were some signs of microvascular dysfunction that were correlated with the extent of cognitive impairment [195]. However, the study published by Tsai et al. found no differences either in the vascular structure or the calibre of retinal vessels in AD transgenic mice, compared to control animals [191].

5.2.3. Amyloid plaques, neurofibrillary tangles and vascular angiopathy

The first unsuccessful attempts to find amyloid plaques, neurofibrillary tangles or vascular retinal angiopathy in eyes of AD patients were performed in 1989 by Blanks et al. [21]. Although none of these typical AD signs were detected in the retina, their findings showed different levels of degeneration in RGC correlated with the degree of impairment of the patient.

In the last few years, β -amyloid deposits and hyperphosphorylated tau proteins have been detected in elderly retinas in a model of AD in double transgenic mice [196–198]. These β -amyloid plaques are distributed from the ganglion-cell layer to the inner plexiform layer. Some of these are also located in the outer nuclear layer, in the outer segments of the photoreceptors and in the ON [197]. These deposits, analysed with immunohistochemical techniques, are found to be accompanied by an increase in MCP-1+ immunoreactivity and F4/80+ in RGC layer. These results suggest that β -amyloid deposits cause neurodegeneration in the retina of these mice. This idea is further supported by the presence of TUNEL+ immunostaining in the RGC layer, so that there is some histological evidence of apoptosis in this layer [196]. In 2009, a β -amyloid vaccine was tested in the experimental mice model mentioned above, resulting in a lower number of retinal β -amyloid deposits. Nevertheless, there was a marked increase in retinal microvascular β -amyloid deposits as well as local neuroinflammation due to microglial infiltration and astrogliosis linked to a disorder in the organisation of the retina [197].

A postmortem study in human retinas showed for the first time the presence of β -amyloid plaques in AD patients [199]. Subsequently, other authors have confirmed the presence of β -amyloid deposits, which were more prevalent in perivascular and perimacular areas, both in AD patients and in those with mild cognitive impairment (MCI) [191, 200]. Campbell et al. recognised β -amyloid plaques in the retina by observing its polarisation properties and proposing it as a new diagnostic method [201].

5.3. Choroid

The latest improvement in OCT technology has enabled us to study the thickness of the choroid in vivo in patients with mild to moderate AD. A statistically significant generalised loss of foveal choroid thickness was found in these patients [191, 202, 203]. According to the authors, this choroidal thinning in AD may be associated with hypoperfusion and/or atrophic changes in this vascular layer. Several immunohistochemical studies in AD transgenic animals have reported a higher frequency of RPE hypertrophy and binucleated cells, but these changes were not seen in human retinas [191]. Previous studies have shown an $A\beta$ accumulation in the choroidal vasculature in ageing mice and in a transgenic mouse model of AD [196, 204]. As happens in the brain, $A\beta$ accumulation in the choroid may induce an inflammatory response and complement activation, which would lead to progressive vasoregression of the choroidal vasculature (and subsequent retinal neurodegeneration), through the same pathological cascade that has already been described in AD brains [191, 205–207].

5.4. The optic nerve

Hinton et al. [8] described widespread axonal degeneration of the optic nerves in 8 out of 10 AD patients that were analysed postmortem. In an additional study, a morphometric analysis of the ON suggested a predominant loss of magnocellular neurons that contribute large-calibre fibres. In a study published in 2005 by Syed et al. [208], some significant differences in axonal density were found by dyeing axon contours with toluidine blue, both in the central and in the peripheral areas of the ON. The analysis was performed on 12 AD patients, compared with 13 advanced-age control subjects. It should be pointed out that Syed's study found a decrease in smaller axons, with transversal section areas measuring less than $1.99 \mu\text{m}^2$. Studies using magnetic resonance imaging (MRI) have found a statistically significant decrease in the ON volume in AD patients. However, this reduction does not correlate with brain volume [209].

Neurofibrillary tangles of tau protein have also been observed in ON [211], although this may not be specific for AD. Low-density lipoprotein receptor-related protein (LRP) is involved in the pathogenesis of AD by mediating the transport of amyloid- β ($A\beta$) out of the brain into the systemic circulation. Recently, Cuzzo et al. [210] found a decrease in the expression of LRP in the optic nerves of 11 patients with AD, compared to 10 control subjects. This would support the theory that LRP may play a role in the physiopathology of the optic neuropathy in AD. In the same study, the group of Cuzzo observed a decrease in neurofilament immunostaining in AD patients in comparison with control, thus confirming the previous findings by Hinton et al. [8]. Also, an increase in the receptor expression of advanced glycation end-products in the astrocytes near microvasculature has been reported in ON samples from AD patients [211].

Different studies have also pointed out some differences between the control group and the AD patients in the appearance of the ON head, both with red-free photography [13, 212, 213] and with scanning laser ophthalmoscopy [214]. However, other studies failed to find such differences between AD patients and controls using the latter technique [31].

5.5. Lateral geniculate nucleus (LGN)

Scholtz et al. [215] noted a myelin loss and reduced function of neurons in the LGN in AD patients. The presence of β -amyloid plaques and neurofibrillary tangles of tau protein are also shown to be more abundant in the parvocellular than in the magnocellular layers of the LGN [218, 219]. On the contrary, a recent study found that tau pathology was scarce in the LGN and it did not differ significantly with age-matched control patients [216].

5.6. Other brain nuclei

5.6.1. Superior coliculus (SC)

The SC, sometimes referred to as the optic tectum, is a paired and laminated structure with a retinotopic organisation in the medium brain, which receives about 10% of RGC axons and is involved in the control of eye movements. Numerous amyloid plaques were found in the SC of AD patients [217]. Furthermore, subsequent studies identified abundant neuropathological

neurofibrillary tangles [216, 218, 219] in this nucleus. These pathological changes in the SC may explain the problems of ocular motility frequently found in patients with AD [220].

5.6.2. *Suprachiasmatic nucleus*

The suprachiasmatic nucleus (SCN) is a paired structure formed by a group of neurons in the medial hypothalamus, above the optic chiasm, which receives direct RGC input through a retinal-hypothalamic tract [221]. In addition, it is a primary control centre of circadian rhythms by stimulating melatonin secretion by the pineal gland. It has been seen that there may be marked changes in the SCN in AD, such as decreases in the volume and number of cells (including specific neuronal subpopulations, such as vasopressin and neurotensin neurons) and the formation of neurofibrillary tangles [222–225]. These neuropathological findings may be correlated with the misalignment of the circadian rhythm in AD [226].

5.6.3. *Pulvinar nuclei*

Pulvinar nuclei, are a collection of nuclei located in the pulvinar thalamus, have reciprocal connections with association areas of the cerebral cortex, in the parietal, occipital and temporal lobes. They consist of several divisions that receive multiple inputs from the visual cortex subdivisions, from the SC and the retina (to a limited extent) [227]. This area is involved in visual attention and the control of eye movements.

Numerous amyloid plaques and some neuritic plaques (extracellular deposits within the brain grey matter which are a mixture between amyloid and death neuronal processes) were found along the various subdivisions of the pulvinar nuclei in nine AD patients compared with younger patients and age-matched controls [228]. This could explain the deterioration of visual attention in AD patients [174].

5.7. Visual cortex

The visual cortex is located in the occipital lobe. It comprises the striate cortex or V1 (primary visual cortex) and visual cortical extrastriate areas such as V2, V3, V4, V5, etc. (secondary visual cortex). Together, the primary and secondary visual cortex consists of a mosaic of several dozen visual areas occupying a large part of the cerebral cortex, approximately 20–25% in humans [229, 230].

In AD, the primary visual cortex is affected after the involvement of other cortical regions [231–233], except in a variant that manifests with early visual symptoms [234, 235]. Nevertheless, the accumulation of amyloid plaques and neurofibrillary tangles, the decrease in the number of neurons and capillary density, and the reduction of certain enzymes in V1 of AD patients are well documented [191, 233–236].

Although some preliminary studies claimed that there are minimal neurofibrillary tangles and amyloid plaques in primary and secondary visual cortex [237], subsequent studies have found abundant neurofibrillary tangles and plaques in the secondary visual cortex (mostly in the extrastriate 18 and 19 areas) [238, 239]. In both areas 17 and 18, the average neuronal density

decreases to a similar degree (~30%) [240]. However, the difference between the two areas was the concentration of neurofibrillary tangles (2% of the neurons present tangles in area 17 vs. 10% in area 18) [240]. The reason for such discrepancy in neuronal loss could be related to the vulnerability of some neurons to the presence of neurofibrillary tangles or to the possibility of some cell loss unrelated to the degeneration of neurofibrillary tangles [47]. In addition to amyloid plaques and tangles, astrocytic gliosis was found in the primary visual cortex [241]. A likely associated dendritic pathology has also been observed in AD: dystrophic dendrites, loss of dendritic branches, and pathological alteration of dendritic spines [242, 243].

6. Visual psychophysical tests in Alzheimer's disease

To perform psychophysical tests in pathology such as AD can be a great challenge, because most of these tests require understanding and memorisation of the protocol for proper test performance. Therefore, without supervision by an experienced examiner, anomalies detected in testing may actually be the result of a failure to perform the task and not a visual deficit.

6.1. Visual acuity

The analysis of VA in AD patients was one of the most controversial tests. Although several studies claim that VA is not altered in this neurodegenerative condition [44, 48, 49, 239, 241, 244–246], other researchers find not only a decrease in VA [40, 247] (**Figure 2A**), but they also link this reduction to visual hallucinations when VA is severely decreased [248, 249]. A

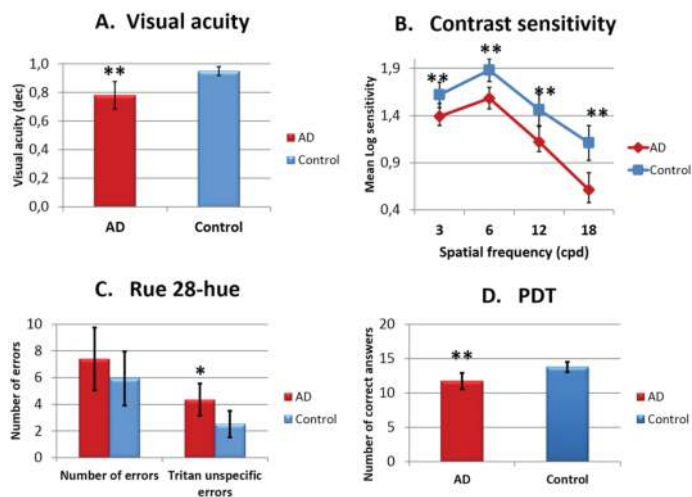


Figure 2. Mean data of the psychophysical tests. (a) Visual acuity, (b) contrast sensitivity, (c) desaturated Rue 28-hue colour test, and (d) perception digital test. Each bar represents the mean \pm SD. * $p < 0.05$ versus control. ** $p < 0.01$ versus control. Mann-Whitney U test (from **Figure 1** of [40] with permission).

correlation between the worsening in VA and the progression of AD has been described [250], together with a decline in AD patients and in AD patients with vascular dementia under low-luminosity conditions [44].

6.2. Colour vision

To perform the colour test in clinical practice in patients with AD is controversial because these patients have a naming deficit and therefore may have trouble verbalizing colours that they see or they might incorrectly name numbers or shapes. Despite this, some colour-vision tests do not require verbalisation, although they require concentration and memorisation of the task.

Some published studies which used Farnsworth's test and Ishihara's test [251–253] found no differences in colour perception between the AD group and the control one. However, other authors found some tritan-axis defects, showing a correlation with the degree of dementia [37, 40, 238, 244] (**Figure 2C**). These data agree with the results of other authors [173, 240, 247, 254]. Pacheco et al., in their analysis with Ishihara test and PV-16, found impaired colour vision consisting of non-specific mistakes. Such responses were more prevalent in AD patients compared with controls, and were unrelated to the severity of the disease [38]. The disparity in the results may be due to the fact that each study used a different method for studying colour vision, so that comparisons of the results are difficult to interpret. Notably, Salamone et al. claimed that the problem of colour discrimination in AD patients is not purely cognitive but rather seems to be related to the damage of the structures responsible for colour perception [39].

6.3. Visual field

Like other psychophysical measures, automated perimetry requires considerable cooperation from the patient; therefore the reports on VF and AD are scarce and most are case reports. VF defects in AD vary from homonymous quadrantanopsia [255, 256] to non-hemianopic VF loss [239]. VF impairment in AD has been found both with manual perimetry [35] and with automated perimetry [34]. The latter showed a significant reduction in differential luminance sensitivity between AD and controls. This study additionally reported that AD patient underwent a diffuse sensitivity loss and, although VF defects involved the central field, deficits were more pronounced in the inferior field, appearing mostly as arcuate defects. They also found that the patients exhibited progressive VF loss 18 months after the initial examination.

6.4. Contrast sensitivity (CS)

CS tests evaluate the ability of the visual system to discriminate an object from the background in which it is located. This allows us to assess the integration of the information by the RGC and its cortical processing. The CS is measured by a threshold curve in which the spatial frequencies examined are depicted. High spatial frequencies examine the role of parvocellular cells, while low spatial frequencies represent the function of magnocellular cells.

The study of CS in AD has given rise to discrepancies in the results. Most reports have shown that CS function is affected in AD patients, the impairment ranging from a reduction in all

spatial frequencies [26, 40, 43, 44, 245, 247, 251, 257–259], to a greater decline in high [26, 40, 258, 260] or low spatial frequencies [239, 244, 261, 262] (**Figure 2B**). By contrast, two studies found no differences between AD patients and controls [48, 246]. Such discrepancies in the results could be due to differences among the patients included in the studies as well as the CS test used [45]. Some CS tests are influenced by VA, such as the Regan chart, a low-contrast letter, and the Vistech VCTS 6500 whereas others are independent on VA, such as the Pelli-Robson test and the Freiburg test [45]. CS impairment in AD patients has consequences for daily functions and cognitive abilities, given that the spatial frequencies most affected appear to be those corresponding to macular function. An example of the importance of CS loss in AD patients is the capacity to predict the risk of falling [45].

6.5. Perception digital test (PDT)

The PDT is a quick, easy, and sensitive method recently developed for evaluating visual-perception disorders in mild AD patients [263]. The test aimed to assess the visual recognition of familiar situations, masked by geometric special effects that hinder perception. Each of the 15 sheets comprising the test shows the same picture at different positions in space. Special effects such as geometric effect (tile) or the effect of the frame 24/48 of MGI Photo Suite III program are used to distort the pictures. The test consists on a set of images that are shown to the patient to identify which one is properly oriented in space. Among the photographs are six common objects, five landscapes, two people, one letter, and one animal. The study of Rami et al. [263] showed that there were significant differences in PDT between mild-AD patients and control as well as a significant correlation with the MMSE. These results have been recently confirmed by Salobar-García et al. [40] indicating that patients with mild AD had significantly more failures than controls and that there was a significant linear association with the MMSE [40] (**Figure 2D**).

6.6. Critical fusion frequency

The critical fusion frequency (CFF), also called temporal resolution, is a psychophysical threshold and in psychological terms is regarded as a measure of information-processing capacity [264]. It is defined as the frequency at which an intermittent light stimulus appears to be completely steady to the average human observer [265]. The CFF threshold is determined by the processing in the magnocellular pathway and frontal and parietal cortex [266]. In some studies the CFF appears normal in AD patients [244, 254, 267] with no retinocalcarine abnormality specific to AD patients [254]. By contrast, other authors found significantly lower CFF and descending scores compared with healthy elderly subjects [239, 264, 268].

6.7. Dark adaptation

Older adults have serious difficulty seeing under low illumination and at night, even in the absence of ocular disease. This fact can be attributed to delayed rhodopsin regeneration [269]. The study of Rizzo et al. showed that 7 of the 10 AD patients studied had a worse adaptation to darkness than did the control group of slightly younger patients [254].

6.8. Depth perception

The ability of the human eye to see in three dimensions and judge the distance of an object is called depth perception. Depth perception is grounded in both stereopsis and monocular cues. Because measuring monocular tracks is difficult, studies typically assess stereopsis. When an object is observed, each eye sees it from a slightly different angle. Those images are then sent back to the brain to be integrated into a single image, creating the 3D effect or stereopsis. Stereopsis relies mainly in the primary visual cortex. However, a more detailed analysis reveals that stereoscopic depth takes place in visual-association areas in the dorsal and ventral cortical pathways [270]. AD patients have been found to have abnormal depth perception in comparison with controls [238, 251, 254, 271, 272]. Disturbances in stereopsis, motion parallax and interpretation of static monocular cues may result from neuropathology in the AD visual cortex [272]. Other studies investigating stereopsis in AD were inconclusive [267] or found normal operation [171]. More recently, the link between worsening depth perception and AD has been demonstrated by means of functional magnetic resonance imaging (fMRI). The fMRI has revealed hypoactivation in the areas responsible for depth perception [273].

6.9. Motion perception

Motion perception is the process of deducing the speed and direction of different elements in a scene based on different sensory stimuli: visual, vestibular and proprioceptive. Visual sensory information for motion perception is based on retina [274], LGN [275] and primary and secondary visual cortex processing [276]. There is controversy in the reports on motion perception in AD patients, as some studies have found no differences in this regard [174, 246, 267] while others have identified several deficiencies in the motion perception [173, 277]. Specifically, patients with an early-stage of AD have great difficulty interpreting the movement of objects, a condition that worsens as the disease progresses [47]. The discrepancy of the results could be related to the test used, since some require discrimination of motion direction while others simply demand the recognition of the occurrence of motion.

6.10. Pupillary response to light

Pupillary response is controlled by a balance between the cholinergic and adrenergic innervation being influenced directly or indirectly by the input from the central and autonomic nervous system.

As an impairment of the cholinergic system is known to occur in dementia and AD [278], it would be expected for the pupillary light reflex to be affected in AD [279, 280]. The constriction at the onset of bright light relative to the resting amplitude was significantly reduced in AD compared with healthy age-matched older adults and young adults [279]. These findings point to the presence of a cholinergic deficit in AD patients [280, 281], as shown by the fact that pharmacological treatment with donepezil, an anticholinesterase agent, partially improves this deficit [280]. However, it is still a challenge to develop a pupillary-response-sensitivity test specific to clinical diagnosis of early AD.

In 1994, Scinto et al. reported that AD patients had hypersensitivity of the pupil dilation after diluted tropicamide instillation [282]. Since the publication of this work, numerous studies have been performed, with several results showing both negative [283–291] and positive results [281, 282, 292–297]. Some of these studies point to a lack of specificity to the pupil tropicamide test in AD [288, 298].

6.11. Ocular motility

For the proper coordination of eye movements the retina, the brain integration of the image, and the extraocular muscles need to be coordinated [299]. It has been reported that in post-mortem studies of AD patients, the oculomotor nuclei of the brain are affected [300, 301]. Boxer et al. reported that AD patients displayed reflexive visually guided saccade abnormalities, specifically, prominent increases in horizontal saccade latency [301].

6.12. The electroretinogram (ERG)

The electroretinogram (ERG) is a record of the bioelectrical response towards light stimuli. The three types used in daily practice are full-field ERG, pattern ERG (PERG) and multifocal ERG (mfERG). For clinical purposes, full-field ERG has been standardised so that the results of different researchers can be compared [302].

There is intense controversy with respect ERG impairment in AD patients. Some studies have found that the amplitude and latency of the retinal potentials did not differ between AD and control groups [29, 32, 254, 303, 304], indicating that the PERG may not be valuable in establishing an early diagnosis of AD [304]. In the study of Kergoat et al., amplitude and latency of ERG was not affected but there was a delay on the latency of the visual evoked potentials (VEP) [32]. Other studies have reported a significant amplitude reduction in AD patients [25, 26, 305] and postulated that this result is consistent with RGC dysfunction [26].

In PERG examination, increased implicit time of P50-wave and amplitude reduction in P50- and N95-waves were observed in AD patients [41, 42, 306], and this could reflect an impairment of the magnocellular stream [306]. In addition to PERG, Krasodomska et al. studied pattern VEP in patients with early stages of AD, and normal routine ophthalmological examination results. Their most prevalent findings were amplitude reduction in N95-wave and increased latency of P100-wave. Such results showed a dysfunction of RGC and optic nerve in early stages of AD [41]. The mfERG measures macular function [337], and a decrease in electrical activity has been found in the macula of AD patients [307].

6.13. Optical coherence tomography (OCT)

OCT is a non-invasive imaging technique that works in a similar way to ultrasound, except that it uses low-coherence light waves instead of sound waves. The light waves are used to take cross-section images of the retina. As OCT allows visualisation of the retinal layers, their thickness can be mapped and measured. In fact, this technique has already been established as the standard image model for retinal tests (**Figure 1**).

Currently, RNFL, RGC and inner layers of the retina are considered indirect biomarkers of the CNS, enabling the prediction of brain pathology in patients suffering from different neurological diseases [184, 308]. Since the development of OCT, this tool has been used to measure the thickness of the RNFL in different neurodegenerative pathologies. Despite that OCT was first developed in 1991 and commercially distributed in 1995, it was not until 2001 when a study was first published on the thickness of the RNFL in patients with AD [42].

During those first years, many studies appeared focusing on the peripapillary RNFL thickness in AD patients. In every study, a significant decrease in RNFL thickness was objectified in AD patients and compared with age-matched controls. These analyses were carried out by segmenting the measures of the peripapillary thickness according to the area (superior, inferior, nasal and temporal). Several studies showed a decrease in the peripapillary RNFL thickness in all areas [10, 14, 16, 18, 42, 309]; others found that the thinning occurred in the inferior and superior regions [17, 307, 310], while in still other studies this significant decrease appeared only in the superior peripapillary region [15, 213, 311–313]. Some studies reported a certain thinning in the RNFL associated with the progressive cognitive decline [203, 312, 314]. Some authors even suggest that the inferior peripapillary quadrants might be the area with most specificity and sensitivity regarding the detection of the cognitive decline in the initial stages of the AD [17]. However, Salobar-García et al. [20] reported that their group of patients with mild AD showed no significant difference with respect to control subjects in terms of RNFL thickness of the peripapillary region (**Figure 3A**). These authors postulated that although no statistically significant differences in peripapillary RNFL were found between control and AD eyes, the increase in peripapillary thickness observed in mild-AD patients could be secondary to an inflammatory process that may represent an early stage of degeneration and could lead to progressive peripapillary fibre damage. The variability in peripapillary RNFL thickness reported in AD might be due to differences in disease progression among patients studied, since patients with greater involvement of the peripapillary region were those with a more advanced stage of AD.

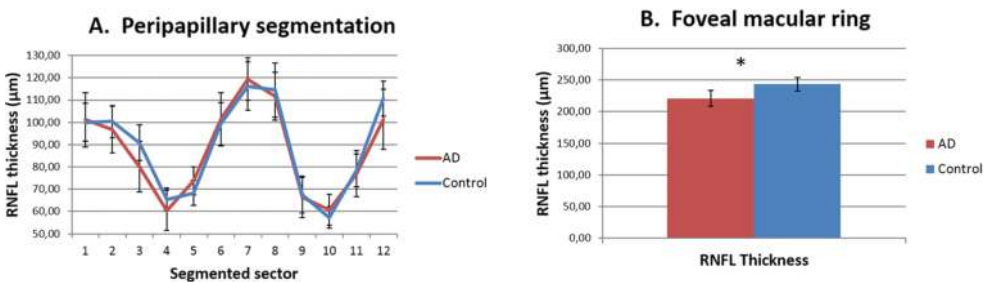


Figure 3. Mean data of RNFL thickness against eye quadrants assessed with optical coherence tomography (OCT). (a) Peripapillary segmentation retinal nerve fibre layer, (b) central macular ring (1 mm away from the fovea). **p* value < 0.01 (modified from **Figure 2** [20] with permission).

Recently, some studies focusing on the analysis of patients with mild cognitive impairment (MCI) found a thinning of the peripapillary region [62, 314–316]. MCI patients also have a thinning in the macular ganglion cell-inner plexiform layer [317]. By contrast, Ascaso et al., reported an increase in the macular volume in MCI when compared to control subjects and AD patients [315]. These findings could be explained as an increase in the macular volume caused by a possible inflammation and gliosis prior to neuronal cell death.

Recently, studies in AD analysed the measurement of not only the peripapillary RNFL thickness but also the RNFL thickness in the macular region. They demonstrated a significant RNFL thinning in the macular region of AD patients compared with age-matched controls [14, 19, 62, 63, 307, 311, 315] (**Figure 3B**). A study carried out using the latest OCT technology, which allows an analysis of the different retinal layers separately, noted that the thickness reduction occurred in the inner layers of the retina (RNFL-RGC complex), whereas the outer layers were not affected [63, 203].

In the most incipient AD stages (mild AD), psychophysical tests having the greatest predictive value are reportedly the CS, VA, unspecific errors in tritan region and the PDT [40]. In addition, the macular RNFL thickness and total macular volume measured by OCT have highly significant sensitivity and specificity for differentiating mild AD patients from healthy subjects, the thickness of the inner upper macular RNFL seeming to have the highest diagnostic value in mild AD neurodegeneration. Probably, the first affected area of the retina in mild AD is the macular area, where, due to the arrangement of the multilayer bodies of the ganglion cells, the decrease is easier to detect [19, 20]. These observations highlight the importance of applying psychophysical tests and OCT in patients with incipient AD stages.

Due to the ageing population increasing, the incidence of neurodegenerative diseases such as AD is growing. As demonstrated by the results of the visual psychophysical test mentioned above, the eye gives us a valuable window for evaluating these neurodegenerations. Therefore, the inclusion of ophthalmological examination could become an important tool in early diagnosis and follow-up of these patients.

7. Alzheimer's disease and glaucoma

In the last decade, several studies have been made on some AD patients and experimental models of glaucoma. These studies have shown some significant similarities between the two pathologies [318–320]. Furthermore, in some clinical studies where the prevalence of primary open-angle glaucoma (POAG) in AD patients was studied, an increase was observed in the incidence rate of POAG in AD patients [321, 322]. Tamura et al. identified an increase in the prevalence of the $\epsilon 4$ allele of the APOE in POAG patients, similar to those that occur in patients suffering from AD. This suggests that common mechanisms could contribute to both pathologies [322]. Lipton et al. [323] have postulated that treatment with memantine, a NMDA receptor blocker used in AD could help to slow the advance of glaucomatous neurodegeneration. This hypothesis is based on the fact that the apoptosis, mediated by excitotoxic cell death, is a factor in the physiopathology of many neurodegenerative diseases, including glaucoma.

This kind of excitotoxicity is caused by the excessive activation of NMDA glutamate receptors, at least partially. This excessive activity in the NMDA receptor entails an abnormally high influx of calcium ions in the neurons, which triggers multiple outcomes resulting in apoptosis. Thus, pharmacological blockage of NMDA receptor activity would prevent apoptosis related to excitotoxicity. However, the use of a neuroprotective drug (memantine) in patients with POAG gave discouraging results [324]. On the other hand, in a recent 12.7-year longitudinal study, no direct link was found between normotensive glaucoma and increase risk of developing dementia or AD, compared with the general population [325].

Whether or not glaucomatous optic neuropathy can be considered an ocular extension during Alzheimer's progression deserves further investigation.

Acknowledgements

This work was supported by the Ophthalmological Network OFTARED (RD12-0034/0002: Prevención, Detección Precoz y Tratamiento de la Patología Ocular Prevalente Degenerativa y Crónica) of the Institute of Health of Carlos III of the Spanish Ministry of Economy. This work has been funded by the PN I+D+i 2008–2011, by the ISCIII-Subdirección General de Redes y Centros de Investigación Cooperativa and by the European programme FEDER; grants to Elena Salobar-García are currently supported by a Predoctoral Fellowship (FPU) from the Spanish Ministry of Education, Culture and Sport. David Nesbitt corrected the English version of this work.

Author details

Elena Salobar-García¹, Ana I. Ramírez², Rosa de Hoz², Pilar Rojas³, Juan J. Salazar², Blanca Rojas¹, Raquel Yubero⁴, Pedro Gil⁴, Alberto Triviño¹ and José M. Ramírez^{1*}

*Address all correspondence to: ramirezs@med.ucm.es

1 Ramon Castroviejo Institute of Ophthalmologic Research, School of Medicine, Complutense University of Madrid (UCM), Spain

2 Ramon Castroviejo Institute of Ophthalmologic Research, School of Optics and Optometry, Complutense University of Madrid (UCM), Spain

3 Service of Ophthalmology Hospital Gregorio Marañón, Ramon Castroviejo Institute of Ophthalmologic Research, Complutense University of Madrid (UCM), Spain

4 Service of Geriatrics, University Hospital Clinico San Carlos, Complutense University of Madrid (UCM), Spain

References

- [1] Jindal V. Interconnection between brain and retinal neurodegenerations. *Molecular Neurobiology*. 2014; 51: 1–8.
- [2] Hirtz D, Thurman D, Gwinn-Hardy K, Mohamed M, Chaudhuri A, Zalutsky R. How common are the “common” neurologic disorders? *Neurology*. 2007; 68: 326–337.
- [3] Brookmeyer R, Johnson E, Ziegler-Graham K, Arrighi HM. Forecasting the global burden of Alzheimer’s disease. *Alzheimer’s and Dementia*. 2007; 3: 186–191.
- [4] Blennow K, de Leon MJ, Zetterberg H. Alzheimer’s disease. *Lancet*. 2006; 368: 387–403.
- [5] Cummings JL, Cole G. Alzheimer disease. *JAMA*. 2002; 287: 2335–2338.
- [6] Small BJ, Gagnon E, Robinson B. Early identification of cognitive deficits: preclinical Alzheimer’s disease and mild cognitive impairment. *Geriatrics*. 2007; 62: 19–23.
- [7] Ikram MK, Cheung CY, Wong TY, Chen CP. Retinal pathology as biomarker for cognitive impairment and Alzheimer’s disease. *Journal of Neurology, Neurosurgery & Psychiatry*. 2012; 83: 917–922.
- [8] Hinton DR, Sadun AA, Blanks JC, Miller CA. Optic-nerve degeneration in Alzheimer’s disease. *The New England Journal of Medicine*. 1986; 315: 485–487.
- [9] Varma R, Bazzaz S, Lai M. Optical tomography-measured retinal nerve fiber layer thickness in normal Latinos. *Investigative Ophthalmology & Visual Science*. 2003; 44: 3369–3373.
- [10] Paquet C, Boissonnot M, Roger F, Dighiero P, Gil R, Hugon J. Abnormal retinal thickness in patients with mild cognitive impairment and Alzheimer’s disease. *Neuroscience Letters*. 2007; 420: 97–99.
- [11] Cohen MJ, Kaliner E, Frenkel S, Kogan M, Miron H, Blumenthal EZ. Morphometric analysis of human peripapillary retinal nerve fiber layer thickness. *Investigative Ophthalmology & Visual Science*. 2008; 49: 941–944.
- [12] Bowd C, Zangwill LM, Blumenthal EZ, Vasile C, Boehm AG, Gokhale PA, et al. Imaging of the optic disc and retinal nerve fiber layer: the effects of age, optic disc area, refractive error, and gender. *Journal of the Optical Society of America A, Optics, Image Science, and Vision*. 2002; 19: 197–207.
- [13] Hedges III TR, Galves RP, Spiegelman D, Barbas NR, Peli E, Yardley CJ. Retinal nerve fiber layer abnormalities in Alzheimer’s disease. *Acta Ophthalmologica Scandinavica*. 1996; 74: 271–275.
- [14] Iseri PK, Altinas Ö, Tokay T, Yüksel N. Relationship between cognitive impairment and retinal morphological and visual functional abnormalities in Alzheimer disease. *Journal of Neuro-ophthalmology*. 2006; 26: 18–24.

- [15] Berisha F, Fekete GT, Trempe CL, McMeel JW, Schepens CL. Retinal abnormalities in early Alzheimer's disease. *Investigative Ophthalmology & Visual Science*. 2007; 48: 2285–2289.
- [16] Valenti DA. Neuroimaging of retinal nerve fiber layer in AD using optical coherence tomography. *Neurology*. 2007; 69: 1060.
- [17] Kesler A, Vakhapova V, Korczyn AD, Naftaliev E, Neudorfer M. Retinal thickness in patients with mild cognitive impairment and Alzheimer's disease. *Clinical Neurology and Neurosurgery*. 2011; 113: 523–526.
- [18] Moreno-Ramos T, Benito-León J, Villarejo A, Bermejo-Pareja F. Retinal nerve fiber layer thinning in dementia associated with Parkinson's disease, dementia with Lewy bodies, and Alzheimer's disease. *Journal of Alzheimer's Disease*. 2013; 34: 659–664.
- [19] Garcia-Martin ES, Rojas B, Ramirez AI, de Hoz R, Salazar JJ, Yubero R, et al. Macular thickness as a potential biomarker of mild Alzheimer's disease. *Ophthalmology*. 2014; 121: 1149–1151.
- [20] Salobar-Garcia E, Hoyas I, Leal M, de Hoz R, Rojas B, Ramirez AI, et al. Analysis of retinal peripapillary segmentation in early Alzheimer's disease patients. *BioMed Research International*. 2015; 2015: 636548.
- [21] Blanks JC, Hinton DR, Sadun AA, Miller CA. Retinal ganglion cell degeneration in Alzheimer's disease. *Brain Research*. 1989; 501: 364–372.
- [22] Sadun A, Bassi C. Optic nerve damage in Alzheimer's disease. *Ophthalmology*. 1990; 97: 9–17.
- [23] Blanks JC, Torigoe Y, Hinton DR, Blanks RHI. Retinal pathology in Alzheimer's disease. I. Ganglion cell loss in foveal/parafoveal retina. *Neurobiology of Aging*. 1996; 17: 377–384.
- [24] Blanks JC, Schmidt SY, Torigoe Y, Porrello KV, Hinton DR, Blanks RH. Retinal pathology in Alzheimer's disease. II. Regional neuron loss and glial changes in GCL. *Neurobiology of Aging*. 1996; 17: 385–395.
- [25] Katz B, Rimmer S, Iragui V, Katzman R. Abnormal pattern electroretinogram in Alzheimer's disease: evidence for retinal ganglion cell degeneration? *Annals of Neurology*. 1989; 26: 221–225.
- [26] Trick GL, Barris MC, Bickler-Bluth M. Abnormal pattern electroretinograms in patients with senile dementia of the Alzheimer type. *Annals of Neurology*. 1989; 26: 226–231.
- [27] Curcio CA, Drucker DN. Retinal ganglion cells in Alzheimer's disease and aging. *Annals of Neurology*. 1993; 33: 248–257.
- [28] Davies D, McCoubrie P, McDonald B, Jobst K. Myelinated axon number in the optic nerve is unaffected by Alzheimer's disease. *British Journal of Ophthalmology*. 1995; 79: 596–600.

- [29] Justino L, Kergoat M, Bergman H, Chertkow H, Robillard A, Kergoat H. Neuroretinal function is normal in early dementia of the Alzheimer type. *Neurobiology of Aging*. 2001; 22: 691–695.
- [30] Kergoat H, Kergoat MJ, Justino L, Robillard A, Bergman H, Chertkow H. Normal optic nerve head topography in the early stages of dementia of the Alzheimer type. *Dementia and Geriatric Cognitive Disorders*. 2001; 12: 359–363.
- [31] Kergoat H, Kergoat M, Justino L, Chertkow H, Robillard A, Bergman H. An evaluation of the retinal nerve fiber layer thickness by scanning laser polarimetry in individuals with dementia of the Alzheimer type. *Acta Ophthalmologica Scandinavica*. 2001; 79: 187–191.
- [32] Kergoat Hln, Kergoat M, Justino L, Chertkow H, Robillard A, Bergman H. Visual retinocortical function in dementia of the Alzheimer type. *Gerontology*. 2002; 48: 197–203.
- [33] Petersen R, Stevens J, Ganguli M, Tangalos E, Cummings J, DeKosky S. Practice parameter: early detection of dementia: mild cognitive impairment (an evidence-based review). Report of the Quality Standards Subcommittee of the American Academy of Neurology. *Neurology*. 2001; 56: 1133–1142.
- [34] Trick GL, Trick LR, Morris P, Wolf M. Visual field loss in senile dementia of the Alzheimer's type. *Neurology*. 1995; 45: 68–74.
- [35] Steffes R, Thralow J. Visual field limitation in the patient with dementia of the Alzheimer's type. *Journal of the American Geriatrics Society*. 1987; 35:198–204.
- [36] Risacher SL, WuDunn D, Pepin SM, MaGee TR, McDonald BC, Flashman LA, et al. Visual contrast sensitivity in Alzheimer's disease, mild cognitive impairment, and older adults with cognitive complaints. *Neurobiology of Aging*. 2013; 34: 1133–1144.
- [37] Cronin-Golomb A, Sugiura R, Corkin S, Growdon JH. Incomplete achromatopsia in Alzheimer's disease. *Neurobiology of Aging*. 1993; 14: 471–477.
- [38] Pache M, Smeets CH, Gasio PF, Savaskan E, Flammer J, Wirz-Justice A, et al. Colour vision deficiencies in Alzheimer's disease. *Age and Ageing*. 2003; 32: 422–426.
- [39] Salamone G, Di Lorenzo C, Mosti S, Lupo F, Cravello L, Palmer K, et al. Color discrimination performance in patients with Alzheimer's disease. *Dementia and Geriatric Cognitive Disorders*. 2009; 27: 501–507.
- [40] Salobarar-Garcia E, de Hoz R, Rojas B, Ramirez AI, Salazar JJ, Yubero R, et al. Ophthalmologic psychophysical tests support OCT findings in mild Alzheimer's disease. *Journal of Ophthalmology*. 2015; Article ID 736949.
- [41] Krasodomska K, Lubiński W, Potemkowski A, Honczarenko K. Pattern electroretinogram (PERG) and pattern visual evoked potential (PVEP) in the early stages of Alzheimer's disease. *Documenta Ophthalmologica*. 2010; 121: 111–121.

- [42] Parisi V, Restuccia R, Fattapposta F, Mina C, Bucci MG, Pierelli F. Morphological and functional retinal impairment in Alzheimer's disease patients. *Clinical Neurophysiology*. 2001; 112: 1860–1867.
- [43] Cronin-Golomb A, Rizzo J, Corkin S, Growdon J. Visual function in Alzheimer's disease and normal aging. *Annals of the New York Academy of Sciences*. 1991; 640: 28–35.
- [44] Lakshminarayanan V, Lagrave J, Kean ML, Dick M, Shankle R. Vision in dementia: contrast effects. *Neurological Research*. 1996; 18: 9–15.
- [45] Neargarder SA, Stone ER, Cronin-Golomb A, Oross S. The impact of acuity on performance of four clinical measures of contrast sensitivity in Alzheimer's disease. *The Journals of Gerontology Series B: Psychological Sciences and Social Sciences*. 2003; 58: P54–P62.
- [46] Valenti DA. Alzheimer's disease: visual system review. *Optometry*. 2010; 81: 12–21.
- [47] Tzekov RT, Mullan M. Vision function abnormalities in Alzheimer's disease. *Survey of Ophthalmology*. 2013; 59: 414–433.
- [48] Schlotterer G, Moscovitch M, Crapper-McLachlan D. Visual processing deficits as assessed by spatial frequency contrast sensitivity and backward masking in normal ageing and Alzheimer's disease. *Brain: A Journal of Neurology*. 1984; 107: 309–325.
- [49] Wright CE, Drasdo N, Harding GF. Pathology of the optic nerve and visual association areas information given by the flash and pattern visual evoked potential, and the temporal and spatial contrast sensitivity function. *Brain*. 1987; 110: 107–120.
- [50] Cronin-Golomb A, Corkin S, Growdon JH. Contrast sensitivity in Alzheimer's disease. *Journal of the Optical Society of America A, Optics, Image Science, and Vision*. 1987; 4: 7.
- [51] Morris JC. Mild cognitive impairment and preclinical Alzheimer's disease. *Geriatrics*. 2005; Suppl: 9–14.
- [52] Inzelberg R, Ramirez JA, Nisipeanu P, Ophir A. Retinal nerve fiber layer thinning in Parkinson disease. *Vision Research*. 2004; 44: 2793–2797.
- [53] Altintas Ö, Iseri P, Özkan B, Çağlar Y. Correlation between retinal morphological and functional findings and clinical severity in Parkinson's disease. *Documenta Ophthalmologica*. 2008; 116: 137–146.
- [54] Burkholder BM, Osborne B, Loguidice MJ, Bisker E, Frohman TC, Conger A, et al. Macular volume determined by optical coherence tomography as a measure of neuronal loss in multiple sclerosis. *Archives of Neurology*. 2009; 66: 1366–1372.
- [55] Aaker GD, Myung JS, Ehrlich JR, Mohammed M, Henchcliffe C, Kiss S. Detection of retinal changes in Parkinson's disease with spectral-domain optical coherence tomography. *Clinical Ophthalmology*. 2010; 4: 1427–1432.

- [56] Albert MS, DeKosky ST, Dickson D, Dubois B, Feldman HH, Fox NC, et al. The diagnosis of mild cognitive impairment due to Alzheimer's disease: Recommendations from the National Institute on Aging-Alzheimer's Association workgroups on diagnostic guidelines for Alzheimer's disease. *Alzheimer's and Dementia*. 2011; 7: 270–279.
- [57] Bodis-Wollner I. Foveal vision is impaired in Parkinson's disease. *Parkinsonism & Related Disorders*. 2012; 19: 1–14.
- [58] La Morgia C, Barboni P, Rizzo G, Carbonelli M, Savini G, Scaglione C, et al. Loss of temporal retinal nerve fibers in Parkinson disease: a mitochondrial pattern? *European Journal of Neurology*. 2012; 20: 198–201.
- [59] Spund B, Ding Y, Liu T, Selesnick I, Glazman S, Shrier E, et al. Remodeling of the fovea in Parkinson disease. *Journal of Neural Transmission*. 2013; 120: 745–753.
- [60] Tátrai E, Simó M, Iljicsov A, Németh J, DeBuc DC, Somfai GM. In vivo evaluation of retinal neurodegeneration in patients with multiple sclerosis. *PLoS ONE*. 2012; 7: e30922.
- [61] Satue M, Garcia-Martin E, Fuertes I, Otin S, Alarcia R, Herrero R, et al. Use of Fourier-domain OCT to detect retinal nerve fiber layer degeneration in Parkinson's disease patients. *Eye*. 2013; 27: 507–514.
- [62] Gao L, Liu Y, Li X, Bai Q, Liu P. Abnormal retinal nerve fiber layer thickness and macula lutea in patients with mild cognitive impairment and Alzheimer's disease. *Archives of Gerontology and Geriatrics*. 2015; 60: 162–167
- [63] Marziani E, Pomati S, Ramolfo P, Cigada M, Giani A, Mariani C, et al. Evaluation of retinal nerve fiber layer and ganglion cell layer thickness in Alzheimer's disease using spectral-domain optical coherence tomography. *Investigative Ophthalmology & Visual Science*. 2013; 54: 5953–5958.
- [64] Maldonado RS, Mettu P, El-Dairi M, Bhatti MT. The application of optical coherence tomography in neurologic diseases. *Neurology: Clinical Practice*. 2015; 5: 460–469.
- [65] Millán Calenti JC. *Gerontology and Geriatrics: assessment and intervention*. Madrid; Médica Panamericana. 2010; 708.
- [66] López-Otín C, Blasco MA, Partridge L, Serrano M, Kroemer G. The hallmarks of aging. *Cell*. 2013; 153: 1194–1217.
- [67] Oh SR, Chokthaweesak W, Annunziata CC, Priel A, Korn BS, Kikkawa DO. Analysis of eyelid fat pad changes with aging. *Ophthalmic Plastic & Reconstructive Surgery*. 2011; 27: 348–351.
- [68] Shore JW. Changes in lower eyelid resting position, movement, and tone with age. *American Journal of Ophthalmology*. 1985; 99: 415–423.
- [69] Van Haeringen N. Aging and the lacrimal system. *British Journal of Ophthalmology*. 1997; 81: 824–826.

- [70] Zhu W, Hong J, Zheng T, Le Q, Xu J, Sun X. Age-related changes of human conjunctiva on in vivo confocal microscopy. *British Journal of Ophthalmology*. 2010; 94: 1448–1453.
- [71] Rada JA, Achen VR, Penugonda S, Schmidt RW, Mount BA. Proteoglycan composition in the human sclera during growth and aging. *Investigative Ophthalmology & Visual Science*. 2000; 41: 1639–1648.
- [72] Grossniklaus HE, Nickerson JM, Edelhauser HF, Bergman LA, Berglin L. Anatomic alterations in aging and age-related diseases of the eye. *Investigative Ophthalmology & Visual Science*. 2013; 54: ORSF23–ORSF27.
- [73] Faragher R, Mulholland B, Tuft S, Sandeman S, Khaw P. Aging and the cornea. *British Journal of Ophthalmology*. 1997; 81: 814–817.
- [74] Gipson IK. Age-related changes and diseases of the ocular surface and cornea. *Investigative Ophthalmology & Visual Science*. 2013; 54: ORSF48–ORSF53.
- [75] McMenamin PG, Lee WR, Aitken DA. Age-related changes in the human outflow apparatus. *Ophthalmology*. 1986; 93: 194–209.
- [76] Salvi S, Akhtar S, Currie Z. Ageing changes in the eye. *Postgraduate Medical Journal*. 2006; 82: 581–587.
- [77] Birren JE, Casperson RC, Botwinick J. Age changes in pupil size. *Journal of Gerontology*. 1950; 5: 216–221.
- [78] Barteselli G, Chhablani J, El-Emam S, Wang H, Chuang J, Kozak I, et al. Choroidal volume variations with age, axial length, and sex in healthy subjects: a three-dimensional analysis. *Ophthalmology*. 2012; 119: 2572–2578.
- [79] Ramrattan RS, van der Schaft, Theo L, Mooy CM, De Bruijn W, Mulder P, De Jong P. Morphometric analysis of Bruch's membrane, the choriocapillaris, and the choroid in aging. *Investigative Ophthalmology & Visual Science*. 1994; 35: 2857–2864.
- [80] Pauleikhoff D, Harper CA, Marshall J, Bird AC. Aging changes in Bruch's membrane: a histochemical and morphologic study. *Ophthalmology*. 1990; 97: 171–178.
- [81] Newsome DA, Huh W, Green WR. Bruch's membrane age-related changes vary by region. *Current Eye Research*. 1987; 6: 1211–1221.
- [82] Ramírez JM, Ramírez AI, Salazar JJ, de Hoz R, Triviño A. Changes of astrocytes in retinal ageing and age-related macular degeneration. *Experimental Eye Research*. 2001; 73: 601–615.
- [83] Grunwald JE, Piltz J, Patel N, Bose S, Riva CE. Effect of aging on retinal macular microcirculation: a blue field simulation study. *Investigative Ophthalmology & Visual Science*. 1993; 34: 3609–3613.
- [84] Moya FJ, Brigatti L, Caprioli J. Effect of aging on optic nerve appearance: a longitudinal study. *British Journal of Ophthalmology*. 1999; 83: 567–572.

- [85] Sebag J. Ageing of the vitreous. *Eye*. 1987; 1: 254–262.
- [86] Dagnelie G. Age-Related Psychophysical Changes and Low Vision. *Investigative Ophthalmology & Visual Science*. 2013; 54: ORSF88–ORSF93.
- [87] Haegerstrom-Portnoy G, Schneck ME, Brabyn JA, Lott LA. Development of refractive errors into old age. *Optometry & Vision Science*. 2002; 79: 643–649.
- [88] Derefeldt G, Lennerstrand G, Lundh B. Age variations in normal human contrast sensitivity. *Acta Ophthalmologica*. 1979; 57: 679–690.
- [89] Leat SJ, Chan LL, Maharaj P, Hrynychak PK, Mittelstaedt A, Machan CM, et al. Binocular vision and eye movement disorders in older adults. *Investigative Ophthalmology & Visual Science*. 2013; 54: 3798–3805.
- [90] Reuter-Lorenz PA. New visions of the aging mind and brain. *Trends in Cognitive Sciences*. 2002; 6: 394–400.
- [91] Creasey H, Rapoport SI. The aging human brain. *Annals of Neurology*. 1985; 17: 2–10.
- [92] Masliah E, Mallory M, Hansen L, DeTeresa R, Terry R. Quantitative synaptic alterations in the human neocortex during normal aging. *Neurology*. 1993; 43: 192.
- [93] Hof PR, Morrison JH. The aging brain: morphomolecular senescence of cortical circuits. *Trends in Neurosciences*. 2004; 27: 607–613.
- [94] Hedden T, Gabrieli JDE. Insights into the ageing mind: a view from cognitive neuroscience. *Nature Reviews Neuroscience*. 2004; 5: 87–96.
- [95] Pappolla M, Omar R, Saran B. The “normal” brain.” Abnormal ubiquitinated deposits highlight an age-related protein change. *American Journal of Pathology*. 1989; 135: 585–591.
- [96] Nakano M, Oenzil F, Mizuno T, Gotoh S. Age-related changes in the lipofuscin accumulation of brain and heart. *Gerontology*. 1995; 41: 69–80.
- [97] Coria F, Moreno A, Rubio I, Garcia M, Morato E. The cellular pathology associated with Alzheimer β -amyloid deposits in non-demented aged individuals. *Neuropathology and Applied Neurobiology*. 1993; 19: 261–268.
- [98] Morris JC, McKeel Jr D, Storandt M, Rubin E, Price J, Grant E, et al. Very mild Alzheimer’s disease Informant-based clinical, psychometric, and pathologic distinction from normal aging. *Neurology*. 1991; 41: 469–478.
- [99] Boone KB, Miller BL, Lesser IM, Mehninger CM, Hill-Gutierrez E, Goldberg MA, et al. Neuropsychological correlates of white-matter lesions in healthy elderly subjects: a threshold effect. *Archives of Neurology*. 1992; 49: 549–554.
- [100] Zerfass R, Geiger-Kabisch C, Sattel H, Besthorn C, Hentschel F. Brain atrophy in normal ageing and Alzheimer’s disease. Volumetric discrimination and clinical correlations. *British Journal of Psychiatry*. 1995; 167: 739–746.

- [101] Reed BR, Eberling JL, Mungas D, Weiner M, Kramer JH, Jagust WJ. Effects of white matter lesions and lacunes on cortical function. *Archives of Neurology*. 2004; 61: 1545–1550.
- [102] O'Brien JT, Erkinjuntti T, Reisberg B, Roman G, Sawada T, Pantoni L, et al. Vascular cognitive impairment. *Lancet Neurology*. 2003; 2: 89–98.
- [103] Fratiglioni L, Mangialasche F, Qiu C. Brain aging: lessons from community studies. *Nutrition Reviews*. 2010; 68: S119–S127.
- [104] Grammas P, Martinez J, Miller B. Cerebral microvascular endothelium and the pathogenesis of neurodegenerative diseases. *Expert Reviews in Molecular Medicine*. 2011; 13: e19.
- [105] Mrazek RE, Griffin S, Graham DI. Aging-associated changes in human brain. *Journal of Neuropathology and Experimental Neurology*. 1997; 56: 1269–1275.
- [106] Li L, Lundkvist A, Andersson D, Wilhelmsson U, Nagai N, Pardo AC, et al. Protective role of reactive astrocytes in brain ischemia. *Journal of Cerebral Blood Flow & Metabolism*. 2007; 28: 468–481.
- [107] Frith CD, Frith U. Implicit and explicit processes in social cognition. *Neuron*. 2008; 60: 503–510.
- [108] Sander M, Bergersen LH, Storm-Mathisen J. Molecular approaches to understanding neural network plasticity and memory: the Kavli Prize Inaugural Symposium on Neuroscience. *Neuroscience*. 2009; 163: 965–976.
- [109] Dámaso S, Viadero C. Normal and Pathological changes in aging brain. *Revista Neuropsicología, Neuropsiquiatría y Neurociencias*. 2012; 12: 21–36.
- [110] Bliss TVP, Lømo T. Long-lasting potentiation of synaptic transmission in the dentate area of the anaesthetized rabbit following stimulation of the perforant path. *Journal of Physiology*. 1973; 232: 331–356.
- [111] Alvarez VA, Sabatini BL. Anatomical and physiological plasticity of dendritic spines. *Annual Review of Neuroscience*. 2007; 30: 79–97.
- [112] VanGuilder HD, Farley JA, Yan H, Van Kirk CA, Mitschelen M, Sonntag WE, et al. Hippocampal dysregulation of synaptic plasticity-associated proteins with age-related cognitive decline. *Neurobiology of Disease*. 2011; 43: 201–212.
- [113] Schliebs R, Arendt T. The cholinergic system in aging and neuronal degeneration. *Behavioural Brain Research*. 2011; 221: 555–563.
- [114] London A, Benhar I, Schwartz M. The retina as a window to the brain—from eye research to CNS disorders. *Nature Reviews Neurology*. 2013; 9: 44–53.
- [115] Ramachandran VS. *Encyclopedia of the Human Brain*. Academic Press; 2002.

- [116] Faden AI, Salzman S. Pharmacological strategies in CNS trauma. *Trends in Pharmacological Sciences*. 1992; 13: 29–35.
- [117] Schwartz M, Belkin M, Yoles E, Solomon A. Potential treatment modalities for glaucomatous neuropathy: neuroprotection and neuroregeneration. *Journal of Glaucoma*. 1996; 5: 427–432.
- [118] Crowe MJ, Bresnahan JC, Shuman SL, Masters JN, Crowe MS. Apoptosis and delayed degeneration after spinal cord injury in rats and monkeys. *Nature Medicine*. 1997; 3: 73–76.
- [119] Yoles E, Schwartz M. Degeneration of spared axons following partial white matter lesion: implications for optic nerve neuropathies. *Experimental Neurology*. 1998; 153: 1–7.
- [120] Levkovitch-Verbin H, Quigley HA, Kerrigan-Baumrind LA, D'Anna SA, Kerrigan D, Pease ME. Optic nerve transection in monkeys may result in secondary degeneration of retinal ganglion cells. *Investigative Ophthalmology & Visual Science*. 2001; 42: 975–982.
- [121] Levkovitch-Verbin H, Quigley HA, Martin KR, Zack DJ, Pease ME, Valenta DF. A model to study differences between primary and secondary degeneration of retinal ganglion cells in rats by partial optic nerve transection. *Investigative Ophthalmology & Visual Science*. 2003; 44: 3388–3393.
- [122] Vidal-Sanz M, Bray GM, Villegas-Perez M, Thanos S, Aguayo AJ. Axonal regeneration and synapse formation in the superior colliculus by retinal ganglion cells in the adult rat. *Journal of Neuroscience*. 1987; 7: 2894–2909.
- [123] Villegas-Perez M, Vidal-Sanz M, Bray GM, Aguayo AJ. Influences of peripheral nerve grafts on the survival and regrowth of axotomized retinal ganglion cells in adult rats. *Journal of Neuroscience*. 1988; 8: 265–280.
- [124] Keirstead S, Rasminsky M, Fukuda Y, Carter D, Aguayo A, Vidal-Sanz M. Electrophysiological responses in hamster superior colliculus evoked by regenerating retinal axons. *Science*. 1989; 246: 255–257.
- [125] Moalem G, Leibowitz-Amit R, Yoles E, Mor F, Cohen IR, Schwartz M. Autoimmune T cells protect neurons from secondary degeneration after central nervous system axotomy. *Nature Medicine*. 1999; 5: 49–55.
- [126] Kipnis J, Yoles E, Porat Z, Cohen A, Mor F, Sela M, et al. T cell immunity to copolymer 1 confers neuroprotection on the damaged optic nerve: possible therapy for optic neuropathies. *Proceedings of the National Academy of Sciences of the United States of America*. 2000; 97: 7446–7451.
- [127] Lingor P, Teusch N, Schwarz K, Mueller R, Mack H, Bähr M, et al. Inhibition of Rho kinase (ROCK) increases neurite outgrowth on chondroitin sulphate proteoglycan in

- vitro and axonal regeneration in the adult optic nerve in vivo. *Journal of Neurochemistry*. 2007; 103: 181–189.
- [128] Benowitz L, Yin Y. Rewiring the injured CNS: lessons from the optic nerve. *Experimental Neurology*. 2008; 209: 389–398.
 - [129] David S, Aguayo AJ. Axonal elongation into peripheral nervous system “bridges” after central nervous system injury in adult rats. *Science*. 1981; 214: 931–933.
 - [130] Streilein JW. Ocular immune privilege: therapeutic opportunities from an experiment of nature. *Nature Reviews Immunology*. 2003; 3: 879–889.
 - [131] Kaur C, Foulds W, Ling E. Blood–retinal barrier in hypoxic ischaemic conditions: basic concepts, clinical features and management. *Progress in Retinal and Eye Research*. 2008; 27: 622–647.
 - [132] Wilbanks GA, Wayne Streilein J. Fluids from immune privileged sites endow macrophages with the capacity to induce antigen-specific immune deviation via a mechanism involving transforming growth factor- β . *European Journal of Immunology*. 1992; 22: 1031–1036.
 - [133] Taylor A, Streilein J. Inhibition of antigen-stimulated effector T cells by human cerebrospinal fluid. *Neuroimmunomodulation*. 1996; 3: 112–118.
 - [134] Nassi JJ, Callaway EM. Parallel processing strategies of the primate visual system. *Nature Reviews Neuroscience*. 2009; 10: 360–372.
 - [135] Mandal PK, Joshi J, Saharan S. Visuospatial perception: an emerging biomarker for Alzheimer’s disease. *Journal of Alzheimer’s Disease*. 2012; 31: 117–135.
 - [136] Livingstone MS, Hubel DH. Psychophysical evidence for separate channels for the perception of form, color, movement, and depth. *Journal of Neuroscience*. 1987; 7: 3416–3468.
 - [137] Maunsell JH, Newsome WT. Visual processing in monkey extrastriate cortex. *Annual Review of Neuroscience*. 1987; 10: 363–401.
 - [138] Chatterjee S, Callaway EM. Parallel colour-opponent pathways to primary visual cortex. *Nature*. 2003; 426: 668–671.
 - [139] Roe AW, Ts’o DY. Visual topography in primate V2: multiple representation across functional stripes. *The Journal of Neuroscience*. 1995; 15: 3689–3715.
 - [140] Braddick OJ, O’Brien JM, Wattam-Bell J, Atkinson J, Hartley T, Turner R. Brain areas sensitive to coherent visual motion. *Perception-London*. 2001; 30: 61–72.
 - [141] Possin KL. Visual spatial cognition in neurodegenerative disease. *Neurocase*. 2010; 16: 466–487.
 - [142] Zeki S. The disunity of consciousness. *Progress in Brain Research*. 2007; 168: 11–268.

- [143] Cheung N, Mosley T, Islam A, Kawasaki R, Sharrett AR, Klein R, et al. Retinal microvascular abnormalities and subclinical magnetic resonance imaging brain infarct: a prospective study. *Brain*. 2010; 133: 1987–1993.
- [144] Wong TY, Klein R, Sharrett AR, Couper DJ, Klein BE, Liao D, et al. Cerebral white matter lesions, retinopathy, and incident clinical stroke. *JAMA*. 2002; 288: 67–74.
- [145] Wong TY, Klein R, Couper DJ, Cooper LS, Shahar E, Hubbard LD, et al. Retinal microvascular abnormalities and incident stroke: the Atherosclerosis Risk in Communities Study. *Lancet*. 2001; 358: 1134–1140.
- [146] Wong TY, Klein R, Klein BE, Tielsch JM, Hubbard L, Nieto FJ. Retinal microvascular abnormalities and their relationship with hypertension, cardiovascular disease, and mortality. *Survey of Ophthalmology*. 2001; 46: 59–80.
- [147] Kalesnykas G, Tuulos T, Uusitalo H, Jolkkonen J. Neurodegeneration and cellular stress in the retina and optic nerve in rat cerebral ischemia and hypoperfusion models. *Neuroscience*. 2008; 155: 937–947.
- [148] Patton N, Aslam T, MacGillivray T, Pattie A, Deary IJ, Dhillon B. Retinal vascular image analysis as a potential screening tool for cerebrovascular disease: a rationale based on homology between cerebral and retinal microvasculatures. *Journal of Anatomy*. 2005; 206: 319–348.
- [149] Baker ML, Hand PJ, Wang JJ, Wong TY. Retinal signs and stroke: revisiting the link between the eye and brain. *Stroke*. 2008; 39: 1371–1379.
- [150] London A, Itskovich E, Benhar I, Kalchenko V, Mack M, Jung S, et al. Neuroprotection and progenitor cell renewal in the injured adult murine retina requires healing monocyte-derived macrophages. *Journal of Experimental Medicine*. 2011; 208: 23–39.
- [151] Wardlaw JM, Doubal F, Armitage P, Chappell F, Carpenter T, Muñoz Maniega S, et al. Lacunar stroke is associated with diffuse blood–brain barrier dysfunction. *Annals of Neurology*. 2009; 65: 194–202.
- [152] Leibowitz U, Alter M. Optic nerve involvement and diplopia as initial manifestations of multiple sclerosis. *Acta Neurologica Scandinavica*. 1968; 44: 70–80.
- [153] McDonald W, Barnes D. The ocular manifestations of multiple sclerosis. 1. Abnormalities of the afferent visual system. *Journal of Neurology, Neurosurgery, and Psychiatry*. 1992; 55: 747–752.
- [154] Sørensen T, Frederiksen J, Brønnum-Hansen H, Petersen H. Optic neuritis as onset manifestation of multiple sclerosis: a nationwide, long-term survey. *Neurology*. 1999; 53: 473–473.
- [155] Patel SJ, Lundy DC. Ocular manifestations of autoimmune disease. *American Family Physician*. 2002; 66: 991–998.

- [156] Gundogan FC, Tas A, Erdem U, Sobaci G. Retinal pathology in multiple sclerosis: insight into the mechanisms of neuronal pathology. *Brain: A Journal of Neurology*. 2011; 134: 1–2 /e171.
- [157] Ghezzi A, Martinelli V, Torri V, Zaffaroni M, Rodegher M, Comi G, et al. Long-term follow-up of isolated optic neuritis: the risk of developing multiple sclerosis, its outcome, and the prognostic role of paraclinical tests. *Journal of Neurology*. 1999; 246: 770–775.
- [158] Regan D, Silver R, Murray TJ. Visual acuity and contrast sensitivity in multiple sclerosis – hidden visual loss: an auxiliary diagnostic test. *Brain: A Journal of Neurology*. 1977; 100: 563–579.
- [159] Balcer L, Baier M, Cohen J, Kooijmans M, Sandrock A, Nano-Schiavi M, et al. Contrast letter acuity as a visual component for the Multiple Sclerosis Functional Composite. *Neurology*. 2003; 61: 1367–1373.
- [160] Fischer P, Jungwirth S, Zehetmayer S, Weissgram S, Hoenigschnabl S, Gelpi E, et al. Conversion from subtypes of mild cognitive impairment to Alzheimer dementia. *Neurology*. 2007; 68: 288–291.
- [161] Monteiro ML, Fernandes DB, Apóstolos-Pereira SL, Callegaro D. Quantification of retinal neural loss in patients with neuromyelitis optical and multiple sclerosis with or without optic neuritis using Fourier-domain optical coherence tomography. *Investigative Ophthalmology & Visual Science*. 2012; 53: 3959–3966.
- [162] Frohman E, Costello F, Zivadinov R, Stuve O, Conger A, Winslow H, et al. Optical coherence tomography in multiple sclerosis. *Lancet Neurology*. 2006; 5: 853–863.
- [163] Zaveri MS, Conger A, Salter A, Frohman TC, Galetta SL, Markowitz CE, et al. Retinal imaging by laser polarimetry and optical coherence tomography evidence of axonal degeneration in multiple sclerosis. *Archives of Neurology*. 2008; 65: 924–928.
- [164] Adam CR, Shrier E, Ding Y, Glazman S, Bodis-Wollner I. Correlation of inner retinal thickness evaluated by spectral-domain optical coherence tomography and contrast sensitivity in Parkinson disease. *Journal of Neuro-ophthalmology*. 2013; 33: 137–142.
- [165] Masson G, Mestre D, Blin O. Dopaminergic modulation of visual sensitivity in man. *Fundamental & Clinical pharmacology*. 1993; 7: 449–463.
- [166] Moschos MM, Tagaris G, Markopoulos I, Margetis I, Tsapakis S, Kanakis M, et al. Morphologic changes and functional retinal impairment in patients with Parkinson disease without visual loss. *European Journal of Ophthalmology*. 2011; 21: 24–29.
- [167] Yu J, Feng Y, Xiang Y, Huang J, Savini G, Parisi V, et al. Retinal nerve fiber layer thickness changes in Parkinson disease: a meta-analysis. *PLoS One*. 2014; 9: e85718.

- [168] Onofrj M, Ghilardi M, Basciani M, Gambi D. Visual evoked potentials in parkinsonism and dopamine blockade reveal a stimulus-dependent dopamine function in humans. *Journal of Neurology, Neurosurgery & Psychiatry*. 1986; 49: 1150–1159.
- [169] Mapstone M, Dickerson K, Duffy CJ. Distinct mechanisms of impairment in cognitive ageing and Alzheimer's disease. *Brain : A Journal of Neurology*. 2008; 131: 1618–1629.
- [170] Prvulovic D, Hubl D, Sack A, Melillo L, Maurer K, Frölich L, et al. Functional imaging of visuospatial processing in Alzheimer's disease. *NeuroImage*. 2002; 17: 1403–1414.
- [171] Rizzo M, Anderson SW, Dawson J, Nawrot M. Vision and cognition in Alzheimer's disease. *Neuropsychologia*. 2000; 38: 1157–1169.
- [172] Tippet WJ, Black SE. Regional cerebral blood flow correlates of visuospatial tasks in Alzheimer's disease. *Journal of the International Neuropsychological Society*. 2008; 14: 1034–1045.
- [173] Kurylo DD, Corkin S, Dolan RP, Rizzo JF, Parker SW, Growdon JH. Broad-band visual capacities are not selectively impaired in Alzheimer's disease. *Neurobiology of Aging*. 1994; 15: 305–311.
- [174] Rizzo M, Anderson S, Dawson J, Myers R, Ball K. Visual attention impairments in Alzheimer's disease. *Neurology*. 2000; 54: 1954–1959.
- [175] Holroyd S, Shepherd ML. Alzheimer's disease: a review for the ophthalmologist. *Survey of Ophthalmology*. 2001; 45: 516–524.
- [176] Jackson GR, Owsley C. Visual dysfunction, neurodegenerative diseases, and aging. *Neurologic Clinics*. 2003; 21: 709–728.
- [177] Cummings JL. Alzheimer's disease. *The New England Journal of Medicine*. 2004; 351: 56–67.
- [178] Denise A. V. Alzheimer's disease: visual system review. *Optometry*. 2010; 81: 12–21.
- [179] Frost S, Martins RN, Kanagasalingam Y. Ocular biomarkers for early detection of Alzheimer's disease. *Journal of Alzheimer's Disease*. 2010; 22: 1–16.
- [180] Kirby E, Bandelow S, Hogervorst E. Visual impairment in Alzheimer's disease: a critical review. *Journal of Alzheimer's Disease*. 2010; 21: 15–34.
- [181] Chiu K, Chan T, Wu A, Leung IY, So K, Chang RC. Neurodegeneration of the retina in mouse models of Alzheimer's disease: what can we learn from the retina? *Age*. 2012; 34: 633–649.
- [182] Chiu K, So K, Chang RC. Progressive neurodegeneration of retina in Alzheimer's disease—are β -amyloid peptide and tau new pathological factors in glaucoma? In: Rumelt S, editor. *Glaucoma – basic and clinical aspects*. InTech; 2013. p. 157–177.

- [183] Sivak JM. The aging eye: common degenerative mechanisms between the Alzheimer's brain and retinal disease. *Investigative Ophthalmology & Visual Science*. 2013; 54: 871–880.
- [184] Ong Y, Ong Y, Ikram MK, Chen CLH, Wong TY, Cheung CY. Potential applications of Spectral-Domain Optical Coherence Tomography (SD-OCT) in the study of Alzheimer's Disease. *Proceedings of Singapore Healthcare*. 2014; 23: 74–83.
- [185] Dehabadi MH, Davis BM, Wong TK, Cordeiro MF. Retinal manifestations of Alzheimer's disease. *Neurodegenerative Disease Management*. 2014; 4: 241–252.
- [186] Thomson KL, Yeo JM, Waddell B, Cameron JR, Pal S. A systematic review and meta-analysis of retinal nerve fiber layer change in dementia, using optical coherence tomography. *Alzheimer's & Dementia: Diagnosis, Assessment & Disease Monitoring*. 2015; 1: 136–143.
- [187] Kopishinskaya S, Svetozarskiy S. Retinal optical coherence tomography in neurodegenerative diseases (review). *Sovremennye Tehnologii v Medicine*. 2015; 7: 116–123.
- [188] Parnell M, Guo L, Abdi M, Cordeiro MF. Ocular manifestations of Alzheimer's disease in animal models. *International Journal of Alzheimer's Disease*. 2012; 2012: 786494.
- [189] Goldstein LE, Muffat JA, Cherny RA, Moir RD, Ericsson MH, Huang X, et al. Cytosolic β -amyloid deposition and supranuclear cataracts in lenses from people with Alzheimer's disease. *Lancet*. 2003; 361: 1258–1265.
- [190] Bei L, Shui Y, Bai F, Nelson SK, Van Stavern GP, Beebe DC. A test of lens opacity as an indicator of preclinical Alzheimer Disease. *Experimental Eye Research*. 2015; 140: 117–123.
- [191] Tsai Y, Lu B, Ljubimov AV, Girman S, Ross-Cisneros FN, Sadun AA, et al. Ocular changes in TgF344-AD rat model of Alzheimer's disease. *Investigative Ophthalmology & Visual Science*. 2014; 55: 523–534.
- [192] Frost S, Kanagasalingam Y, Sohrabi H, Vignarajan J, Bourgeat P, Salvado O, et al. Retinal vascular biomarkers for early detection and monitoring of Alzheimer's disease. *Translational Psychiatry*. 2013; 3: e233.
- [193] de la Torre JC. Alzheimer disease as a vascular disorder: nosological evidence. *Stroke*. 2002; 33: 1152–1162.
- [194] Bell RD, Zlokovic BV. Neurovascular mechanisms and blood–brain barrier disorder in Alzheimer's disease. *Acta Neuropathologica*. 2009; 118: 103–113.
- [195] Mroczkowska S, Benavente-Perez A, Patel S, Qin L, Bentham P, Gherghel D. Retinal vascular dysfunction relates to cognitive impairment in Alzheimer disease. *Alzheimer Disease and Associated Disorders*. 2014; 28: 366–367.

- [196] Ning A, Cui J, To E, Ashe KH, Matsubara J. Amyloid- β deposits lead to retinal degeneration in a mouse model of Alzheimer disease. *Investigative Ophthalmology & Visual Science*. 2008; 49: 5136–5143.
- [197] Liu B, Rasool S, Yang Z, Glabe CG, Schreiber SS, Ge J, et al. Amyloid-peptide vaccinations reduce β -amyloid plaques but exacerbate vascular deposition and inflammation in the retina of Alzheimer's transgenic mice. *American Journal of Pathology*. 2009; 175: 2099–2110.
- [198] Gasparini L, Anthony Crowther R, Martin KR, Berg N, Coleman M, Goedert M, et al. Tau inclusions in retinal ganglion cells of human P301S tau transgenic mice: effects on axonal viability. *Neurobiology of Aging*. 2011; 32: 419–433.
- [199] Koronyo-Hamaoui M, Koronyo Y, Ljubimov AV, Miller CA, Ko MK, Black KL, et al. Identification of amyloid plaques in retinas from Alzheimer's patients and noninvasive in vivo optical imaging of retinal plaques in a mouse model. *NeuroImage*. 2011; 54: S204–S217.
- [200] Kayabasi U, Sergott R, Rispoli M. Retinal examination for the diagnosis of Alzheimer's disease. *International Journal of Ophthalmic Pathology*. 2014; 3: 4.
- [201] Campbell MC, DeVries D, Emptage L, Cookson C, Kisilak M, Bueno J, Avila F. Polarization properties of amyloid beta in the retina of the eye as a biomarker of Alzheimer's disease. In *Optics in the life sciences, OSA technical digest (online)*. Optical Society of America; 2015, paper BM3A.4.
- [202] Gharbiya M, Trebbastoni A, Parisi F, Manganiello S, Cruciani F, D'Antonio F, et al. Choroidal thinning as a new finding in Alzheimer's disease: evidence from enhanced depth imaging spectral domain optical coherence tomography. *Journal of Alzheimer's Disease*. 2014; 40: 907–917.
- [203] Bayhan HA, Aslan Bayhan S, Celikbilek A, Tanık N, Gürdal C. Evaluation of the chorioretinal thickness changes in Alzheimer's disease using spectral-domain optical coherence tomography. *Clinical & Experimental Ophthalmology*. 2014; 43: 145–151.
- [204] Kam JH, Lenassi E, Jeffery G. Viewing ageing eyes: diverse sites of amyloid Beta accumulation in the ageing mouse retina and the up-regulation of macrophages. *PLoS One*. 2010; 5: e13127.
- [205] Bailey TL, Rivara CB, Rocher AB, Hof PR. The nature and effects of cortical microvascular pathology in aging and Alzheimer's disease. *Neurological Research*. 2004; 26: 573–578.
- [206] Marchesi VT. Alzheimer's dementia begins as a disease of small blood vessels, damaged by oxidative-induced inflammation and dysregulated amyloid metabolism: implications for early detection and therapy. *FASEB*. 2011; 25: 5–13.
- [207] Miao J, Xu F, Davis J, Otte-Höller I, Verbeek MM, Van Nostrand WE. Cerebral microvascular amyloid β protein deposition induces vascular degeneration and neuroin-

- flammation in transgenic mice expressing human vasculotropic mutant amyloid β precursor protein. *American Journal of Pathology*. 2005; 167: 505–515.
- [208] Syed AB, Armstrong RA, Smith C. A quantitative analysis of optic nerve axons in elderly control subjects and patients with Alzheimer's disease. *Folia Neuropathologica*. 2005; 43: 1–6.
- [209] Kusbeci T, Kusbeci OY, Mas NG, Karabekir HS, Yavas G, Yucel A. Stereological evaluation of the optic nerve volume in Alzheimer disease. *Journal of Craniofacial Surgery*. 2015; 26: 1683–1686.
- [210] Cuzzo LM, Ross-Cisneros FN, Yee KM, Wang MY, Sadun AA. Low density lipoprotein receptor-related protein (LRP) is decreased in optic neuropathy of Alzheimer's disease. *Journal of Neuro-ophthalmology*. 2011; 31: 139–146.
- [211] Wang MY, Ross-Cisneros FN, Aggarwal D, Liang C, Sadun AA. Receptor for advanced glycation end products is upregulated in optic neuropathy of Alzheimer's disease. *Acta Neuropathologica*. 2009; 118: 381–389.
- [212] Tsai CS, Ritch R, Schwartz B, Lee SS, Miller NR, Chi T, et al. Optic nerve head and nerve fiber layer in Alzheimer's disease. *Archives of Ophthalmology*. 1991; 109: 199–204.
- [213] Kromer R, Serbecic N, Hausner L, Aboul-enein F, Froelich L, Beutelspacher S. Detection of retinal nerve fiber layer defects in Alzheimer's disease using SD-OCT. *Frontiers in Psychiatry*. 2014; 5: 22.
- [214] Danesh-Meyer H, Birch H, Ku JYF, Carroll S, Gamble G. Reduction of optic nerve fibers in patients with Alzheimer disease identified by laser imaging. *Neurology*. 2006; 67: 1852–1854.
- [215] Scholtz C, Swettenham K, Brown A, Mann D. A histoquantitative study of the striate cortex and lateral geniculate body in normal, blind and demented subjects. *Neuropathology and Applied Neurobiology*. 1981; 7: 103–114.
- [216] Dugger BN, Tu M, Murray ME, Dickson DW. Disease specificity and pathologic progression of tau pathology in brainstem nuclei of Alzheimer's disease and progressive supranuclear palsy. *Neuroscience Letters*. 2011; 491: 122–126.
- [217] Iseki E, Matsushita M, Kosaka K, Kondo H, Ishii T, Amano N. Distribution and morphology of brain stem plaques in Alzheimer's disease. *Acta Neuropathologica*. 1989; 78: 131–136.
- [218] Leuba G, Saini K. Pathology of subcortical visual centres in relation to cortical degeneration in Alzheimer's disease. *Neuropathology and Applied Neurobiology*. 1995; 21: 410–422.
- [219] Parvizi J, Van Hoesen GW, Damasio A. The selective vulnerability of brainstem nuclei to Alzheimer's disease. *Annals of Neurology*. 2001; 49: 53–66.

- [220] Katz B, Rimmer S. Ophthalmologic manifestations of Alzheimer's disease. *Survey of Ophthalmology*. 1989; 34: 31–43.
- [221] Dai J, Vliet JVD, Swaab DF, Buijs RM. Human retinohypothalamic tract as revealed by in vitro postmortem tracing. *Journal of Comparative Neurology*. 1998; 397: 357–370.
- [222] Swaab DF, Fliers E, Partiman T. The suprachiasmatic nucleus of the human brain in relation to sex, age and senile dementia. *Brain Research*. 1985; 342: 37–44.
- [223] Goudsmit E, Hofman M, Fliers E, Swaab F. The supraoptic and paraventricular nuclei of the human hypothalamus in relation to sex, age and Alzheimer's disease. *Neurobiology of Aging*. 1990; 11: 529–536.
- [224] Stopa EG, Volicer L, Kuo-Leblanc V, Harper D, Lathi D, Tate B, et al. Pathologic evaluation of the human suprachiasmatic nucleus in severe dementia. *Journal of Neuropathology & Experimental Neurology*. 1999; 58: 29–39.
- [225] Harper DG, Stopa EG, Kuo-Leblanc V, McKee AC, Asayama K, Volicer L, et al. Dorsomedial SCN neuronal subpopulations subserve different functions in human dementia. *Brain*. 2008; 131: 1609–1617.
- [226] Wu Y, Swaab DF. Disturbance and strategies for reactivation of the circadian rhythm system in aging and Alzheimer's disease. *Sleep Medicine*. 2007; 8: 623–636.
- [227] Kaas JH, Lyon DC. Pulvinar contributions to the dorsal and ventral streams of visual processing in primates. *Brain Research Reviews*. 2007; 55: 285–296.
- [228] Kuljis RO. Lesions in the pulvinar in patients with Alzheimer's disease. *Journal of Neuropathology & Experimental Neurology*. 1994; 53: 202–211.
- [229] Braak H, Braak E. Neuropathological staging of Alzheimer-related changes. *Acta Neuropathologica*. 1991; 82: 239–259.
- [230] Braak H, Braak E. Evolution of neuronal changes in the course of Alzheimer's disease. In: Jellinger K, Fazekas F, Windisch M, editors. *Ageing and Dementia*. Vienna: Springer; 1998. p. 127–140.
- [231] Dickerson BC, Bakkour A, Salat DH, Feczko E, Pacheco J, Greve DN, et al. The cortical signature of Alzheimer's disease: regionally specific cortical thinning relates to symptom severity in very mild to mild AD dementia and is detectable in asymptomatic amyloid-positive individuals. *Cerebral Cortex*. 2009; 19: 497–510.
- [232] Hof PR, Bouras C, Constandinidis J, Morrison JH. Balit's syndrome in Alzheimer's disease: specific disruption of the occipito-parietal visual pathway. *Brain Research*. 1989; 493: 368–375.
- [233] Hof PR, Morrison JH. Quantitative analysis of a vulnerable subset of pyramidal neurons in Alzheimer's disease. II. Primary and secondary visual cortex. *Journal of Comparative Neurology*. 1990; 301: 55–64.

- [234] Buee L, Hof P, Bouras C, Delacourte A, Perl D, Morrison J, et al. Pathological alterations of the cerebral microvasculature in Alzheimer's disease and related dementing disorders. *Acta Neuropathologica*. 1994; 87: 469–480.
- [235] Wong-Riley M, Antuono P, Ho K, Egan R, Hevner R, Liebl W, et al. Cytochrome oxidase in Alzheimer's disease: biochemical, histochemical, and immunohistochemical analyses of the visual and other systems. *Vision Research*. 1997; 37: 3593–3608.
- [236] Leuba G, Saini K. Pathology of subcortical visual centres in relation to cortical degeneration in Alzheimer's disease. *Neuropathology and Applied Neurobiology*. 1995; 21: 410–422.
- [237] Leuba G, Kraftsik R. Visual cortex in Alzheimer's disease: Occurrence of neuronal death and glial proliferation, and correlation with pathological hallmarks. *Neurobiology of Aging*. 1994; 15: 29–43.
- [238] Cronin-Golomb A, Corkin S, Growdon JH. Visual dysfunction predicts cognitive deficits in Alzheimer's disease. *Optometry & Vision Science*. 1995; 72: 168–176.
- [239] Levine DN, Lee JM, Fisher C. The visual variant of Alzheimer's disease A clinicopathologic case study. *Neurology*. 1993; 43: 305.
- [240] Cohen J, Cronin-Golomb A, Growdon JH, Corkin S. Color vision deficits in Alzheimer's disease. *Society for Neuroscience Abstracts*. 1988; 14: 219.
- [241] Martinelli V, Locatelli T, Comi G, Lia C, Alberoni M, Bressi S, et al. Pattern visual evoked potential mapping in Alzheimer's disease correlations with visuospatial impairment. *Dementia and Geriatric Cognitive disorders*. 1996; 7: 63–68.
- [242] Baloyannis S. Dendritic pathology in Alzheimer's disease. *Journal of the Neurological Sciences*. 2009; 283: 153–157.
- [243] Mavroudis IA, Fotiou DF, Manani MG, Njaou SN, Frangou D, Costa VG, et al. Dendritic pathology and spinal loss in the visual cortex in Alzheimer's disease: a Golgi study in pathology. *International Journal of Neuroscience*. 2011; 121: 347–354.
- [244] Cronin-Golomb A, Corkin S, Rizzo JF, Cohen J, Growdon JH, Banks KS. Visual dysfunction in Alzheimer's disease: relation to normal aging. *Annals of Neurology*. 1991; 29: 41–52.
- [245] Mendez MF, Tomsak RL, Remler B. Disorders of the visual system in Alzheimer's disease. *Journal of Neuro-Ophthalmology*. 1990; 10: 62–69.
- [246] Rizzo M, Nawrot M. Perception of movement and shape in Alzheimer's disease. *Brain*. 1998; 121: 2259–2270.
- [247] Sadun A, Borchert M, DeVita E, Hinton D, Bassi C. Assessment of visual impairment in patients with Alzheimer's disease. *American Journal of Ophthalmology*. 1987; 104: 113–120.

- [248] Murgatroyd C, Prettyman R. An investigation of visual hallucinosis and visual sensory status in dementia. *International Journal of Geriatric Psychiatry*. 2001; 16: 709–713.
- [249] Chapman FM, Dickinson J, McKeith I, Ballard C. Association among visual hallucinations, visual acuity, and specific eye pathologies in Alzheimer's disease: treatment implications. *American Journal of Psychiatry*. 1999; 156: 1983–1985.
- [250] Uhlmann RF, Larson EB, Koepsell TD, Rees TS, Duckert LG. Visual impairment and cognitive dysfunction in Alzheimer's disease. *Journal of General Internal Medicine*. 1991; 6: 126–132.
- [251] Bassi CJ, Solomon K, Young D. Vision in aging and dementia. *Optometry & Vision Science*. 1993; 70: 809–813.
- [252] Wood S, Mortel KF, Hiscock M, Breitmeyer BG, Caroselli JS. Adaptive and maladaptive utilization of color cues by patients with mild to moderate Alzheimer's disease. *Archives of Clinical Neuropsychology*. 1997; 12: 483–489.
- [253] Massoud F, Chertkow H, Whitehead V, Overbury O, Bergman H. Word-reading thresholds in Alzheimer disease and mild memory loss: a pilot study. *Alzheimer Disease & Associated Disorders*. 2002; 16: 31–39.
- [254] Rizzo III JF, Cronin-Golomb A, Growdon JH, Corkin S, Rosen TJ, Sandberg MA, et al. Retinocalcarine function in Alzheimer's disease: a clinical and electrophysiological study. *Archives of Neurology*. 1992; 49: 93–101.
- [255] Shuren J, Heilman KM. Visual field loss in Alzheimer's disease. *Journal of the American Geriatrics Society*. 1993; 41: 1114–1115.
- [256] Whittaker K, Burdon M, Shah P. Visual field loss and Alzheimer's disease. *Eye*. 2002; 16: 206–208.
- [257] Gilmore GC, Levy JA. Spatial contrast sensitivity in Alzheimer's disease: a comparison of two methods. *Optometry & Vision Science*. 1991; 68: 790–794.
- [258] Gilmore GC, Whitehouse PJ. Contrast sensitivity in Alzheimer's disease: a 1-year longitudinal analysis. *Optometry & Vision Science*. 1995; 72: 83–91.
- [259] Crow RW, Levin LB, LaBree L, Rubin R, Feldon SE. Sweep visual evoked potential evaluation of contrast sensitivity in Alzheimer's dementia. *Investigative Ophthalmology & Visual science*. 2003; 44: 875–878.
- [260] Hutton JT, Morris JL, Elias JW, Poston JN. Contrast sensitivity dysfunction in Alzheimer's disease. *Neurology*. 1993; 43: 2328–2328.
- [261] Baker D, Mendez M, Townsend J, Ilsen P, Bright D. Optometric management of patients with Alzheimer's disease. *Journal of the American Optometric Association*. 1997; 68: 483–494.

- [262] Cronin-Golomb A, Gilmore GC, Neargarder S, Morrison SR, Laudate TM. Enhanced stimulus strength improves visual cognition in aging and Alzheimer's disease. *Cortex*. 2007; 43: 952–966.
- [263] Rami L, Serradell M, Bosch B, Villar A, Molinuevo JL. Perception Digital Test (PDT) for the assessment of incipient visual disorder in initial Alzheimer's disease. *Neurologia*. 2007; 22: 342–347.
- [264] Curran S, Wilson S, Musa S, Wattis J. Critical Flicker Fusion Threshold in patients with Alzheimer's disease and vascular dementia. *International Journal of Geriatric Psychiatry*. 2004; 19: 575–581.
- [265] Valdés M, De Flores T. *Psychobiology of stress*. Barcelona: Martínez Roca; 1985.
- [266] Carmel D, Lavie N, Rees G. Conscious awareness of flicker in humans involves frontal and parietal cortex. *Current Biology*. 2006; 16: 907–911.
- [267] Mendola JD, Cronin-Golomb A, Corkin S, Growdon JH. Prevalence of visual deficits in Alzheimer's disease. *Optometry and Vision Science*. 1995; 72: 155–167.
- [268] Curran S, Wattis J. Critical flicker fusion threshold: a potentially useful measure for the early detection of Alzheimer's disease. *Human Psychopharmacology: Clinical and Experimental*. 2000; 15: 103–112.
- [269] Jackson GR, Owsley C, McGwin G. Aging and dark adaptation. *Vision Research*. 1999; 39: 3975–3982.
- [270] Blake R, Wilson H. Binocular vision. *Vision Research*. 2011; 51: 754–770.
- [271] Kiyosawa M, Bosley T, Chawluk J, Jamieson D, Schatz N, Savino P, et al. Alzheimer's disease with prominent visual symptoms. Clinical and metabolic evaluation. *Ophthalmology*. 1989; 96: 1077–1085; discussion 1085–1086.
- [272] Mendez M, Chekrier M, Meadows R. Depth perception in Alzheimer's disease. *Perceptual and Motor Skills*. 1996; 83: 987–995.
- [273] Thiyagesh SN, Farrow TF, Parks RW, Accosta-Mesa H, Young C, Wilkinson ID, et al. The neural basis of visuospatial perception in Alzheimer's disease and healthy elderly comparison subjects: an fMRI study. *Psychiatry Research: Neuroimaging*. 2009; 172: 109–116.
- [274] Vaney DI, Sivyer B, Taylor WR. Direction selectivity in the retina: symmetry and asymmetry in structure and function. *Nature Reviews Neuroscience*. 2012; 13: 194–208.
- [275] Chapman C, Hoag R, Giaschi D. The effect of disrupting the human magnocellular pathway on global motion perception. *Vision Research*. 2004; 44: 2551–2557.
- [276] Skottun B. On the use of visual motion perception to assess magnocellular integrity. *Journal of Integrative Neuroscience*. 2011; 10: 15–32.

- [277] Trick GL, Silverman SE. Visual sensitivity to motion age-related changes and deficits in senile dementia of the Alzheimer type. *Neurology*. 1991; 41: 1437–1437.
- [278] Francis PT, Palmer AM, Snape M, Wilcock GK. The cholinergic hypothesis of Alzheimer's disease: a review of progress. *Journal of Neurology, Neurosurgery & Psychiatry*. 1999; 66: 137–147.
- [279] Tales A, Troscianko T, Lush D, Haworth J, Wilcock G, Butler S. The pupillary light reflex in aging and Alzheimer's disease. *Aging*. 2001; 13: 473–478.
- [280] Fotiou F, Fountoulakis K, Tsolaki M, Goulas A, Palikaras A. Changes in pupil reaction to light in Alzheimer's disease patients: a preliminary report. *International Journal of Psychophysiology*. 2000; 37: 111–120.
- [281] Prettyman R, Bitsios P, Szabadi E. Altered pupillary size and darkness and light reflexes in Alzheimer's disease. *Journal of Neurology, Neurosurgery & Psychiatry*. 1997; 62: 665–668.
- [282] Scinto LF, Daffner KR, Dressler D, Ransil BI, Rentz D, Weintraub S, et al. A potential noninvasive neurobiological test for Alzheimer's disease. *Science*. 1994; 266: 1051–1054.
- [283] Ferrario E, Molaschi M, Villa L, Varetto O, Bogetto C, Nuzzi R. Is videopupillography useful in the diagnosis of Alzheimer's disease? *Neurology*. 1998; 50: 642–644.
- [284] FitzSimon JS, Waring SC, Kokmen E, McLaren JW, Brubaker RF. Response of the pupil to tropicamide is not a reliable test for Alzheimer disease. *Archives of Neurology*. 1997; 54: 155–159.
- [285] Fridh M, Havelius U, Elofsson G, Hindfelt B. The pupillary response to tropicamide in Alzheimer's disease. *Acta Ophthalmologica Scandinavica*. 1996; 74: 276–279.
- [286] Graff-Radford NR, Lin SC, Brazis PW, Bolling JP, Liesegang TJ, Lucas JA, Uitti RJ, O'Brien PC. Tropicamide eyedrops cannot be used for reliable diagnosis of Alzheimer's disease. *Mayo Clinic Proceedings*. 1997; 72: 495–504.
- [287] Growdon JH, Graefe K, Tennis M, Hayden D, Schoenfeld D, Wray SH. Pupil dilation to tropicamide is not specific for Alzheimer disease. *Archives of Neurology*. 1997; 54: 841–844.
- [288] Kálmán J, Kanka A, Maglóczy E, Szóke A, Járdánházy T, Janka Z. Increased mydriatic response to tropicamide is a sign of cholinergic hypersensitivity but not specific to late-onset sporadic type of Alzheimer's dementia. *Biological Psychiatry*. 1997; 41: 909–911.
- [289] Kurz A, Marquard R, Fremke S, Leipert K. Pupil dilation response to tropicamide: a biological test for Alzheimer's disease? *Pharmacopsychiatry*. 1997; 30: 12–15.
- [290] Loupe DN, Newman NJ, Green RC, Lynn MJ, Williams KK, Geis TC, et al. Pupillary response to tropicamide in patients with Alzheimer disease. *Ophthalmology*. 1996; 103: 495–503.

- [291] Treloar A, Assin M, MacDonald A. Pupillary response to topical tropicamide as a marker for Alzheimer's disease. *British Journal of Clinical Pharmacology*. 1996; 41: 256–257.
- [292] Gómez-Tortosa E, Barrio A, Jiménez-Alfaro I. Pupil response to tropicamide in Alzheimer's disease and other neurodegenerative disorders. *Acta Neurologica Scandinavica*. 1996; 94: 104–109.
- [293] Granholm E, Morris S, Galasko D, Shults C, Rogers E, Vukov B. Tropicamide effects on pupil size and pupillary light reflexes in Alzheimer's and Parkinson's disease. *International Journal of Psychophysiology*. 2003; 47: 95–115.
- [294] Grünberger J, Linzmayer L, Walter H, Rainer M, Masching A, Pezawas L, et al. Receptor test (pupillary dilatation after application of 0.01% tropicamide solution) and determination of central nervous activation (Fourier analysis of pupillary oscillations) in patients with Alzheimer's disease. *Neuropsychobiology*. 1999; 40: 40–46.
- [295] Hou R, Samuels E, Raisi M, Langley R, Szabadi E, Bradshaw C. Why patients with Alzheimer's disease may show increased sensitivity to tropicamide eye drops: role of locus coeruleus. *Psychopharmacology*. 2006; 184: 95–106.
- [296] Iijima A, Haida M, Ishikawa N, Ueno A, Minamitani H, Shinohara Y. Re-evaluation of tropicamide in the pupillary response test for Alzheimer's disease. *Neurobiology of Aging*. 2003; 24: 789–796.
- [297] Kaneyuki H, Mitsuno S, Nishida T, Yamada M. Enhanced miotic response to topical dilute pilocarpine in patients with Alzheimer's disease. *Neurology*. 1998; 50: 802–804.
- [298] Reitner A, Baumgartner I, Thuile C, Dilmaghani R, Ergun E, Kaminsky S, et al. The mydriatic effect of tropicamide and its diagnostic use in Alzheimer's disease. *Vision Research*. 1997; 37: 165–168.
- [299] Levin LA, Nilsson SFE, Ver Hoeve J, Wu S, Kaufman PL, Alm A. *Adler's physiology of the eye*. Elsevier Health Sciences; 2011. p. 796.
- [300] Rüb U, Del Tredici K, Schultz C, Büttner-Ennever J, Braak H. The premotor region essential for rapid vertical eye movements shows early involvement in Alzheimer's disease-related cytoskeletal pathology. *Vision research*. 2001; 41: 2149–2156.
- [301] Boxer AL, Garbutt S, Seeley WW, Jafari A, Heuer HW, Mirsky J, et al. Saccade abnormalities in autopsy-confirmed frontotemporal lobar degeneration and Alzheimer disease. *Archives of Neurology*. 2012; 69: 509.
- [302] McCulloch DL, Marmor MF, Brigell MG, Hamilton R, Holder GE, Tzekov R, et al. ISCEV Standard for full-field clinical electroretinography (2015 update). *Documenta Ophthalmologica*. 2015; 130: 1–12.

- [303] Strenn K, Dal-Bianco P, Weghaupt H, Koch G, Vass C, Gottlob I. Pattern electroretinogram and luminance electroretinogram in Alzheimer's disease. *Journal of Neural Transmission Suppl.* 1991; 33: 73–80
- [304] Prager TC, Schweitzer FC, Peacock LW, Garcia CA. The effect of optical defocus on the pattern electroretinogram in normal subjects and patients with Alzheimer's disease. *American Journal of Ophthalmology.* 1993; 116: 363–369.
- [305] Nesher R, Trick GL. The pattern electroretinogram in retinal and optic nerve disease. *Documenta Ophthalmologica.* 1991; 77: 225–235.
- [306] Sartucci F, Borghetti D, Bocci T, Murri L, Orsini P, Porciatti V, et al. Dysfunction of the magnocellular stream in Alzheimer's disease evaluated by pattern electroretinograms and visual evoked potentials. *Brain Research Bulletin.* 2010; 82: 169–176.
- [307] M Moschos M, Markopoulos I, Chatziralli I, Rouvas A, G Papageorgiou S, Ladas I, et al. Structural and functional impairment of the retina and optic nerve in Alzheimer's disease. *Current Alzheimer Research.* 2012; 9: 782–788.
- [308] Simao LM. The contribution of optical coherence tomography in neurodegenerative diseases. *Current Opinion in Ophthalmology.* 2013; 24: 521–527.
- [309] He XF, Liu YT, Peng C, Zhang F, Zhuang S, Zhang JS. Optical coherence tomography assessed retinal nerve fiber layer thickness in patients with Alzheimer's disease: a meta-analysis. *International Journal of Ophthalmology.* 2012; 5: 401–405.
- [310] Lu Y, Li Z, Zhang X, Ming B, Jia J, Wang R, et al. Retinal nerve fiber layer structure abnormalities in early Alzheimer's disease: evidence in optical coherence tomography. *Neuroscience Letters.* 2010; 480: 69–72.
- [311] Chi Y, Wang YH, Yang L. The investigation of retinal nerve fiber loss in Alzheimer's disease. *Chinese Journal of Ophthalmology.* 2010; 46: 134–139.
- [312] Shen Y, Shi Z, Jia R, Zhu Y, Cheng Y, Feng W, et al. The attenuation of retinal nerve fiber layer thickness and cognitive deterioration. *Frontiers in Cellular Neuroscience.* 27 2013; 7: 142.
- [313] Kirbas S, Turkyilmaz K, Anlar O, Tufekci A, Durmus M. Retinal nerve fiber layer thickness in patients with Alzheimer disease. *Journal of Neuro-Ophthalmology.* 2013; 33: 58–61.
- [314] Oktem EO, Derle E, Kibaroglu S, Oktem C, Akkoyun I, Can U. The relationship between the degree of cognitive impairment and retinal nerve fiber layer thickness. *Neurological Sciences.* 2015; 36: 1141–1146.
- [315] Ascaso FJ, Cruz N, Modrego PJ, Lopez-Anton R, Santabàrbara J, Pascual LF, et al. Retinal alterations in mild cognitive impairment and Alzheimer's disease: an optical coherence tomography study. *Journal of Neurology.* 2014; 261: 1522–1530.

- [316] Liu D, Zhang L, Li Z, Zhang X, Wu Y, Yang H, et al. Thinner changes of the retinal nerve fiber layer in patients with mild cognitive impairment and Alzheimer's disease. *BMC Neurology*. 2015; 15: 14.
- [317] Cheung CY, Ong YT, Hilal S, Ikram MK, Low S, Ong YL, et al. Retinal ganglion cell analysis using high-definition optical coherence tomography in patients with mild cognitive impairment and Alzheimer's disease. *Journal of Alzheimer's Disease*. 2015; 45: 45–56.
- [318] Vickers J. The cellular mechanism underlying neuronal degeneration in glaucoma: parallels with Alzheimer's disease. *Australian and New Zealand Journal of Ophthalmology*. 1997; 25: 105–109.
- [319] McKinnon SJ. Glaucoma: ocular Alzheimer's disease. *Frontiers in Bioscience*. 2003; 8: s1140–s1156.
- [320] Guo L, Duggan J, Cordeiro M. Alzheimer's disease and retinal neurodegeneration. *Current Alzheimer Research*. 2010; 7: 3–14.
- [321] Bayer A, Ferrari F, Erb C. High occurrence rate of glaucoma among patients with Alzheimer's disease. *European Neurology*. 2002; 47: 165–168.
- [322] Tamura H, Kawakami H, Kanamoto T, Kato T, Yokoyama T, Sasaki K, et al. High frequency of open-angle glaucoma in Japanese patients with Alzheimer's disease. *Journal of the Neurological Sciences*. 2006; 246: 79–83.
- [323] Lipton SA. Possible role for memantine in protecting retinal ganglion cells from glaucomatous damage. *Survey of Ophthalmology*. 2003; 48: S38–S46.
- [324] Osborne NN. Recent clinical findings with memantine should not mean that the idea of neuroprotection in glaucoma is abandoned. *Acta Ophthalmologica*. 2009; 87: 450–454.
- [325] Bach-Holm D, Kessing SV, Mogensen U, Forman JL, Andersen PK, Kessing LV. Normal tension glaucoma and Alzheimer disease: comorbidity? *Acta Ophthalmologica*. 2012; 90: 683–685.