

Xenogenous bone blocks for maxillary reconstruction- histologic and microtomographic split-mouth clinical trial

Carvalho PHA¹, Trento G¹, Okamoto R², Gonçalves M¹, Pereira-Filho VA¹

¹ São Paulo State University, Dental School at Araraquara, Department of Diagnosis and Surgery

² São Paulo State University, Dental School at Araçatuba, Department of Basic Sciences

Abstract

Background: Atrophic ridges are a challenge in the oral rehabilitation with osseointegrated implants. Autogenous bone graft is the gold standard in ridge augmentation. However, the resorption rates and donor site morbidity limit its use. The deproteinized bovine bone (DPBB) are a viable alternative. DPBB can be particulate or compacted in a block, like the autogenous bone block. There are few clinical studies evaluating the DPBB graft incorporation to the receptor site and its remodeling properties. **Aim/hypothesis:** This study hypothesis is deproteinized bovine bone blocks (DPBB) sintered in low temperatures, present similar characteristics of mineralization and bone neoformation than autogenous graft from mandibular ramus. **Material and methods:** Six patients with edentulous atrophic maxillary ridges were randomized selected in a list of patients whose sought for oral rehabilitation with implants. The inclusion criteria were absence of systemic health issues, age between 20 and 70 years old, with hormonal stability, and consent. Irradiated patients, patients with systemic diseases and post menopause women were excluded. The patients were submitted to reconstruction surgery under general anesthesia. Each side of anterior maxilla received one type of graft, according to randomization process, xenogenous block (test) or Mandibular ramus block graft (control). After 9 months of healing, at implant placement, a biopsy was performed with a 2mm trephine bur, in horizontal direction, Specimens were first processed in 10% formaldehyde for 48h, washed for 24h and stored in 70% alcohol, after they were processed in a digital microCT scan, and then submitted to paraffin inclusion and histomorphometry analysis. **Results:** The analyzed parameters were tissue volume, bone volume, bone volume percent, tissue surface, bone surface, bone density and porosity, soft tissue and mineralized tissue. The trabecular number, thickness and separation were also evaluated. All the evaluated parameters respect the normal distribution (Shapiro-Wilk; $p = 0.060 - 0.975$) and homoscedastic (Levene; $p = 0.250 - 0.972$). There was statistical difference between groups only for the trabecular thickness. Autogenous bone graft presented larger trabeculae (0.45mm) than DPBB (0.29mm) ($p < 0.05$). **Conclusions and Clinical Implications:** Results suggest that the DPBB block tested presented similar micro structural and bone formation characteristics to the autologous bone graft from mandibular ramus, furthermore, Deproteinized Bovine Block grafts could be a suitable clinical alternative to autologous bone when this is contraindicated, for example in compromised health patients or in cases with no sufficient autologous bone donation site.

Results

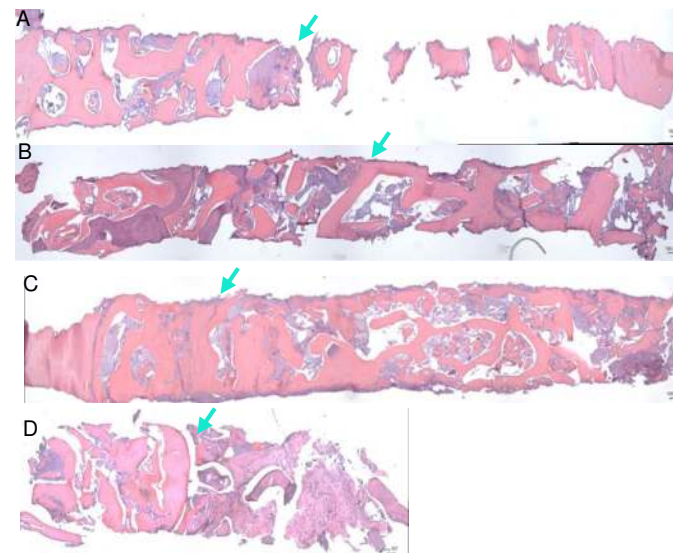


Figure 3. Histomicrographs of entire biopsies removed from (A and C) Autogenous graft from mandibular ramus and (B and D) Bovine deproteinized bone block (green arrows indicate the interface between host bone and graft). Hematoxylin-eosin stain (100µm)

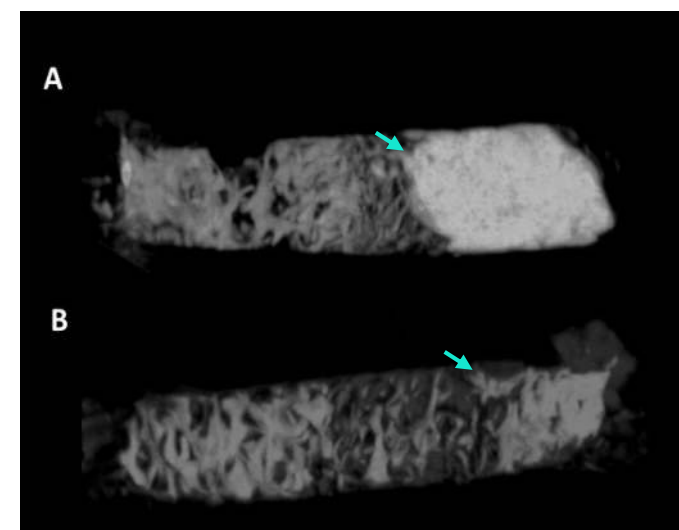


Figure 4. Microtomographs of entire biopsies removed from (A) Autogenous graft from mandibular ramus and (B) Bovine deproteinized bone block (green arrows indicate the interface between host bone and graft).

Table 1. Distribution of evaluated parameters on microtomographic analysis. Mean (SD) for Autogenous bone and Deproteinized bovine bone block grafts (DPBB)

	Autogenous (6)	DPBB (6)
Sample vol.	23,01 (8,29)	32,94 (6,57)
Bone vol.	8,66 (4,44)	9,15 (3,36)
Bone vol. (%)	37,84 (10,93)	28,43 (9,84)
Bone surface vol.	11,45 (2,06)	13,28 (2,43)
Bone surface	96,15 (40,74)	116,9 (39,54)
Tissue surface	51,94 (15,47)	67,17 (10,33)
Trabecular number	0,87 (0,33)	0,95 (0,29)
Trabecular separation	0,39 (0,12)	0,49 (0,17)
Trabecular thickness	0,46 (0,15)*	0,29 (0,04)*
Bone density	4,20 (1,04)	3,59 (0,98)
Porosity	62,16 (10,93)	71,56 (9,84)

Background and Aim

Early teeth loss;
Atrophic ridges;
Implant rehabilitation;
Autogenous bone as gold standard;
Alternatives to autogenous bone grafting

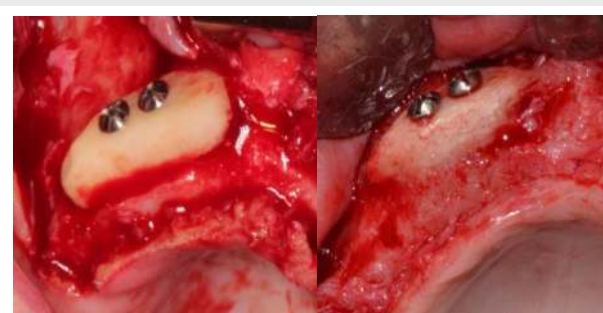

Figure 1. Volume comparison between initial (A) and after 9 months (B) for autogenous bone graft.

AIM

To evaluate the mineralization and new bone formation of a bovine deproteinized bone block in comparison to autogenous graft from mandibular ramus.

Conclusion

DPBB block tested presented similar micro structural and bone formation characteristics to the autologous bone graft from mandibular ramus.

Methods and Materials

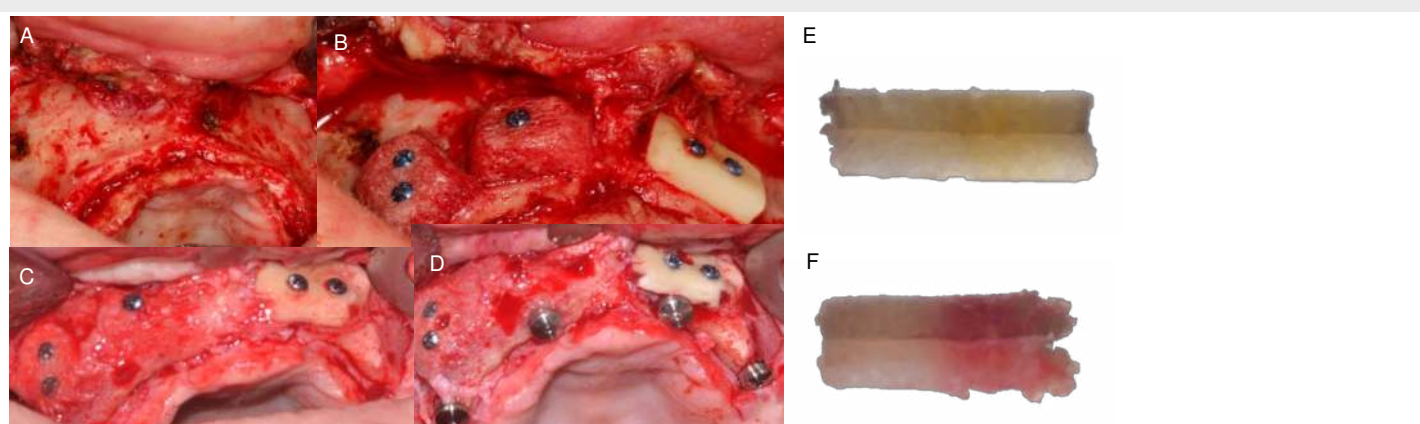


Figure 2. Study design. (A) Patient selection with total edentulism and maxillary resorption with at least 10mm of ridge height and 2mm of thickness. (B) Split mouth graft placement. (C) Reopening of grafts after 9 months, biopsy and (D) implant placement. (E and F) core biopsies of autogenous and bovine bone blocks for microCT and Histology.

References

- Sakkas A, Wilde F, Heufelder M, Winter K, Schramm A. Autogenous bone grafts in oral implantology—is it still a “gold standard”? A consecutive review of 279 patients with 456 clinical procedures. *Int J Implant Dent. International Journal of Implant Dentistry*; 2017;3(1).
- Nkenke E, Neukam FW. Autogenous bone harvesting and grafting in advanced jaw resorption: morbidity, resorption and implant survival. *Eur J Oral Implantol* [Internet]. 2014;7 Suppl 2:S203-17. Available from: <http://www.ncbi.nlm.nih.gov/pubmed/24977256>
- Hämmerle CHF, Jung RE, Yaman D, Lang NP. Ridge augmentation by applying bioresorbable membranes and deproteinized bovine bone mineral: A report of twelve consecutive cases. *Clin Oral Implants Res.* 2008;19(1):19–25.
- Benic GI, Thoma DS, Jung RE, Sanz-Martin I, Unger S, Cantalapiedra A, et al. Guided bone regeneration with particulate vs. block xenogenic bone substitutes: a pilot cone beam computed tomographic investigation. *Clin Oral Implants Res.* 2017;28(11):e262–70.
- Schwarz F, Ferrari D, Balic E, Buser D, Becker J, Sager M. Lateral ridge augmentation using equine- and bovine-derived cancellous bone blocks: A feasibility study in dogs. *Clin Oral Implants Res.* 2010;21(9):904–12.
- Felice P, Pistilli R, Lizio G, Pellegrino G, Nisii A, Marchetti C. Inlay versus onlay iliac bone grafting in atrophic posterior mandible: A prospective controlled clinical trial for the comparison of two techniques. *Clin Implant Dent Relat Res.* 2009;11(SUPPL 1):69–82.
- Elnayef B, Porta C, del Amo F, Mordini L, Gargallo-Albiol J, Hernández-Alfaro F. The Fate of Lateral Ridge Augmentation: A Systematic Review and Meta-Analysis. *Int J Oral Maxillofac Implants.* 2018;33(3):622–35.
- Spin-Neto R, Stavropoulos A, Coletti FL, Faeda RS, Pereira LAVD, Marcantonio E. Graft incorporation and implant osseointegration following the use of autologous and fresh-frozen allogeneic block bone grafts for lateral ridge augmentation. *Clin Oral Implants Res.* 2014;25(2):226–33.