

---

# Sudden Sensorineural Hearing Loss

---

Harun Acıpayam, Hasan Emre Koçak and  
Mustafa Suphi Elbistanlı

Additional information is available at the end of the chapter

<http://dx.doi.org/10.5772/intechopen.72219>

---

## Abstract

Sudden hearing loss (SHL) is a common disease in the daily practice of ear-nose-throat (ENT) and audiology clinics. It is usually defined as a sensorineural type hearing loss of 30 dB or greater in three contiguous frequencies. Although several factors were suggested for the etiology of SHL, in most of the cases, no cause could be detected and they were diagnosed as idiopathic cases. Although certain specific treatments might be applied in patients with known etiology, corticosteroids are the main component in the treatment of idiopathic SHL. Many experts and centers have developed different treatment protocols with similar approaches. SHL is considered as an emergency in ENT, as it may cause a permanent loss in hair cells, if it is not treated or the treatment is not initiated at the right time. For patients, who did not or partially benefit from the initial treatment, different salvage treatment protocols had been developed. As SHL severely affects the patient's quality of life, its diagnosis and treatment should be thoroughly deliberated.

**Keywords:** idiopathic hearing loss, salvage treatment, sudden deafness, sudden hearing loss, treatment

---

## 1. Definition

Sudden hearing loss (SHL) is an ear-nose-throat (ENT) emergency and as sensorineural hearing loss of 30 dB or greater in three contiguous audiometric frequencies occurring over 72 h. SHL was first described by Dekleyn in [1] (**Figure 1A**). Although the definition mentioned above involves the widely accepted diagnostic criteria of SHL, it actually develops within hours or minutes and is usually noticed by the patient early in the morning or during a telephone conversation. With an approach from a broader perspective, we may consider all identifiable and measurable hearing losses, which are noticed within minutes or within few days, as SHL. Patients usually visit an ENT specialist in a great panic, thinking they became deaf.

---

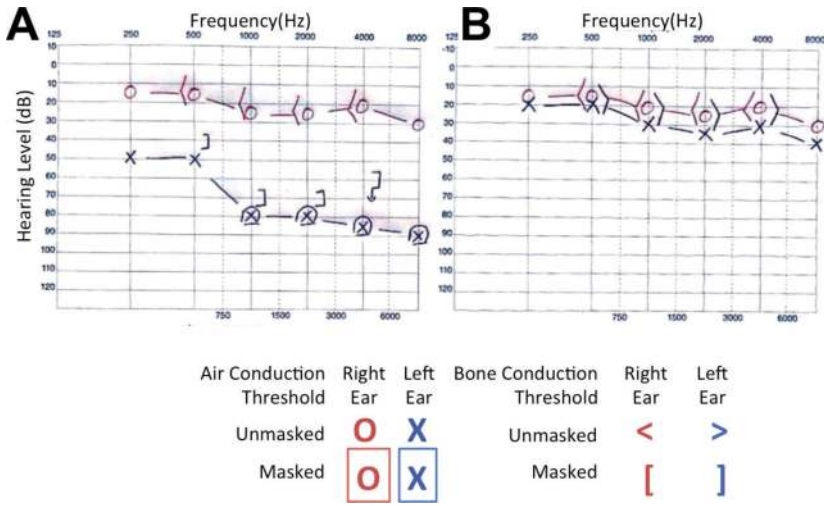


Figure 1. A: Sudden hearing loss sample audiogram. B: After treatment normal hearing level.

The physician, first of all, should calm the patient and then examine his/her medical condition, proceed immediately with the diagnostic procedures, identify—if possible—the etiology and initiate without delay the proper treatment.

## 2. Epidemiology

Although SHL constitutes approx. 1% of all sensorineural hearing losses, its incidence changes between 5 and 20/100,000 in different sources [2]. However, high rates such as 160/100,000 had also been reported in the literature and 40,000 new cases were diagnosed every year in the USA [3]. The incidence and prevalence of SHL are probably slightly higher than the calculated values, because of the rapid development of SHL and the high rate of spontaneous regression. Many studies reported that SHL had no correlation with gender and that the female/male ratio was equal or insignificantly different. In this regard, it seems safe to say that gender is not a risk factor. Similarly, no significant left/right ear distinction was detected. Although SHL is usually unilateral, bilateral involvement is emerging in a small percentage of patients (1–2%) [4]. Nevertheless, bilateral SHL is a more serious condition compared to the unilateral form and is often related to systemic disorders and has a relatively worse prognosis [5, 6].

## 3. Physiopathology

Among the mechanisms causing SHL, in particular, intracochlear hypoxia and/or inflammation in the inner ear play a major role. Several causes, which were suggested regarding the

pathogenesis of SHL, can be classified into four main groups. Vascular factors, viral infections, autoimmune processes, and intracochlear membrane rupture.

### 3.1. Vascular factors

As it is well known, the cochlea is an end-organ perfused by the labyrinthine artery, which is a branch of the basilar artery and does not have collateral circulation [7]. The labyrinthine artery divides into two branches (vestibular and cochlear arteries) after entering through the internal acoustic meatus. The cochlear artery enters the cochlea after the division of its branch the vestibulocochlear artery [8]. Therefore, factors such as thrombi, emboli, atherosclerosis, vasospasm, and decreased blood flow may end up with vascular insufficiency and consequently a loss of function in the cochlea. A sudden interruption of the blood flow to the cochlea may induce the development of SHL, which will cause a complete restriction of the oxygen supply.

The obstructions in the vertebrobasilar system may also cause SHL. Here, it should be noticed that a bilateral SHL emerges, in these cases, as the basilar artery, which is the only artery supplying that region. Kim et al. [9] detected a thrombus in the bilateral distal vertebral artery in a patient with bilateral SHL and observed improvement after the restoration of the circulation with a stent. In his experimental study, Perlman [10] stated that the occlusion of the internal auditory artery caused changes in the cochlea secondary to the ischemia and some of these changes were irreversible. The difference of this study from SHL patients is that the findings in SHL are reversible. In a recent study similar to these studies, Chung [11] found out a relation between increased arterial stiffness and SHL development and the response to the treatment and drew attention to the development of SHL with vascular causes. Subclinical atherosclerosis has also been reported in the literature, as a cause of SHL [12].

It is understandable that the temporary and permanent problems in the cochlear microcirculation may cause SHL depending on the damage in the cochlear hair cells [13]. Also, in cases of hypercoagulopathy, a possible intravascular obstruction may cause damage to the inner ear in the same way. Bernhard [14] investigated the effects of experimental hyperfibrinogenemia on the development of SHL and stated that although they did not respond to corticosteroids, intravenous defibrinogenation (ancrod) improved the process markedly. He suggested that defibrinogenation therapy should be considered in non-responding SHL patients. Similarly, the relation of SHL to the factors capable of intravenous obstruction such as sickle cell anemia, Waldenström's macroglobulinemia or contraceptive drugs have been reported in the literature [15]. Although, some studies have suggested that there is a relationship between Factor V Leiden mutation and SHL, it was shown with a meta-analysis that there is no clear relationship between these two pathologies [16]. It is clear that these diseases will not respond to corticosteroids and the main treatment should be targeted to the underlying cause. Cochlear damage may emerge due to the acute emboli after the cardiopulmonary bypass or non-otological, non-coronary operations and may result consequently in SHL [17]. Any obstruction due to any reason in the cochlear microcirculation will manifest itself with the symptoms corresponding to the level of the obstructed artery. For example, although hearing loss is the only finding in the presence of the cochlear artery obstructions, vestibular symptoms like vertigo and tinnitus will also emerge in the labyrinthine artery obstructions along with hearing loss.

Cappacio [18] suggested that dyslipidemia may be associated with SHL pathogenesis and that impaired serum lipid profile might be an important factor in the development of SHL. There are also other studies in the literature linking serum lipid levels with SHL [19]. However, Chang [20] reported in his meta-analysis that serum lipid profile did not have any correlation with the SHL development and its prognosis.

### 3.2. Viral infections

Viral infections are the most common factor worldwide in the etiology of SHL in the world [21]. In 1954, Lindsay and Hemenway [22] detected degeneration in the tectorial membrane, corti organ, and stria vascularis during their cochlear histopathological examination and determined findings of measles virus in the cochlea in the same study. Shortly thereafter, Lindsay [23] found that the mumps virus could also do similar damage to the inner ear. So, the relationship between hearing loss and viral infections is well known. In a meta-analysis, it has been reported that 40% of the congenital hearing loss is associated with viruses and the most common responsible agent is cytomegalovirus (CMV) along with some other viral in utero infections [24]. Similarly, Van Dishoeck [25] suggested that there might be a link between upper airway infections and SHL and those upper airway viruses, which might penetrate the inner ear through neighborhood or blood circulation, might cause an immune response and an eventual damage in the inner ear. Especially, the herpes family of viruses, influenza, and enteroviruses are frequently blamed viral agents in the SHL etiology [26]. In a study conducted by Wilson [27], he found out that viral serology titration in SHL patients was two times higher than in the control group. It is believed that the penetration of the virus itself or the viral antigens to the membranous labyrinth cause an immune response and the resulting inflammation the formation of SHL. As the emerged cochleitis causes hearing loss, it is believed that the presence of vertigo, which is considered as a sign of bad prognosis for SHL, depends on the labyrinthitis emerging concomitantly.

In addition to the viral infections, bacteria can also cause the formation of SHL. In the USA, the two most common bacterial diseases causing SHL are Lyme disease and syphilis [28]. Lyme disease is caused by *Borrelia burgdorferi* and in long-term it may involve neurologic structures, especially the seventh nerve, which may cause facial paralysis. It may also cause hearing loss due to the involvement of the eighth nerve [28]. Although some studies showed that the incidence of Lyme disease is relatively high in SHL (up to 20%), some other reported very low rates [29, 30]. Syphilis is a systemic infection caused by *Treponema pallidum* and may present diverse clinical manifestations. Especially at the stage of neurosyphilis, if the neuritis of eighth nerve and cochleitis are added to the picture, it is called as otosyphilis. Otosyphilis may be encountered in different forms such as SHL, progressive hearing loss, fluctuating hearing loss or Meniere's syndrome [31].

In fact, viral infection hypothesis depends on three possible mechanisms considering its relation to the hearing loss [32]. The first of them, as mentioned above, is that the virus itself or its antigens, which may induce an immune response, penetrate the inner ear, and may cause cochleitis and neuritis in the cochlear nerve. The path may be hematogenous, but it may also spread directly through the neighborhood. The cerebrospinal fluid may be also a vehicle for

the spread of the virus. The second hypothesis is that the latent virus infection in the inner ear may reactivate due to several reasons and cause SHL. Especially, it is a fact that *Varicella zoster* and other neurotropic viruses may cause latent virus infections, which strengthens this hypothesis. The next hypothesis is more complicated than the first two hypotheses and is indirectly related to viruses as well. As follows: the antibodies found in the systemic circulation and secreted against the viral antigens outside the inner ear may cause the development of a cross-reaction against the structural antigens in the inner ear, which may damage the inner ear and consequently cause hearing loss. In one respect, this last theory is an example of the relation between SHL and autoimmunity.

These findings, clinical, and histopathological studies eventually give the impression that viral etiology is one of the main etiologies in SHL. Nevertheless, it is also believed that the corticosteroids, which constitute the main therapeutic approach to SHL, have an anti-inflammatory effect in the inner ear, cures the emerged cochleitis, and enable healing through these mechanisms.

### 3.3. Autoimmunity

Autoimmunity theory is based on the main principle of the cross-reaction of the circulating antibodies or activated-cytotoxic T cells with the inner ear antigens [33]. The antibodies in the systemic circulation may be formed not only against a virus or bacterium, but also against several allergens. Eventually, these antibodies may become sensitive to the target antigens in the inner ear such as Type 2 collagen, tectorin, and beta-actin. The best documented among these antigens is the choline transporters like protein 2 (CTL-2) an inner ear glycoprotein [34–38]. In a study, antibodies formed against CLK-2 were detected in the systemic circulation in 9 of 20 patients [39]. In an experimental study on mice with Cogan syndrome, it was shown that the antibodies, which were formed against some supportive cells called CD148 and against connexin 26 (a well-known gap-junction protein), caused hearing loss [40].

In some SHL patients, antibodies against some cochlear proteins (p30, p80) and against some antigens such as Type 2 collagen and cardiolipin in the membranous labyrinth [41–43]. In some studies, it was also found out that the levels of some T-lymphocyte substances like C3b were increased in SHL [44]. Anti-endothelial antibodies (AECA) present another example. These antibodies are a group of heterogeneous autoantibodies that develop against endothelial cells and cause damage to the vessel walls. These antibodies may cause inflammation in the vascular endothelial cells in many different regions of the body via the immune system. They were also associated with many connective tissue disorders and systemic vasculitis; therewith, they got specific terminological naming [45]. The relationship between AECA and SHL was demonstrated with several studies [46, 47]. Harris reported that the relationship between circulating antibodies and bilateral, progressive, and fluctuating SHL was sufficiently evident [48]. In this study, although he detected antibodies against an antigen, which he thought was specific to the inner ear. He concluded that his further analyses revealed that this antigen was heat-shock protein 70 (Hsp-70) and that it existed not only in the inner ear, but also in different regions of the body. The relationship between the anti-Hsp70 antibodies and SHL were tried to be confirmed by further studies [49, 50].

It has also been reported in the literature that there is a relation between systemic lupus erythematosus (SLE) and SHL. It was reported that circulating autoantibodies might enter into the reaction directly with the inner ear antigens in SLE patients and the activated T cells might increase the levels of intracellular interferon gamma and some other cytokines and thus cause cellular damage [51]. Additionally, it is well known that in SLE, circulation antibodies such as anticardiolipin antibody, lupus anticoagulant, and anti- $\beta$ 2 GP1, antiphospholipid antibodies cause emboli and microinfarcts in the systemic circulation. As these antibodies may cause the same problems in the cochlear microcirculation, they may also cause SHL with the mechanism explained in the vascular hypothesis of SHL. Meanwhile, it was also stated in the literature that the SHL, which is believed to be developed due to SLE, might improve with a proper anticoagulant treatment [52, 53].

Hearing losses, which are believed that they develop in relationship with autoimmunity and manifest themselves with progressive, recurrent, and fluctuating clinical picture, are also called autoimmune hearing loss or autoimmune inner ear disease [54]. Yoo [41] created hearing loss in rats with Type 2 collagen immunization and showed the monoclonal antibodies, which were formed against the antigen related to the otic capsule, with radioimmunoassay. Harris [55] identified five antibodies formed against the inner ear antigens and suggested that the inner ear might have its own immunoreactive mechanism apart from the systemic immune response, but this was not supported by studies conducted after this hypothesis was introduced. Lymphocyte transformation and Western-blot tests are recommended for the diagnosis of the autoimmune hearing loss. Heywood [56] used infliximab in the treatment of fluctuating and progressive high-frequency recurrent hearing loss and reported that the patients benefited from this anti-TNF-alpha agent. Although all these findings might show the place of the autoimmunity in the etiology of SHL, there is still a need for further studies with larger samples size, as the sample sizes in the available studies are relatively small.

### **3.4. Intracochlear membrane rupture**

Round- and oval-window membranes are two anatomical structures that separate the inner and middle ear from each other. These structures are responsible for restricting the endolymph to the inner ear and for preventing its penetration to the middle ear. There are other additional membranes in the inner ear that prevent the endolymph from interfering with the perilymph, and it is well known that their rupture will cause hearing loss. Goodhill [57] detected a perilymph fistula in three patients with SHL. Simmons [58] was one of the earliest authors, who suggested that the labyrinthine membrane damages might play a role in the etiology of SHL. Gussen [59] has identified healed Reissner membrane in the temporal bone dissections and succeeded to reveal membrane ruptures in the SHL etiology. Similarly, Kamerer [60] demonstrated microfissures between the posterior canal ampulla and the round-window niche during his temporal bone studies. Although there are other studies with small patient sizes, the main question is whether the hearing losses depending on membrane ruptures should be classified as SHL. Because, in that case, we have to assume that SHL arises from a mechanical problem and the treatment procedure should be based mainly on surgical

or conservative procedures. But, the main thing that should be known about these patients is that they will not respond to standard SHL treatment protocols. However, if we look at the classic definition of SHL, they also conform to the SHL definition.

#### 4. Histopathology

The histopathology of SHL is quite diverse because of the several factors blamed regarding its etiology. In the temporal bone studies, as mentioned above, along with the membrane ruptures, degenerative findings such as atrophy in the corti organ, loss of cochlear neurons, and neuron fibrils might be encountered in the viral etiology. On the other hand, histopathological findings such as labyrinthine fibrosis and new bone formation are the predominant histopathological findings in vascular events. Yood [61] observed certain changes in 7 of 11 temporal bones in his histopathological study. These changes include especially damage to the corti organ or loss of total corti organ; even it may differ according to the etiology. On the other hand, Vasama [62] determined in his study on 12 temporal bones degeneration and loss in the spiral ligament and stria vascularis. He also observed cochlear ossification in one patient. Since SHL's etiology is multifactorial, multiple histopathological findings are expected and it can be suggested that majority of these findings might be reversible regarding the spontaneous healing rates of SHL.

#### 5. Etiology

Although an etiological factor could be determined only in a small number of SHL patients, a wide spectrum of etiologic factors and diseases were blamed. Among these, infectious cause being in the first place, vascular causes, endothelial dysfunctions, hyperlipidemia, hypercoagulopathy, increased oxidative stress, autoimmunity, trauma, neurological disorders, endocrinopathies, iron deficiency anemia, neoplastic causes, paraneoplastic causes, and toxic causes are the most important factors. The most blamed causes in the SHL etiology are shown in **Table 1**. But it should be emphasized that none of these factors has been confirmed as a cause of SHL and idiosyncrasy is still the most common category in SHL (**Table 1**).

---

Vascular Causes	Trauma
Hypercoagulopathy	Perilymph fistula
Vertebrobasilar Insufficiency	Round window rupture
Thrombo-embolism	Rupture of the oval window
Sickle Cell Anemia	Intralabyrinthine hemorrhage
Moyamoya disease	Temporal bone fractures
Polycythemia vera	Previous otological surgeries

Atherosclerotic disorders	Previous cardiopulmonary surgeries
Arteriovenous malformations	Acoustic trauma
Aneurysm	
Erythrocyte Deformities	
<b>Infection</b>	<b>Neoplastic Causes</b>
Viral Causes	Acoustic Schwannoma
Herpes viridea family (HSV Type 1, 2; VZV, CMV, EBV)	Multiple Myeloma
Mumps	Metastatic tumors
Rubella	Meningeal carcinomatosis
Rubeola	
HIV	<b>Endocrine Causes</b>
Influenza family	Hypothyroidism
Enteroviridea family	Iron deficiency anemia
Adenovirus	Diabetes mellitus
Human Spumaretrovirus	<b>Toxic Causes</b>
Bacteria-Parasite	Aminoglycosides
<i>Treponema pallidum</i>	Gold
<i>Borrelia burgdorferi</i>	Quinine
<i>Toxoplasma gondii</i>	Iron-containing drugs
<i>Mycoplasma</i> spp.	ACE inhibitors
<i>Cryptococcus</i> spp.	Loop Diuretics
<i>Meningococci</i>	Cisplatin
<i>Enterobacteriae</i>	Aspirin
<b>Autoimmune Causes</b>	Chemotherapeutic agents
Autoimmune inner ear disease	Phosphodiesterase Type-5 inhibitors
Crohn's Disease	Heroin
Ulcerative Colitis	Narcotic analgesics
SLE	Benzodiazepines
Small vessel vasculitis	<b>Neurological Causes</b>
Cogan syndrome	Multiple Sclerosis
Antiphospholipid Antibody Syndrome	<b>Psychiatric Causes</b>
Sarcoidosis	Histrionic (somatoform) deafness
Endolymphatic hydrops	<b>Idiosyncrasy</b> (most common cause)

---

**Table 1.** Etiology of sudden hearing loss.



## 6. Medical history and physical examination

Medical history is typical in SHL. Patients usually notice in the morning, during a telephone conversation, after exiting a noisy environment that their hearing sense is suddenly disappeared and generally they visit panicked the nearest physician with a fear of being deaf. In sudden hearing loss, as patients consult immediately a physician, early diagnosis and treatment are possible. During the physical examination, as no SHL-specific finding can be detected during the bilateral otomicroscopic examination, otoscopic examination is usually normal. In some cases, there can be an obstructive ear plug, which may be removed with difficulty. At the same time, in patients with otological disorders like chronic otitis media and tympanic membrane retraction, previous audiometry reports might be needed for the diagnosis and especially in patients with presbycusis and missing audiometry reports, diagnosing is relatively difficult. In such cases, we have to depend only on the anamnesis. In the anamnesis, the important points are the presence of tinnitus and ringing, the presence of concomitant vertigo, and presence of a similar event in the past. Questioning of these aspects will provide useful information regarding the differential diagnosis. The patients should also be evaluated for the known chronic diseases and used medication. Especially autoimmune disorders, coagulation disorders, cardiovascular diseases, previous infectious diseases, and trauma should be questioned. Following the physical examination, hearing examination (Weber, Rinne) should be carried out in order to evaluate the type and severity of the hearing loss. Afterwards, the diagnosis should be confirmed with pure-tone audiometry.

## 7. Diagnosis

### 7.1. Audiology

The audiological examination is the most important process regarding the diagnosis. Pure-tone audiometry may enable a definitive diagnosis and also provide information about the severity of the hearing loss and the type of the audiological curve with additional data related to both differential diagnosis and prognosis. In addition to the pure-tone audiometry, tympanometric examination, acoustic reflex, speech audiometry may support the diagnosis. Such additional tests are not always needed. They are only recommended if there is a clinical necessity. In patients who cannot comply with the audiometry process ABR might be useful for the diagnosis. A definitive diagnosis of SHL can be made, if a hearing loss of 30 dB or greater is observed in three contiguous frequencies.

### 7.2. Laboratory analysis

As several different causes were suggested in respect of SHL etiology, the necessity of routine laboratory examination is still disputable regarding the diagnosis. The general consensus is that laboratory examination should be carried out only for the suspected etiological factors. If a viral involvement is suspected, viral antigen titration; if an autoimmune mechanism is

suspected, levels of the relevant auto-antibodies; thyroid function tests, homocysteine, PT, APTT, INR or markers like specific factor levels, Elisa for HIV, HCV viruses, fasting blood sugar level, HbA1C, lipid profile, VDRL, RPR for syphilis, Lyme titration, serum iron levels can be checked. The control of all these parameters in each patient is not reasonable and also not always possible so that it is much more appropriate to make these analyses only in suspected etiological cases.

### 7.3. Radiology

In SHL, unlike the laboratory examinations, a radiological examination should be definitely performed considering the differential diagnosis. Approximately in 1% of patients diagnosed with SHL, a tumor was identified in the cerebellopontine angle. Therefore, a contrast-enhanced, thin-sectioned temporal MRI must be carried out regarding the differential diagnosis and to determine the etiological factor. In MRI examination, we may observe a space-occupying mass lesion and also in SHL cases with vascular pattern, we may also observe hyperintensity in the pre-contrast examinations depending on the methemoglobin accumulated in the inner ear. In the presence of inflammation, hyperintensity might be observed in the 3D-flair sequence depending on the accumulation of the proteinous materials in the dense exudation [63]. Regarding the literature, the rate of the patients with MRI findings related to SHL was between 27 and 53% [64, 65]. In addition, MRI may also enable the identification of AICA aneurysms and vertebrobasilar system anomalies.

## 8. Treatment

As the etiological factor is mostly not identifiable in SHL, its treatment is arranged in certain protocols. Several therapeutic modalities clinically different but similar in respect of main aspects have been developed. Systemic corticosteroids are beyond dispute the main therapeutic agents and they are also considered as the golden standard in the literature. Moreover, multiple medical agents can be used in the treatment. In patients, who did not respond or partially respond to the primary treatment, salvage treatment should be implemented. Although these treatments may change according to the patient and physician's algorithm, it should be initiated with the primary treatment. In SHL cases with identified etiology, treatment should be targeted to the underlying disorder. Hereinafter, the treatment protocols especially for the idiopathic SHL will be discussed.

### 8.1. Medical treatment

#### 8.1.1. Systemic corticosteroids

They are currently the main therapeutic agents (**Figure 1B**). They should be included in the treatment protocols of SHL cases with unknown etiology. Although the mechanism of action of the corticosteroids considering the SHL pathogenesis is not fully elucidated, it is believed that they decrease the inflammation in the inner ear and accelerate the regeneration. An early initiation

of the systemic corticosteroid therapy enables a relatively better respond to the treatment [66]. Wilson [66], in his randomized double-blind placebo-controlled study, showed clearly the positive effect of the corticosteroids on the SHL. The following numerous studies confirmed these findings. Although there are few studies in the literature reporting that corticosteroids are ineffective, we observed in our clinical practice, that they are highly effective and included them in our routine treatment protocol. Systemic corticosteroid therapy is a short-term treatment, which is initiated with a dose of 1 mg/kg and continued with a gradual dose reduction. This treatment with gradually declining dosage enables that the suppressed adrenal glands have enough time to produce steroids again. The SHL treatment guideline, which was published by the American Otolaryngology Academia in 2012, indicated the corticosteroids as the first-line therapy. It was stated that a dose of 1 mg/kg for approx. 10–14 days is sufficient for the treatment of SHL [67]. Systemic corticosteroids have diverse side effects. The most common side effects are acne, blurred vision, cataract or glaucoma, sleeping problems, hypertension, increased appetite, hypertrichosis, insomnia, immunosuppression, muscle weakness, irritability, uneasiness, osteoporosis, increase of insulin need in diabetic patients, diffuse edema due to the water and salt retention in kidneys, aseptic necrosis in the femur head. Steroids should be used carefully particularly in patients with comorbidity and in the pregnant and the risk-benefit of the therapy should be thoroughly evaluated. If in these patients corticosteroid use is risky, intratympanic corticosteroid injection should be considered in the primary treatment [68, 69].

#### *8.1.2. Antiviral agents*

Antiviral agents were added to the treatment protocols in many clinics in respect of the findings related to the role of viruses in the etiology of SHL. Even though the responsible virus mostly cannot be isolated, they are used in combination with corticosteroids. Stookross created labyrinthitis with HSV-1 antigens in an experimental animal study and applied corticosteroids as monotherapy or in combination with acyclovir. He observed that the viral replication was suppressed in the 14th day of the treatment and discontinued the application. He concluded that acyclovir and corticosteroid combination provided better recovery compared to the corticosteroid monotherapy [70]. Park [71] conducted a study with 85 patients and administered a combination of steroid + antiviral + anticoagulant + stellar ganglion blockage to one group and corticosteroid monotherapy to another group. He observed better recovery in the combination group. In contrary, Westerlaken [72] conducted a placebo-controlled randomized study with 91 patients and administered acyclovir + corticosteroid combination in one group and corticosteroid alone in the other group. He concluded that antiviral agents did not provide additional benefit. Similarly, Tucci [73] concluded in his study conducted with 105 patients that the addition of valacyclovir to the corticosteroid therapy did not provide additional benefit and that antiviral treatment is ineffective in SHL. Antiviral agents like valacyclovir and famciclovir might be used instead acyclovir.

#### *8.1.3. Vasodilators and plasma expanders*

The goal of this treatment is to increase the blood perfusion in the inner ear and the oxygenation. In order to obtain this, either the arteries in the inner ear should be dilated or the viscosity

of the blood should be decreased in order to increase its fluidity. Papaverine, histamine, and carbogen (mixture of 5% CO<sub>2</sub> and 95% O<sub>2</sub>) were used for this purpose in the literature. In particular, agents such as histamine and papaverine have found effective as they reduced systemic vascular pressure [74]. Compared to these agents, carbogen treatment is more effective and provides a safer treatment option, which means that the oxygenation of the perilymph changes depending on the blood concentration of O<sub>2</sub> and CO<sub>2</sub> and systemic vascular resistance. Especially, the partial CO<sub>2</sub> level in the peripheral blood is an important stimulator of the perilymphatic oxygenation. Kallinen demonstrated that carbogen treatment increased the perilymphatic oxygenation more than 100% O<sub>2</sub> [75]. There are plenty of studies conducted with piracetam, prostaglandin E1, dextran (plasma expander) and various rheological agents. These agents are not used alone in the idiopathic SHL but added to the systemic corticosteroid therapy protocol as adjuvant agents [76].

#### 8.1.4. Diuretics

If endolymphatic hydrops is responsible for SHL, diuretics may be used in the treatment. Besides this, they are not included in the standard treatment protocols.

#### 8.1.5. Magnesium

Nageris [77] showed that corticosteroid and magnesium combination is more effective in SHL compared to the corticosteroid and placebo combination. Similarly, Gordin [78] determined also that magnesium treatment had positive effects on the recovery in SHL via antioxidant effects and recommended the addition of magnesium to the treatment regimes as an antioxidant.

#### 8.1.6. Low-density lipoprotein apheresis

Low-density lipoproteins may cause the development of SHL, if their elevated concentrations increase the plasma viscosity. In a study with a large sample size, it was reported that the treatment with low-density lipoprotein apheresis and fibrinogen increased the recovery rate in SHL although the result was not statistically significant [79].

#### 8.1.7. Ozone therapy

Ragab [92] conducted a study with 45 patients and reinjected the 100 ml blood, which he had taken from the patients and exposed to a 1:1 gas mixture of oxygen and ozone. After the implementation of this treatment protocol for a total of 10 sessions twice a week, he compared the ozone group with the placebo group. He concluded that a significant recovery was observed in the ozone group.

## 8.2. Salvage therapies

If known treatment protocols provided no or limited response in SHL patients, salvage treatments should be considered. The efficacy of the salvage treatments, which became popular

in the recent years, was shown in different studies with control groups. Hyperbaric O<sub>2</sub> and intratympanic steroid treatment can be mentioned among these treatment principles.

### 8.2.1. Intratympanic steroid therapy (ITS)

We already mentioned that corticosteroids had a well-established efficacy in the treatment of SHL. In patients, in whom corticosteroids have limited use or efficacy, they may be administered intratympanically with different methods. Thus corticosteroids penetrate through the middle ear membranes to the inner ear and achieve high concentrations, which consequently increased the recovery rate [80]. ITS is a treatment method, which has an ongoing increase in popularity, minimizes the side effects of corticosteroids and enables achievement of therapeutic steroid concentrations with low doses. ITS is not only effective as a salvage therapy, but it also enables good results if it is combined with systemic corticosteroids during the primary treatment or administered as the primary treatment agent in patients, who cannot tolerate systemic steroids [81–84].

### 8.2.2. Hyperbaric oxygen therapy

Hyperbaric O<sub>2</sub> therapy (HBO) is another salvage therapy method and investigated with a large number of studies. The basic principle is to increase the partial O<sub>2</sub> pressure, which is decreased in the perilymph and cochlea in patients with SHL. Experimental studies have demonstrated that HBO increased the partial O<sub>2</sub> pressure in the inner ear [85]. The increased partial O<sub>2</sub> pressure in the inner ear supplies the needed O<sub>2</sub> even if the blood flow is decreased and stimulates the cells. It decreases the platelet aggregation and increases the flexibility of the erythrocytes which positively affects the nutrition of the inner ear. Several recent studies demonstrated that the combined use of HBO therapy and corticosteroids or the use of HBO as a salvage therapy had positive effects on SHL [86–91]. The basic principle of the HBO therapy is to apply 100% O<sub>2</sub> with a 2–3 atm pressure in repeated doses and to increase the O<sub>2</sub> pressure in the inner ear with a controlled process. During the application of this procedure, the possible damage of the free O<sub>2</sub> radicals should be taken into consideration.

## 8.3. Surgical treatment

Surgical treatment can only be carried out in a subgroup of patients with a known etiology. Cases with membrane ruptures, intracochlear membrane ruptures, endolymphatic hydrops, and acoustic neuroma can be treated with surgical interventions.

## 9. Prognosis

As SHL has a multifactorial etiology, the prognosis is variable. Considering all SHL cases, spontaneous regression rate is over 60%. In addition, some factors, which have positive or negative effects on the prognosis, have been described. Even though these factors do not change the treatment, they provide useful information about the course of the disease.

The most important criterion is the time between the emergence of the symptoms and the initiation of the treatment. The prognosis is much better in patients started treatment early. Another factor is the age of the patient. An age less than 15 or greater than 65 years indicates a bad prognosis. The prognosis worsens with the severity of the hearing loss. Although the prognosis is relatively better in the low-frequency hearing loss compared to the high-frequency hearing loss, an ascendant type audiometric curve promises a better prognosis than the descendant type audiometric curve. The presence of vertigo and nystagmus, which shows that vestibular system is also affected, is a sign of bad prognosis. In contrary, tinnitus indicates a good prognosis in SHL, because tinnitus is considered as a sign that the hair cells in the inner ear are not completely destroyed. Bilateral SHL has a relatively worse prognosis. Increased sedimentation rate and an increase in the high sensitive CRP levels are related to the severity of the inflammation and thus to the bad prognosis. In SHL, recovery can be observed within 6 months to 1 year, it is wise to arrange the pre-rehabilitation follow-up plan according to this duration. In SHL patients, who did not show any recovery after 1 year, hearing rehabilitation can be planned upon the patient's request and according to the severity of the hearing loss.

## 10. Conclusion

As we have seen, SHL preserves its darkness as an enigma of ENT world. There are several already-published and a large number of ongoing studies on the etiology and treatment of SHL in the literature. Although certain diagnosis and treatment algorithms developed for SHL are already available, they cannot be implemented in all SHL cases. If corticosteroids cannot deliver sufficient results, there are not much treatment choices. Further studies for a full elucidation of the physiopathology, etiology, and treatment of SHL are required.

## Abbreviations

SHL	Sudden hearing loss
ENT	Ear-nose-throat
CMV	Cytomegalovirus
CTL-2	Choline transporters like protein 2
AECA	Anti-endothelial antibodies
Hsp-70	Heat-shock protein 70
SLE	Systemic lupus erythematosus
ITS	Intratympanic steroid therapy
HBO	Hyperbaric O <sub>2</sub> therapy

## Author details

Harun Acipayam<sup>1\*</sup>, Hasan Emre Koçak<sup>2</sup> and Mustafa Suphi Elbistanlı<sup>2</sup>

\*Address all correspondence to: [harunacipayam@gmail.com](mailto:harunacipayam@gmail.com)

1 Department of Otolaryngology, Kanuni Sultan Süleyman Training and Research Hospital-Beylikdüzü Campus, İstanbul, Turkey

2 Department of Otolaryngology, Bakırköy Sadi Konuk Training and Research Hospital, İstanbul, Turkey

## References

- [1] Kleyn AD. Sudden complete or partial loss of function of the octavus-system in apparently normal persons. *Acta Oto-Laryngologica*. 1944;**32**(5):407-429
- [2] Oiticica J, Bittar RSM. Metabolic disorders prevalence in sudden deafness. *Clinics*. 2010;**65**(11):1149-1153
- [3] Stachler RJ, Chandrasekhar SS, Archer SM, Rosenfeld RM, Schwartz SR, Barrs DM, et al. Clinical practice guideline: Sudden hearing loss. *Otolaryngology and Head and Neck Surgery*. 2012;**146**(3):1-35
- [4] Sara SA, Teh BM, Friedland P. Bilateral sudden sensorineural hearing loss. *The Journal of Laryngology & Otology*. 2014 Jan;**128**(S1):8-15
- [5] Fetterman BL, Luxford WM, Saunders JE. Sudden bilateral sensorineural hearing loss. *Laryngoscope*. 1996;**106**:1347-1350
- [6] JH O, Park K, Lee SJ, Shin YR, Choung YH. Bilateral versus unilateral sudden sensorineural hearing loss. *Otolaryngology and Head and Neck Surgery*. 2007;**136**:87-91
- [7] Lister RJ, Rhoton AL Jr, Matsushima T, Peace DA. Microsurgical anatomy of the posterior inferior cerebellar artery. *Neurosurgery*. 1982;**10**(2):170-199
- [8] Çelik O. *Otoloji-Nörootoloji*. Manisa, Türkiye: Elit Ofset; 2013
- [9] Kim JH, Roh KJ, Suh SH, Lee KY. Improvement of sudden bilateral hearing loss after vertebral artery stenting. *Journal of Neurointerventional Surgery*. 2016;**8**(3):12-13
- [10] Perlman HB, Kimura R, Fernandez C. Experiments on temporary obstruction of the internal auditory artery. *The Laryngoscope*. 1959;**69**(6):591-613
- [11] Chung JH, Lee SH, Park CW, Kim C, Park JK, Shin JH. Clinical significance of arterial stiffness in idiopathic sudden sensorineural hearing loss. *The Laryngoscope*. 2016;**126**(8):1918-1922
- [12] Rajati M, Azarpajoo MR, Mouhebat M, Nasrollahi M, Salehi M, Khadivi E, Nourizadeh N, Hashemi F, Bakhshae M. Is sudden hearing loss associated with atherosclerosis? *Iranian Journal of Otorhinolaryngology*. 2016;**28**(86):189

- [13] Koçak HE, Filiz Acıpayam AŞ, Acıpayam H, Çakıl Erdoğan B, Alakhraş WM, Kıral MN, Kayhan FT. Microvascular dysfunction affects the development and prognosis of sudden idiopathic hearing loss. *Clinical Otolaryngology*. 2017;**42**(3):602-607
- [14] Weiss BG, Bertlich M, Bettag SA, Desinger H, Ihler F, Canis M. Drug-induced defibrinogenation as new treatment approach of acute hearing loss in an animal model for inner ear vascular impairment. *Otology & Neurotology*. 2017;**38**(5):648-654
- [15] Hanna GS. Sudden deafness and the contraceptive pill. *The Journal of Laryngology and Otology*. 1986;**100**(6):701-706
- [16] Shu J, Si Y, Yin S, He M. Association between the V Leiden G1691A mutation and sudden sensorineural hearing loss in Italian population: A meta-analysis. *European Archives of Oto-Rhino-Laryngology*. 2016;**273**(9):2467-2472
- [17] Sargent EW. Sudden sensorineural hearing loss following nonotologic, noncardiopulmonary bypass surgery. *Archives of Otolaryngology – Head & Neck Surgery*. 1997;**123**(9):994-998
- [18] Capaccio P, Ottaviani F, Cuccarini V, Bottero A, Schindler A, Cesana BM, et al. Genetic and acquired prothrombotic risk factors and sudden hearing loss. *Laryngoscope*. 2007;**117**:547-551
- [19] Cadoni G, Scipione S, Agostino S, Addolorato G, Cianfrone F, Leggio L, Paludetti G, Lippa S. Coenzyme Q 10 and cardiovascular risk factors in idiopathic sudden sensorineural hearing loss patients. *Otology & Neurotology*. 2007;**28**(7):878-883
- [20] Chang IJ, Kang CJ, Yueh CY, Fang KH, Yeh RM, Te Tsai Y. The relationship between serum lipids and sudden sensorineural hearing loss: A systematic review and meta-analysis. *PLoS One*. 2015;**10**(4):e0121025
- [21] Linthicum FH Jr, Doherty J, Berliner KI. Idiopathic sudden sensorineural hearing loss: Vascular or viral? *Otolaryngology – Head and Neck Surgery*. 2013;**149**(6):914-917
- [22] Lindsay JR, Hemenway WG. LIV inner ear pathology due to measles. *Annals of Otology, Rhinology and Laryngology*. 1954;**63**(3):754-771
- [23] Lindsay JR, Davey PR, Ward PH. Inner ear pathology in deafness due to mumps. *The Annals of Otology, Rhinology, and Laryngology*. 1960;**69**:918-935
- [24] Cohen BE, Durstenfeld A, Roehm PC. Viral causes of hearing loss: A review for hearing health professionals. *Trends in Hearing*. 2014;**18**:2331216514541361
- [25] Van Dishoeck HAE, Bierman TA. Sudden perceptive deafness and viral infection: Report of the first one hundred patients. *Annals of Otology, Rhinology and Laryngology*. 1957;**66**(4):963-980
- [26] Chau JK, Lin JR, Atashband S, Irvine RA, Westerberg BD. Systematic review of the evidence for the etiology of adult sudden sensorineural hearing loss. *The Laryngoscope*. 2010;**120**(5):1011-1021



- [27] Wilson WR, Veltri RW, Laird N, Sprinkle PM. Viral and epidemiologic studies of idiopathic sudden hearing loss. *Otolaryngology – Head and Neck Surgery*. 1983;**91**(6):653-658
- [28] Kuhn M, Heman-Ackah SE, Shaikh JA, Roehm PC. Sudden sensorineural hearing loss: A review of diagnosis, treatment, and prognosis. *Trends in Amplification*. 2011;**15**(3):91-105
- [29] Lorenzi MC, Bittar RS, Pedalini ME, Zerati F, Yoshinari NH, Bento RF. Sudden deafness and Lyme disease. *The Laryngoscope*. 2003;**113**(2):312-315
- [30] Walther LE, Hentschel H, Oehme A, Gudziol H, Beleites E. Lyme disease— A reason for sudden sensorineural hearing loss and vestibular neuronitis? *Laryngo-Rhino-Otologie*. 2003;**82**(4):249-257
- [31] Marra CM. Update on neurosyphilis. *Current Infectious Disease Reports*. 2009;**11**(2):127
- [32] Wilson WR. The relationship of the herpesvirus family to sudden hearing loss: A prospective clinical study and literature review. *The Laryngoscope*. 1986;**96**(8):870-877
- [33] Greco A, Fusconi M, Gallo A, Marinelli C, Macri GF, De Vincentiis M. Sudden sensorineural hearing loss: An autoimmune disease? *Autoimmunity Reviews*. 2011;**10**(12):756-761
- [34] Garcia Berrocal JR, Ramirez-Camacho R. Sudden sensorineural hearing loss: Supporting the immunologic theory. *The Annals of Otolaryngology, Rhinology, and Laryngology*. 2002;**111**:989-997
- [35] Yoo TJ, Tomoda H, Hernandez AD. Type II collagen-induced autoimmune inner ear lesions in guinea pigs. *The Annals of Otolaryngology, Rhinology, and Laryngology*. 1984;**113**:3-5
- [36] Solares CA, Edling AE, Johnson JM, Baek MJ, Hirose K, Hughes GB, et al. Murine autoimmune hearing loss mediated by CD4+ T cells specific for inner ear peptides. *The Journal of Clinical Investigation*. 2004;**113**:1210-1217
- [37] Boulassel MR, Deggouj N, Tomasi JP, Gersdorff M. Inner ear autoantibodies and their targets in patients with autoimmune inner ear diseases. *Acta Oto-Laryngologica*. 2001;**121**:28-34
- [38] Boulassel MR, Tomasi JP, Deggouj N, Gersdorff M. Identification of beta-actin as a candidate autoantigen in autoimmune inner ear disease. *Clinical Otolaryngology and Allied Sciences*. 2000;**25**:535-541
- [39] Disher MJ, Ramakrishnan A, Nair TS, Miller JM, Telian SA, Arts HA, et al. Human autoantibodies and monoclonal antibody KHRI-3 bind to a phylogenetically conserved inner-ear-supporting cell antigen. *Annals of the New York Academy of Sciences*. 1997;**830**:253-265
- [40] Lunardi C, Bason C, Leandri M, et al. Autoantibodies to inner ear and endothelial antigens in Cogan's syndrome. *Lancet*. 2002;**360**:915-921
- [41] Yoo TJ, Tomoda K, Stuart JM, Cremer MA, Townes AS, Kang AH. Type II collagen induced autoimmune sensorineural hearing loss and vestibular dysfunction in rats. *Annals of Otolaryngology, Rhinology and Laryngology*. 1983;**92**:267-271

- [42] Toubi E, Ben-David J, Kessel A, Podoshin L, Golan TD. Autoimmune aberration in sudden sensorineural hearing loss: Association with anti-cardiolipin antibodies. *Lupus*. 1997;**6**:540-542
- [43] Joliat T, Seyer J, Bernstein J, et al. Antibodies against a 30kDA cochlear protein and type II and type IX collagens in the serum of patients with inner ear disease. *The Annals of Otolaryngology, Rhinology, and Laryngology*. 1992;**101**:1000-1006
- [44] Nordang L, Laurent C, Mollnes TE. Complement activation in sudden deafness. *Archives of Otolaryngology – Head & Neck Surgery*. 1998;**124**:633-636
- [45] Meroni PL, D'Cruz D, Khamashta M, Youinou O, Hughes GRV. Anti-endothelial cell antibodies: Only for scientists or for clinicians too ? *Clinical and Experimental Immunology*. 1996;**104**:199-202
- [46] McCabe BF. Autoimmune sensorineural hearing loss. *The Annals of Otolaryngology, Rhinology, and Laryngology*. 1979;**88**:585-589
- [47] Ottaviani F, Cadoni G, Marinelli M, et al. Anti-endothelial autoantibodies in patients with sudden hearing loss. *Laryngoscope*. 1999;**109**:1084-1087
- [48] Harris JP, Sharp PA. Inner ear autoantibodies in patients with rapidly progressive sensorineural hearing loss. *Laryngoscope*. 1990;**100**:516-524
- [49] Garcia Berrocal JR, Ramirez-Camacho R, Arellano B, Vargas JA. Validity of the western blot immunoassay for heat shock protein-70 in associated and isolated immunorelated inner ear disease. *Laryngoscope*. 2002;**112**:304-309
- [50] Samuelsson AK, Hyden D, Roberg M, Skogh T. Evaluation of anti-hsp 70 antibody screening in sudden deafness. *Ear and Hearing*. 2003;**24**:233-235
- [51] Chawki S, Aouizerate J, Trad S, Prinseau J, Hanslik T. Bilateral sudden sensorineural hearing loss as a presenting feature of systemic lupus erythematosus: Case report and brief review of other published cases. *Medicine*. 2016;**95**(36):e4345
- [52] Compadretti GC, Brandolini C, Tasca I. Sudden SNHL in lupus erythematosus associated with antiphospholipid syndrome. *The Annals of Otolaryngology, Rhinology, and Laryngology*. 2005;**114**:214-218
- [53] Naarendrop M, Spiera H. Sudden SNHL in patients with SLE and antiphospholipid antibodies. *The Journal of Rheumatology*. 1998;**25**:589-592
- [54] Harris JP, Sharp PA. Inner ear autoantibodies in patients with rapidly progressive sensorineural hearing loss. *The Laryngoscope*. 1990;**100**(5):516-524
- [55] Stearns GS, Keithley EM, Harris JP. Development of high endothelial venule-like characteristics in the spiral modiolar vein induced by viral labyrinthitis. *The Laryngoscope*. 1993;**103**(8):890-898
- [56] Heywood RL, Hadavi S, Donnelly S, Patel N. Infliximab for autoimmune inner ear disease: Case report and literature review. *The Journal of Laryngology & Otolaryngology*. 2013;**127**(11):1145-1147

- [57] Goodhill V, Harris I. Sudden hearing loss syndrome. In: *Ear Diseases, Deafness, and Dizziness*. New York: Harper-Collins; 1979. pp. 664-681
- [58] Simmons FB. Theory of membrane breaks in sudden hearing loss. *Archives of Otolaryngology*. 1968;**88**(1, 1):41-48
- [59] Gussen R. Sudden hearing loss associated with cochlear membrane rupture: Two human temporal bone reports. *Archives of Otolaryngology*. 1981;**107**(10):598-600
- [60] Kamerer DB, Sando I, Hirsch B, Takagi A. Perilymph fistula resulting from microfissures. *Otology & Neurotology*. 1987;**8**(6):489-494
- [61] Yood TH, Paparella MM, Schacern PA, Alleva M. Histopathology of sudden hearing loss. *The Laryngoscope*. 1990;**100**(7):707-715
- [62] Vasama JP, Linthicum FH Jr. Idiopathic sudden sensorineural hearing loss: Temporal bone histopathologic study. *Annals of Otolaryngology, Rhinology and Laryngology*. 2000;**109**(6):527-532
- [63] Conte G, Di Berardino F, Sina C, Zanetti D, Scola E, Gavagna C, Gaini L, Palumbo G, Capaccio P, Triulzi F. MR imaging in sudden sensorineural hearing loss. Time to talk. *AJNR – American Journal of Neuroradiology*. 2017 Aug;**38**(8):1475-1479
- [64] Lee JI, Yoon RG, Lee JH, et al. Prognostic value of labyrinthine 3DFLAIR abnormalities in idiopathic sudden sensorineural hearing loss. *AJNR. American Journal of Neuroradiology*. 2016;**37**:2317-2322
- [65] Ryu IS, Yoon TH, Ahn JH, et al. Three-dimensional fluid-attenuated inversion recovery magnetic resonance imaging in sudden sensorineural hearing loss: Correlations with audiologic and vestibular testing. *Otology & Neurotology*. 2011;**32**:1205-1209
- [66] Wilson WR, Byl FM, Laird N. The efficacy of steroids in the treatment of idiopathic sudden hearing loss: A double-blind clinical study. *Archives of Otolaryngology*. 1980;**106**(12):772-776
- [67] Stachler RJ, Chandrasekhar SS, Archer SM, Rosenfeld RM, Schwartz SR, Barrs DM, Brown SR, Fife TD, Ford P, Ganiats TG, Hollingsworth DB. Clinical practice guideline: Sudden hearing loss. *Otolaryngology – Head and Neck Surgery*. 2012;**146**(3\_suppl):S1-35
- [68] Goh AY, Hussain SS. Sudden hearing loss and pregnancy: A review. *The Journal of Laryngology & Otology*. 2012;**126**(4):337-339
- [69] Rauch SD, Halpin CF, Antonelli PJ, Babu S, Carey JP, Gantz BJ, Goebel JA, Hammerschlag PE, Harris JP, Isaacson B, Lee D. Oral vs. intratympanic corticosteroid therapy for idiopathic sudden sensorineural hearing loss: A randomized trial. *Journal of the American Medical Association*. 2011;**305**(20):2071-2079
- [70] Stokroos RJ, Albers FWJ, Schirm J. The etiology of idiopathic sudden sensorineural hearing loss. Experimental herpes simplex virus infection of the inner ear. *The American Journal of Otolaryngology*. 1998;**19**:447-452

- [71] Park KH, Lee CK, Lee JD, Park MK, Lee BD. Combination therapy with systemic steroids, an antiviral agent, anticoagulants, and stellate ganglion block for treatment of sudden sensorineural hearing loss. *Korean Journal of Audiology*. 2012;**16**(2):71-74
- [72] Westerlaken BO, Stokroos RJ, Wit HP, Dhooge IJ, Albers FW. Treatment of idiopathic sudden sensorineural hearing loss with antiviral therapy: A prospective, randomized, double-blind clinical trial. *Annals of Otolaryngology, Rhinology and Laryngology*. 2003;**112**(11):993-1000
- [73] Tucci DL, Farmer JC Jr, Kitch RD, Witsell DL. Treatment of sudden sensorineural hearing loss with systemic steroids and valacyclovir. *Otology & Neurotology*. 2002;**23**(3):301-308
- [74] Kronenberg J, Almagor M, Bendet E, Kushnir D. Vasoactive therapy versus placebo in the treatment of sudden hearing loss: A double-blind clinical study. *The Laryngoscope*. 1992;**102**(1, 1):65-68
- [75] Kallinen J, Laippala P, Laurikainen E, Grénman R. Sudden deafness: A comparison of anticoagulant therapy and carbogen inhalation therapy. *Annals of Otolaryngology, Rhinology and Laryngology*. 1997;**106**(1):22-26
- [76] Probst R, Tschopp K, Lodin E, Kellerhals B, Podvinec M, Pfaltz CR. A randomized, double-blind, placebo-controlled study of dextran/pentoxifylline medication in acute acoustic trauma and sudden hearing loss. *Acta Oto-Laryngologica*. 1992;**112**(3):435-443
- [77] Nageris BI, Ulanovski D, Attias J. Magnesium treatment for sudden hearing loss. *Annals of Otolaryngology, Rhinology and Laryngology*. 2004;**113**(8):672-675
- [78] Gordin A, Goldenberg D, Golz A, Netzer A, Joachims HZ. Magnesium: A new therapy for idiopathic sudden sensorineural hearing loss. *Otology & Neurotology*. 2002;**23**(4):447-451
- [79] Suckfüll M. Hearing loss study group. Fibrinogen and LDL apheresis in treatment of sudden hearing loss: A randomised multicentre trial. *The Lancet*. 2002;**360**(9348):1811-1817
- [80] Slattery WH, Fisher LM, Iqbal Z, Friedman RA, Liu N. Intratympanic steroid injection for treatment of idiopathic sudden hearing loss. *Otolaryngology – Head and Neck Surgery*. 2005;**133**(2):251-259
- [81] Xenellis J, Papadimitriou N, Nikolopoulos T, Maragoudakis P, Segas J, Tzagaroulakis A, Ferekidis E. Intratympanic steroid treatment in idiopathic sudden sensorineural hearing loss: A control study. *Otolaryngology – Head and Neck Surgery*. 2006;**134**(6):940-945
- [82] Herr BD, Marzo SJ. Intratympanic steroid perfusion for refractory sudden sensorineural hearing loss. *Otolaryngology – Head and Neck Surgery*. 2005;**132**(4):527-531
- [83] Battaglia A, Burchette R, Cueva R. Combination therapy (intratympanic dexamethasone+ high-dose prednisone taper) for the treatment of idiopathic sudden sensorineural hearing loss. *Otology & Neurotology*. 2008;**29**(4):453-460
- [84] Gülüstan F, Yazıcı ZM, Alakhras WM, Erdur O, Acipayam H, Kufeciler L, Kayhan FT. Intratympanic steroid injection and hyperbaric oxygen therapy for the treatment of refractory sudden hearing loss. *Brazilian Journal of Otorhinolaryngology*. 2016

- [85] Lamm K, Lamm C, Arnold W. Effect of isobaric oxygen versus hyperbaric oxygen on the normal and noise-damaged hypoxic and ischemic guinea pig inner ear. In: Yanagita N, Nakashima T, editors. *Hyperbaric Oxygen Therapy in Otorhinolaryngology*. Advances in Otorhinolaryngology. Vol. 54. Basel: Karger; 1998. pp. 59-85
- [86] Fattori B, Berrettini S, Casani A, Nacci A, De Vito A, De Iaco G. Sudden hypoacusis treated with hyperbaric oxygen therapy: A controlled study. *Ear, Nose, & Throat Journal*. 2001;**80**:655-660
- [87] Pilgramm M, Roth M, Fisher B. Der Einfluss der hyperbaren oxygenation auf rheologische parameter. *Perfusion*. 1988;**2**:79-82
- [88] Racic G, Maslovara S, Roje Z, Dogas Z, Tafra R. Hyperbaric oxygen in the treatment of sudden hearing loss. *ORL*. 2003;**65**(6):317-320
- [89] Bennett MH, Kertesz T, Yeung P. Hyperbaric oxygen for idiopathic sudden sensorineural hearing loss and tinnitus. *Cochrane Database of Systematic Reviews*. 2007 Jan 24;(1):CD004739
- [90] Fujimura T, Suzuki H, Shiomori T, Udaka T, Mori T. Hyperbaric oxygen and steroid therapy for idiopathic sudden sensorineural hearing loss. *European Archives of Oto-Rhino-Laryngology*. 2007;**264**(8):861-866
- [91] Horn CE, Himel HN, Selesnick SH. Hyperbaric oxygen therapy for sudden sensorineural hearing loss: A prospective trial of patients failing steroid and antiviral treatment. *Otology & Neurotology*. 2005;**26**(5):882-889
- [92] Ragab A, Shreef E, Behiry E, Zalat S, Noaman M. Randomised, double-blinded, placebo-controlled, clinical trial of ozone therapy as treatment of sudden sensorineural hearing loss. *The Journal of Laryngology & Otology*. 2009;**123**(1):54-60

