
Cardiac Dyssynchrony as a Pathophysiologic Factor of Functional Mitral Regurgitation: Role of Cardiac Resynchronization Therapy

Barbara Brzezińska and Krystyna Łoboz-Grudzień

Additional information is available at the end of the chapter

<http://dx.doi.org/10.5772/intechopen.76605>

Abstract

Functional mitral regurgitation, a common problem in patients with left ventricular systolic dysfunction, has a strong negative impact on prognosis. Beneficial effects of surgical treatment in functional mitral regurgitation are still a matter of debate. Thus, cardiac dyssynchrony, a factor involved in functional mitral regurgitation pathophysiology, may become a therapeutic target in patients with this condition. This part of the book presents the pathophysiology of functional mitral regurgitation as a dynamic process, with particular emphasis on cardiac dyssynchrony, as both a contributor to functional mitral regurgitation and a target for cardiac resynchronization therapy. The underlying mechanisms of success and failure in the resynchronization therapy are discussed, along with therapeutic approaches to symptomatic patients with severe left ventricular dysfunction and significant persistent functional mitral regurgitation.

Keywords: functional mitral regurgitation, left ventricular remodeling, cardiac dyssynchrony, cardiac resynchronization therapy

1. Introduction

Secondary (functional) mitral regurgitation (MR) is a common finding in patients with global left ventricular (LV) dilatation and dysfunction, in both ischemic and non-ischemic cardiomyopathy. This functional disorder of the mitral valve is more common and far more complex than organic MR. In secondary MR, mitral valve is structurally normal (or almost normal) but its geometry and function are disrupted due to an imbalance between closing and tethering

forces secondary to alterations in the geometry and function of the left ventricle. Functional MR can promote progressive LV remodeling. This results in a vicious circle, with both LV dilatation and functional MR acting as self-perpetuating processes. While prognosis is affected only in severe organic MR, even a mild functional MR may significantly worsen the outcome. However, it is unclear whether the unfavorable impact of functional MR on prognosis is independent of underlying LV dysfunction. We still do not know if mitral valve surgery, effective in the treatment of organic diseases of the mitral valve, can be equally beneficial in functional MR, since the surgical correction of valve dysfunction does not reverse the underlying LV pathology. Thus, indications for mitral valve surgery in heart failure (HF) patients with functional MR are not well defined in any currently available guidelines. Also the role of other treatment modalities, such as medical and interventional therapies, still raises controversies because of their limited effectiveness in functional MR management. This is related to both the underlying heart disease and the complexity of functional MR phenomenon. Also, adequate assessment of functional MR mechanisms and severity by means of imaging studies prior to making any therapeutic decisions constitute a challenge for clinicians. Cardiac dyssynchrony is a mechanism that provides a pathophysiologic basis for potential improvement of functional MR after the use of cardiac resynchronization therapy (CRT).

This part of the book presents the pathomechanism of functional MR with particular emphasis on the influence of cardiac dyssynchrony on mitral valve function, as well as the mechanisms of MR improvement after implantation of a CRT device, and prognostic value of both functional MR and its regression in response to CRT in patients with chronic heart failure.

2. Incidence and importance of functional mitral regurgitation in left ventricular dysfunction

Functional MR is a common, but often 'silent,' finding in heart failure patients [1–6]. Reported prevalence of functional MR varies depending on a diagnostic method (angiography, color Doppler echocardiography) and heart failure etiology (ischemic, non-ischemic) [1–5]. The incidence of functional MR after myocardial infarction varies from 20 to 50% but exceeds 50% in patients with non-ischemic dilated cardiomyopathy [4–6]. According to general estimates, nearly a half of heart failure patients may have a functional MR of some degree, and approximately one-third of them may suffer from moderate or severe functional MR [1, 3, 7].

Functional MR is an independent predictor of worse prognosis in patients with either ischemic or non-ischemic etiology of heart failure [3]. In patients with non-ischemic LV dysfunction, functional MR is associated with a two- to three-fold increased risk of heart failure episodes and cardiac mortality [4]. After myocardial infarction the presence of at least moderate functional MR is associated with a 3-fold increased risk of heart failure and a 1.6-fold increased risk of death at the 5-year follow-up [2]. Assessment of mitral valve function is included in routine risk stratification after myocardial infarction.

Functional MR is present in a large proportion of patients eligible for cardiac resynchronization therapy, with the incidence varying slightly from population to population and depending

on the evaluation method. Significant—that is, at least moderate—functional MR is present in about 40% of patients qualified to CRT [8–10]. Nowadays, functional MR no longer disqualifies patients from resynchronization therapy if such treatment is indicated. Furthermore, a decrease in functional MR severity is a determinant of response to CRT [10–12].

3. Difficulties in echocardiographic quantification of functional mitral regurgitation

Adequate evaluation of functional MR requires detailed clinical information (including functional NYHA class), physical examination, electrocardiography, and imaging studies. Echocardiography is essential for the evaluation of mitral valve anatomy and quantification of MR severity [13]. Transthoracic and transesophageal echocardiography may provide complementary clinically useful information, especially in the context of surgical or transcatheter repair feasibility. Usually, transesophageal echocardiography is more suitable for the evaluation of underlying anatomical conditions and identification of functional MR mechanism. However, due to changes in LV loading conditions during transesophageal evaluation (vasodilatory effect of sedation, hypovolemia, or anesthesia), the severity of functional MR may be underestimated; this favors transthoracic echocardiography as a method to quantify mitral regurgitation. Moreover, transthoracic examination is more suitable for the evaluation of other important parameters, such as LV volume, function and sphericity, left atrial size, pulmonary artery pressure, and function of the right ventricle and tricuspid valve. Three-dimensional (3D) echocardiography (either transesophageal or transthoracic) may provide additional information about MR severity, especially with regard to noncircular orifice geometry in functional MR [14]. 3D echocardiography overcomes some limitations of two-dimensional (2D) imaging; for example, it can be used for direct planimetric measurement of *vena contracta* area, a parameter which corresponds directly to the effective regurgitant orifice area (EROA) irrespective of the orifice shape or number of jets. However, both 3D and 2D color Doppler flows tend to overestimate the jet area (volume) due to their known bias in correct assessment of a turbulent stream. Considering all the difficulties previously mentioned, it needs to be stressed that no single parameter (also “quantitative”) is sufficient to adequately assess the severity of functional MR and thus, this condition should be evaluated with multiple methods [14].

In practical terms, echocardiographic severity of MR can be graded as mild, moderate or severe. Since available evidence suggests that functional MR of lesser severity may have similar or greater impact on mortality than primary MR [2], distinguishing between moderate and severe MR becomes of vital importance [15]. While severe primary MR is defined as EROA ≥ 40 mm² and regurgitant volume ≥ 60 mL, in line with current guidelines, severe secondary MR should be diagnosed whenever EROA ≥ 20 mm² and regurgitant volume ≥ 30 mL [13, 15] (Table 1) [16]. However, adequate evaluation of functional MR severity in a clinical setting is far more challenging. In functional MR, both regurgitant orifice and jet area depend strongly on the mechanism of mitral regurgitation. Functional MR severity may be overestimated if determined based on the jet size on color Doppler imaging, or underestimated if

	Primary (organic) MR	Secondary (functional) MR
EROA	$\geq 0.4 \text{ cm}^2$	$\geq 0.2 \text{ cm}^2$
Regurgitant volume	$\geq 60 \text{ mL}$	$\geq 30 \text{ mL}$
Regurgitant fraction	$\geq 50\%$	$\geq 50\%$
Vena contracta	$\geq 0.7 \text{ cm}$	—
Jet area	Central jet $>40\%$ LA or holosystolic eccentric jet	—

Table 1. Quantitative echocardiographic criteria for severe MR in primary and secondary disease of the mitral valve [16].

assessed using other traditional measures of mitral regurgitation such as proximal isovelocity surface area (PISA) and *vena contracta* width [14]. Also the limitations of the volumetric method in the assessment of regurgitant volume and fraction are well-known issues [14]. Furthermore, low inter- and intra-observer agreement between cardiologists reviewing the same dataset was documented [17]. It is now known that due to the limitations inherent to each available method, no single parameter is accurate enough to quantify the degree of MR. Therefore, current guidelines recommend an integrative approach including multiple qualitative and quantitative parameters, along with certain signs and measures of MR severity, such as left ventricular size and function, left atrial size, mitral valve leaflet morphology and motion, mitral filling pattern, pulmonary venous flow pattern and others [13, 16]. If during the first attempt MR is not unequivocally defined as mild or severe, the integrative approach should be used to exclude the severe character of mitral regurgitation.

Functional MR is an evidently dynamic phenomenon. A typical phasic variation in regurgitant volume and orifice, with the maximum values observed in early and late systole and minimum ones in mid-systole (at peak transmitral pressure gradient generated by LV), is documented [18]. This intra-beat variability (referred to as the “loitering pattern”) hinders functional MR assessment, which is traditionally carried out in mid-systole. The severity of functional MR may also show a beat-to-beat variability depending on changes in loading conditions and hemodynamic parameters (e.g., during arrhythmia). The dynamic nature of functional MR has particular practical meanings in two situations: during physical exertion and intraoperative assessment. Induction of anesthesia and inotropic agents may significantly reduce MR and thus, may directly affect intraoperative decisions regarding its repair. Owing the dynamic nature of functional MR, in patients whose symptoms at rest are inadequate to assess the severity of mitral regurgitation, more accurate information may be obtained during exercise echocardiography. Exercises contribute to a greater cardiac load and thus, may also trigger dynamic geometric changes in the LV and mitral valve apparatus (even despite the lack of provoked ischemia), which may eventually result in acute “flash pulmonary edema” [19]. This may be a reason behind worse prognosis associated with even a mild functional MR. An exercise-induced increase in EROA by at least 13 mm^2 was shown to correlate with higher morbidity and mortality [20]. Exercise echocardiography may also unmask increasing pulmonary artery pressure and the lack of LV contractile reserve, both being important predictors of the outcome [19, 20]. Finally, exercises may reveal or trigger greater LV dyssynchrony with increased functional MR [21]. Despite some caveats of this approach, current guidelines recommend echocardiographic quantification of secondary MR during exercises, as this may

provide prognostically important information about dynamic characteristics of this condition [13]. Owing to documented limitations of echocardiography in this setting, newer imaging techniques, such as cardiac magnetic resonance and multidetector-row computed tomography, play an increasing role in the evaluation of patients with heart failure and functional MR. Both these techniques provide complementary data, such as true volumetric measures of cardiac chamber size and function, and can be used to assess myocardial viability and scars.

4. Pathophysiology of functional mitral regurgitation

The term “functional mitral regurgitation” refers to a dysfunction of the valve without its primary organic damage. Optimal function of the mitral valve provides nonrestrictive blood flow during diastole and leak tightness during systole. This diastolic and systolic competence is possible due to a synchronous coordination of all components of the mitral valve apparatus, acting under a balanced influence of closing and opening forces. Mitral valve apparatus is an integrated unit consisting of mitral valve itself (formed by two leaflets and mitral annulus) and subvalvular components (chordae tendineae, two papillary muscles, left ventricle and posterior left atrial wall). An effective function of the mitral valve is determined not only by the compatible cooperation between its components but also by their appropriate structural and spatial relations.

4.1. Left ventricular remodeling and dysfunction as a mechanism of functional mitral regurgitation

All changes in LV function and geometry affect functioning of mitral valve through opposing strength vectors: the tethering force (created by displacement of papillary muscles) and the LV-generated leaflet closing force (created by effective contraction causing transmitral pressure gradient) (**Figure 1**) [22]. Global LV dilation results in incomplete mitral leaflet closure and mitral regurgitation, which correlates with LV dysfunction. Local or global dilation of the LV is a prerequisite for incomplete mitral leaflet closure [22]. However, functional MR does not result from LV dilatation per se but from an increase in LV sphericity and resultant posterolateral displacement of the papillary muscles [23, 24]. If functional MR has an ischemic etiology, it does not necessarily need to be preceded by global systolic dysfunction [25]. Regional abnormalities in cardiac wall motion after inferior myocardial infarction may contribute to mitral valve tethering (with systolic tenting of the leaflets), which is strong enough to cause severe mitral regurgitation despite preserved LV ejection fraction (LVEF) [25].

Two main patterns of leaflet tethering can be distinguished in functional mitral regurgitation (**Figure 2**) [26, 27]. The symmetric pattern is characterized by global LV dilation with increased sphericity and predominant apical displacement of both leaflets with central regurgitant jet direction. Also the mitral valve annulus dilates symmetrically, primarily in the septal-lateral direction [26, 27]. This configuration is typical for non-ischemic functional MR (Carpentier type III B symmetric) [27, 28]. The asymmetric pattern is typically resulted from local remodeling of the posterior papillary muscle-bearing wall segment, with posterior tenting of both leaflets and a posteriorly directed asymmetric regurgitant jet (Carpentier type III B asymmetric) [25–28]. While the displacement of posterior papillary muscle is similar regardless of the leaflet tethering pattern, symmetric tethering is characterized by greater posterior and lateral displacement of

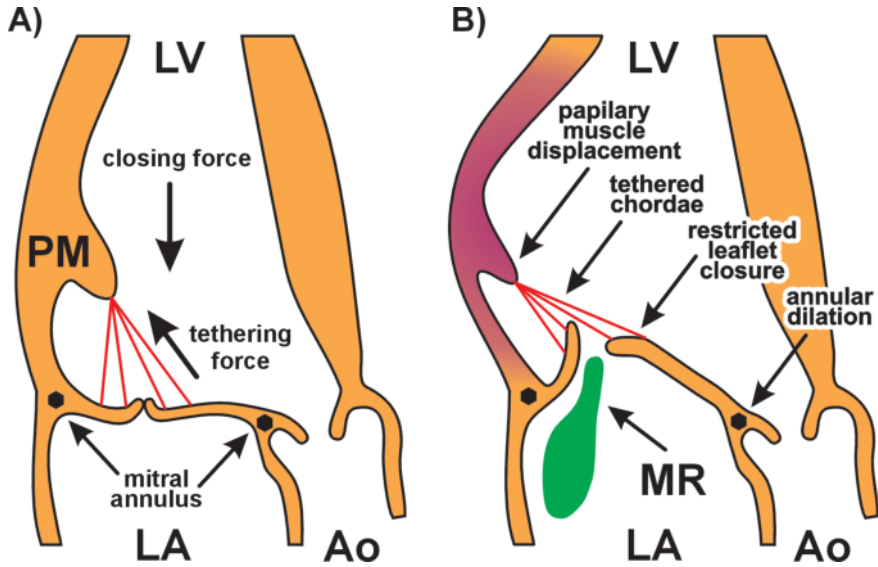


Figure 1. Mechanism of functional mitral regurgitation. (A) Balance of closing and tethering forces acting on mitral leaflets during systole. (B) Disrupted balance of closing and tethering forces due to local LV remodeling (dark shading). LA: left atrium; LV: left ventricle; PM: papillary muscle; Ao: aorta; ME: mitral regurgitation.

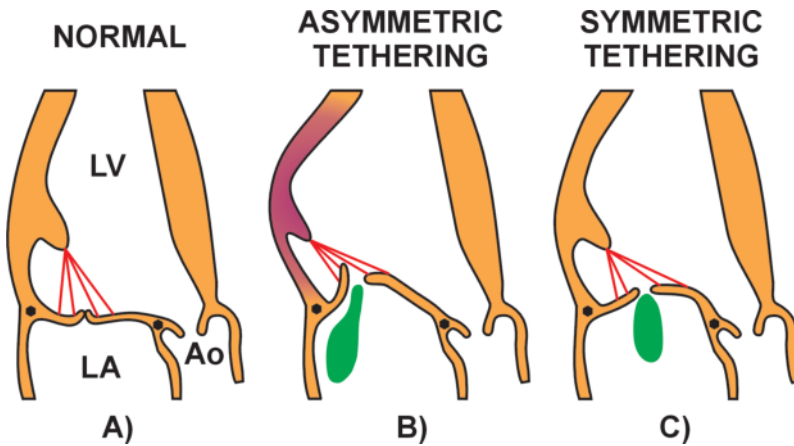


Figure 2. Patterns of leaflet tenting in functional mitral regurgitation. (A) Normal coaptation of mitral leaflets. (B) Asymmetric pattern—predominant posterior displacement of both leaflets with prevent restriction of posterior leaflet and large eccentric regurgitant jet. (C) Symmetric pattern—predominant apical displacement of both leaflets with central regurgitant jet.

anterior papillary muscle and longer inter-papillary distance [27]. Both patterns of leaflet tethering can be observed in ischemic MR [25–27]. The occurrence of the symmetric pattern in ischemic MR is associated with more advanced systolic dysfunction, global remodeling and increased LV sphericity [23, 24, 27]. This pattern is typical for non-ischemic dilated cardiomyopathy [26].

While geometric changes of LV are an essential component of functional MR pathomechanism, it is the tethering distance between the tip of posterior papillary muscle and the anterior pole of mitral annulus (“posterior papillary-fibrosa distance”), which constitutes the final common pathway determining the plane of leaflet coaptation [22, 29]. Mitral annular dilation typically occurs at late stage of ischemic MR [30, 31]. Isolated dilation and flattening of mitral valve annulus are occasionally the cause of severe mitral regurgitation, representing type I in Carpentier’s classification [28, 30, 31]. Although atrial fibrillation constitutes a quite frequent cause of functional MR, it rarely results in severe valve dysfunction. Isolated enlargement of the left atrium, with concomitant atrial fibrillation or without, leads to dilatation of mitral annulus and reduced leaflet coaptation [32]. Diastolic MR results from a reversal of atrioventricular pressure gradient during diastole. This form of MR occurs in patients with atrioventricular block, cardiomyopathy and aortic regurgitation, as well as in individuals with long filling periods in atrial tachyarrhythmia [31].

4.2. Cardiac dyssynchrony as a pathophysiologic factor of functional mitral regurgitation

Dyssynchrony, defined as an uncoordinated regional myocardial contraction [33, 34], may manifest as (1) “primary electrical dyssynchrony” (i.e., electrical conduction delay which causes non-uniform timing of myocyte depolarization), (2) abnormalities in excitation-contraction coupling (a surrogate for regional electromechanical coupling is the interval between the onset of QRS complex in ECG and the onset of systolic velocity in spectral pulsed-wave tissue Doppler imaging), or (3) “primary mechanical dyssynchrony” (i.e., a regional delay in onset shortening and in time to peak shortening of LV segments) [34]. Primary electrical dyssynchrony is typical for left bundle branch block (LBBB) and primary mechanical dyssynchrony—for regional ischemia or fibrosis [33, 34]. Currently, QRS duration remains the only clinically significant surrogate for the timing of myocardial contraction and the only criterion amenable for CRT [35, 36]. Clinical significance of “clear” primary mechanical dyssynchrony remains ambiguous [37, 38]. CRT does not provide any benefit (and may be even harmful) in heart failure patients with mechanical dyssynchrony without QRS widening (<130 ms) [38]. Various echocardiographic measures of dyssynchrony turned out not to be a superior selection criterion for CRT [39, 40]. Moreover, unacceptable variability, poor reproducibility and limited practical predictive value of the most echocardiographic parameters of dyssynchrony are documented [41]. Thus, although the predictive value of prolonged QRS also varies from study to study [42, 43], qualification to CRT is still based primarily on this parameter [35, 36].

Functional MR correlates strongly with QRS duration. Left bundle branch block and right ventricular pacing (which produce a conduction abnormality similar to LBBB), but not right bundle branch block or left anterior hemi-block, are strongly associated with functional MR [44]. The relationship between right ventricular pacing and mitral regurgitation indicates that the key determinant of functional MR is a conduction abnormality, rather than the underlying disease causing LBBB [44]. Those findings have important implications for biventricular pacing as a treatment option in heart failure patients with functional MR.

LV dyssynchrony is a less important determinant of functional MR than systolic valvular tenting, which is the strongest predictor of EROA [45]. However, the impact of systolic valvular tenting on functional MR in different subsets of patients with LV dysfunction varies. Mitral valve tenting and local LV remodeling (in the papillary muscle-bearing wall segments), but not regional dyssynchrony, are independent predictors of functional MR degree in ischemic LV dysfunction; these local changes result directly from ischemic lesions. In non-ischemic LV dysfunction, regional dyssynchrony exacerbates functional MR independently of LV geometry but as a factor of lesser importance [45].

5. Effect of cardiac resynchronization therapy on functional mitral regurgitation

Cardiac resynchronization therapy is an established treatment option for patients with advanced chronic heart failure and prolonged QRS duration [35, 36]. The benefits of CRT are attributed mainly to increased efficiency of LV filling and ejection, resulting from the improvement in atrioventricular coupling, intra- and interventricular synchronization [46–48]. CRT can attenuate heart failure symptoms and improve exercise capacity and survival in patients with heart failure and prolonged QRS duration [49–51]. In line with current ESC guidelines, cardiac resynchronization therapy is recommended (class I recommendation) in symptomatic (despite optimal medical therapy) patients with heart failure in sinus rhythm, with LBBB and QRS duration of at least 130 ms, with LVEF $\leq 35\%$, and in individuals with LV dysfunction (regardless of the NYHA class) who have an indication for ventricular pacing and high degree atrioventricular block [36]. The outcome of cardiac resynchronization therapy is determined by a number of clinical factors, and improvement of functional mitral regurgitation is currently considered as one of the mechanisms underlying the beneficial effect of the treatment.

Echocardiographic studies demonstrate that cardiac resynchronization therapy may correct the pathophysiologic determinants of functional MR. The following mechanisms are considered to mediate the clinical efficacy of CRT.

1. Restoration of the LV and papillary muscle synchronous contraction improves spatial relations and function of the subvalvular apparatus and the mitral valve itself (a decrease in mitral valve tethering force); the effect is specific for this therapeutic method [52, 53].
2. Improved coordination of LV wall contraction and resultant improvement of LV ejection function contribute to an increase in transmitral pressure gradient (greater mitral valve closing force); the effect is specific for this therapeutic method [54, 55].
3. Remote reverse remodeling of the LV with the reduction of LV volume and sphericity induce favorable changes in the geometry of mitral valve apparatus (a decrease in tethering force) and contribute to further improvement in LV systolic function (an increase in mitral valve closing force); the effect is not specific for this therapeutic method and particularly pronounced at the later phase of CRT [53, 55–57].
4. The effect of cardiac resynchronization therapy on mitral valve annular size and function (through the recoordination of contraction in LV basal segments and then through reverse remodeling of the LV) is uncertain [52, 53].

5. Optimization of atrioventricular delay with the restoration of proper timing for atrioventricular synchrony/atrioventricular relaxation contributes to generation of an adequate transmitral pressure gradient during the cardiac cycle and eliminates diastolic MR (if present); this effect is only partially specific for this therapeutic method [58].

5.1. Biphasic response of functional mitral regurgitation to cardiac resynchronization therapy

The improvement of functional MR after the use of cardiac resynchronization therapy has two phases:

1. Immediate, short-term functional MR reduction occurring directly after the implantation of a CRT device. The effect manifests as better-coordinated contraction of the papillary muscle-bearing segment (diminished tethering force) and improvement of LV ejection function (an increase in transmitral pressure gradient—LV dp/dt , which represents the mitral valve closing force) [52–54]. CRT contributes primarily to a decrease in early-systolic MR [59, 60].
2. Late, long-term functional MR reduction occurring weeks to months after the implantation of a CRT device. This phase manifests primarily as reverse remodeling of the LV. A decrease in LV volume and sphericity induces favorable geometric changes in mitral valve apparatus, with the reduction of tethering force. The improvement of LV systolic function is reflected by an increase in closing force [53, 55, 57]. Attenuation of both resting and exercise-induced functional MR usually can be observed in this phase, along with the improvement of cardiopulmonary performance [61].

In fact, the two phases of functional MR improvement may be less distinct. LV reverse remodeling can occur relatively early [10]. Subacute improvement in systolic shape of the LV (lesser sphericity) and subvalvular traction after CRT implementation are also probably related to an increase in LV longitudinal function [56].

Effective CRT reduces the transmitral regurgitant volume in about 40% of patients immediately and in the next 20% of them at a later stage [53]. The sequence of functional MR improvement may depend on a pattern of baseline dyssynchrony. Early and late responders may show a similar extent of LV dyssynchrony; however, the site of latest activation in early responders is mostly inferior or posterior (adjacent to the posterior papillary muscle), whereas in late responders, the latest activation occurs primarily in the lateral wall [53]. Late responders may also show acute improvement in LV end-systolic volume, presumably as an effect of re-coordinated and, hence, more effective LV contraction. Acting through the mechanisms described above, CRT can attenuate moderate-to-severe functional mitral regurgitation to a clinically non-significant MR in about one-third of heart failure patients. Published data about the association between baseline functional MR and response to CRT are ambiguous [8, 62–64]. The post-CRT improvement of functional MR may be relatively more frequent in patients with greater severity of mitral regurgitation at the baseline. Moreover, an acute or subacute attenuation of functional MR is a predictor of further improvement [8]. Lack of improvement in functional MR in response to CRT is associated with worse prognosis (unfavorable profile of clinical evolution, higher incidence of arrhythmic events and lesser occurrence of LV reverse remodeling [62, 65]). This raises a question about the predictors of functional MR response to CRT.

5.2. Predictors of functional mitral regurgitation improvement in response to cardiac resynchronization therapy

Despite appropriate selection of candidates for CRT, not all of them respond to the treatment. The mechanisms responsible for post-CRT improvement in functional MR are complex. Although QRS duration is the main determinant of primary electrical dyssynchrony and a primary criterion considered during selection of patients for CRT, it is not a good predictor of response to the treatment [42, 43]. Aside from dyssynchrony, the post-CRT improvement in functional MR may also depend on other factors, such as myocardial viability, presence of scar/fibrosis and the extent of LV remodeling at the baseline [10, 66, 67].

Many echocardiographic measures of dyssynchrony do not confirm their value as the predictors of CRT outcomes [39–41]. Inter-ventricular mechanical delay (IVMD, the time difference between right ventricular and left ventricular ejection, determined as the time elapsed since the onset of the QRS to the onset of left ventricular vs. right ventricular ejection, usually measured using pulsed Doppler flow) seems to be a simple and reproducible parameter of dyssynchrony, correlating well with the response to CRT, either LV reverse remodeling or functional MR improvement [10, 41, 68, 69]. Also, speckle-tracking radial strain imaging (time difference in peak septal to posterior wall strain) appears as a relatively simple measure of dyssynchrony, having established a predictive value with regard to CRT outcome [67]. There is no unambiguous evidence regarding the site of the latest activation as an independent predictor of the improvement in functional MR [10, 53]. Myocardial viability (in heart failure with ischemic etiology) and contractile reserve (in non-ischemic cardiomyopathy) are important determinants of CRT effectiveness in terms of functional MR improvement [10, 70–73]. The outcome of CRT may be also associated with the location of contractile reserve (particularly in relation to the papillary muscle-bearing segments and to the paced LV region), as well as with the size of the contractile reserve area [10, 66, 72, 73]. The importance of discordant LV lead position and myocardial scar, especially extensive scar burden, as the predictors of CRT outcomes, is documented [74, 75]. The potential role of myocardial fibrosis stimulates research on biochemical predictors of CRT responses (among them on galactin-3, a protein involved in fibrogenesis) [76].

5.3. Functional mitral regurgitation improvement and left ventricular reverse remodeling in response to CRT

The change in LV end-diastolic volume after the use of cardiac resynchronization therapy proved to be the most powerful independent predictor of death [77]. CRT effectively reversed LV remodeling, both in patients with moderate-to-severe heart failure (NYHA III/IV class) and in individuals with mild heart failure (NYHA I/II class) [49, 50]. The response to CRT may be influenced by the presence of functional mitral regurgitation prior to the implantation of a CRT device and by its persistence despite the treatment. Patients, who do not respond to CRT, present with a significant functional MR more often than the responders [78]. On the other hand, an improvement in pre-existing functional MR contributes to LV reverse remodeling during follow-up after the implantation of a CRT device [60]. The incidence of reverse remodeling, defined as an improvement in LVEF and forward stroke volume, is the highest in patients who show a reduction of total functional MR, intermediate in individuals with mild functional MR or lack thereof at the baseline and the lowest in

persons who do not show an improvement in total functional MR after 3 months of post-CRT follow-up [60]. Correlation between clinical and echocardiographic indices of post-CTR improvement is rather weak [10, 77]. However, the direction and magnitude of LV reverse remodeling correlate with survival, and a 1-year mortality after CRT implementation is predicted by echocardiographic parameters, rather than by clinical indices [77].

Finally, volumetric limitation for functional MR improvement in response to cardiac resynchronization therapy needs to be emphasized. Not only irreversibly damaged ischemic myocytes respond less to CRT, the post-CRT improvement in functional MR is also less likely in patients who present with greater degree of LV dilatation at the baseline. Lesser baseline LV diameters (end-diastolic and end-systolic) and volumes are the independent predictors of functional MR improvement in response to CRT [10, 67, 79–81]. The cut-off value for LV end-diastolic dimension is close to 75 mm [10, 82] and for LV end-systolic dimension index 29 mm/m² [67]. Non-responders present a significantly higher baseline LV dilatation. CRT may be insufficient to overcome poor natural history of systolic heart failure but may slow down its progression. The effectiveness of all currently available therapeutic options is limited, and critical enlargement of the left ventricle may trigger the previously mentioned vicious circle of self-perpetuating LV dilatation and functional mitral regurgitation [10, 83, 84].

6. Management of patients with persistent significant functional mitral regurgitation after the use of CRT

Therapeutic targets in patients with functional MR include attenuation of symptoms, lesser number of heart failure hospitalizations, better quality of life and, potentially, survival. At present, the most effective therapies of functional MR are aimed at the underlying LV dysfunction. Therefore, as the first step, optimal medical therapy according to the guidelines for the management of heart failure should be used [36]. As the second step, whenever appropriate, CRT should be implemented in line with the respective guidelines [35, 36]. In patients who remain symptomatic despite optimal medical therapy and CRT (if indicated), mitral valve intervention (surgical or transcatheter repair) should be considered; however, there is no evidence that a reduction of functional MR improves survival [13]. Moreover, the surgery has never clearly been demonstrated to alter the natural history of the primary disease (dilated cardiomyopathy) [85]. Limited empirical data contribute to a lower level of evidence for management recommendations, highlighting the importance of decisions made by the Heart Team. The multidisciplinary Heart Team consisting of imaging experts, heart failure and electrophysiology specialists, interventional cardiologists, and cardiac surgeons should try to reach a consensus on appropriate care. Not only the feasibility of the procedure but also comorbidities, the level of surgical risk, and surgeon experience should be considered [13]. In patients undergoing revascularization, the evaluation and decision to treat (or not to treat) ischemic MR should be made prior to surgery. There is an overall agreement that severe functional MR should be addressed at the time of coronary artery bypass grafting (CABG). The management of moderate functional MR in patients undergoing CABG still raises controversies [86]. The thresholds of functional MR severity are also a matter of debate (as stated earlier). Surgical options in patients with functional MR include mitral valve repair and replacement.

Mitral valve deformation	Coaptation distance ≥ 1 cm Tenting area $> 2.5\text{--}3$ cm ² Complex jets originating centrally and posteromedially Posterolateral angle $>45^\circ$ (high posterior leaflet tethering)
Local LV remodeling	Interpapillary muscle distance >20 mm Posterior papillary-fibrosa distance >40 mm Lateral wall motion abnormality
Global LV remodeling	EDD >65 mm, ESD >51 mm (ESV >140 mL) (low likelihood of reverse LV remodeling after repair and poor long-term outcome) Systolic sphericity index >0.7

EDD, end-diastolic diameter; ESD, end-systolic diameter; ESV, end-systolic volume; LV, left ventricle.

Table 2. Unfavorable TTE characteristics for mitral valve repair in secondary MR [88].

Mechanical LV-assisted devices and heart transplantation should be considered in the most advanced stage of heart failure.

The controversies regarding an optimal surgical approach should be emphasized [87]. After surgical annuloplasty (undersized complete ring to restore leaflet coaptation), residual or recurrent functional MR is frequently observed (in approximately one-third of the cases) [88]. Valve-sparing mitral valve replacement techniques (leaving the leaflet and subvalvular apparatus intact to preserve the LV function) should be considered in patients with echocardiographic predictors of repair failure (**Table 2**) [88]. The surgery should also be considered in heart failure patients with severe functional MR and LVEF $<30\%$ but with an option for CABG and the evidence of myocardial viability. Qualification for surgical treatment of functional MR should be restrained if concomitant revascularization is not indicated [89].

Percutaneous edge-to-edge repair (MitraClip device) for FMR is a low-risk procedure and may be considered in patients during high surgical risk, whenever feasible [90]. The treatment may attenuate symptoms, improve quality of life and promote LV reverse remodeling but is inferior to surgical methods in terms of functional MR reduction. Valve intervention is generally contraindicated in patients with LVEF $< 15\%$ [13]. Two investigational extracardiac devices, CorCap (Acorn Cardiovascular) [91] and Coapsys (Myocor, Inc., Maple Grove, Minnesota) [92], which have been used to reshape the LV and thus to reduce the degree of functional MR, remained an interesting experiment. In cases of more advanced LV dysfunction (LVEF $\leq 30\%$) with no option for CABG, the Heart Team should choose between a palliative treatment of functional MR (surgical or transcatheter procedures, ventricular assist devices, heart transplantation) and a conservative therapy, after careful individual appraisal of the patient [13].

7. Conclusion

Irrespective of heart failure etiology, functional mitral regurgitation has a significant unfavorable impact on prognosis. The benefits of surgical treatment in functional mitral regurgitation

are unclear and thus, resynchronization therapy remains a valuable option in eligible patients. Indications for such treatment should be considered as early as possible, before the development of a severe left ventricular dilatation, a predictor of failure in resynchronization therapy.

Acronyms and abbreviations

CABG	coronary artery bypass grafting
CRT	cardiac resynchronization therapy
EROA	effective regurgitant orifice area
HF	heart failure
LBBS	left bundle branch block
LV	left ventricle
LVEF	left ventricular ejection fraction
MR	mitral regurgitation
NYHA	New York Heart Association
PISA	proximal isovelocity surface area

Author details

Barbara Brzezińska^{1*} and Krystyna Łoboz-Grudziń^{1,2}

*Address all correspondence to: be.brzezinska@gmail.com

1 Department of Cardiology, T. Marciniak Hospital, Wrocław, Poland

2 Faculty of Health Science, Wrocław Medical University, Poland

References

- [1] Lamas GA, Mitchell GF, Flaker GC, Smith SC Jr, Gersh BJ, Basta L, Moye L, Braunwald E, Pfeffer MA, Survival and Ventricular Enlargement Investigators. Clinical significance of mitral regurgitation after acute myocardial infarction. *Circulation*. 1997;**96**:827-833. DOI: 10.1161/01.CIR.96.3.827
- [2] Grigioni F, Enriquez-Sarano M, Zehr KJ, Bailey KR, Tajik AJ. Ischemic mitral regurgitation: Long-term outcome and prognostic implications with quantitative Doppler assessment. *Circulation*. 2001;**103**:1759-1764. DOI: 10.1161/01.CIR.103.13.1759

- [3] Trichon BH, Felker GM, Shaw LK, et al. Relation of frequency and severity of mitral regurgitation to survival among patients with left ventricular systolic dysfunction and heart failure. *The American Journal of Cardiology*. 2003;**91**:538-543. DOI: 10.1016/S0002-9149(02)03301-5
- [4] Rossi A, Dini FL, Faggiano P, et al. Independent prognostic value of functional mitral regurgitation in patients with heart failure. A quantitative analysis of 1256 patients with ischemic and non-ischemic dilated cardiomyopathy. *Heart*. 2011;**97**:1675-1680. DOI: 10.1136/hrt.2011.225789
- [5] Bursi F, Enriquez-Sarano M, Nkomo VT, et al. Heart failure and death after myocardial infarction in the community. The emerging role of mitral regurgitation. *Circulation*. 2005;**111**:295-301. DOI: 10.1161/01.CIR.0000151097.30779.04
- [6] Koelling TM, Aaronson KD, Cody RJ, Bach DS, Armstrong WF. Prognostic significance of mitral regurgitation and tricuspid regurgitation in patients with left ventricular systolic dysfunction. *American Heart Journal*. 2002;**144**:524-529. DOI: 10/1067/mhj.2002.12357
- [7] van Bommel RJ, Marsan NA, Delgado V, et al. Cardiac resynchronization therapy as a therapeutic option in patients with moderate-severe functional mitral regurgitation and high operative risk. *Circulation*. 2011;**124**:912-919. DOI: 10.1161/CIRCULATIONAHA.110.009803
- [8] Di Biase L, Auricchio A, Mohanty P, et al. Impact of cardiac resynchronization therapy on the severity of mitral regurgitation. *Europace*. 2011;**13**:829-838. DOI: 10.1093/europace/eur047
- [9] Cabrera-Bueno F, Molina-Mora MJ, Alzueta J, et al. Persistence of secondary mitral regurgitation and response to cardiac resynchronization therapy. *European Journal of Echocardiography*. 2010;**11**:131-137. DOI: 10.1093/ejehocard/jep184
- [10] Brzezińska B, Łoboz-Grudzień K, Wita K, et al. Predictors of functional mitral regurgitation improvement during a short-term follow-up after cardiac resynchronization therapy. *Kardiologia Polska*. 2016;**74**(7):665-673. DOI: 10.5603/KP.a2016.0005
- [11] Boriani G, Gasparini M, Landolina M, et al. Impact of mitral regurgitation on the outcome of patients treated with CRT-D: Data from the InSync ICD Italian Registry. *Pace*. 2012;**35**:146-154. DOI: 10.1111/j.1540-8159.2011.03280.x
- [12] Upadhyay GA, Chatterjee NA, Kandala J, et al. Assessing mitral regurgitation in prediction of clinical outcome after cardiac resynchronization therapy. *Heart Rhythm*. 2015;**12**(6):1201-1208. DOI: 10.1016/j.hrthm.2015.02.022
- [13] Baumgartner H, Falk V, Bax JJ, et al. 2017 ESC/EACTS Guidelines for the management of valvular heart disease: The Task Force for the management of valvular heart disease of the European Society of Cardiology (ESC) and the European Association for Cardio-Thoracic Surgery (EACTS). *European Heart Journal*. 2017;**38**:2739-2791. DOI: 10.1093/eurheartj/ehx391
- [14] Grayburn PA, Weissman NJ, Zamorano JL. Quantification of mitral regurgitation. *Circulation*. 2012;**126**:2005-2017. DOI: 10.1016/j.amjcard.2013.07.047
- [15] Grayburn PA, Carabello B, Hung J, et al. Defining 'severe' secondary mitral regurgitation. Emphasizing an integrated approach. *Journal of the American College of Cardiology*. 2014;**64**:2792-2780. DOI: 10.1016/j.jacc.2014.10.016

- [16] Nishimura RA, Otto CM, Bonow RO, et al. 2014 AHA/ACC guideline for the management of patients with valvular heart disease, a report of the American College of Cardiology/American Heart Association Task Force on Practice Guidelines. *Journal of the American College of Cardiology*. 2014;**63**:e57-e185. DOI: 10.1016/j.jacc.2014.02.536
- [17] Biner S, Raphique A, Rafii F, et al. Reproducibility of proximal isovelocity surface area, vena contracta, and regurgitant jet area for assessment of mitral regurgitation severity. *Journal of the American College of Cardiology*. 2010;**3**:235-243. DOI: 10.1016/j.jcmg.2009.09.029
- [18] Schwammenthal E, Chen C, Benning F, et al. Dynamics of mitral regurgitation flow and orifice area; physiologic application of the proximal flow convergence method: Clinical data and experimental testing. *Circulation*. 1994;**90**:307-322. DOI: 10.1161/01.CIR.90.1.307
- [19] Pierard L, Lancellotti P. The role of ischemic mitral regurgitation in the pathogenesis of acute pulmonary edema. *The New England Journal of Medicine*. 2004;**352**:1627-1634. DOI: 10.1056/NEJMoa040532
- [20] Lancellotti P, Transfontaines P, Toussaint AC, et al. Prognostic importance of exercise-induced changes in mitral regurgitation in patients with chronic ischemic left ventricular dysfunction. *Circulation*. 2003;**108**:1713-1717. DOI: 10.1161/01.CIR.0000087599.49332.05
- [21] Lancellotti P, Stainier PY, Lebois F, Pierard LA. Effect of dynamic left ventricular dyssynchrony on dynamic mitral regurgitation in patients with heart failure due to coronary artery disease. *The American Journal of Cardiology*. 2005;**96**:1304-1307. DOI: 10.1016/j.amjcard.2005.06.077
- [22] Otsuji Y, Handschumacher MD, Schwammenthal E, et al. Insight from tree-dimensional echocardiography into the mechanism of functional mitral regurgitation: Direct in vivo demonstration of altered leaflet tethering geometry. *Circulation*. 1997;**96**:1999-2008. DOI: 10.1161/01.CIR.96.6.1999
- [23] Kono T, Sabbah HN, Rosman H, et al. Left ventricular shape is the primary determinant of functional mitral regurgitation in heart failure. *Journal of the American College of Cardiology*. 1992;**20**:1594-1598. DOI: 10.1016/0735-1097(92)90455-V
- [24] Sabbah HN, Rosman H, Kono T, et al. On the mechanism of functional mitral regurgitation. *American Journal of Cardiology*. 1993;**72**:1074-1076. DOI: 10.1016/0735-1097(94)00426-Q
- [25] Kumanohoso T, Otsuji Y, Yoshifuku S, et al. Mechanism of higher incidence of ischemic mitral regurgitation in patients with inferior myocardial infarction: Quantitative analysis of left ventricular and mitral valve geometry in 103 patients with prior myocardial infarction. *The Journal of Thoracic and Cardiovascular Surgery*. 2003;**125**:135-143. DOI: 10.1067/mva.2003.78
- [26] Yiu SF, Enriquez-Sarano M, Tribouilloy C, et al. Determinants of the degree of functional mitral regurgitation in patients with systolic left ventricular dysfunction. A quantitative clinical study. *Circulation*. 2000;**102**:1400-1406. DOI: 10.1161/01.CIR.102.12.1400
- [27] Agricola E, Oppizzi M, Maisano F, et al. Echocardiographic classification of chronic ischemic mitral regurgitation caused by restricted motion according to tethering pattern. *European Journal of Echocardiography*. 2004;**5**:326-334. DOI: 10.1016/j.euje.2004.03.001

- [28] Carpentier A. Cardiac valve surgery: The "French correction." *The Journal of Thoracic and Cardiovascular Surgery*. 1983;**86**:323-337
- [29] Otsuji Y, Levine RA, Takeuchi M, et al. Mechanism of ischemic mitral regurgitation. *Journal of Cardiology*. 2008;**51**:145-156. DOI: 10.1016/j.jcc.2008.03.005
- [30] Boltwood CM, Tei C, Wong M, et al. Quantitative echocardiography of the mitral complex in dilated cardiomyopathy: The mechanism of functional mitral regurgitation. *Circulation*. 1983;**68**:498-508. DOI: 10.1161/01.CIR.68.3.498
- [31] Nof E, Glikson M, Bar-Lev D, et al. Mechanism of diastolic mitral regurgitation in candidates for cardiac resynchronization therapy. *The American Journal of Cardiology*. 2006;**97**(11):1611-1614. DOI: 10.1016/j.amjcard.2005.12.064
- [32] Gertz ZM, Raina A, Saghy L, et al. Evidence of atrial functional mitral regurgitation due to atrial fibrillation: Reversal with arrhythmia control. *Journal of the American College of Cardiology*. 2011;**58**:1474-1781. DOI: 10.1016/j.jacc.2011.06.032
- [33] Task FM, Vardas PE, Auricchio A, et al. Guidelines for cardiac pacing and cardiac resynchronization therapy: The Task Force for Cardiac Pacing and Cardiac Resynchronization Therapy of the European Society of Cardiology. Developed in collaboration with the European Heart Rhythm Association. *European Heart Journal*. 2007;**28**:2256-2295. DOI: 10.1093/eurheartj/ehm305
- [34] Smiseth OA, Russell K, Skulstad H. The role of echocardiography in quantification of left ventricular dyssynchrony: State of the art and future directions. *European Heart Journal—Cardiovascular Imaging*. 2012;**13**:61-68. DOI: 10.1093/ejehocard/jer243
- [35] Brignole M, Auricchio A, Baron-Esquivias G, et al. ESC Guidelines on cardiac pacing and cardiac resynchronization therapy. The Task Force on cardiac pacing and resynchronization therapy of the European Society of Cardiology (ESC). Developed in collaboration with the European Heart Rhythm Association. *European Heart Journal*. 2013;**34**:2281-2329. DOI: 10.1093/eurheartj/ehf150
- [36] Ponikowski P, Voors AA, Anker DA, et al. ESC Guidelines for the diagnosis and treatment of acute and chronic heart failure. The Task Force for the diagnosis and treatment of acute and chronic heart failure of the European Society of Cardiology (ESC). Developed with the special contribution of the heart failure association (HFA) of the ESC. *European Heart Journal*. 2016;**37**:2129-2200. DOI: 10.1093/eurheartj/ehw128
- [37] D'Andrea A, Mele D, Nistri S, et al. The prognostic impact of dynamic ventricular dyssynchrony in patients with idiopathic dilated cardiomyopathy and narrow QRS. *European Heart Journal. Cardiovascular Imaging*. 2013;**14**:183-189. DOI: 10.1093/ehjci/jes154
- [38] Ruschitzka F, Abraham WT, Singh JP, et al. EchoCR TSG. Cardiac-resynchronization therapy in heart failure with narrow QRS complex. *The New England Journal of Medicine*. 2013;**369**:1395-1405. DOI: 10.1056/NEJMoa1306687
- [39] Hawkins NM, Petrie MC, Burgess MI, et al. Selecting patients for cardiac resynchronization therapy: The fallacy of echocardiographic dyssynchrony. *Journal of the American College of Cardiology*. 2009;**53**:1944-1959. DOI: 10.1016/j.jacc.2008.11.062

- [40] Fornwalt BK, Sprague WW, BeDell P, et al. Agreement is poor among current criteria used to define response to cardiac resynchronization therapy. *Circulation*. 2010;**121**:1985-1991. DOI: 10.1161/CIRCULATIONAHA.109.910778
- [41] Chung ES, Leon AR, Tavazzi L, et al. Results of the predictors of response to CRT (PROSPECT) Trial. *Circulation*. 2008;**117**:2608-2616. DOI: 10.1161/CIRCULATIONAHA.107.74312
- [42] Mollema SA, Bleeker GB, van der Wall EE, et al. Usefulness of QRS duration to predict response to cardiac resynchronization therapy in patients with end-stage heart failure. *The American Journal of Cardiology*. 2007;**100**:1665-1670. DOI: 10.1016/j.amjcard.2007.06.071
- [43] Gervais R, Leclercq C, Shankar A, et al. Surface electrocardiogram to predict outcome in candidates for cardiac resynchronization therapy: A sub-analysis of the CARE-HF trial. *European Journal of Heart Failure*. 2009;**11**:699-705. DOI: 10.1093/eurjhf/hfp074
- [44] Erlebacher JA, Barbarash S. Intraventricular conduction delay and functional mitral regurgitation. *The American Journal of Cardiology*. 2001;**88**(A7):83-86. DOI: 10.1016/S0002-9149(01)01595-8
- [45] Agricola E, Oppizzi M, Galderisi M, et al. Role of regional mechanical dyssynchrony as a determinant of functional mitral regurgitation in patients with ventricular systolic dysfunction. *Heart*. 2006;**92**:1390-1395. DOI: 10.1136/hrt.2005.082115
- [46] Nishimura RA, Hayes DL, Holmes DR Jr, et al. Mechanism of hemodynamic improvement by dual-chamber pacing for severe left ventricular dysfunction: An acute Doppler and catheterization hemodynamic study. *Journal of the American College of Cardiology*. 1995;**25**:281-288. DOI: 10.1016/0735-1097(94)00419-Q
- [47] Auricchio A, Stellbrink C, Block M, et al. Effect of pacing chamber and atrioventricular delay on acute systolic function of paced patients with congestive heart failure. *Circulation*. 1999;**99**:2993-3001. DOI: 10.1161/01.CIR.99.23.2993
- [48] Nelson GS, Curry CW, Wyman BT, et al. Predictors of systolic augmentation from left ventricular preexcitation in patients with dilated cardiomyopathy and intraventricular conduction delay. *Circulation*. 2000;**101**:2703-2709. DOI: 10.1161/01.CIR.101.23.2703
- [49] St John Sutton MG, Plappert T, Abraham WT, et al. Effect of cardiac resynchronization therapy on left ventricular size and function in chronic heart failure. The Multicenter InSync Randomized Clinical Evaluation (MIRACLE) Study Group. *Circulation*. 2003;**107**:1985-1990. DOI: 10.1161/01.CIR.0000065226.24159.E9
- [50] Linde C, Abraham WT, Gold MR, et al. Randomized trial of cardiac resynchronization therapy in mildly symptomatic heart failure patients and in asymptomatic patients with left ventricular dysfunction and previous heart failure symptoms. The REVERSE study group. *Journal of the American College of Cardiology*. 2008;**52**:1834-1843. DOI: 10.1016/j.jacc.2008.08.027
- [51] Cazeau S, Leclercq C, Lavergne T, et al. Effects of multisite biventricular pacing in patients with heart failure and intraventricular conduction delay. *The New England Journal of Medicine*. 2001;**344**:873-880. DOI: 10.1056/NEJM200103223441202

- [52] Kanzaki H, Bazaz R, Schwartzman D, et al. A mechanism for immediate reduction in mitral regurgitation after myocardial infarction. *Journal of the American College of Cardiology*. 2004;**44**:1619-1625. DOI: 10.1016/j.jacc.2004.07.036
- [53] Ypenburg C, Lancellotti P, Tops LF, et al. Mechanism of improvement in mitral regurgitation after cardiac resynchronization therapy. *European Heart Journal*. 2008;**29**:757-765. DOI: 10.1093/eurheartj/ehn063
- [54] Breithardt OA, Sinha AM, Schwammenthal E, et al. Acute effects of cardiac resynchronization therapy on functional mitral regurgitation in advanced systolic heart failure. *Journal of the American College of Cardiology*. 2003;**41**:765-770. DOI: 10.1016/S0735-1097(02)02937-6
- [55] Solis J, McCarthy D, Levine RA, et al. Mechanism of decrease in mitral regurgitation after cardiac resynchronization therapy: Optimization of the force-balance relationship. *Circulation. Cardiovascular Imaging*. 2009;**2**:444-450. DOI: 10.1161/CIRCIMAGIN.108.823732
- [56] Vinereanu D, Turner M, Bleasdale R, et al. Mechanisms of reduction of mitral regurgitation by cardiac resynchronization therapy. *Journal of the American Society of Echocardiography*. 2007;**20**:54-62. DOI: 10.1016/j.echo.2006.07.002
- [57] Porciani MC, Macioce R, Demarchi G, et al. Effects of cardiac resynchronization therapy on the mechanisms underlying functional mitral regurgitation in congestive heart failure. *European Journal of Echocardiography*. 2006;**7**:31-39. DOI: 10.1016/j.euje.2005.03.008
- [58] Bordachar P, Garrigue S, Laffite S, et al. Intraventricular and intra-left ventricular electromechanical delays in right ventricular paced patients with heart failure: Implications for upgrading to biventricular stimulation. *Heart*. 2003;**89**:1401-1405. DOI: 10.1136/heart.89.12.1401
- [59] Fukuda S, Grimm R, Song JM, et al. Electric conduction disturbance effects on dynamic changes of functional mitral regurgitation. *Journal of the American College of Cardiology*. 2005;**46**:2270-2276. DOI: 10.1016/j.jacc.2005.08.037
- [60] Liang YJ, Zhang Q, Fung JWH, et al. Impact of reduction in early- and late-systolic functional mitral regurgitation on reverse remodeling after cardiac resynchronization therapy. *European Heart Journal*. 2010;**31**:2359-2368. DOI: 10.1093/eurheartj/ehq134
- [61] Madaric J, Vanderheyden M, Van Laethem C, et al. Early and late effect of cardiac resynchronization therapy on exercise-induced mitral regurgitation: Relationship with left ventricular dyssynchrony, remodeling and cardiopulmonary performance. *European Heart Journal*. 2007;**28**:2134-2141. DOI: 10.1093/eurheartj/ehm126
- [62] Cabrera-Bueno F, Pinilla JMG, Hernandez JP, et al. Repercussion of functional mitral regurgitation on reverse remodeling in cardiac resynchronization therapy. *Europace*. 2007;**9**:757-761. DOI: 10.1093/europace/eum122
- [63] Van Bommel RJ, Borleffs CJW, Ypenburg C, et al. Morbidity and mortality in heart failure patients treated with cardiac resynchronization therapy: Influence of pre-implantation characteristics on long-term outcome. *European Heart Journal*. 2010;**31**:2783-2790. DOI: 10.1093/eurheartj/ehq252

- [64] Verhaert D, Popovic ZB, De S, et al. Impact of mitral regurgitation on reverse remodeling and outcome in patients undergoing cardiac resynchronization therapy. *Circulation. Cardiovascular Imaging*. 2012;**5**:21-26. DOI: 10.1161/CIRCIMAGIN.111.966580
- [65] Kwon DH, Kusunose K, Obuchowski NA, et al. Predictors and prognostic impact of progressive ischemic mitral regurgitation in patients with advanced ischemic cardiomyopathy—A multimodality study. *Circulation. Cardiovascular Imaging*. 2016;**e004577**:9. DOI: 10.1161/CIRCIMAGIN.115.004577
- [66] Senechal M, Lancellotti P, Magne J, et al. Impact of mitral regurgitation and myocardial viability on left ventricular reverse remodeling after cardiac resynchronization therapy in patients with ischemic cardiomyopathy. *The American Journal of Cardiology*. 2010;**106**:31-37. DOI: 10.1016/j.amjcard.2010.02.012
- [67] Onishi T, Onishi T, Marek JJ, et al. Mechanistic features associated with improvement in mitral regurgitation after cardiac resynchronization therapy and their relation to long-term patient outcome. *Circulation. Heart Failure*. 2013;**6**:685-693. DOI: 10.1161/CIRCHEARTFAILURE.112.000112
- [68] Gorcsan IIIJ, Abraham T, Agler DA, et al. Echocardiography for cardiac resynchronization therapy: Recommendations for performance and reporting—A report from American Society of Echocardiography Dyssynchrony Writing Group endorsed by the Heart Rhythm Society. *Journal of American Society of Echocardiography*. 2008;**21**(3): 191-213. DOI: 10.1016/j.echo.2008.01.003
- [69] Stockburger M, Fateh-Moghadam S, Nitardy A, et al. Baseline Doppler parameters are useful predictors of chronic left ventricular reduction in size by cardiac resynchronization therapy. *Europace*. 2008;**10**:69-74. DOI: 10.1093/europace/eum269
- [70] Altman R, McCarthy D, Chen-Tournoux A, et al. Usefulness of low-dose dobutamine echocardiography to predict response and outcome in patients undergoing cardiac resynchronization therapy. *The American Journal of Cardiology*. 2011;**108**:253-257. DOI: 10.1111/j.1540-8175.2009.00962.x
- [71] Gasparini M, Muto C, Iacopino S, et al. Low-dose dobutamine test associated with interventricular dyssynchrony: A useful tool to identify cardiac resynchronization therapy responders: Data from the LODO-CRT phase 2 study. *American Heart Journal*. 2012;**163**:422-429
- [72] Lim P, Bars C, Mitchell-Heggs L, et al. Importance of contractile reserve for CRT. *Europace*. 2007;**9**:739-743. DOI: 10.1093/europace/eum117
- [73] Mizia-Stec K, Wita K, Mizia A, et al. Preserved contractile reserve in a dobutamine test for the prediction of a response to resynchronization therapy in ischaemic and non-ischaemic cardiomyopathy: A multicenter ViaCRT study. *International Journal of Cardiology*. 2014;**172**:476-477. DOI: 10.1016/j.ijcard.2013.12.204
- [74] Delgado V, van Bommel RJ, Bertni M, et al. Relative merits of left ventricular dyssynchrony, left ventricular lead position, and myocardial scar to predict long-term survival of ischemic heart failure patients undergoing cardiac resynchronization therapy. *Circulation*. 2011;**123**:70-78. DOI: 10.1161/CIRCULATIONAHA.110.945345

- [75] Adelstein EC, Tanaka H, Soman P, et al. Impact of scar burden by single-photon emission computed tomography myocardial perfusion imaging on patients outcomes following cardiac resynchronization therapy. *European Heart Journal*. 2011;**32**:93-103. DOI: 10.1093/eurheart/ehq389
- [76] Beaudoin J, Singh JP, Szymonifka J, et al. Novel heart failure biomarkers predict improvement of mitral regurgitation in patients receiving cardiac resynchronization therapy—The BIOCRT Study. *The Canadian Journal of Cardiology*. 2016;**32**(12):1478-1484. DOI: 10.1016/j.cjca.2016.05.013
- [77] Yu CM, Bleeker GB, Fung JW, et al. Left ventricular reverse remodeling but not clinical improvement predicts long-term survival after cardiac resynchronization therapy. *Circulation*. 2005;**112**:1580-1586. DOI: 10.1161/CIRCULATIONAHA.105.538272
- [78] Cleland JG, Daubert JC, Erdmann E, et al. The effect of cardiac resynchronization on morbidity and mortality in heart failure. *The New England Journal of Medicine*. 2005;**352**:1539-1549. DOI: 10.1056/NEJMoa050496
- [79] Stellbrink C, Breithardt OA, Franke A, et al. Impact of cardiac resynchronization therapy using hemodynamically optimized pacing on left ventricular remodeling in patients with congestive heart failure and ventricular conduction disturbances. *Journal of the American College of Cardiology*. 2001;**38**:1957-1965. DOI: 10.1016/S0735-1097(01)01637-0
- [80] Carluccio E, Biagioli P, Alunni G, et al. Presence of extensive LV remodeling limits the benefits of CRT in patients with intraventricular dyssynchrony. *Journal of the American College of Cardiology*. 2011;**4**:1067-1076. DOI: 10.1016/j.jcmg.2011.07.006
- [81] Tayal B, Sogaard P, Delgado-Montero A, et al. Interaction of left ventricular remodeling and regional dyssynchrony on long-term prognosis after cardiac resynchronization therapy. *Journal of the American Society of Echocardiography*. 2017;**30**:244-250. DOI: 10.1016/j.echo.2016.11.010
- [82] Diaz-Infante E, Mont L, Leal J, et al. Predictors of lack of response to resynchronization therapy. *The American Journal of Cardiology*. 2005;**95**:1436-1440. DOI: 10.1016/j.amjcard.2005.02.009
- [83] Brzezińska B, Łoboz-Grudzień K, Sokalski L. Patterns of post-MI left ventricular volume changes: Clinical implications. *Kardiologia Polska*. 2007;**65**:1190-1198
- [84] Cleland JG, Tavazzi L, Daubert JC, et al. CRT. Cardiac resynchronization therapy. Are modern myths preventing appropriate use? *Journal of the American College of Cardiology*. 2009;**53**:608-611. DOI: 10.1016/j.jacc.2008.10.040
- [85] Calafiore AM, Iaco AL, Gallina S, et al. Surgical treatment of functional mitral regurgitation. *International Journal of Cardiology*. 2013;**166**:559-571. DOI: 10.1016/j.ijcard.2012.05.027
- [86] Michler RE, Smith PK, Parides MK, et al. Two-years outcomes of surgical treatment of moderate ischemic mitral regurgitation. *The New England Journal of Medicine*. 2016;**374**:1932-1941. DOI: 10.1056/NEJMoa1602003

- [87] Acker MA, Parides MK, Perrault LP, et al. Mitral-valve repair versus replacement for severe ischemic mitral regurgitation. *The New England Journal of Medicine*. 2014;**370**: 23-32. DOI: 10.1056/NEJMoa1312808
- [88] Lancellotti P, Tribouilloy C, Hagendorff A, et al. Scientific Document Committee of the European Association of Cardiovascular Imaging. Recommendations for echocardiographic assessment of native valvular regurgitation: An executive summary from European Association of Cardiovascular Imaging. *European Heart Journal. Cardiovascular Imaging*. 2013;**14**:1611-1644. DOI: 10.1093/ehjci/jet105
- [89] Wu AH, Aaronson KD, Bolling SF, Pagani FD, et al. Impact of mitral valve annuloplasty on mortality risk in patients with mitral regurgitation and left ventricular systolic dysfunction. *Journal of the American College of Cardiology*. 2005;**45**:381-387. DOI: 10.1016/j.jacc.2004.09.073
- [90] Maisano F, Franzen O, Baldus S, et al. Percutaneous mitral valve interventions in the real world: Early and 1-year results from the ACCESS-EU, a prospective, multicenter, nonrandomized postapproval study of the MitraClip therapy in Europe. *Journal of the American College of Cardiology*. 2013;**62**(12):1052-1061. DOI: 10.1016/j.jacc.2013.02.094
- [91] Mann DL, Kubo SH, Sabbah HN, et al. Beneficial effects of the CorCap cardiac support device: Five-year results from the Acorn Trial. *The Journal of Thoracic and Cardiovascular Surgery*. 2012;**143**:1036-1042. DOI: 10.1016/j.jtcvs.2011.06.014
- [92] Grossi EA, Patel N, Woo J, Goldberg JD, et al. Outcomes of the RESTOR-MV trial (Randomized Evaluation of a Surgical Treatment for Off-Pump Repair of the Mitral Valve). *Journal of the American College of Cardiology*. 2010;**56**:1984-1993. DOI: 10.1016/j.jacc.2010.06.051

