

## Chapter

# Periodic EEG Patterns in the Intensive Care Unit (ICU): Definition, Recognition and Clinical Significance

*Boulenouar Mesraoua, Musab Abdalhalim Ali, Rola Hosni Mohamed Hashem Khodair, Yazan Nofal, Dirk Theophiel O. Deleu, Hassan Jasim Al Hail, Osama Robin Elalamy, Gayane Melikyan, Covanis Athanasios and Ali Akbar Asadi-Pooya*

## Abstract

Periodic electroencephalographic (EEG) patterns are frequently recorded during ICU EEG monitoring in patients with altered mental status; these EEG features represent electrical discharges, ictal in appearance, occurring at regular intervals. They are known as lateralized periodic discharges (LPDs), bilateral independent periodic discharges (BIPDs), generalized periodic discharges (GPDs), continuous 2/s GPDs with triphasic morphology or triphasic waves (TWs) and Stimulus Induced Evolving Lateralized Rhythmic delta activity or Si-Evolving LRDA (previously SIRPIDS); other periodic, rhythmic patterns are Occasional frontally predominant brief 2/s GRDA (FIRDA previously), Lateralized rhythmic delta activity (LRDA) and Brief potentially ictal rhythmic discharges or B (I)RDs. The role of most (not all) of these EEG patterns is controversial; there is no consensus on which patterns are associated with ongoing seizure injury, which patterns need to be treated, and how aggressively they should be treated. Many authors consider these patterns as an unstable state on an ictal-interictal EEG continuum; the aim of the present chapter is to gain knowledge of these EEG features, show their association with known neurologic pathologies/syndromes and finally how to manage them.

**Keywords:** ICU, periodic EEG patterns, altered mental status, treatment

## 1. Introduction

Periodic electroencephalographic (EEG) patterns are frequently recorded during ICU EEG monitoring in patients with Altered Mental Status (AMS) [1]; these controversial EEG patterns consist of discharges usually epileptiform in appearance, which occur at regular intervals, in critically ill patients. They are commonly classified as periodic lateralized discharges (PLDs), bilateral independent PLDs or BIPLDs, generalized periodic discharges (GPDs) and triphasic waves. Stimulus-induced rhythmic,

periodic or ictal discharges (SIRPIDs) are peculiar EEG patterns, which may be present as periodic discharges. Other periodic, rhythmic patterns are Occasional frontally predominant brief 2/s GRDA (FIRDA previously), Lateralized rhythmic delta activity (LRDA) and Brief potentially ictal rhythmic discharges or B (I)RDs.

There is still no consensus on which specific EEG features are associated with ongoing neuronal injury, which ones should be treated and how aggressively they should be treated [2]. In critically ill patients, a high index of suspicion of ongoing status epilepticus (SE), particularly non-convulsive epileptic status (NCSE) should alert the intensive care team and the neurologist, in the presence of these EEG periodic discharges, especially in patients with impaired consciousness, prompting the use of antiseizure medications [3, 4]. In addition, the occurrence of such EEG features may be in favor of cerebral impairment, acute or subacute [4, 5].

The aim of this study is to make a review of these periodic EEG features, emphasizing the importance of their recognition and clinical significance. Their clinical significance is uncertain, it is related to a variety of etiologies, and many authors suggest that these patterns are unequivocally epileptogenic in some cases. Their recognition and classification are important to establish a correlation between clinical, neurological, neuroimaging data with the EEG results.

## 2. Historical note

There is still a scientific debate regarding these EEG features. Until recently, there was no uniformly accepted nomenclature for those frequently encountered ICU EEG abnormalities such as periodic epileptiform discharges, fluctuating rhythmic patterns and combinations.

Based on these questions, the American Clinical Neurophysiology Society (ACNS) recently proposed new terminology for these controversial EEG patterns [6, 7] (**Table 1**); terms such as “triphasic waves,” which implies for many clinicians a metabolic encephalopathy was eliminated; in addition, the use of “ictal,” “interictal”

New Terms for Older Terms	
OLD Term	NEW Term
Triphasic waves, most of record	= continuous 2/s GPDs (with triphasic morphology)
PLEDs	= LPDs
BIPLEDs	= BIPDs
GPEDs/PEDs	= GPDs
FIRDA	= Occasional frontally predominant brief 2/s GRDA (if 1–10% of record)
PLEDs+	=LPDs+
SIRPIDs* w/ focal evolving RDA	=SI-Evolving LRDA
Lateralized seizure, delta frequency	= Evolving LRDA
Semirhythmic delta	= Quasi-RDA
<b>SIRPIDs: stimulus-induced rhythmic, periodic or ictal discharges</b>	
<i>PLEDs: Periodic Lateralized Epileptiform Discharges; LPDs: Lateralized Periodic Discharges; BIPLEDs: Bilateral Independant Periodic Lateralized Epileptiform Discharges; BIPDs: Bilateral Independant Periodic Discharges; GPEDs/PEDs: Generalized Periodic Epileptiform Discharges/Periodic Epileptiform Discharges; FIRDA: Frontal Intermittent Rhythmic Delta Activity; LRDA: Lateralized rhythmic Delta Activity; SIRPIDs: Stimulus-induced rhythmic, periodic or ictal discharges</i>	

**Table 1.**  
ICU periodic EEG patterns: Old vs. new terminology [6].

and “epileptiform” for the equivocal patterns was avoided; these EEG features are now termed Periodic Lateralized Discharges (PLDs), (formerly Periodic lateralized Epileptiform Discharges or PLEDs), Bilateral independent Periodic Discharges or BIPLDs, (formerly Bilateral independent Periodic Lateralized Epileptiform Discharges or BIPLEDs), Generalized Periodic Discharges (GPDs), formerly Generalized Periodic Epileptiform Discharges (GPEDs) and continuous GPD 2 / s with triphasic morphology) (formerly Triphasic Waves or TWs). SI-Evolving LRDA, Stimulus-induced Lateralized Rhythmic Delta Activity (formerly stimulus-induced rhythmic, periodic or ictal discharges or SIRPIDs) are also peculiar, recently discovered EEG patterns, and may manifest as periodic discharges [8]. The other periodic and rhythmic patterns are the occasional brief 2 / s GRDA predominantly frontal (formerly Frontal Intermittent Rhythmic Delta Activity or FIRDA), Evolving Lateralized Rhythmic Delta Activity or Evolving LRDA, (formerly Lateralized Rhythmic Delta Activity (LRDA) or Lateralized seizure delta activity, and Short ictal potential rhythmic discharges or B(I)RDs, will also be briefly discussed in this chapter.

### **3. Lateralized periodic discharges (LPDs)**

#### **3.1 EEG characteristics**

LPDs are stereotyped, repetitive EEG discharges and recur periodically at regular intervals at 0.5 to 3 Hz; they are broadly lateralized over one hemisphere, particularly over the parasagittal and temporal areas; LPDs are usually epileptiform in appearance; they appear like sharp waves/sharp waves complexes ranging from 50 to 300  $\mu$ V in amplitude or as blunt delta waves that recur in stereotyped periodic fashion (**Figure 1**). They are maximal in any focal brain lesion, sometimes asymmetrical (**Figure 2**). They are also associated with additional EEG evidence of ipsilateral cerebral dysfunction such as focal slowing, loss of posterior dominant rhythm.

#### **3.2 Frequency**

LPDs frequency on continuous EEG Monitoring (cEEG) varies from 6.2% to 8.6% [9]. In the intensive care unit, LPDs are found in 47% of patients [9]. LPDs are most commonly seen in patients with focal neurological deficit and are associated with varying degree of altered consciousness.

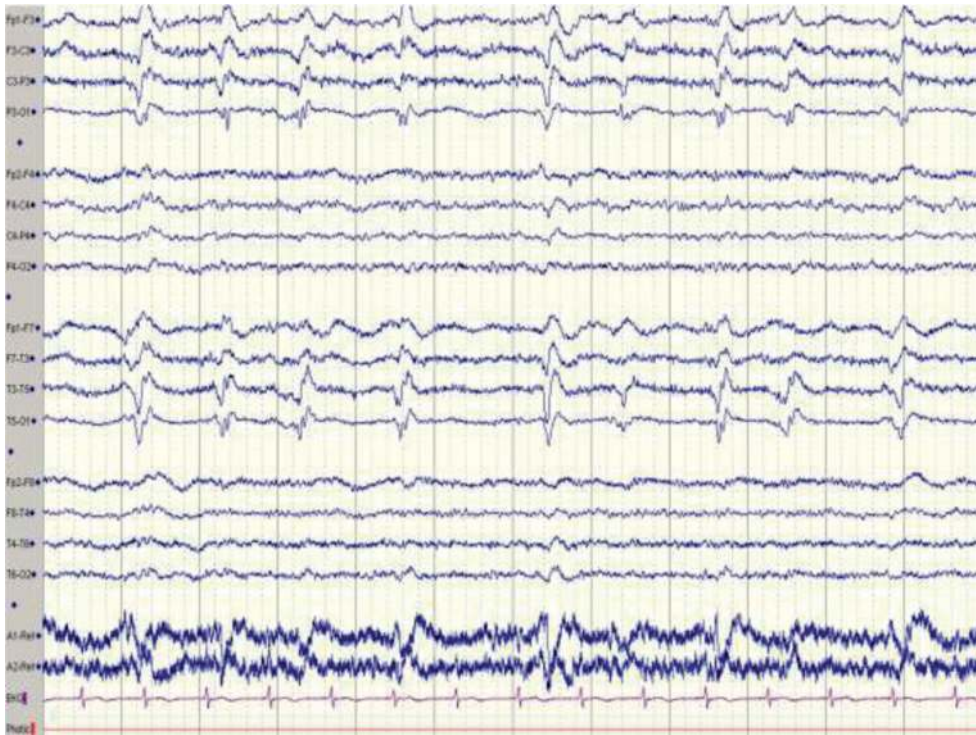
#### **3.3 Etiology**

LPDs are frequently associated with acute, structural brain lesion; very often with Ischemic stroke, viral encephalitis, including autoimmune encephalitis [10], tumors, intracerebral hemorrhage (ICH) [11], Anoxic encephalopathy, Creutzfeldt-jacob disease CJD [12], Subarachnoid Hemorrhage (SAH) [13], Multiple Sclerosis (MS), Posterior Reversible Encephalopathy Syndrome (PRES) (**Figure 3**); they have been also reported in Migraine headache, Mitochondrial Encephalopathy with lactic acidosis and stroke like episodes, (MELAS).

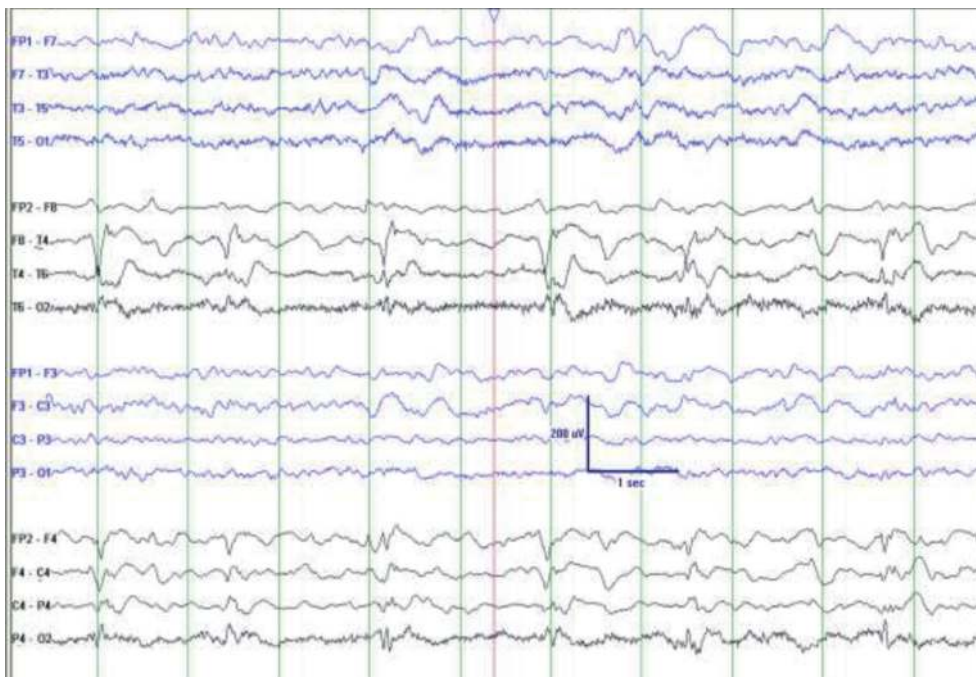
LPDs are most commonly associated with cortical gray matter or subcortical gray and white matter lesion [14]; however no structural abnormality is found on neuroimaging in 25–33% of patients with LPDs.

#### **3.4 Significance**

Are LPDs a transient EEG phenomenon following acute neurologic insult resolving usually within days to weeks? or a chronic phenomenon associated with

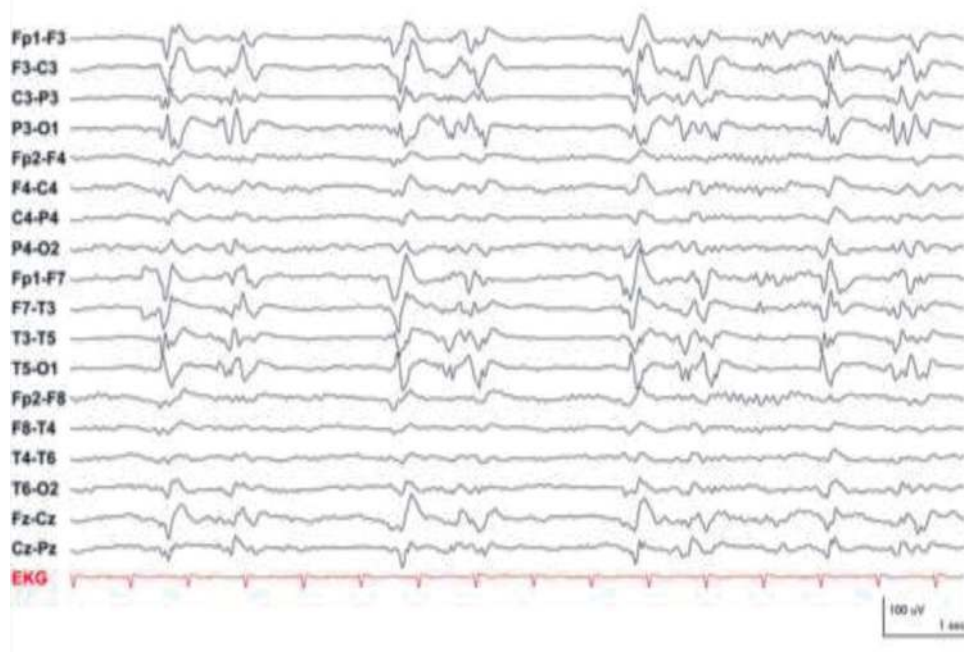


**Figure 1.** LPDs in a 70-year-old male patient with HTN. Brain MRI compatible with PRES syndrome. Quasi-periodic LPDs lateralized over the left hemisphere. PRES: Posterior Reversible Encephalopathy Syndrome.



**Figure 2.** Unilateral, LPDs in a 61-year-old patient with right temporal hemorrhage.

epilepsy? Studies have reported that LPDs are found in 5–30% of patients with history of epilepsy [15], in 26% of patients with remote brain injury and epilepsy [16] and also in patients with structural brain lesions and symptomatic epilepsy [17];



**Figure 3.** “LPDs Plus” with complex morphology and prolonged after discharges; “Ictal appearing” LPDs in a 50 ys old patient with left sided stroke and right sided clonic seizures.

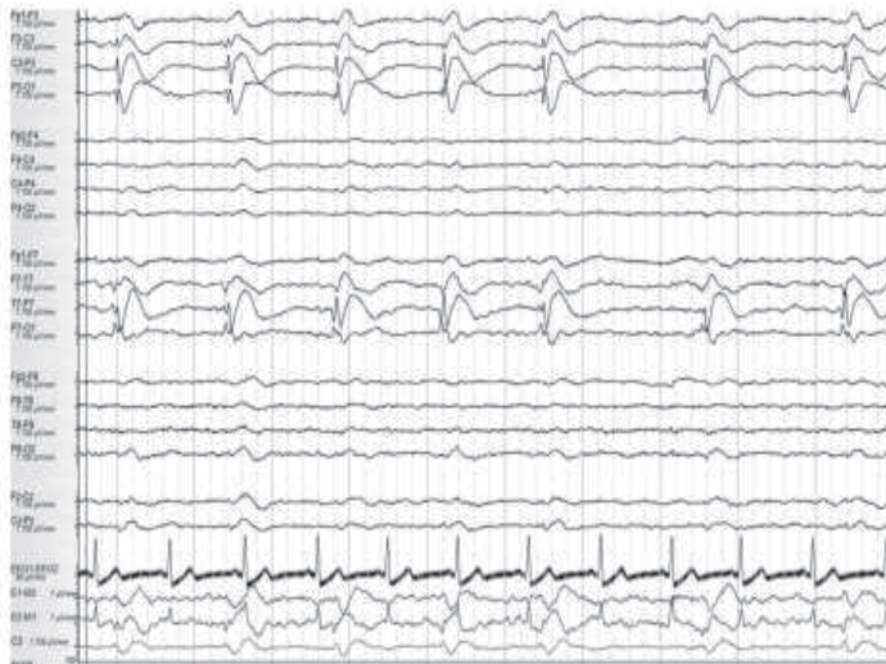some authors consider LPDs as an unstable, potentially epileptogenic state, a pattern on the “ictal-interictal continuum [18].

### 3.5 LPDs and seizures: LPDs ictal pattern??

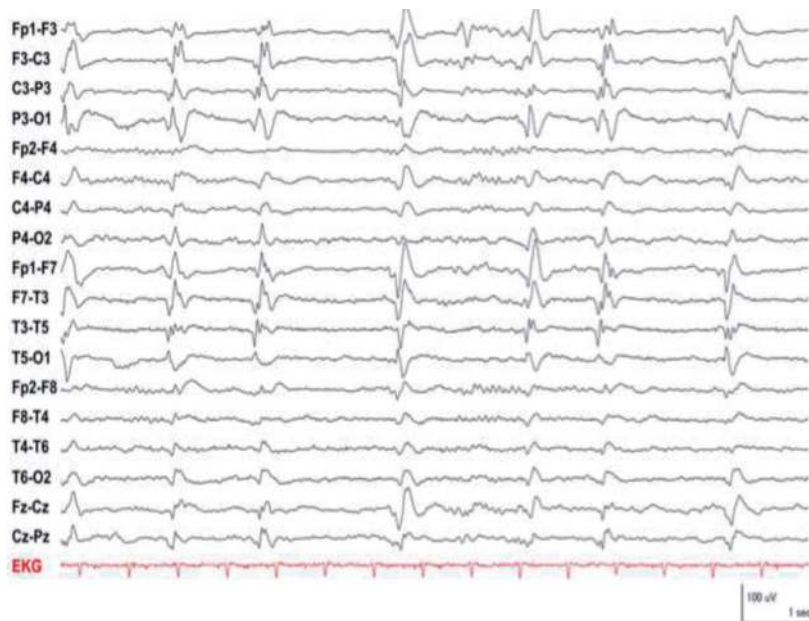The presence of LPDs in patients with altered mental status (AMS) is associated with increased risk of seizures. Clinical seizures are indeed very frequent in patients with LPDs; focal motor seizures are the most common (**Figure 3**) [19]; such seizures can occur prior or at the same time as LPDs [20]; the risk of developing subsequent seizures following LPDs is 10–56% [21]; LPDs may represent an ictal pattern when associated with clinical correlate such as focal clonic seizures (Stroke) and Epilepsia Partialis continua (EPC); LPDs may be ictal when associated with subtle clinical manifestations such as eye deviation, aphasia, hemianopsia in patients with AMS; in this setting both LPDs and clinical symptoms improve with antiseizure drugs (ASD); Claassen et al. have reported that LPDs are highly associated with Non Convulsive Seizures (NCSs), as high as 40% [22]. The frequency of LPDs is correlated with seizure risk [23]: LPDs of less than 1 Hz: 40% risk of seizures, LPDs of 2 Hz or greater: 66% risk of seizures. “Lateralized Periodic Discharges Plus (“LPDs plus”) are LPDs with a Complex morphology, a prolonged after discharges and an “Ictal appearing” (**Figures 3–5**); in addition, intervening fast activities (LPD + F) (**Figures 3 and 5**), superimposed rhythmic activity (LPD + R) or both (LPD + FR) can complicate this picture. “LPDs plus” have a rapid repetitive rate (>2HZ) and are highly associated with clinical seizures [24].

### 3.6 Management of patients with LPDs

There are no clear data regarding the management of the LPDs in patients with AMS. However neuroimaging should be performed in all patients with LPDs; metabolic/reversible conditions should be treated; as mentioned above,

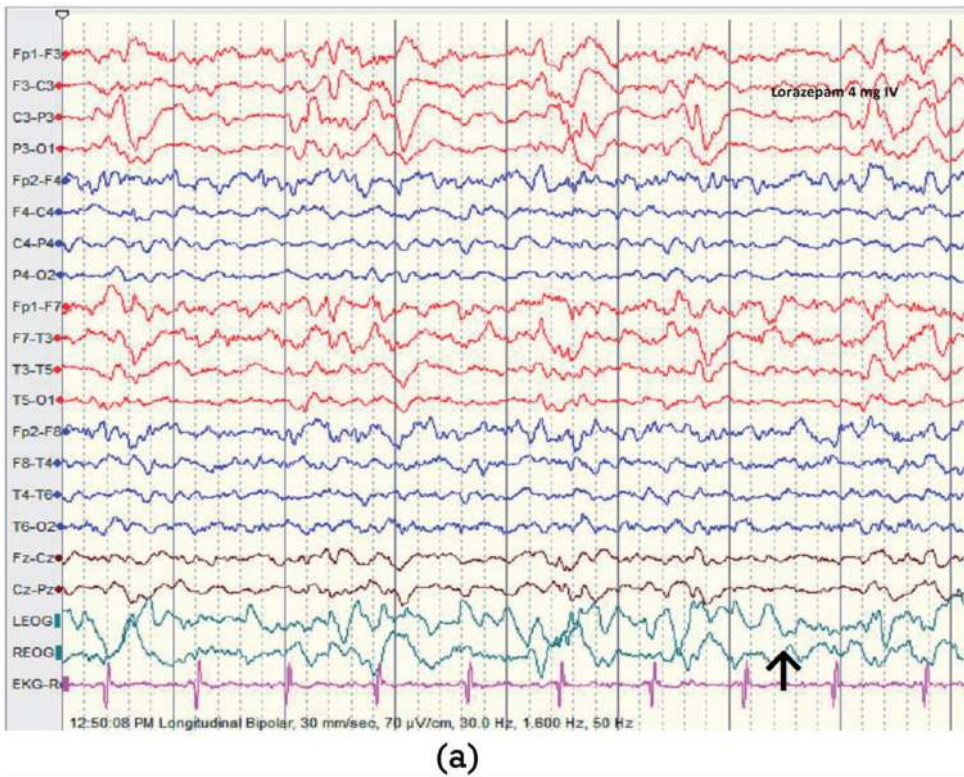


**Figure 4.**  
*LPDs at a frequency of 0.5 to 1/s with a spiky appearance running at nearly regular interval.*

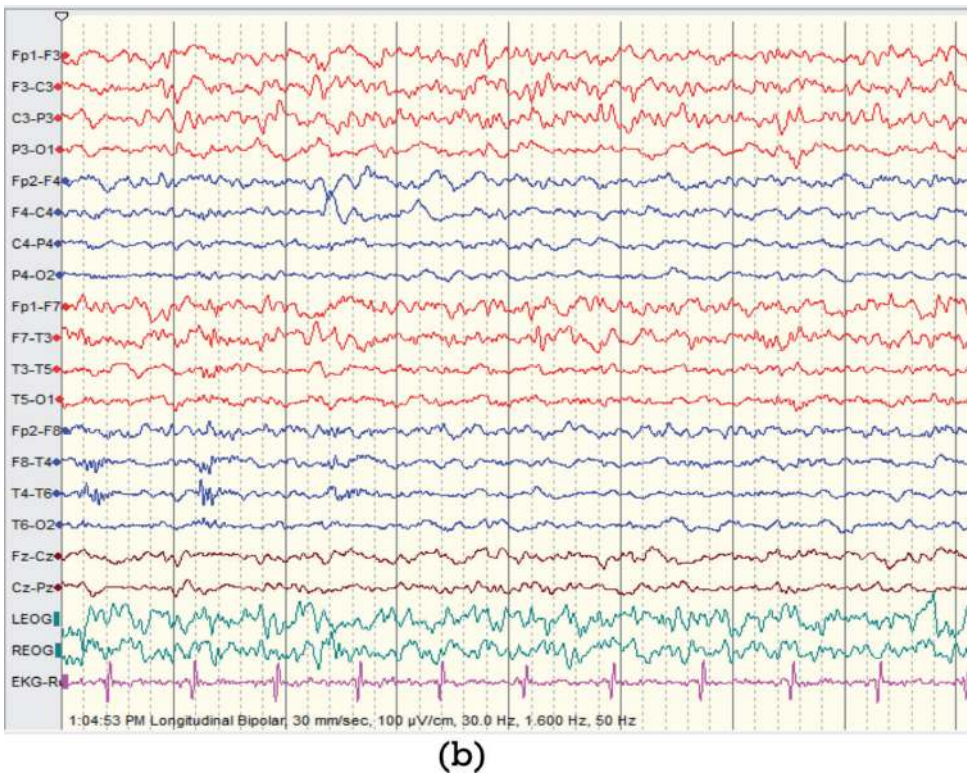


**Figure 5.**  
*64 year old left MCA infarction with jerky movements of the right upper limb. MCA: Middle Cerebral Artery.*

prolonged EEG monitoring (>24 h) is recommended in the presence of LPDs because of their association with seizures, particularly NCSs and NCSE. When LPDs are found in a confused patient, a benzodiazepine trial, such as lorazepam IV should be considered and the patient monitored (**Figures 6 and 7**). The clinical significance and management of LPDs in comatose patients is controversial [25] and there no available data regarding the continuation of ASDs after hospitalization.



**Figure 6.** LPDs in a 58 ys old male admitted to ICU with AMS, confused; no abnormal movements; given lorazepam 4 mg IV. AMS: Altered mental status; ICU: Intensive care unit.



**Figure 7.** Same patient in **Figure 6**, 14mn following lorazepam IV. Note the dramatic EEG improvement; the patient also showed an improvement in the level of consciousness.

## 4. Generalized periodic discharges (GPDs)

### 4.1 EEG characteristics, frequency

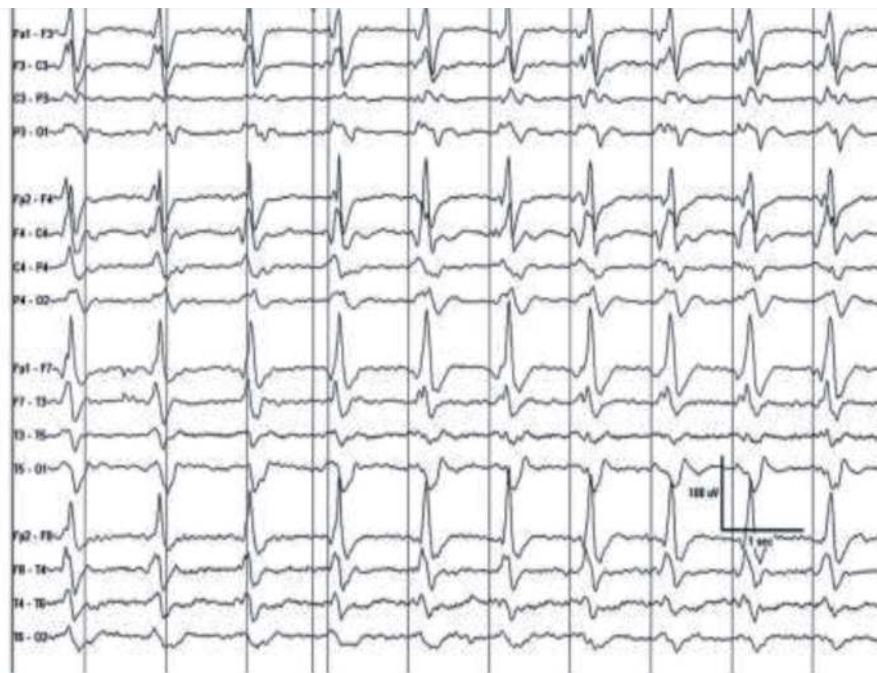
GPDs are symmetric, bilateral, repetitive discharges with regular morphology and a frontal or occipital predominance; they show the same morphology and in general the same interdischarge interval (quasi-periodic in more than 50%); slowing of the delta or theta range, frequently a background suppression of cortical activity accompany GPDs (**Figure 8**). Their occurrence with LPDs and BIPDs in the same patient is not rare [26]. GPDs are frequently encountered in comatose patients (>55%) and very early during cEEG Monitoring and are observed in 5–10% during cEEG [26].

### 4.2 Etiology

GPDs have been described in hypoxic anoxic encephalopathy, acute ischemic stroke, herpes encephalitis, Sepsis, Systemic lupus Erythematosus (SLE), traumatic brain injury (TBI), hepatic encephalopathy, Hashimoto's encephalitis, hypo/hypernatremia, uremia, renal failure, hypoglycemia, hypothyroidism, Epileptic Encephalopathy, Status Epilepticus (SE), Creutzfeldt Jacob disease, Steroid responsive encephalopathy Subacute, Sclerosing Panencephalitis (SSPE), Alzheimer Disease, Benzodiazepines, Barbiturates, propofol withdrawal; with baclofen, lithium, Phencycline or ketamine, Tiagabine and Cyclosporine, Cefepime, and other cephalosporines [27–31].

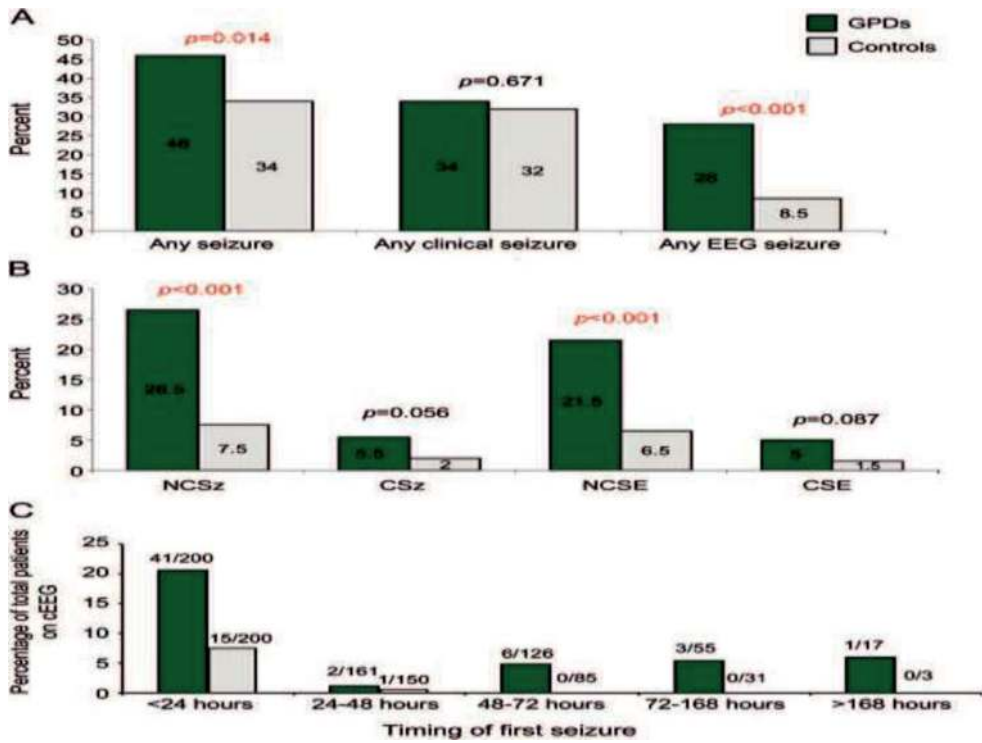
### 4.3 GPDs and seizures

GPDs are associated with seizures [32]; one study found NCSs in 27% vs. 8% of patients with/without GPDs and NCSE in 22% vs. 7% only [26]. GPDs with “plus

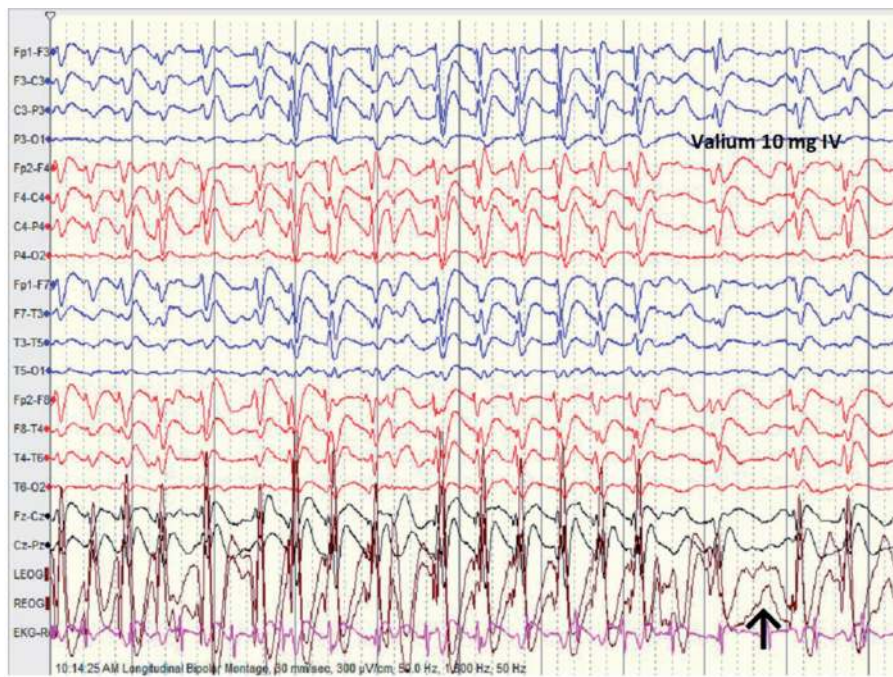


**Figure 8.**  
*GPDs. One per second GPDs with clear frontal predominance and a sharp morphology.*



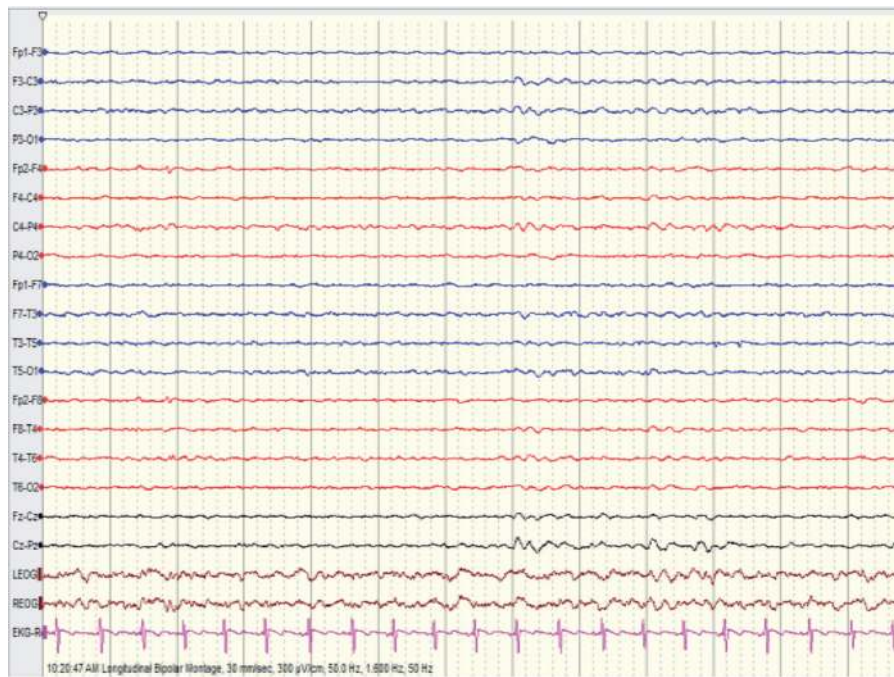


**Figure 9.** Association of NCSs, NCSE with GDPs. Generalized periodic discharges and NCSs, NCSE. (A) Seizure occurrence at any time in patients with GDPs vs. controls (%) and (B) during cEEG in patients with GDPs vs. controls (%). (C) Timing of first recorded seizure in patients with GDPs vs. controls. CSE convulsive status epilepticus; CSz convulsive seizure; NCSE nonconvulsive status epilepticus; NCSz nonconvulsive seizure.



(a)

**Figure 10.** GDPs with Triphasic morphology (GDPs TM) in a 59-year-old patient following cardiac arrest. GDPs show frequency change and qualify probably for “evolving GDPs”. Patient given 10 mg diazepam IV.



(b)

**Figure 11.**

Same patient in **Figure 10** following 10 mg of diazepam. Note the EEG improvement 6 mn following diazepam IV; however, there was no clinical improvement (patient remained comatose): “Possible NCSE in coma” (“comatose NCSE”?).

features”, sharper morphology, and high frequency increase the possibility of seizures on EEG [23]. Sutter R et al. have shown that GDPs are strongly associated with NCSs, NCSE [33] (**Figure 9**). GDPs may reflect an ictal rhythm; they may manifest with a triphasic morphology [31]; in addition there is a clear GDPs response (triphasic morphology) to Benzodiazepines (BDZs) (**Figures 10 and 11**).

#### 4.4 GDPs with triphasic morphology (GDPs TM)

##### 4.4.1 EEG characteristics

GDPs TM (**Figure 10**) [7] are known as moderate to high voltage EEG discharges (100-300uv), with a frequency varying from 1 to 2 Hz; they are usually characterized by the presence of 3 phases: Negative–positive –negative in polarity with a predominant positive phase; often, there is a frontal predominance, and sometimes an anterior –posterior or posterior –anterior phase lag.

##### 4.4.2 Etiology

GDPs with triphasic morphology are reported in metabolic disturbances, hypertensive encephalopathy, subcortical white-matter disease, infections, strokes, hypoglycemia hypernatremia/hyponatremia, postictal states, lithium and baclofen toxicity.

##### 4.4.3 GDPs with triphasic morphology and seizures

GDPs TM association with seizures has been discussed by several authors especially concerning nonconvulsive status epilepticus (NCSE) where the

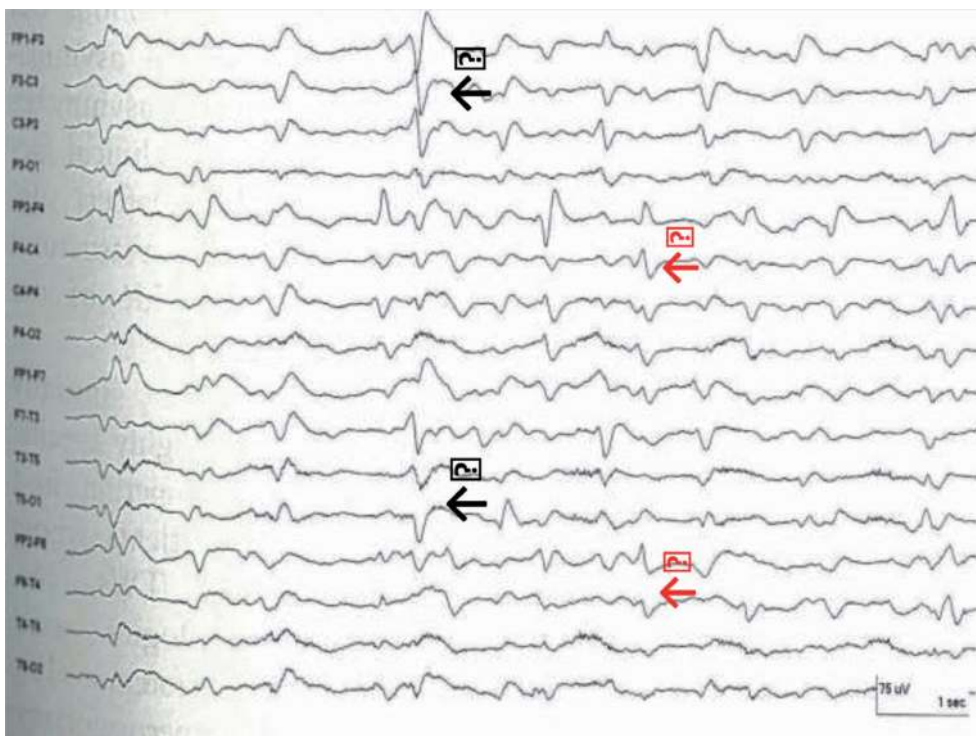
improvement of both EEG and patient level of consciousness with BDZs is consistent with NCSE; Jirsh et al. define a possible NCSE in a patient, a state where BDZs abolish GDPs TM without clinical improvement [34] (**Figures 10 and 11**); patients with GDPs and TM are likely to develop seizures as those without (25% vs. 26%) [35]; furthermore anterior to posterior “phase lag” does not occur with GDPs TWs related NCSE.

#### 4.4.4 Significance, prognosis of GDPs

In one study the mortality of patients with GDPs is estimated at 53% [36]. Predictor of poor outcome in patients with GDPs include Dementia, altered to poor mental status, focal neuroimaging abnormalities and cardiac arrest [36]. Few Patients with GDPs and anoxic brain damage regain consciousness [37].

## 5. Bilateral independent periodic discharges BIPDs

BIPDs occur as LPDs involving both hemispheres, in an independent and asynchronous manner (**Figure 12**); The true prevalence and incidence of BIPDs is unknown; however, they are less common than LPDs; studies mention that seizures are also less common in association with BIPDs than with LPDs, successively 29% vs. 44% [23] and 43% vs. 70% [17]. BIPDs are associated with acute brain lesions (anoxic brain damage, stroke, CNS infection, tumor); in general the clinical status and prognosis of patients showing BIPDs is worse than those with LPDs; mortality rate for BIPDs compared to LPDs is much higher 47, 8% vs. 14% respectively [38].

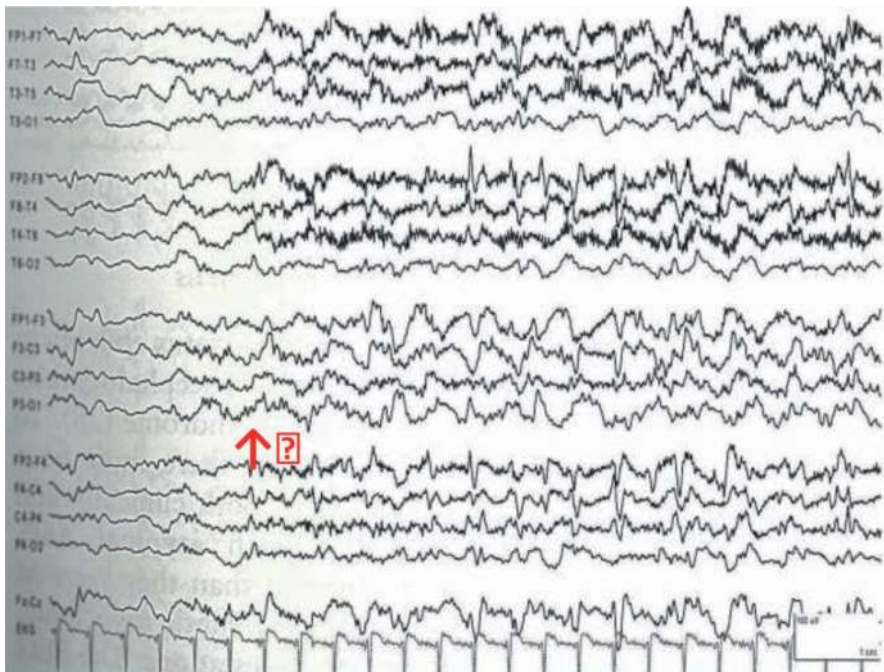

**Figure 12.** Bilateral independent periodic discharges BIPDs. Black arrows show discharge arising from the left hemisphere, red arrows discharges arising from the right hemisphere.

## 6. Stimulus induced evolving lateralized rhythmic delta activity (Si-evolving LRDA)

These EEG features were recently described by Hirsch et al. in ICU patients [8]. They occur whenever ICU patients with AMS are stimulated using auditory, sternal rub, suctioning, or other stimulating procedures (**Figure 13**); these curious EEG patterns appear ictal, they are sometimes associated with an evolving lateralized rhythmic delta activity, stimulus induced also; Si-Evolving LRDA looks like an epileptiform activity recurring at regular intervals; there are in general purely EEG changes; however, few patients showing these features present focal motor seizures.

No data are available regarding the pathophysiology and prognostic significance of these stimuli-induced EEG features.



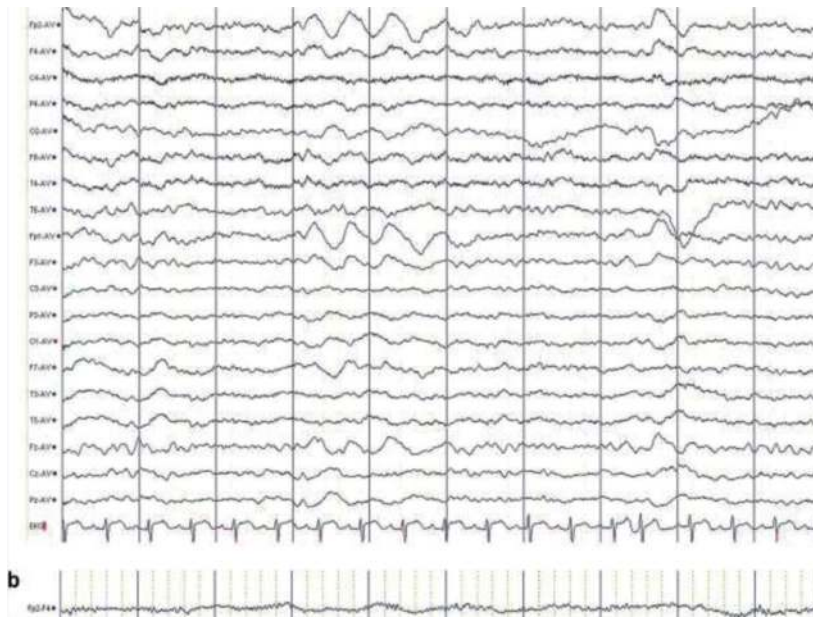**Figure 13.** Stimulus induced evolving lateralized Rhythmic delta activity (Si-evolving LRDA) in a patient with SAH. Sternal Rub (red arrow) inducing right sided periodic spikes at 2 Hz. Also note the presence of rhythmic delta activity over the left side. SAH: subarachnoid hemorrhage.

## 7. Occasional frontally predominant brief 2/s generalized rhythmic delta activity (GRDA)

These EEG waves are bilateral, bisynchronous, symmetric activity of 4 Hz or less, intermittent, predominant anterior activities (**Figure 14**). It is the most EEG feature frequently seen in the ICU [39].

It is reported in various diseases and syndromes such as structural brain lesion, metabolic encephalopathy, epilepsy, neurodegenerative disorders.

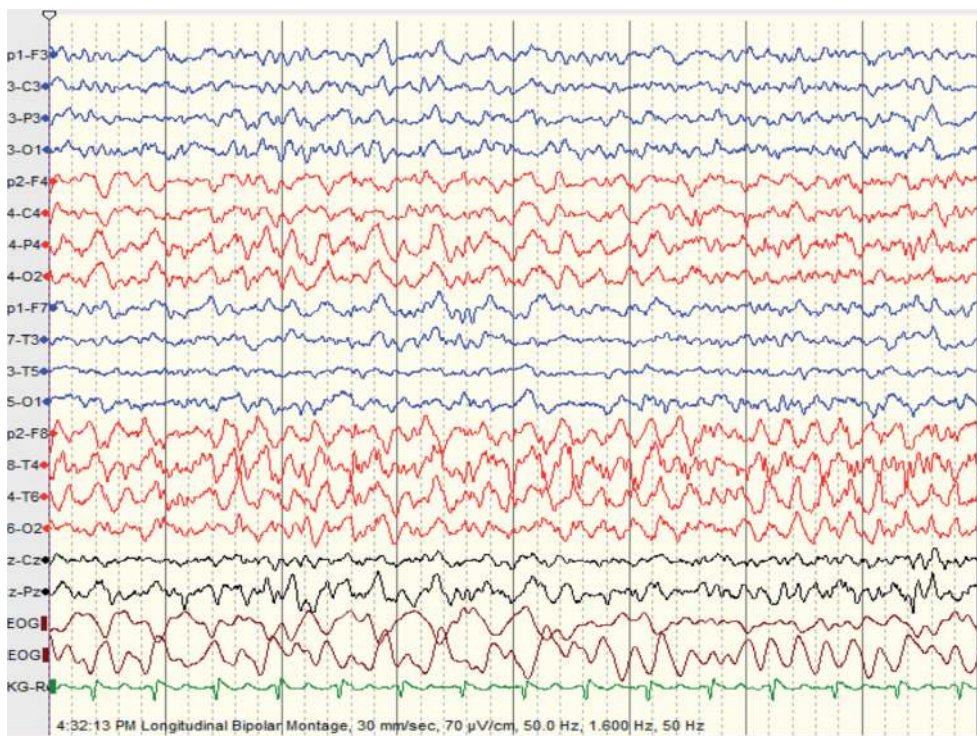
Study has shown that this pattern is not associated with an increasing risk of seizures [23]. In general, this EEG feature represents a benign pattern and is associated with a good outcome.



**Figure 14.**  
*Generalized Rhythmic Delta activity (GRDA). Average montage. Note the brief (lasting 2 s), 2 cps, bilateral, predominantly anterior delta activity.*

## 8. Evolving lateralized rhythmic delta activity (LRDA)

These interesting EEG features are unilateral rhythmic activity of 4 Hz or less, are found in various central nervous system lesions such as cortical and deep gray matter lesions, acute brain injury, and in chronic seizure disorder (**Figure 15**); there



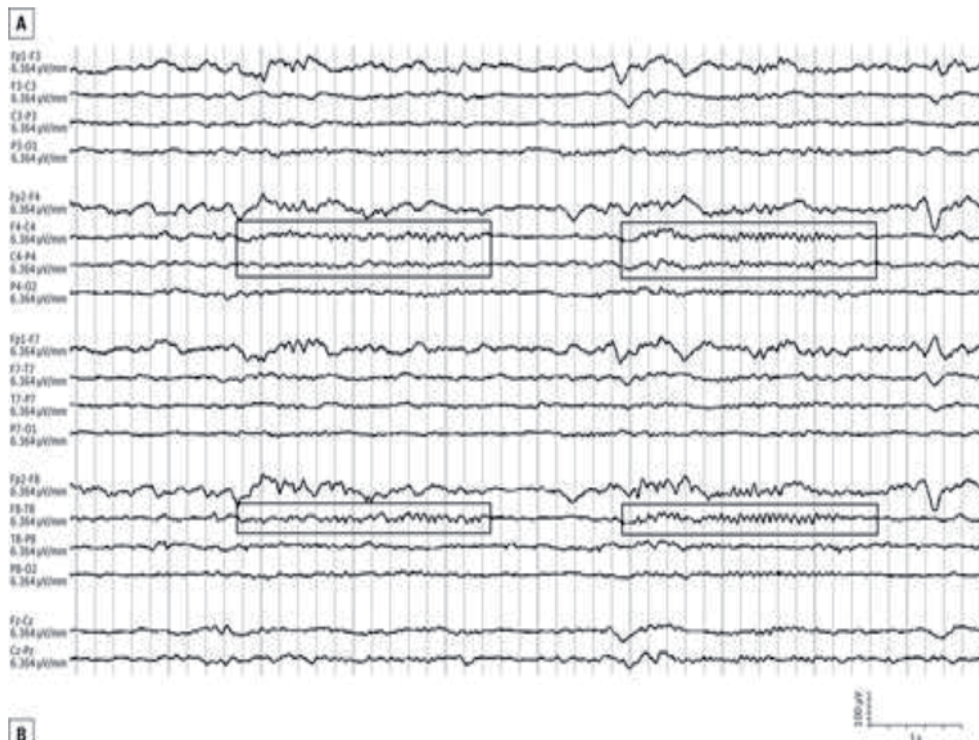
**Figure 15.**  
*LRDA in a 50 years old patient with NCSE. Note the right sided continuous lateralized focal predominantly fronto-temporal 3, 5 to 4 cps delta activity.*

are also seen in acute seizures in 63% of patients [40] and are frequently associated with LPDs; LRDA carries similar implications as LPDs [40].

## 9. Brief potentially ictal rhythmic discharges [B(I)RDs]

B(I)RDs are very brief EEG discharges, of moderate to low amplitude, lasting between 10s and 4 s, firing at around 4 Hz or more, rhythmic focal theta activity (**Figure 16**); they are most often seen in neonates and occur in 2% in ICU population during cEEG monitoring.

Patient with B(I)RDs suffer from various neurological disorders especially chronic seizure disorder, and acute cerebral injury; a large majority of patients with B(I)RDs experience seizures.



**Figure 16.** B(I)RDs in a 80 ys old patient. Patient suffered from generalized tonic–clonic seizure and was unconscious. EEG shows a very brief run of sharply contoured, intermittent rhythmic theta activity over the right anterior region (boxed areas).

## 10. Conclusion

The electrographic patterns discussed above, such as LPDs, GPDs, LRDA, and B(I)RDs are strongly associated with seizures; this association is well established in ICU patients suffering from AMS. There are however many unanswered questions regarding these abnormal EEG features: do they reflect the severity of the brain injury? Do they actively contribute to its damage and how should we treat them are still largely unknown. Equally not established is their association with long term seizures and the risk of epilepsy.

## Author details

Boulenouar Mesraoua<sup>1,2\*</sup>, Musab Abdalhalim Ali<sup>1</sup>,  
Rola Hosni Mohamed Hashem Khodair<sup>1</sup>, Yazan Nofal<sup>1</sup>,  
Dirk Theophiel O. Deleu<sup>1,2</sup>, Hassan Jasim Al Hail<sup>1,2</sup>, Osama Robin Elalamy<sup>1,2</sup>,  
Gayane Melikyan<sup>1,2</sup>, Covanis Athanasios<sup>3</sup> and Ali Akbar Asadi-Pooya<sup>4,5</sup>

1 Hamad Medical Corporation, Doha, Qatar

2 Weill Cornell Medical College, Doha, Qatar

3 Neurology and Neurophysiology Department, The Children's Hospital Agia Sophia, Athens, Greece

4 Department of Neurology, Thomas Jefferson University, Philadelphia, PA, USA

5 Department of Neurology, Shiraz University of Medical Sciences, Shiraz, Iran

\*Address all correspondence to: [boulenouar.mesraoua@wanadoo.fr](mailto:boulenouar.mesraoua@wanadoo.fr)

## IntechOpen

---

© 2021 The Author(s). Licensee IntechOpen. This chapter is distributed under the terms of the Creative Commons Attribution License (<http://creativecommons.org/licenses/by/3.0>), which permits unrestricted use, distribution, and reproduction in any medium, provided the original work is properly cited. 

## References

- [1] Boulenouar Mesraoua, Dirk Deleu, Hassan Al Hail, Faisal Ibrahim, Gayane Melikyan, Hassan Al Hussein, Rajvir Singh, Basim Uthman, Leopold Streletz, Peter W Kaplan, Heinz Gregor Wieser. *Journal of Drug Assessment* 2017, <https://doi.org/10.1080/21556660.2017.1396992>
- [2] Chong DJ, Hirsch LJ. Which EEG patterns warrant treatment in the critically ill? Reviewing the evidence for treatment of periodic epileptiform discharges and related patterns. *J Clin Neurophysiol* 2005;22:79-91.
- [3] Hirsch LJ, Brenner RP. Periodic discharges and other controversial EEG patterns. In: Hirsch LJ, Brenner RP (Eds). *Atlas of EEG in critical care*. Chichester: Wiley-Blackwell, 2010: 129-160.
- [4] Garzon E, Fernandes RM, Sakamoto AC. Serial EEG during human status epilepticus: evidence for PLED as an ictal pattern. *Neurology* 2001;57:1175-1183. [ Links ]
- [5] Rossetti AO, Hirsch LJ, Drislane FW. Nonconvulsive seizures and nonconvulsive status epilepticus in the neuro ICU should or should not be treated aggressively: A debate. *Clin Neurophysiol Pract*. 2019 Aug 9;4:170-177. doi: 10.1016/j.cnp.2019.07.001. eCollection 2019. PMID: 31886441
- [6] Hirsch LJ, Brenner RP, Drislane FW, et al. The ACNS subcommittee on research terminology for continuous EEG monitoring: proposed standardized terminology for rhythmic and periodic EEG patterns encountered in critically ill patients. *J Clin Neurophysiol* 2005;22:128-135.
- [7] Hirsch LJ, LaRoche SM, Gaspard N, Gerard E, Svoronos A, Herman ST, Mani R, Arif H, Jette N, Minazad Y, Kerrigan JF, Vespa P, Hantus S, Claassen J, Young GB, So E, Kaplan PW, Nuwer MR, Fountain NB, Drislane FW. American Clinical Neurophysiology Society's Standardized Critical Care EEG Terminology: 2012 version. *Journal of clinical neurophysiology: official publication of the American Electroencephalographic Society*. 2013 Feb;30(1):1-27.
- [8] Hirsch LJ, Claassen J, Mayer SA, Emerson RG. Stimulus-induced rhythmic, periodic, or ictal discharges (SIRPIDs): a common EEG phenomenon in the critically ill. *Epilepsia* 2004;45:109-123.
- [9] Rai V, Jetli S, Rai N, Padma MV, Tripathi M. Continuous EEG predictors of outcome in patients with altered sensorium. *Seizure*. 2013 Oct;22(8):656-61. doi: 10.1016/j.seizure.2013.05.002. Epub 2013 Jun 12. PMID: 23768540
- [10] Francisco Hernández-Fernández, Eva Fernández-Díaz, Jose M Pardal-Fernández, Tomás Segura, Jorge García-García. Periodic lateralized epileptiform discharges as manifestation of pneumococcal meningitis. *Int Arch Med*. 2011; 4: 23. Published online 2011 Jun 25. doi: 10.1186/1755-7682-4-23 PMID: PMC3141320
- [11] Claassen J, Jette N, Chum F, et al. Electrographic seizures and periodic discharges after intracerebral hemorrhage. *Neurology* 2007; 69: 1356-1365 [PubMed] [Google Scholar]
- [12] Binelli S, Agazzi P, Giaccone G, Will RG, Bugiani O, Franceschetti S, Tagliavini F. Periodic electroencephalogram complexes in a patient with variant Creutzfeldt-Jakob disease. *Ann Neurol*. 2006 Feb; 59(2):423-7.
- [13] Claassen J, Hirsch LJ, Frontera JA, et al. Prognostic significance of continuous EEG monitoring in



patients with poor-grade subarachnoid hemorrhage. *Neurocrit Care* 2006; 4: 103-112 [PubMed] [Google Scholar]

[14] Lu Lin, Frank W Drislane. Lateralized Periodic Discharges: A Literature Review. *J Clin Neurophysiol*. 2018 May;35(3):189-198. doi: 10.1097/WNP.0000000000000448.

[15] García-Morales I, García MT, Galán-Dávila L, Gómez-Escalonilla C, Saiz-Díaz R, Martínez-Salio A, de la Peña P, Tejerina JA. Periodic lateralized epileptiform discharges: etiology, clinical aspects, seizures, and evolution in 130 patients. *J Clin Neurophysiol*. 2002 Apr;19(2):172-7. doi: 10.1097/00004691-200203000-00009. PMID: 11997729

[16] Rup K Sainju, Louis N Manganas, Emily J Gilmore, Ognen A Petroff, Nishi Rampal, Lawrence J Hirsch, Nicolas Gaspard. Clinical Correlates and Prognostic Significance of Lateralized Periodic Discharges in Patients Without Acute or Progressive Brain Injury: A Case-Control Study. *J Clin Neurophysiol*. 2015 Dec;32(6):495-500. doi:10.1097/WNP.0000000000000206.

[17] Orta DS, Chiappa KH, Quiroz AZ, Costello DJ, Cole AJ Prognostic implications of periodic epileptiform discharges.. *Arch Neurol*. 2009 Aug;66(8):985-91. doi: 10.1001/archneurol.2009.137. PMID: 19667220

[18] Gregory Kapinos, Eugen Trinka, Peter W Kaplan. Multimodal Approach to Decision to Treat Critically Ill Patients With Periodic or Rhythmic Patterns Using an Ictal-Interictal Continuum Spectral Severity Score. *J Clin Neurophysiol*. 2018 Jul;35(4):314-324. doi: 10.1097/WNP.0000000000000468.

[19] Chatrian GE, Shaw CM, Leffman H. The Significance of Periodic Lateralized Epileptiform Discharges in Eeg: an Electrographic, Clinical and

Pathological Study. *Electroencephalogr Clin Neurophysiol*. 1964 Aug;17:177-93. doi: 10.1016/0013-4694(64)90149-x. PMID: 14204927

[20] S M Snodgrass, K Tsuburaya, C Ajmone-Marsan. Clinical significance of periodic lateralized epileptiform discharges: relationship with status epilepticus. *J Clin Neurophysiol*. 1989 Apr;6(2):159-72. doi: 10.1097/00004691-198904000-00003.

[21] J M Walsh, R P Brenner. Periodic lateralized epileptiform discharges--long-term outcome in adults. *Epilepsia*. Sep-Oct 1987;28(5):533-6. doi: 10.1111/j.1528-1157.1987.tb03684.x.

[22] Claassen J, Mayer SA, Kowalski RG, Emerson RG, Hirsch LJ. Detection of electrographic seizures with continuous EEG monitoring in critically ill patients. *Neurology*. 2004 May 25;62(10):1743-8. doi: 10.1212/01.wnl.0000125184.88797.62. PMID: 15159471 Review.

[23] Andres Rodriguez Ruiz, Jan Vlachy, Jong Woo Lee, Emily J Gilmore, Turgay Ayer, Hiba Arif Haider, Nicolas Gaspard, J Andrew Ehrenberg, Benjamin Tolchin, Tadeu A Fantaneanu, Andres Fernandez, Lawrence J Hirsch, Suzette LaRoche, Critical Care EEG Monitoring Research Consortium. Association of Periodic and Rhythmic Electroencephalographic Patterns With Seizures in Critically Ill Patients. *JAMA Neurol*. 2017 Feb 1;74(2):181-188. doi: 10.1001/jamaneurol.2016.49

[24] Aaron F Struck, Berk Ustun, Andres Rodriguez Ruiz, Jong Woo Lee, Suzette M LaRoche, Lawrence J Hirsch, Emily J Gilmore, Jan Vlachy, Hiba Arif Haider, Cynthia Rudin, M Brandon Westover. Association of an Electroencephalography-Based Risk Score With Seizure Probability in Hospitalized Patients. *JAMA Neurol*. 2017 Dec 1;74(12):1419-1424. doi: 10.1001/jamaneurol.2017.245

- [25] Bauer G, Trinka E. Nonconvulsive status epilepticus and coma. *Epilepsia*. 2010 Feb;51(2):177-90. doi: 10.1111/j.1528-1167.2009.02297.x. Epub 2009 Sep 10
- [26] Brandon Foreman, Jan Claassen, Karine Abou Khaled, Jeffrey Jirsch, Daniel M Alschuler, John Wittman, Ronald G Emerson, Lawrence J Hirsch. Generalized periodic discharges in the critically ill: a case-control study of 200 patients. *Neurology*. 2012 Nov 6;79(19):1951-60. doi: 10.1212/WNL.0b013e3182735cd7. Epub 2012 Oct
- [27] San-Juan OD, Chiappa KH, Costello DJ, Cole AJ. Periodic epileptiform discharges in hypoxic encephalopathy: BiPLEDs and GPEDs as a poor prognosis for survival. *Seizure*. 2009 Jun;18(5):365-8. doi: 10.1016/j.seizure.2009.01.003. Epub 2009 Feb 4. PMID: 19196524
- [28] Ficker DM, Westmoreland BF, Sharbrough FW. Epileptiform abnormalities in **hepatic encephalopathy**. *J Clin Neurophysiol*. 1997 May;14(3):230-4. doi: 10.1097/00004691-199705000-00008. PMID: 9244163
- [29] Lai CW, Gragasin ME. Electroencephalography in herpes simplex encephalitis. *J Clin Neurophysiol*. 1988 Jan;5(1):87-103. doi: 10.1097/00004691-198801000-00003. PMID: 3150762
- [30] B K Madhusudhan. Nonconvulsive status epilepticus and Creutzfeldt-Jakob-like EEG changes in a case of lithium toxicity. *Epilepsy Behav Case Rep*. 2014 Nov 28;2:203-5. doi: 10.1016/j.ebcr.2014.08.005. eCollection 2014.
- [31] A R Towne, E J Waterhouse, J G Boggs, L K Garnett, A J Brown, J R Smith Jr, R J DeLorenzo. Prevalence of nonconvulsive status epilepticus in comatose patients. *Neurology*. 2000 Jan 25;54(2):340-5. doi: 10.1212/wnl.54.2.340
- [32] Muge Yemisci, Gunfer Gurer, Serap Saygi, Abdurrahman Ciger. Generalised periodic epileptiform discharges: clinical features, neuroradiological evaluation and prognosis in 37 adult patients. *Seizure*. 2003 Oct;12(7):465-72. doi: 10.1016/s1059-1311(02)00351-5.
- [33] Sutter, Raoul. Are We Prepared to Detect Subtle and Nonconvulsive Status Epilepticus in Critically Ill Patients? *Journal of Clinical Neurophysiology*. 33(1):25-31, February 2016. DOI: 10.1097/WNP.0000000000000216
- [34] J Jirsch, L J Hirsch. Nonconvulsive seizures: developing a rational approach to the diagnosis and management in the critically ill population. *Clin Neurophysiol*. 2007 Aug;118(8):1660-70. doi: 10.1016/j.clinph.2006.11.312. Epub 2007 Jun 27.
- [35] Foreman B, et al. Generalized periodic discharges and 'triphase waves': A blinded evaluation of inter-rater agreement and clinical significance. *Clin Neurophysiol*. 2016. PMID: 26294138
- [36] Jadeja N, Zarnegar R, Legatt AD. Clinical outcomes in patients with generalized periodic discharges. *Seizure*. 2017 Feb;45:114-118. doi: 10.1016/j.seizure.2016.11.025. Epub 2016 Dec 7.
- [37] Barry J Ruijter, Michel J A M van Putten, Jeannette Hofmeijer. Generalized epileptiform discharges in postanoxic encephalopathy: Quantitative characterization in relation to outcome. *Epilepsia*. 2015 Nov;56(11):1845-54. doi: 10.1111/epi.13202. Epub 2015 Sep 19.
- [38] de la Paz D, Brenner RP. Bilateral independent periodic lateralized epileptiform discharges. Clinical significance. *Arch Neurol*. 1981 Nov;38(11):713-5. doi: 10.1001/archneur.1981.00510110073012. PMID: 7305701
- [39] Dericicoglu N, Khasiyev F, Arsava EM, Topcuoglu MA. Frontal

Intermittent Rhythmic Delta Activity (FIRDA) in the Neurological Intensive Care: Prevalence, Determinants, and Clinical Significance. *Clin EEG Neurosci.* 2018 Jul;49(4):272-277. doi: 10.1177/1550059416688108. Epub 2017 Jan 24.

[40] Gaspard N, Manganas L, Rampal N, Petroff OA, Hirsch LJ. Similarity of lateralized rhythmic delta activity to periodic lateralized epileptiform discharges in critically ill patients. *JAMA Neurol.* 2013 Oct;70(10):1288-95. doi: 10.1001/jamaneurol.2013.3475. PMID: 23921464