
Motor Imagery and Action Observation as Effective Tools for Physical Therapy

Hideki Nakano and Takayuki Kodama

Additional information is available at the end of the chapter

<http://dx.doi.org/10.5772/67519>

Abstract

Motor imagery and action observation facilitate motor recovery of patients because both the motor imagery and the action observation share the activation of cortical neural networks implicated in movement execution. Specifically, imagery, observation, and execution activate the medial parietal area of the brain located between the parieto-occipital sulcus and the posterior end of the cingulate sulcus. This chapter reviews the neural mechanisms and clinical studies of motor imagery and action observation and discusses the applications in physical therapy.

Keywords: action observation, motor imagery, physical therapy

1. Introduction

Motor imagery and action observation have been proven as effective tools in rehabilitation [1]. Motor imagery is a cognitive process in which a subject only imagines completing a movement, without tensing any muscles (**Figure 1(a)**) [2]. While motor imagery alone can improve motor performance [3], it is particularly effective when associated with physical practice [4] as compared to physical practice alone. Héту et al. reported the neural network of motor imagery using ALE meta-analysis [5]. The meta-analysis examined the general pattern of consistent activations during motor imagery and revealed several large clusters of activated tissue spanning over both hemispheres of the brain. In the frontal lobes, the bilateral inferior frontal gyri (IFG, including the pars opercularis), precentral gyrus (PcG), middle

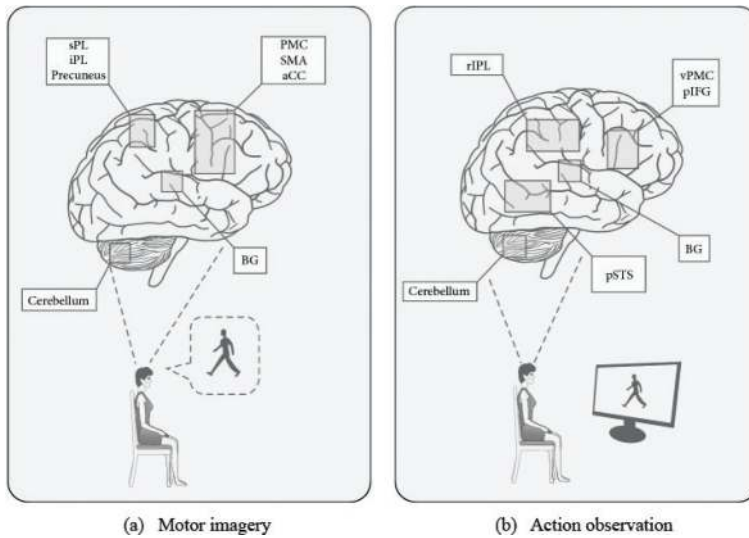


Figure 1. Motor imagery and action observation [2]. Human brain activity during motor imagery (a) and action observation (b). (a) Brain areas activated during kinesthetic and visual motor imagery. The pattern of activity includes the following regions: ventral and dorsal part of the premotor cortex (PMC); the supplementary motor area (SMA); anterior cingulate cortex (aCC); superior parietal lobule (sPL) and inferior parietal lobule (IPL); precuneus; basal ganglia (BG); and cerebellum. (b) The complex brain network ("mirror neuron system") involved in action observation: the ventral premotor cortex (vPMC), posterior part of the inferior frontal gyrus (pIFG), rostral part of the inferior parietal lobule (rIPL), and posterior superior temporal sulcus (pSTS).

frontal gyrus (MfG), supplementary motor area (SMA), and regions of the anterior insula were regions consistently activated during motor imagery. In the parietal lobes, the bilateral superior parietal lobule (SPL), supramarginal gyrus (SMG), and left inferior parietal lobule (IPL) and, in the subcortical regions, the left putamen, right thalamus, and pallidum were activated. Finally, the areas VI (bilateral) and the vermis of the cerebellum (CB) were also found to be consistently activated.

When a subject observes a specific action being performed, activation of the same neural structures used for the movement pattern is also repeated in the subject (**Figure 1(b)**) [2]. The neurophysiological basis of action observation is represented by the discovery of mirror neurons in the cerebral cortex of monkeys [6, 7]. These neurons discharge during both the execution of goal-directed actions and the observation of other individuals performing similar movements. The definition of the mirror neuron system (MNS) is the area that comprises the cerebral areas containing mirror neurons. Evidence with the use of transcranial magnetic stimulation (TMS) and functional magnetic resonance imaging (fMRI) suggested that MNS is also present in the human brain [8]. Some studies suggest a similar learning effect of action observation and physical practice [9–11]. Caspers et al. reported the neural network of action observation using ALE meta-analysis [12]. Brain regions showing consistent activation across action observation experiments were observed symmetrically across both hemispheres in frontal areas BA 44/45, lateral dorsal

premotor cortex (dPMC, BA 6), supplementary motor area (SMA, BA 6), rostral IPL (area Pft), primary somatosensory cortex (SI, BA 1/2), SPL (area 7A), intraparietal cortex (IPS, area hIP3), posterior middle temporal gyrus (pMTG) at the transition to visual area V5, and the fusiform face area/fusiform body area (FFA/FBA). Both motor imagery and action observation share the activation of cortical neural networks as implicated in movement execution (**Figure 2**) [13]. Moreover, we reported that brain activity during movement observation, imagery, and execution uses different pathways according to the sensory modality (**Figure 3**) [14]. This chapter discusses the clinical results of motor imagery and action observation studies and rehabilitation applications.

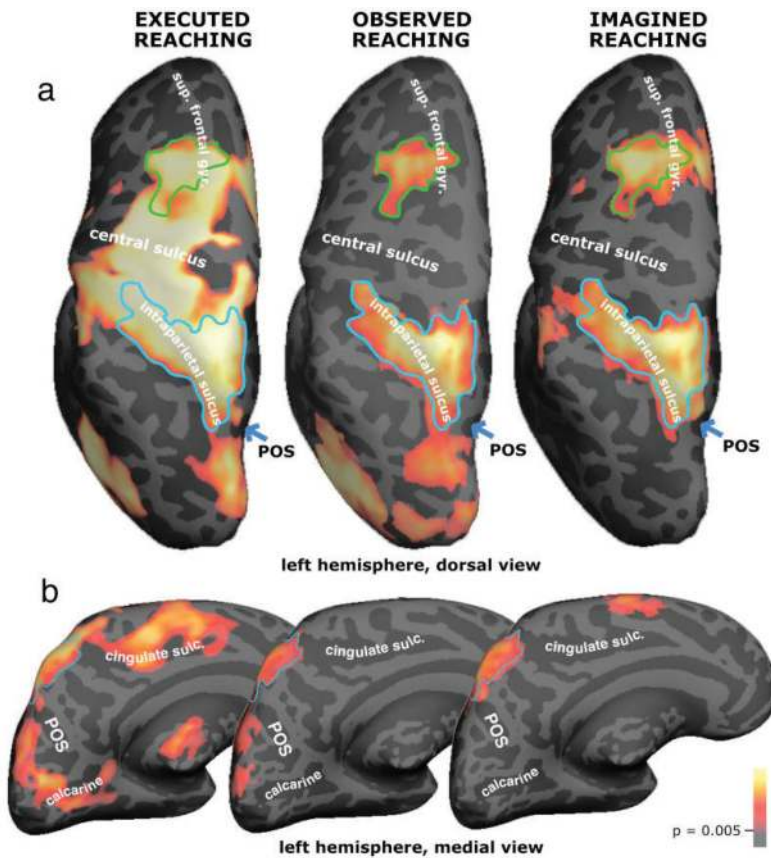


Figure 2. Outline of the overlap between executed, observed, and imagined reaching in the left dorsal premotor (superior frontal sulcus and gyrus) and left posterior parietal areas [13]. The overlaps in the premotor and parietal regions served as regions of interest in the percent signal change analysis. (a) Dorsal view of the left hemisphere. (b) Medial view of the left hemisphere. Executed, observed, and imagined reaching all activated a medial parietal area located in-between the parieto-occipital sulcus and the posterior end of the cingulate sulcus, outlined in light blue. Sup. frontal gyr., superior frontal gyrus; POS, parieto-occipital sulcus; calcarine, calcarine sulcus; cingulate sulc., cingulate sulcus.

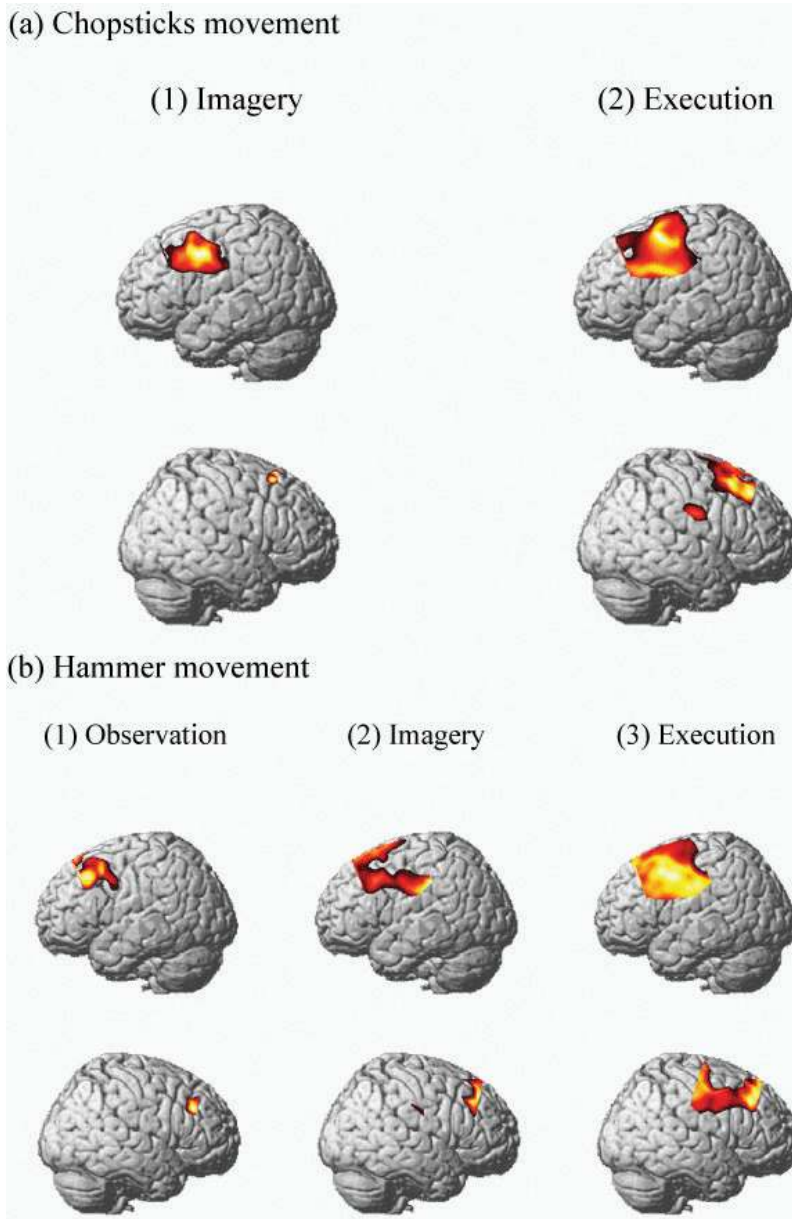


Figure 3. Brain activity during observation, imagery, and execution of tool use [14]. The top row of the images shows the left side of the brain, whereas the bottom row of the images shows the right side of the brain. (a) Brain regions where a significant increase in the oxyhemoglobin (oxyHb) levels was detected during (1) imagery and (2) execution of the chopsticks movement. No significant differences in the oxyHb levels were detected during observation of the chopsticks movement. (b) Brain regions where a significant increase in the oxyHb levels was detected during (1) observation, (2) imagery, and (3) execution of the hammer movement.

2. Clinical studies of motor imagery

Motor imagery studies were conducted on several diseases relating to the central nervous system and acute injuries involving orthopedics such as subacute stroke [15–19], chronic stroke [20–22], traumatic brain injury [23], multiple sclerosis [23], shoulder impingement syndrome [24], postsurgical anterior cruciate ligament [25], postsurgical flexor tendon repair [26], burn injury [27], phantom limb pain [28], complex regional pain syndrome [28, 29], and motor coordination problems [30]. **Table 1** lists motor imagery clinical studies found in PubMed. “Motor imagery” which did not include “Brain Computer Interface (BCI)” or “Brain Machine Interface (BMI)” was used as a finding keyword, and the searched article type was “Randomized Controlled Trial (RCT).”

Nearly all studies reported that the effectiveness of motor imagery in orthopedic diseases was significant. Hoyek et al. investigated the effect of motor imagery on a range of motion and pain in patients with stage II shoulder impingement syndrome [24] and found positive results in the intervention group compared to the control group. This indicates that motor imagery contributes to a range of motion improvements and pain reductions in patients with stage II shoulder impingement syndrome. Lebon et al. investigated the effect of motor imagery on muscle activity in patients with a postsurgical anterior cruciate ligament [25]. The results showed that the intervention group significantly improved compared to the control group, which states that motor imagery improves motor recovery in patients after anterior cruciate ligament surgery. Stenekes et al. examined the effect of motor imagery on hand function during immobilization after flexor tendon repair [26]. The results showed that increased preparation time significantly reduced after the immobilization period in the intervention group compared with the control group. This study disclosed that motor imagery improves hand functions in patients after surgical flexor tendon repair.

The effectiveness of motor imagery in patients with pain is also significant. Moseley et al. investigated the effect of graded motor imagery on pain and swelling in patients with complex regional pain syndrome [24]. The results showed that the neuropathic pain scale and finger circumference both significantly improved after training in the intervention group compared to the control group. Moreover, the improvement was observed for 12 weeks. Another study by Moseley et al. indicated that a motor imagery program for patients with complex regional pain syndrome not displaying a limp was effective. Moseley et al. reported the effect of graded motor imagery on pain and disability in patients with phantom limb pain or complex regional pain syndrome, and the results indicated that pain and disability significantly improved through motor imagery after training in the intervention group compared with the control group. In addition, the effect of the training lasted for 6 months [28].

On the other hand, some studies indicate that motor imagery has both effective and ineffective results for motor recovery in stroke patients. The effects of motor imagery were observed in upper extremity function in subacute [16] and chronic [23] stroke patients, gait function in subacute [15, 18] and chronic [20–22] stroke patients, and balance functions in chronic stroke patients [22]. Motor imagery used for motor recovery showed a lack of results in subacute stroke patients with limited upper extremity function [19], stroke patients struggling with goal attainment and

References	Study design	Type of patients	N	Intervention	Treatment period	Outcome measures and results
Oostra et al. [15]	RCT	Patients with subacute stroke	44	MI + standard rehab vs muscle relaxation + standard rehab	6 weeks	MIQ-RS visual (-) MIQ-RS kinesthetic (+) Imagery walking time/actual walking time (-) 10-m walk test (+) FMA-LE (-)*
Hoyek et al. [24]	RCT	Patients with stage II shoulder impingement syndrome	16	MI + standard rehab vs standard rehab	4 weeks	Constant score (+) ROM (+) Pain VAS (+)
Dickstein et al. [20]	RCT	Patients with chronic stroke	23	Integrated MI practice vs upper extremity rehab	4 weeks	10-m walk test (+) Community ambulation (steps) (-) Community ambulation (maximal activity) (-) Falls efficacy scale (+)*
Sun et al. [21]	RCT	Patients with severe chronic stroke	18	MI + standard rehab vs standard rehab	4 weeks	FMA-UE (+) fMRI
Mihara et al. [16]	RCT	Patients with subacute stroke	20	Real-neurofeedback with MI + standard rehab vs sham-neurofeedback with MI + standard rehab	2 weeks	FMA (+) Action research arm test (-) Motor activity log (-) KVIQ-10 (+)
Cho et al. [22]	RCT	Patients with chronic stroke	28	MI + gait training vs gait training	6 weeks	Functional reach test (+) Timed up-and-go test (+) 10-m walk test (+) FMA (+)
Schuster et al. [17]	RCT	Patients with subacute stroke	39	MI embedded into physiotherapy vs MI added to physiotherapy vs physiotherapy	2 weeks	Motor task (time) (+)* Motor task (help) (+)* KVIQ visual (-) KVIQ kinesthetic (-) Imprax visual (-) Berg balance scale (-) Activities-specific balance confidence scale (-) Wellbeing VAS (-)

References	Study design	Type of patients	N	Intervention	Treatment period	Outcome measures and results
Lebon et al. [25]	RCT	Patients with anterior cruciate ligament injury	20	MI + standard rehab vs standard rehab	5 weeks	Quadriceps EMG activity (+) Pain VAS (+) Anthropometric data (-) Lower extremity functional scale test (-)
Verma et al. [18]	RCT	Patients with subacute stroke	30	Task-oriented circuit class training with MI vs standard rehab	2 weeks	Functional ambulation classification (+) Rivermead visual gait assessment (+) Step length asymmetry (+) Stride length asymmetry (-) Cadence (-) Comfortable walking speed (-) Maximal walking speed (-) 6-minute walk test (-)
Ietswaart et al. [19]	RCT	Patients with subacute stroke	121	MI + standard rehab vs Attention-Placebo Control + standard rehab vs Normal Care Control	4 weeks	Action research arm test (+)* Grip strength (-) Timed manual dexterity task (-) Barthel index (-) Functional limitations profile (-)
Bovend'Eerd et al. [23]	RCT	Patients with stroke, traumatic brain injury, multiple sclerosis	30	Integrated MI program vs standard rehab	5 weeks	Goal attainment scaling (+)* Barthel index (+)* Rivermead mobility index (+)* Nottingham extended ADL index (+)* Action research arm test (+)*
Guillot et al. [27]	RCT	Patients with severe hand burn injury	14	MI + standard rehab vs standard rehab	2 weeks	Spellcaster wrist movement (extension) (-) Spellcaster wrist movement (flexion) (-) Finger opposition task (+) Finger flexion task (+)

References	Study design	Type of patients	N	Intervention	Treatment period	Outcome measures and results
Stenekes et al. [26]	RCT	Patients after surgical flexor tendon repair	28	MI + standard rehab vs standard rehab	6 weeks	Preparation time (+) Michigan hand outcome questionnaire score (-) Hand function VAS (-) Kinematic analysis (-) Active total motion (-) Grip strength (-)
Moseley et al. [28]	RCT	Patients with phantom limb pain, CRPS1	51	Graded MI vs standard rehab	6 weeks	Pain VAS (+) Function NRS (+)
Moseley et al. [29]	RCT	Patients with chronic CRPS1	13	Graded MI vs ongoing medical management	6 weeks	Neuropathic pain scale (+) Finger circumference (+)
Wilson et al. [30]	RCT	Children with motor coordination problems	54	MI training vs Traditional Perceptual-Motor Training vs No-treatment	5 weeks	Total movement assessment battery for children scores (+)

*Significant within-subject factor of time ($P < 0.05$) but no significant between-subject factor of group or interaction time \times group ($P > 0.05$).

RCT, Randomized Controlled Trial; CRPS1, Complex Regional Pain Syndrome type 1; MI, Motor Imagery; MIQ-RS, Movement Imagery Questionnaire-Revised, Second Edition, FMA-UE/LE, Fugl-Meyer Assessment Upper Extremity/Lower Extremity; ROM, Range of Motion; VAS, Visual Analogue Scale, fMRI, functional Magnetic Resonance Imaging; KVIQ, Kineshetic and Visual Imagery Questionnaire; EMG, Electromyogram; NRS, Numerical Rating Scale.

Table 1. Representative clinical studies of motor imagery.

task performance [17], and those with traumatic brain injury and multiple sclerosis [23]. A possible reason for the different effects of motor imagery is the decline of cognitive function after a patient experiences a stroke. A previous study reported that not only motor function but also cognitive function declines after a stroke [31]. Moreover, cognitive function is largely associated with the ability to execute motor imagery [32]. Therefore, the cognitive function level in stroke patients influences the outcome of motor imagery training.

3. Clinical studies of action observation

Clinical studies of action observation were also conducted on a wide range of diseases, such as central nervous system diseases and orthopedic events that include acute stroke [33], sub-acute stroke [34], chronic stroke [35], Parkinson's disease [36, 37], cerebral palsy [38], and orthopedic surgery [39]. **Table 2** lists clinical studies of action observations found in PubMed. "Action observation" was used as a finding keyword, and "Randomized Controlled Trial (RCT)" was the article type that was searched.

The first clinical study of action observation was reported by Ertelt et al. [35]. This study examined the effect of action observation therapy on motor recovery in chronic stroke patients using motor

References	Study design	Type of patients	N	Intervention	Treatment period	Outcome measures and results
Sale et al. [34]	RCT	Patients with subacute stroke	67	AO + standard rehab vs sham-AO + standard rehab	4 weeks	FMA (+) BBT (+)
Pelosin et al. [36]	RCT	Patients with Parkinson's disease	38	AO vs ACOUSTIC vs sham-AO vs AO (on, off)	1 day	Self-paced movement rate (+) Intertapping interval (+) Touch duration (+)*
Buccino et al. [38]	RCT	Children with cerebral palsy	15	AO + standard rehab vs sham-AO + standard rehab	3 weeks	Melbourne Assessment Scale (+)
Franceschini et al. [33]	RCT	Patients with acute stroke	102	AO + standard rehab vs sham-AO + standard rehab	4 weeks	FMA-UE (+)* FAT (-) BBT (+) Modified ashworth scale (-) Functional independence measure motor items (+)*
Bellelli et al. [39]	RCT	Patients after orthopedic surgery		AO + standard rehab vs sham-AO + standard rehab	3 weeks	FIM scores (+) FIM motor subscores (+) Tinetti scores (+) Dependence on walking aids (+)

References	Study design	Type of patients	N	Intervention	Treatment period	Outcome measures and results
Pelosin et al. [37]	RCT	Patients with Parkinson's disease	20	AO + standard rehab vs landscape + standard rehab	4 weeks	FOG Questionnaire (+) Number of FOG episodes (total) (+) Number of FOG episodes (start walking) (+) Number of FOG episodes (turn) (+) Number of FOG episodes (obstacle) (-) Timed up and go test (+) 10-meter walking test (+) Tinetti scale (part I) (+) Berg balance scale (+) Tinetti scale (part II) (+) 39-item PD questionnaire (+)
Ertelt et al. [35]	RCT	Patients with chronic stroke	16	AO + standard rehab vs sham-AO + standard rehab	4 weeks	FAT (+) Wolf motor function test (+) Stroke impact scale (+) fMRI (+)

*Significant within-subject factor of time ($P < 0.05$) but no significant between-subject factor of group or interaction time \times group ($P > 0.05$).

RCT, Randomized Controlled Trial; AO, Action Observation; FMA-UE, Fugl-Meyer Assessment Upper Extremity; BBT, Box and Block Test; FAT, Frenchay Arm Test; FIM, Functional Independence Measure; FOG, Freezing of Gait; fMRI, functional Magnetic Resonance Imaging.

Table 2. Representative clinical studies of action observation.

function outcome and functional magnetic resonance imaging (fMRI). The results showed that motor function after a four-week training significantly improved. Moreover, the improvement was retained for 8 weeks post-training. fMRI during the sensorimotor task of object manipulation showed that significant activations in the bilateral ventral premotor cortex (vPMC), bilateral superior temporal gyrus, supplementary motor area, and the contralateral supramarginal gyrus were observed in the intervention group compared to the control group. This study indicated that action observation has positive effects for motor recovery in stroke patients. Similarly, other studies reported that action observation is effective for motor recovery of upper extremity function in acute stroke patients [33] and for the improvement of motor function in subacute stroke patients [34].

Action observation is also helpful in patients with Parkinson's disease. Pelosin et al. investigated the effect of action observation on gait-freezing (GF) [37]. The results showed that the GF functional score after training significantly improved in both the intervention and control groups. In addition, retention was observed after the four-week training period in only the intervention group. This study indicated that action observation had a positive effect on the walking ability in Parkinson's disease patients displaying GF. In the same manner, another study reported that action observation improved finger function in patients with Parkinson's disease [36].

Action observation is also a useful tool for postsurgical orthopedic patients. Bellelli et al. reported the effect of action observation treatment on motor function in patients who underwent hip arthroplasty, knee arthroplasty, and hip fracture repair [39]. The functional score after training was significantly higher in the intervention group than the control group. This revealed that action observation treatment is effective for postsurgical orthopedic patients.

These studies suggest that the effect of action observation is improved not only in central nervous system diseases but also in orthopedic diseases and events.

4. Application of motor imagery and action observation to physical therapy

As described above, motor imagery and action observation have positive effects on central nervous system diseases, as well as in patients who experienced orthopedic diseases and events.

Kim and Lee reported the comparison of the effects of both action observation and motor imagery training on motor recovery of chronic stroke patients [40]. The results showed significant improvements in a timed up-and-go test, gait speed, cadence, and single limb support of the affected side in motor imagery and action observation groups after training. Although no significant difference was observed between action observation and motor imagery groups, the action observation group showed significant improvement compared with the control group. This study indicated that action observation had positive effects on dynamic balance and gait abilities compared with motor imagery.

The different effects between motor imagery and action observation are associated with the degree of difficulty in training methods. Specifically, action observation uses a bottom-up approach based on sensory information. Human motor control has high dependence on visual information; therefore, as action observation uses the sense of vision, the level of difficulty is lower compared with motor imagery. Additionally, action observation can influence human movement easily. On the other hand, motor imagery uses a top-down approach based on cognitive information. The cognitive function is greatly associated with cognitive information processing. Therefore, the level of difficulty is higher in motor imagery than action observation, especially for stroke patients who see a decline in cognitive function [31]. How then are action observation and motor imagery used for physical therapy?

Gatti et al. revealed that action observation is superior to motor imagery in the early stages of new complex motor learning, as shown by behavioral [41] and EEG data [42]. As described above, motor imagery is influenced by the environment, personal imaging ability, and mental effort. In contrast, action observation is easier to apply, despite activation of the same neural network as motor imagery [43]. In addition, Conson et al. revealed that action observation had an effect of promoting motor imagery [44]. According to these studies, it is recommended that strategies should transfer from action observation performed in the early stages of motor learning to motor imagery performed during the later stages of motor learning.

Graded motor imagery is a similar therapeutic approach that consists of three specific levels of increasing complexity in terms of time and difficulty, which is thought to reflect graded activation of cortical networks [45]. Graded motor imagery includes three consecutive steps: implicit motor imagery, explicit motor imagery, and mirror therapy [46]. Polli et al. investigated the feasibility and clinical effects of graded motor imagery in motor function recovery after a stroke [47]. The results showed that the Wolf Motor Function Test and Fugl-Meyer Assessment after training in the intervention group significantly improved compared to the control group. This study demonstrated that graded motor imagery is a feasible treatment for stroke patients to provide better outcomes than conventional therapy.

Thus, gradually increasing the difficulty level of treatment strategy is recommended. However, motor imagery and action observation are just tools for modulating brain states [48]. Therefore, it is important to choose the appropriate treatment strategy according to functional characteristics and recovery phases of patients in the clinical setting [49].

Acknowledgements

This work was supported by JSPS KAKENHI (Grant Number JP26750208) and ASTEM RI/KYOTO.

Author details

Hideki Nakano* and Takayuki Kodama

*Address all correspondence to: nakano-h@tachibana-u.ac.jp

Department of Physical Therapy, Faculty of Health Science, Kyoto Tachibana University, Kyoto, Japan

References

- [1] Mulder T. Motor imagery and action observation: Cognitive tools for rehabilitation. *J Neural Transm (Vienna)*. 2007;114(10):1265–78.
- [2] Abbruzzese G, Avanzino L, Marchese R, Pelosin E. Action observation and motor imagery: Innovative cognitive tools in the rehabilitation of Parkinson's disease. *Parkinsons Dis*. 2015;2015:1–9.
- [3] Gentili R, Han CE, Schweighofer N, Papaxanthis C. Motor learning without doing: Trial-by-trial improvement in motor performance during mental training. *J Neurophysiol*. 2010;104(2):774–83.
- [4] Gentili R, Papaxanthis C, Pozzo T. Improvement and generalization of arm motor performance through motor imagery practice. *Neuroscience*. 2006;137(3):761–72.

- [5] Héту S, Grégoire M, Saimpont A, Coll MP, Eugène F, Michon PE, Jackson PL. The neural network of motor imagery: An ALE meta-analysis. *Neurosci Biobehav Rev.* 2013;37(5):930–49.
- [6] Gallese V, Fadiga L, Fogassi L, Rizzolatti G. Action recognition in the premotor cortex. *Brain.* 1996;119(Part 2):593–609.
- [7] Rizzolatti G, Fadiga L, Gallese V, Fogassi L. Premotor cortex and the recognition of motor actions. *Brain Res Cogn Brain Res.* 1996;3(2):131–41.
- [8] Fabbri-Destro M, Rizzolatti G. Mirror neurons and mirror systems in monkeys and humans. *Physiology (Bethesda).* 2008;23:171–9.
- [9] Hayes SJ, Elliott D, Bennett SJ. General motor representations are developed during action-observation. *Exp Brain Res.* 2010;204(2):199–206.
- [10] Heyes CM, Foster CL. Motor learning by observation: Evidence from a serial reaction time task. *Q J Exp Psychol A.* 2002;55(2):593–607.
- [11] Vinter A, Perruchet P. Implicit motor learning through observational training in adults and children. *Mem Cognit.* 2002;30(2):256–61.
- [12] Caspers S, Zilles K, Laird AR, Eickhoff SB. ALE meta-analysis of action observation and imitation in the human brain. *Neuroimage.* 2010;50(3):1148–67.
- [13] Filimon F, Nelson JD, Hagler DJ, Sereno MI. Human cortical representations for reaching: Mirror neurons for execution, observation, and imagery. *Neuroimage.* 2007;37(4):1315–28.
- [14] Nakano H, Ueta K, Osumi M, Morioka S. Brain activity during the observation, imagery, and execution of tool use: An fNIRS/EEG study. *J Nov Physiother.* 2012;S1:009.
- [15] Oostra KM, Oomen A, Vanderstraeten G, Vingerhoets G. Influence of motor imagery training on gait rehabilitation in sub-acute stroke: A randomized controlled trial. *J Rehabil Med.* 2015;47(3):204–9.
- [16] Mihara M, Hattori N, Hatakenaka M, Yagura H, Kawano T, Hino T, Miyai I. Near-infrared spectroscopy-mediated neurofeedback enhances efficacy of motor imagery-based training in poststroke victims: A pilot study. *Stroke.* 2013;44(4):1091–8.
- [17] Schuster C, Butler J, Andrews B, Kischka U, Ettlín T. Comparison of embedded and added motor imagery training in patients after stroke: Results of a randomised controlled pilot trial. *Trials.* 2012;13:11.
- [18] Verma R, Arya KN, Garg RK, Singh T. Task-oriented circuit class training program with motor imagery for gait rehabilitation in poststroke patients: A randomized controlled trial. *Top Stroke Rehabil.* 2011;18(Suppl 1):620–32.
- [19] Ietswaart M, Johnston M, Dijkerman HC, Joice S, Scott CL, MacWalter RS, Hamilton SJ. Mental practice with motor imagery in stroke recovery: Randomized controlled trial of efficacy. *Brain.* 2011;134(Part 5):1373–86.

- [20] Dickstein R, Deutsch JE, Yoeli Y, Kafri M, Falash F, Dunsky A, Eshet A, Alexander N. Effects of integrated motor imagery practice on gait of individuals with chronic stroke: A half-crossover randomized study. *Arch Phys Med Rehabil*. 2013;94(11):2119–25.
- [21] Sun L, Yin D, Zhu Y, Fan M, Zang L, Wu Y, Jia J, Bai Y, Zhu B, Hu Y. Cortical reorganization after motor imagery training in chronic stroke patients with severe motor impairment: A longitudinal fMRI study. *Neuroradiology*. 2013;55(7):913–25.
- [22] Cho HY, Kim JS, Lee GC. Effects of motor imagery training on balance and gait abilities in post-stroke patients: A randomized controlled trial. *Clin Rehabil*. 2013;27(8):675–80.
- [23] Bovend'Eerd T, Dawes H, Sackley C, Izadi H, Wade DT. An integrated motor imagery program to improve functional task performance in neurorehabilitation: A single-blind randomized controlled trial. *Arch Phys Med Rehabil*. 2010;91(6):939–46.
- [24] Hoyek N, Di Rienzo F, Collet C, Hoyek F, Guillot A. The therapeutic role of motor imagery on the functional rehabilitation of a stage II shoulder impingement syndrome. *Disabil Rehabil*. 2014;36(13):1113–9.
- [25] Lebon F, Guillot A, Collet C. Increased muscle activation following motor imagery during the rehabilitation of the anterior cruciate ligament. *Appl Psychophysiol Biofeedback*. 2012;37(1):45–51.
- [26] Stenekes MW, Geertzen JH, Nicolai JP, De Jong BM, Mulder T. Effects of motor imagery on hand function during immobilization after flexor tendon repair. *Arch Phys Med Rehabil*. 2009;90(4):553–9.
- [27] Guillot A, Lebon F, Vernay M, Girbon JP, Doyon J, Collet C. Effect of motor imagery in the rehabilitation of burn patients. *J Burn Care Res*. 2009;30(4):686–93.
- [28] Moseley GL. Graded motor imagery for pathologic pain: A randomized controlled trial. *Neurology*. 2006;67(12):2129–34.
- [29] Moseley GL. Graded motor imagery is effective for long-standing complex regional pain syndrome: A randomised controlled trial. *Pain*. 2004;108(1–2):192–8.
- [30] Wilson PH, Thomas PR, Maruff P. Motor imagery training ameliorates motor clumsiness in children. *J Child Neurol*. 2002;17(7):491–8.
- [31] Arsic S, Konstantinovic Lj, Eminovic F, Pavlovic D, Popovic MB, Arsic V. Correlation between the quality of attention and cognitive competence with motor action in stroke patients. *Biomed Res Int*. 2015;2015:823136.
- [32] Munzert J, Lorey B, Zentgraf K. Cognitive motor processes: The role of motor imagery in the study of motor representations. *Brain Res Rev*. 2009;60(2):306–26.
- [33] Franceschini M, Ceravolo MG, Agosti M, Cavallini P, Bonassi S, Dall'Armi V, Massucci M, Schifini F, Sale P. Clinical relevance of action observation in upper-limb stroke rehabilitation: A possible role in recovery of functional dexterity. A randomized clinical trial. *Neurorehabil Neural Repair*. 2012;26(5):456–62.

- [34] Sale P, Ceravolo MG, Franceschini M. Action observation therapy in the subacute phase promotes dexterity recovery in right-hemisphere stroke patients. *Biomed Res Int.* 2014;2014:1–7.
- [35] Ertelt D, Small S, Solodkin A, Dettmers C, McNamara A, Binkofski F, Buccino G. Action observation has a positive impact on rehabilitation of motor deficits after stroke. *Neuroimage.* 2007;36(Suppl 2):T164–73.
- [36] Pelosin E, Bove M, Ruggeri P, Avanzino L, Abbruzzese G. Reduction of bradykinesia of finger movements by a single session of action observation in Parkinson disease. *Neurorehabil Neural Repair.* 2013;27(6):552–60.
- [37] Pelosin E, Avanzino L, Bove M, Stramesi P, Nieuwboer A, Abbruzzese G. Action observation improves freezing of gait in patients with Parkinson's disease. *Neurorehabil Neural Repair.* 2010;24(8):746–52.
- [38] Buccino G, Arisi D, Gough P, Aprile D, Ferri C, Serotti L, Tiberti A, Fazzi E. Improving upper limb motor functions through action observation treatment: A pilot study in children with cerebral palsy. *Dev Med Child Neurol.* 2012;54(9):822–8.
- [39] Bellelli G, Buccino G, Bernardini B, Padovani A, Trabucchi M. Action observation treatment improves recovery of postsurgical orthopedic patients: Evidence for a top-down effect? *Arch Phys Med Rehabil.* 2010;91(10):1489–94.
- [40] Kim JH, Lee BH. Action observation training for functional activities after stroke: A pilot randomized controlled trial. *NeuroRehabilitation.* 2013;33(4):565–74.
- [41] Gatti R, Tettamanti A, Gough PM, Riboldi E, Marinoni L, Buccino G. Action observation versus motor imagery in learning a complex motor task: A short review of literature and a kinematics study. *Neurosci Lett.* 2013;540:37–42.
- [42] Gonzalez-Rosa JJ, Natali F, Tettamanti A, Corsi M, Velikova S, Comi G, Gatti R, Leocani L. Action observation and motor imagery in performance of complex movements: Evidence from EEG and kinematics analysis. *Behav Brain Res.* 2015;281:290–300.
- [43] Buccino G. Action observation treatment: a novel tool in neurorehabilitation. *Philos Trans R Soc Lond B Biol Sci.* 2014;369(1644):20130185.
- [44] Conson M, Sarà M, Pistoia F, Trojano L. Action observation improves motor imagery: Specific interactions between simulative processes. *Exp Brain Res.* 2009;199(1):71–81.
- [45] Moseley GL. Is successful rehabilitation of complex regional pain syndrome due to sustained attention to the affected limb? A randomised clinical trial. *Pain.* 2005;114(1–2):54–61.
- [46] Bowering KJ, O'Connell NE, Tabor A, Catley MJ, Leake HB, Moseley GL, Stanton TR. The effects of graded motor imagery and its components on chronic pain: A systematic review and meta-analysis. *J Pain.* 2013;14(1):3–13.
- [47] Polli A, Moseley LG, Gioia E, Beames T, Baba A, Agostini M, Tonin P, Turolla A. Graded motor imagery for patients with stroke: A non-randomised controlled trial of a new approach. *Eur J Phys Rehabil Med.* 2017;53(1):14–23.

- [48] Vogt S, Di Rienzo F, Collet C, Collins A, Guillot A. Multiple roles of motor imagery during action observation. *Front Hum Neurosci.* 2013;7:807.
- [49] Hatem SM, Saussez G, Della Faille M, Prist V, Zhang X, Dispa D, Bleyenheuft Y. Rehabilitation of motor function after stroke: A multiple systematic review focused on techniques to stimulate upper extremity recovery. *Front Hum Neurosci.* 2016;10:442.