
CBCT Imaging of Paranasal Sinuses and Variations

Kaan Orhan, Secil Aksoy and Ulas Oz

Additional information is available at the end of the chapter

<http://dx.doi.org/10.5772/intechopen.69090>

Abstract

Paranasal sinuses located in the bones surrounding the nasal cavity are called maxillary, ethmoid, frontal and sphenoid sinuses. In relation with their location, these sinuses contribute to the development of the facial structures, jaws and upper airway. During the developmental process of the paranasal sinuses, anatomic variations can occur in consequence of intra and extramural migration of the ethmoid air cells, overpneumatization or hypoplasia of the sinuses and bulging of the neurovascular structures to the sinuses. Some of these anatomic variations may affect the drainage pathways, pave the way for chronic infections and cause difficulties when performing paranasal sinuses surgery. Therefore, the aim of this chapter was to examine the paranasal sinus anatomic variations with cone beam computed tomography (CBCT).

Keywords: cone beam computed tomography, paranasal sinuses, anatomic variations

1. Introduction

Paranasal sinuses are located in the bones surrounding the nasal cavity; and they are called according to anatomical relations such as maxillary, ethmoid, frontal and sphenoid sinuses. The sinuses develop mostly after birth, and their degree of development varies greatly. It is controversial that paranasal sinuses have an aid to facial growth and development or persist as residual remnants of an evolutionary structure found in an additional role as an adjunct to the nasal cavity [1–5]. There are numerous results explaining the function of paranasal sinuses.

In relation with their location, these sinuses contribute to the development of the facial structures, jaws, upper airway, some degree of warmth and humidification to inspired air, thermal isolation, resonance of voice, weight of the skull and expansion of olfactory surfaces.

The paranasal sinuses can act to improve nasal function; they improve the production of nitric oxide and in aiding the immune defences of the nasal cavity [1]. Besides, the sinuses can show adaptability to environmental stress in relation to human facial morphology, for example, human paranasal sinuses have been shown to have higher volumes in individuals living in warmer climates [2, 3].

Additionally, there are findings relating the paranasal sinuses with vascular thermal mechanism. The vascular mechanism in which the arterial blood destined for the brain is cooled by venous blood returning from the evaporating surfaces of the head is called the carotid rete [4]. However, in terms of missing the selective brain cooling mechanism temporarily or permanently, a vascular structure that facilitates counter-current heat exchange is located at the base of the skull in some mammals. In case of lacking a vascular mechanism or an aid to the selective brain cooling system, larger paranasal sinuses and also broader nasal cavity would be providing more evaporating surfaces; such variations have been shown in individuals, especially living in hot climates [4].

Paranasal sinuses may assure harmony in facial growth and make the skull lighter. They also can be seen as a protector of the brain. In prenatal growth and development, the facial cranium distinctly retracts, the maxillary sinus is enlarged because of the new osteogenic activity for erupting molar teeth. During embryogenic life, the functions of the sinuses such as air conditioning progress in harmony with the change in the dental arch and the enlargement of the masticatory muscles.

In addition, the mucociliary apparatus has an important role in maintaining the integrity of the nasal airway and paranasal sinuses as well as that of the rest of the respiratory tract, that is, mucociliary transport relies not only on coordinated ciliary activity but also on mucus and its specific rheological properties.

2. Imaging techniques of paranasal sinuses

2.1. Conventional X rays

The conventional imaging techniques have included Water's (occipitomeatal view), Caldwell (occipitofrontal view), lateral (cephalometric), basal and oblique and submentovertex radiographies for the sinuses.

Sinus X rays are still frequently used in the evaluation of paranasal sinuses. The conventional diagnostic tools of two-dimensional X rays have shown various advantages such as low amount of radiation doses, simple and quick, noninvasive and low-cost advantages. According to recent studies, a low-dose high-resolution three-dimensional scans might be given more accurate diagnostic data for certain conditions such as surgical intervention, anatomic variations and nasal and osteomeatal unit evaluation. However, appearance of new digital two-dimensional systems with numerous features of image enhancement, in addition to the mentioned advantages, might represent digital two-dimensional radiography as a simple and acceptable modality in this field [5].

The Water's view is also known as the occipitomental view, where the X-ray beam is angled at 37° to the canthomeatal line. The radiographic plate is placed positioning towards the face and perpendicular to the midsagittal plane. It is commonly used to view of maxillary sinuses.

Lateral X-ray images show the osteogenic border of maxillary, sphenoid and frontal sinuses. It specially is used to survey the skull and facial bones for evidence of disease, trauma and developmental anomalies in orthodontics. Lateral cephalograms is also used for assessing facial growth.

Caldwell's view projects the osteogenic border of frontal sinus well. It has also included excellent capability in illustrating opacified frontal sinuses and ethmoidal air cells as well as nasal septum deviation [5].

Submentovertex view often is used for evaluating fractures and displacement of fractured zygomatic arch. However, this view is contraindicated with the cases suspected for spinal injury. On the other hand, it reveals the position of the condyles, sphenoid sinus, and the lateral wall of maxillary sinuses, which is an obvious advantage of visualizing of paranasal sinuses' air and fluid levels for sphenoid sinus. But, the view could be ineffective to reveal the degree of chronic inflammatory diseases especially for ethmoid sinuses [6]. Yet some findings such as opacification of the sphenoid sinus in mucocele, the radiographic identification is usually possible [7]. Such inconstancies emphasize the need for more detailed tomography [5–7].

2.2. Computed tomography

Computed tomography (CT) is currently the modality of choice in the evaluation of paranasal sinuses. A variety of CT scans such as conventional and/or cone beam CT techniques offer certain advantages and disadvantages even in comparison with other imaging techniques. Therefore, a primary concern to the clinician evaluating the paranasal sinuses should be conceiving an effective methodology [6–8].

CT imaging of the sinuses has been acquired in the axial, antero-posterior, and coronal planes as well as three-dimensional visual images using contiguous scans [8]. Either two-dimensional or three-dimensional usage of CT scans brings various advantages such as displaying bone and soft tissue anatomy and extent of diseases related with paranasal sinuses and around the paranasal sinuses [6–8]. In contrast, the conventional X-ray imaging methods, CT scans, can guide clearly visualization of the sinus anatomy, ostiomeatal channels, which is extremely useful in the pre-operative planning and in post-operative follow-up in cases of surgical interventions. Thus, the combination of CT scans with additional imaging methods such as functional endoscopy will bring significant advantage to treat particular cases more effectively, facilitating reduced morbidity and complications.

It is well stated that current multi-slice multi-channel CT scanners can acquire slices as thin as 0.5-mm images in any desired plane [6]. In some special conditions, such as lack of availability of multi-channel CT scan, scanning might be routinely finalized with contiguous 3-mm-thick images [6]. Although the diagnostic quality of CT scanning is accepted as sufficient, the radiation dose may be controversial [7, 8]. Therefore, numerous considerable reduction techniques

in radiation exposure alternatives have been the most challenging issue for the manufacturer. Recently, cone beam computed tomography (CBCT) was introduced for dental and maxillofacial imaging [9]. CBCT has several advantages over traditional CT, including lower radiation dose, higher image resolution and lower cost of machine [10]. CBCT scans can be as thin as 0.125 mm, compared to 0.5–3 mm for CT.

2.3. Cone beam computed tomography

CBCT was first described in 1980 and was first applied to dentomaxillofacial radiology in 1998 [11, 12]. CBCT is accepted as one of the pioneering tool assessing paranasal sinuses by dentists, maxillofacial radiologists and otolaryngologists [11]. The technique has several advantages as mentioned above such as higher resolution and lower radiation doses.

3. Variations of paranasal sinuses

During the developmental process of the paranasal sinuses, ethmoid sinuses have a strategic central position. Especially, extramural and intramural expansion of the ethmoid cells causes highly variable anatomy in the nasal complex [13]. These anatomic variations may contribute to the occurrence of the paranasal sinus disease or cause operative complications when performing sinus surgery. While some of the anatomic variations such as concha bullosa, agger nasi cell (ANC), nasal septum deviation, pneumatization of the uncinat process and Haller's cell compromise already narrow the drainage pathways and produce obstruction in the osteomeatal unit (OMU) and thereby recurrent sinusitis [14], others from the onodi cell, protrusion of the internal carotid artery (ICA), optic nerve (ON), vidian canal (VC) and maxillary nerve (MN) to the sphenoid sinus can cause complications such as fatal bleeding, blindness and neurologic sequelae [15]. Consequently, it is necessary to determine the anatomy and the variations of the sinuses, particularly when the patient needs functional endoscopic sinus surgery (FESS).

3.1. Agger nasi cell

Embryologically, the lateral nasal wall has five foetal ridges and six furrows. Each ridge has an ascending and descending part. While some of the ridges and furrows disappear or fuse, some of them compromise the nasal concha. No concha develops from the first ethmoturbinal, but the remnant of the ascending portion forms the ANC [16, 17].

Extramural migration of the anterior ethmoid cells to the frontal process of the maxilla is called ANC [18]. This cell is in a close relationship with the lacrimal bone and affects the shape and size of the frontal recess (FR) anteriorly (**Figure 1**) [16]. Coronal CT images provide the clear identification of the ANC; however, sagittal views demonstrate the relation between the frontal sinus ostium, FR and ANC (**Figure 2**) [19]. The reported prevalence of ANC ranges from 15 to 92% [17, 19–22]. Also, Scribano et al. [23] reported that ANC was seen in nearly all patients. If there is an extensive pneumatization, it is thought that an enlarged ANC may narrow the drainage pathway of the frontal sinus and result in a chronic sinusitis [19]. However, no significant relationship was found between the ANC and frontal sinusitis [17, 20, 21].

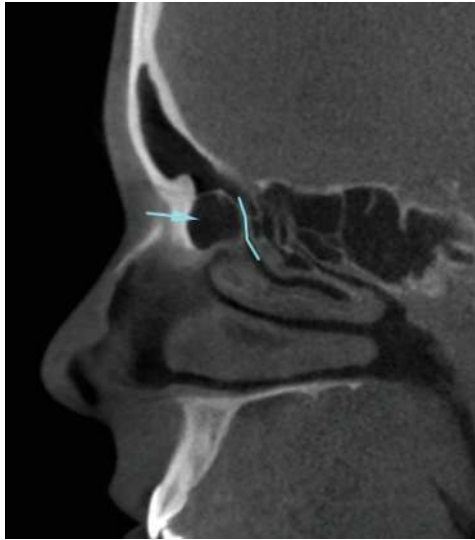


Figure 1. Sagittal CBCT images showing the large ANC (arrow) and its relation with the FR (line).

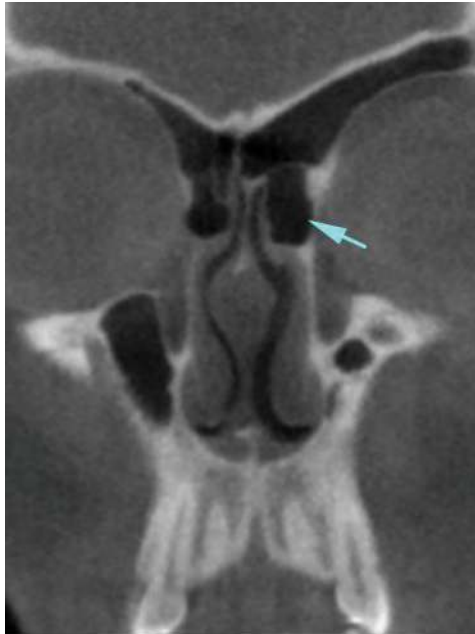


Figure 2. Coronal CBCT showing large ANC (arrow) on the left side which narrows the FR.

3.2. Infraorbital ethmoid cell (Haller's cell)

Haller's cells are defined as extramural migration of the posterior ethmoid cells situated beneath the floor of the orbit (the roof of the maxillary sinus), below the ethmoid bulla, most inferior portion of the lamina papyracea, and lateral to the uncinate process [18, 24]. The frequency rates of Haller's cell have been variously reported to be between 6 and 51% [17, 19–22, 24–27]. These cells are closely related with the maxillary sinus ostium, and according to its size, they may negatively affect the maxillary sinus ventilation (**Figure 3**). Although the presence of this anatomic variant was thought to be a predisposing factor for sinusitis, no statistically significant correlation was found in many studies [17, 20–22, 27]. However, Stackpole and Edelstein [26] classified Haller's cell as small, medium and large, and they found a statistically significant increase in maxillary sinus mucosal disease in patients with medium and large cells than the small ones.

3.3. Onodi (sphenothmoid) cell

Extension of the most posterior ethmoid cells into the sphenoid sinus is termed as the onodi cell. This cell is located in the superolateral wall of the sphenoid sinus and is closely associated with the optic nerve (**Figure 4**) [18]. The reported prevalence of onodi cells is highly variable in the studies. The importance of these cells comes from risk of injury to the optic nerve when performing the sphenoid sinus surgery or the transsphenoidal approach to the hypophyseal fossa and a potential cause of incomplete sphenoidectomy [28]. The mean minimum of bone thickness between the onodi cell and optic nerve was reported as 0.08 mm by Thanaviratnanich et al. [29] in a cadaveric study. Therefore, these nerves are particularly

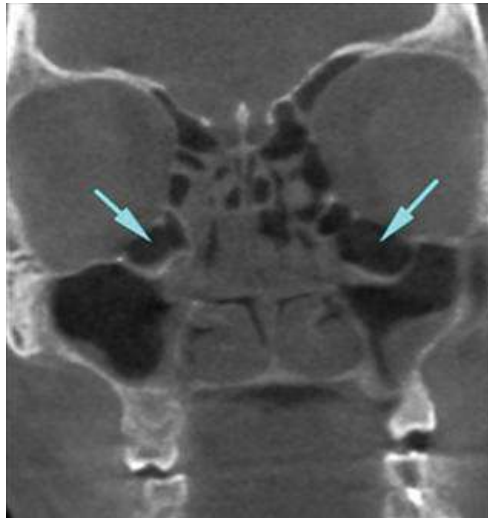

Figure 3. Bilateral huge infraorbital ethmoid cells.

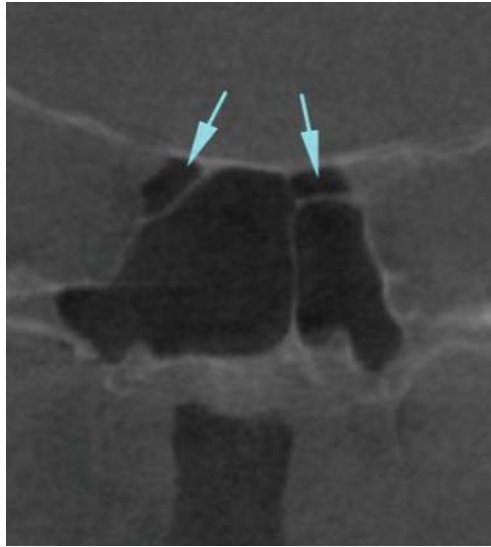

Figure 4. Coronal CBCT images. Bilateral onodi cell and its close relation with the optic nerve.

vulnerable to injury, and orbital complications such as blindness may occur during the surgery. Although optic nerve injury is the most important surgical complication in patients with onodi cells, there are other risks to vision as well. During the transsphenoidal surgery, onodi cells may limit the exposure of the sellar floor and should be removed [30, 31].

Onodi cells are not the single factor of the sphenoid sinusitis; however, with other predisposing factors, they may increase the prevalence of the sphenoiditis [32]. On the other hand, isolated mucoceles in an onodi cell may comprise the optic nerve and cause optic neuropathy [33, 34].

3.4. Concha bullosa

Intramural migration of the posterior ethmoid cells to the middle turbinate is called concha bullosa (CB) [18]. This anatomic variation was divided into three groups according to extent of the pneumatization: lamellar type (pneumatization in the lamellar portion), bulbous type (pneumatization in the bulbous portion; **Figure 5**), and extensive type (pneumatization in the both vertical lamellar and inferior bulbous portion) [35]. The prevalence of the CB varies from 4.6 to 89.5% [17, 20–22, 36–39]. This may be due to the different definition criteria for CB. While some researchers defined the CB as any degree of pneumatization in the middle concha regardless of location, the others restricted CB to specific locations.

CB is often associated with contralateral deviation of the nasal septum [16, 37]. It is still debated in the literature whether CB has a role in sinusitis aetiology. However, in most of the studies, no statistical significant relationship is found between the CB and maxillary sinusitis [17, 20–22, 36–39].

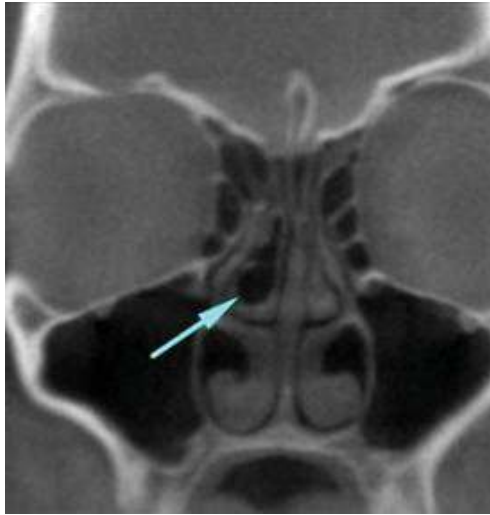

Figure 5. A bulbous type of the CB.

Pneumatization of the superior and inferior turbinate is also called superior and inferior concha bullosa. Superior and inferior CB are rare anatomic variations. If the pneumatization is extensive in the superior concha, it may cause headache with nasal obstruction and mucosal contact without any inflammation [19].

3.5. Uncinate bulla

Pneumatization of the uncinete process is referred to as uncinete bulla (UB) (**Figure 6**). This anatomic variation is believed to be extension of the ANC into the anterosuperior portion of the uncinete process [18]. UB may cause functional blockage of the osteomeatal unit. If the uncinete process is medially displaced and comes in contact with the middle turbinate, it may cause obstruction in OMU [19, 27, 39].

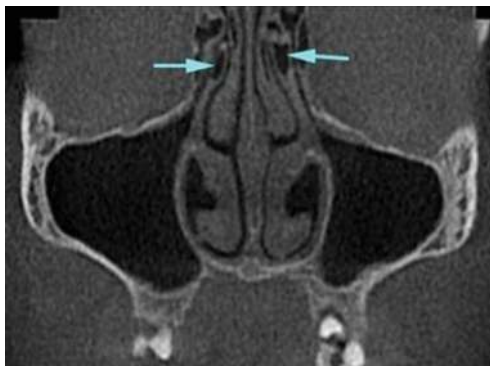


Figure 6. Bilateral uncinete process pneumatization.

3.6. Secondary concha

Secondary inferior, middle, or superior turbinate (**Figure 7**) are very rare anatomical variations. Embryologically, extra turbinates are consisted of secondary invagination and evaginations from the lateral nasal wall [40]. The incidence of the secondary middle turbinate is reported to be between the 2 and 14.3% [17, 19, 40, 41]. Secondary middle turbinate originates from the lateral nasal wall, and posterior part of the middle meatus and lamina papyracea may be damaged during the surgical operation for it [41].

3.7. Ethmomaxillary sinus

Extension of an enlarged posterior ethmoid cell above the maxillary sinus is called ethmomaxillary sinus (EMS). It is important to differentiate the maxillary sinus with septa and EMS [42–44]. While septate maxillary sinus drains into the middle meatus, EMS drains into the superior meatus (**Figure 8**) [43]. EMS is a rare anatomic variation, and the reported incidence of this anatomic variation ranges from 0.7 to 2% [42–44].

3.8. Sphenomaxillary plate

The partition between the ethmoid and maxillary sinus is called ethmomaxillary plate which is triangular in shape. In case of extensive pneumatization as a continuation of the ethmomaxillary plate, a thin-walled separating partition between the sphenoid and maxillary sinus is called sphenomaxillary plate (SMP) (**Figure 9**) [25, 45, 46]. It is important to identify this anatomic variation which may be mistaken for posterior ethmoid cells during transantral ethmoidectomy and increases the risk of inadvertent entry to the sphenoid sinus [45]. Reported incidence of the SMP was 11 [45], 14 [46], and 15% [19].

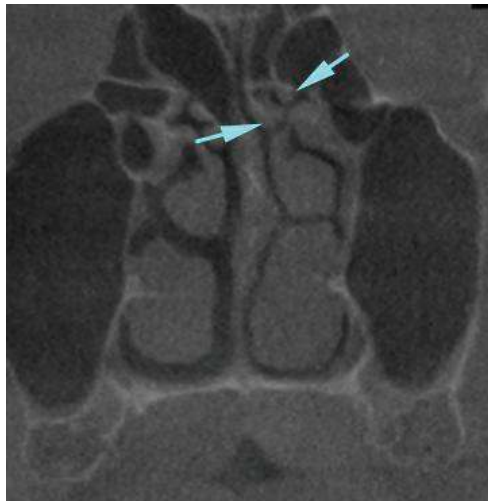

Figure 7. Coronal CBCT images showing the bifid superior turbinate.

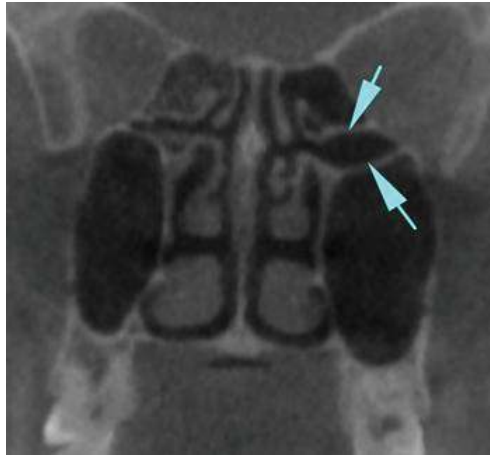


Figure 8. Left-side ethmoidal sinus and its drainage into the superior meatus.

3.9. Sphenoid sinus ICA and MN relations

Sphenoid sinus is located within the body of the sphenoid bone and closely related with the numerous neurovascular structures. ICA and MN lie adjacent to the lateral wall of the sphenoid sinus and during their passage may produce variable bulging into the sinus [18]. These neurovascular structures are covered by a thin bone separating the ICA and MN from the sphenoid sinus mucosa. Sometimes, this bony canal covering is found to be partially dehiscent, and ICA and MN are only covered by the mucoperiosteum. In this situation, neurovascular structures become vulnerable to infection and damage [15, 47].

The prevalence of the ICA bulging (Figure 10) into the sphenoid sinus varies from 3 to 41% [15, 47–51]. In case of bulging, an ICA injury may occur due to a trauma or a complication of sinus disease. If the surgeon is not aware of this variation, fatal haemorrhage can occur; it is

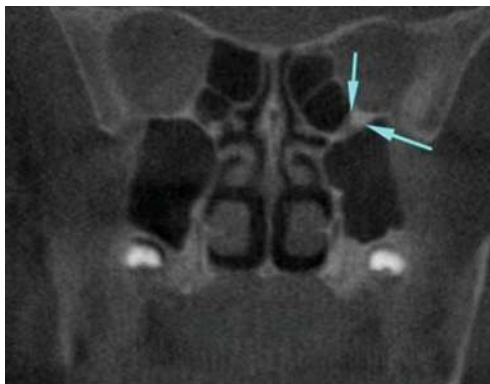

Figure 9. Left-side SMP.

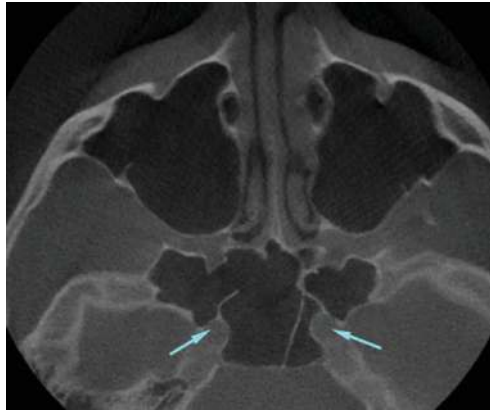


Figure 10. ICA protrusion into the sphenoid sinus bilaterally.

hardly possible to control the bleeding from this artery, and neurological sequelae are inevitable [15, 51]. Another complication during the surgery is if the septum in the sphenoid sinus (**Figure 11**) adheres to the wall of the ICA, the surgeon must be careful about not fracturing it to avoid the artery damage [18, 50].

The frequency rates of MN bulging (**Figure 12**) have been reported to be between 14.2 and 30.3% [47, 50, 51]. MN is also at risk during sphenoid sinus surgery, and sinus pathology may be related with the trigeminal neuralgia [52].

3.10. Pneumatization of the pterygoid, anterior versus posterior clinoid process

There are two definitions about the pterygoid process (PP) pneumatization (**Figure 13**) in the literature. If there is an extensive sphenoid sinus pneumatization that extends beyond a horizontal plane crossing the VC [51], or a plane between the VC and FR [15, 47], it is considered

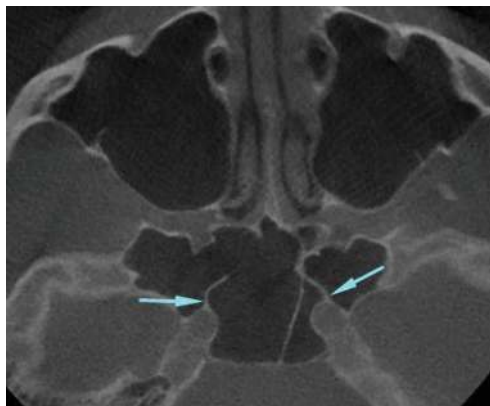


Figure 11. Axial CBCT images. Sphenoid sinus septum adheres to the ICA wall bilaterally.

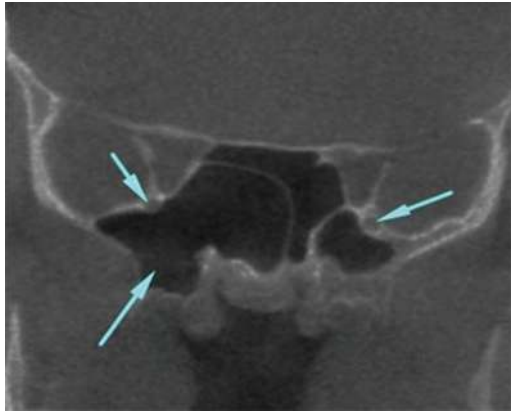


Figure 12. Bilateral MN protrusion into the sphenoid sinus.

that patient has PP pneumatization. If the sinus expands to the pterygoid processes, the sinus floor creates a definite ridge where the vidian channel is located. PP pneumatization may lead to the formation of a potential cavity for the accumulation of sinus-associated purulent exudate [47]. PP pneumatization is a very important surgical route for access to the middle part of the skull base without brain retraction. This route can be used in the endoscopic repair of the leak of cerebrospinal fluid and endoscopic biopsy of skull-base lesions [53].

Pneumatization of the sphenoid sinus may extend into the anterior (**Figure 14**) or posterior clinoid (**Figure 15**) process. In most of the study, ACP pneumatization was found to be significantly associated with the optic nerve protrusion [15, 47, 48, 51].

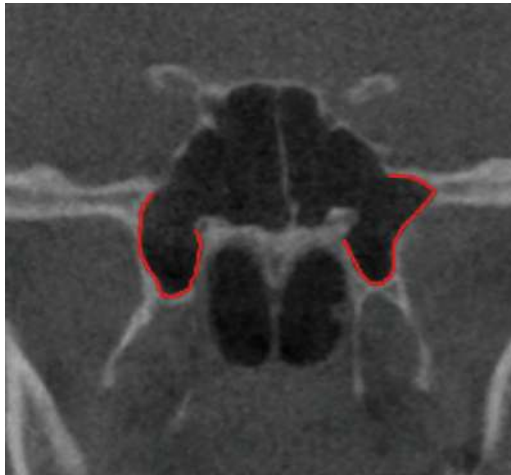

Figure 13. Coronal CBCT images show the bilateral remarkable PP pneumatization.

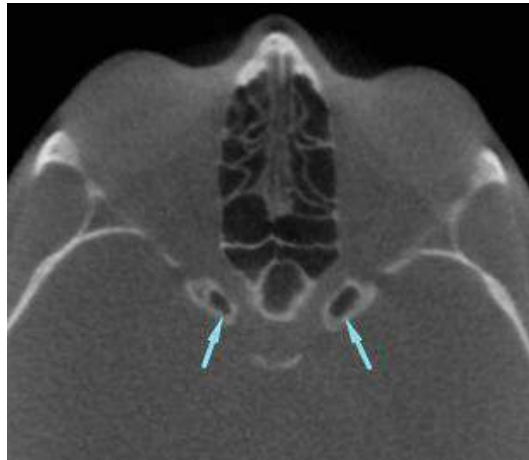


Figure 14. Extensive pneumatization of the sphenoid sinus to the bilateral ACP.

The posterior clinoid process pneumatization prevalence is reported to be 1% by Lu et al. [54].

3.11. Nasal septum deviation and pneumatization

Congenital or acquired deviation could be seen in the nasal septum (**Figure 16**). Deviated nasal septum may compress the middle turbinate laterally and narrow the middle meatus [52]. The reported prevalence of nasal septum deviation ranges from 18 to 75.9% [20, 21, 25, 27, 29, 55].

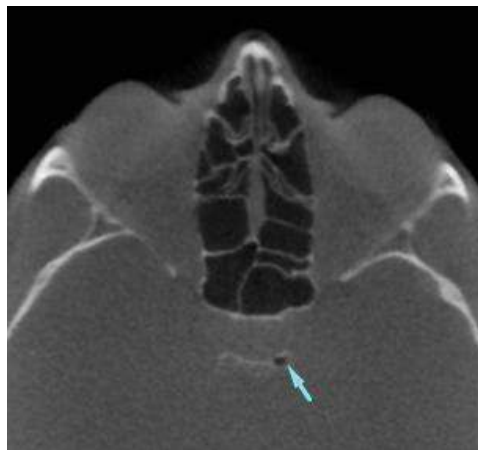


Figure 15. Posterior clinoid process pneumatization on the left side.

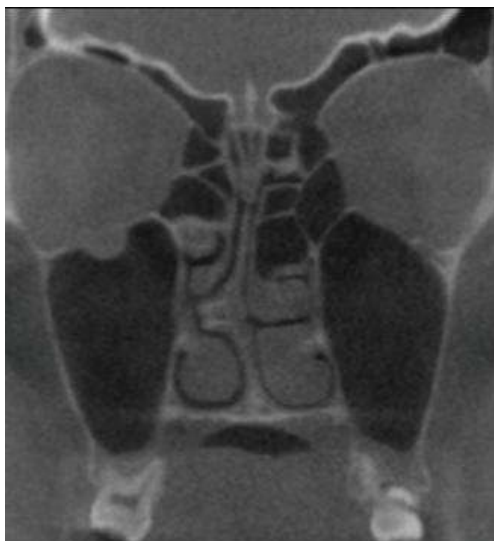

Figure 16. Nasal septum deviation to the right side with a septal spur.

Air cells are usually located within the posterosuperior portion of the nasal septum (**Figure 17**) and related with the sphenoid sinus. These cells may also be affected by any inflammation within the paranasal sinus [18]. This anatomic variation is generally not important but sometimes may narrow the sphenoethmoid recess [52].

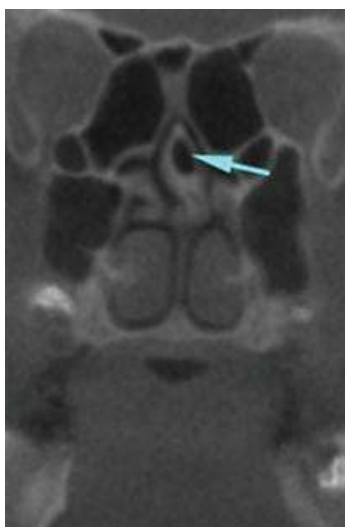


Figure 17. Nasal septum pneumatization.

3.12. Interfrontal sinus septa cell

Interfrontal sinus septa cells (IFSSCs) are defined as discrete air cells in the frontal sinus septum (**Figure 18**) [56]. These cells drain into the one of the FR and are well defined in the coronal and axial scans [57]. The incidence rate in the literature is reported as 12.4 [56] and 14% [58].

3.13. Supraorbital ethmoid cell

Supraorbital ethmoid cell (SOEC) is formed by anterior ethmoid cells that pneumatize the roof of the orbit behind the posterior wall of the frontal sinus (**Figure 19**) [25]. If the pathology in these cells cannot be determined, it may lead to failure of operations performed on the frontal sinus. On coronal images, the presence of bony septum between the ethmoid complex and the recess separates the frontal sinus from the SOEC [18]. These cells drain into the lateral aspect of the FR [57]. Because of the close relation between the SOEC and anterior ethmoidal artery, enlarging the SOEC could risk damage to the artery [59].

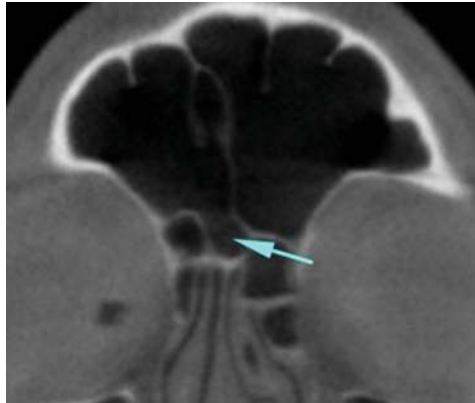


Figure 18. The coronal image shows the IFSSC.

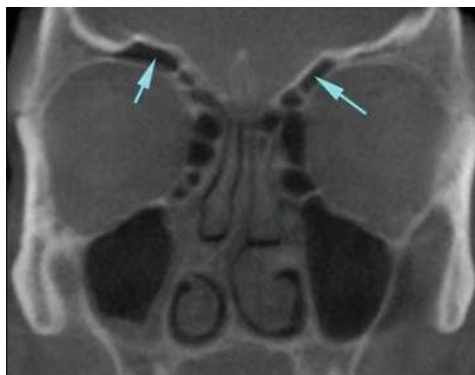

Figure 19. Bilateral supraorbital ethmoid cells.

3.14. Crista galli pneumatization

The pneumatized crista galli (**Figure 20**) is associated with the frontal recess, and with the obstruction of this ostium, chronic sinusitis or mucocele formation may occur in crista galli [18].

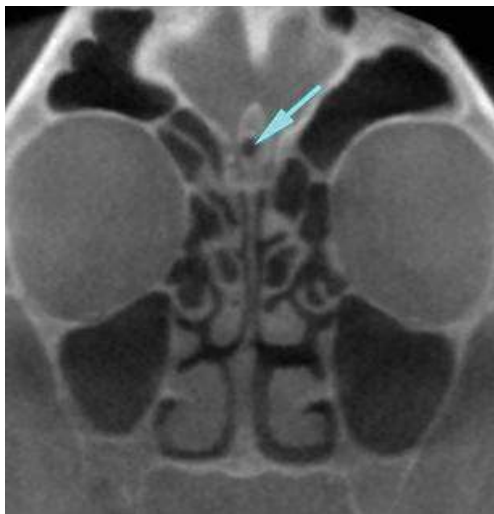

Figure 20. Aeration of the crista galli.

4. Conclusion

Paranasal sinus variations are very common. Before the sinus surgery, CBCT is the best imaging method with lower radiation dose for the determination of sinonasal anatomy.

Author details

Kaan Orhan^{1*}, Secil Aksoy² and Ulas Oz³

*Address all correspondence to: call53@yahoo.com

1 Faculty of Dentistry, Department of Dentomaxillofacial Radiology, Ankara University, Ankara, Turkey

2 Faculty of Dentistry, Department of Dentomaxillofacial Radiology, Near East University, Nicosia, Northern Cyprus

3 Faculty of Dentistry, Department of Orthodontics, Near East University, Nicosia, Northern Cyprus

References

- [1] Keir J. Why do we have paranasal sinuses?. *The Journal of Laryngology & Otology*. 2009;**123**(1):4–8
- [2] Gallup AC, Hack GD. Human paranasal sinuses and selective brain cooling: A ventilation system activated by yawning? *Medical Hypotheses*. 2011;**77**(6):970–973
- [3] Koertvelyessy T. Relationships between the frontal sinus and climatic conditions: A skeletal approach to cold adaptation. *American Journal of Physical Anthropology*. 1972;**37**(2):161–172
- [4] Irmak MK, Korkmaz A, Erogul O. Selective brain cooling seems to be a mechanism leading to human craniofacial diversity observed in different geographical regions. *Medical Hypotheses*. 2004;**63**(6):974–979
- [5] Ebrahimnejad H, Zarch SH, Langaroodi AJ. Diagnostic efficacy of digital waters' and Caldwell's radiographic views for evaluation of sinonasal area. *Journal of Dentistry (Tehran)*. 2016;**13**(5):357–364
- [6] Aygun N, Zinreich SJ. Radiology of the nasal cavity and paranasal sinuses. In: Cummings Otolaryngology: Head & Neck Surgery. 5th ed. Philadelphia, PA: Elsevier Mosby. 2010 pg: 662–663
- [7] Konen E, Faibel M, Kleinbaum Y, Wolf M, Lusky A, Hoffman C, Eyal A, Tadmor R. The value of the occipitontal (Waters') view in diagnosis of sinusitis: A comparative study with computed tomography. *Clinical Radiology*. 2000;**55**(11):856–860
- [8] Fatterpekar GM, Delman BN, Som PM. Imaging the paranasal sinuses: Where we are and where we are going. *The Anatomical Record*. 2008;**291**(11):1564–1572
- [9] Scarfe WC, Farman AG, Sukovic P. Clinical applications of cone-beam computed tomography in dental practice. *Journal-Canadian Dental Association*. 2006;**72**(1):75
- [10] Phothikhun S, Suphanantachat S, Chuenchompoonut V, Nisapakultorn K. Cone-beam computed tomographic evidence of the association between periodontal bone loss and mucosal thickening of the maxillary sinus. *Journal of Periodontology*. 2012;**83**(5):557–564
- [11] Altschuler MD, Censor Y, Eggermont PP, Herman GT, Kuo YH, Lewitt RM, McKay M, Tuy HK, Udupa JK, Yau MM. Demonstration of a software package for the reconstruction of the dynamically changing structure of the human heart from cone beam x-ray projections. *Journal of Medical Systems*. 1980;**4**(2):289–304
- [12] Brüllmann DD, Schmidtman I, Hornstein S, Schulze RK. Correlation of cone beam computed tomography (CBCT) findings in the maxillary sinus with dental diagnoses: A retrospective cross-sectional study. *Clinical Oral Investigations*. 2012;**16**(4):1023–1029
- [13] Márquez S, Tessema B, Clement PA, Schaefer SD. Development of the ethmoid sinus and extramural migration: The anatomical basis of this paranasal sinus. *The Anatomical Record*. 2008;**291**(11):1535–1553

- [14] Dasar U, Gokce E. Evaluation of variations in sinonasal region with computed tomography. *World Journal of Radiology*. 2016;**8**(1):98
- [15] Sirikci A, Bayazit YA, Bayram M, Mumbuc S, Güngör K, Kanlıkama M. Variations of sphenoid and related structures. *European Radiology*. 2000;**10**(5):844–848
- [16] Maroldi R, Borghesi A, Maculotti P. CT and MR anatomy of paranasal sinuses: Key elements. In: *Imaging in Treatment Planning for Sinonasal Diseases*. Berlin, Heidelberg: Springer; 2005. pp. 9–27
- [17] Sivaslı E, Sirikçi A, Bayazıt Y, Gümüşburun E, Erbagci H, Bayram M, Kanlıkama M. Anatomic variations of the paranasal sinus area in pediatric patients with chronic sinusitis. *Surgical and Radiologic Anatomy*. 2002;**24**(6):399–404
- [18] Som PM, Curtin HD. *Head and Neck Imaging*. 5th ed. St. Louis, MO: Elsevier Mosby. 2011 pg: 120–124
- [19] Kantarci M, Karasen RM, Alper F, Onbas O, Okur A, Karaman A. Remarkable anatomic variations in paranasal sinus region and their clinical importance. *European Journal of Radiology*. 2004;**50**(3):296–302
- [20] Al-Qudah M. The relationship between anatomical variations of the sino-nasal region and chronic sinusitis extension in children. *International Journal of Pediatric Otorhinolaryngology*. 2008;**72**(6):817–821
- [21] Jun Kim H, Jung Cho M, Lee JW, Tae Kim Y, Kahng H, Sung Kim H, Hahm KH. The relationship between anatomic variations of paranasal sinuses and chronic sinusitis in children. *Acta Oto-Laryngologica*. 2006;**126**(10):1067–1072
- [22] Nitinavakarn B, Thanaviratananich S, Sangsilp N. Anatomical variations of the lateral nasal wall and paranasal sinuses: A CT study for endoscopic sinus surgery (ESS) in Thai patients. *Journal of the Medical Association of Thailand*. 2005;**88**(6):763–768
- [23] Scribano E, Ascenti G, Cascio F, Racchiusa S, Salamone I. Computerized tomography in the evaluation of anatomic variations of the ostiomeatal complex. *La Radiologia Medica*. 1993;**86**(3):195–199
- [24] Bašić N, Bašić V, Jukić T, Bašić M, Jelić M, Hat J. Computed tomographic imaging to determine the frequency of anatomical variations in pneumatization of the ethmoid bone. *European Archives of Oto-Rhino-Laryngology*. 1999;**256**(2):69–71
- [25] Arslan H, Aydınlioğlu A, Bozkurt M, Egeli E. Anatomic variations of the paranasal sinuses: CT examination for endoscopic sinus surgery. *Auris Nasus Larynx*. 1999;**26**(1): 39–48
- [26] Stackpole SA, Edelstein DR. The anatomic relevance of the Haller cell in sinusitis. *American Journal of Rhinology*. 1997;**11**(3):219–223
- [27] Azila A, Irfan M, Rohaizan Y, Shamim AK. The prevalence of anatomical variations in osteomeatal unit in patients with chronic rhinosinusitis. *The Medical Journal of Malaysia*. 2011;**66**(3):191–194

- [28] Hwang SH, Joo YH, Seo JH, Cho JH, Kang JM. Analysis of sphenoid sinus in the operative plane of endoscopic transsphenoidal surgery using computed tomography. *European Archives of Oto-Rhino-Laryngology*. 2014;**271**(8):2219–2225
- [29] Thanaviratnanich S, Chaisiwamongkol K, Kraitrakul S, Tangsawad W. The prevalence of an Onodi cell in adult Thai cadavers. *Ear, Nose & Throat Journal*. 2003;**82**(3):200
- [30] İmre A, Pinar E, Yüceer N, Songu M, Olgun Y, Aladağ İ. Does Onodi cell limit the exposure of sella during transsphenoidal pituitary surgery? *Kulak Burun Bogaz İhtisas Dergisi: KBB=Journal of Ear, Nose, and Throat*. 2014;**25**(2):82–86
- [31] Shin JH, Kim SW, Hong YK, Jeun SS, Kang SG, Kim SW, Cho JH, Park YJ. The Onodi cell: An obstacle to sellar lesions with a transsphenoidal approach. *Otolaryngology—Head and Neck Surgery*. 2011;**145**(6):1040–1042
- [32] Senturk M, Guler I, Azgin I, Sakarya EU, Ovet G, Alatas N, Tolu I, Erdur O. The role of Onodi cells in sphenoiditis: results of multiplanar reconstruction of computed tomography scanning. *Brazilian journal of otorhinolaryngology*. 2017;**83**:88–93
- [33] Kitagawa K, Hayasaka S, Shimizu K, Nagaki Y. Optic neuropathy produced by a compressed mucocele in an Onodi cell. *American Journal of Ophthalmology*. 2003;**135**(2):253–254
- [34] Lim CT, Dillon WP, McDermott MW. Mucocele involving the anterior clinoid process: MR and CT findings. *American Journal of Neuroradiology*. 1999;**20**(2):287–290
- [35] Bolger WE, Parsons DS, Butzin CA. Paranasal sinus bony anatomic variations and mucosal abnormalities: CT analysis for endoscopic sinus surgery. *The Laryngoscope*. 1991;**101**(1):56–64
- [36] Haruna S, Sawada K, Nakajima T, Moriyama H. Relationship between pediatric sinusitis and middle turbinate pneumatization—ethmoidal sinus pyocele thought to be caused by middle turbinate pneumatization. *International Journal of Pediatric Otorhinolaryngology*. 2005;**69**(3):375–379
- [37] Stallman JS, Lobo JN, Som PM. The incidence of concha bullosa and its relationship to nasal septal deviation and paranasal sinus disease. *American Journal of Neuroradiology*. 2004;**25**(9):1613–1618
- [38] Smith KD, Edwards PC, Saini TS, Norton NS. The prevalence of concha bullosa and nasal septal deviation and their relationship to maxillary sinusitis by volumetric tomography. *International Journal of Dentistry*. 2010;**2010**
- [39] Hatipoglu HG, Cetin MA, Yüksel E. Concha bullosa types: Their relationship with sinusitis, ostiomeatal and frontal recess disease. *Diagnostic and Interventional Radiology*. 2005;**11**(3):145
- [40] El-Shazly AE, Poirrier AL, Cabay J, Lefebvre PP. Anatomical variations of the lateral nasal wall: The secondary and accessory middle turbinates. *Clinical Anatomy*. 2012;**25**(3):340–346

- [41] Ozcan KM, Selcuk A, Özcan I, Akdogan O, Dere H. Anatomical variations of nasal turbinates. *Journal of Craniofacial Surgery*. 2008;**19**(6):1678–1682
- [42] Ozcan KM, Selcuk A, Oruk V, Sarikaya Y, Dere H. Ethmoidmaxillary sinus. *European Archives of Oto-Rhino-Laryngology*. 2008;**265**(2):185–188
- [43] Sirikçi A, Bayazit YA, Bayram M, Kanlıkama M. Ethmoidmaxillary sinus: A particular anatomic variation of the paranasal sinuses. *European Radiology*. 2004;**14**(2):281–285
- [44] Selcuk A, Ozcan KM, Akdogan O, Bilal N, Dere H. Variations of maxillary sinus and accompanying anatomical and pathological structures. *Journal of Craniofacial Surgery*. 2008;**19**(1):159–164
- [45] Nouraei SA, Elisay AR, Dimarco A, Abdi R, Majidi H, Madani SA, Andrews PJ. Variations in paranasal sinus anatomy: Implications for the pathophysiology of chronic rhinosinusitis and safety of endoscopic sinus surgery. *Journal of Otolaryngology – Head and Neck Surgery*. 2009;**38**(1):32
- [46] Meloni F, Mini R, Rovasio S, Stomeo F, Teatini GP. Anatomic variations of surgical importance in ethmoid labyrinth and sphenoid sinus. A study of radiological anatomy. *Surgical and Radiologic Anatomy*. 1992;**14**(1):65–70
- [47] Kazkayasi M, Karadeniz Y, Arikan OK. Anatomic variations of the sphenoid sinus on computed tomography. *Rhinology*. 2005;**43**(2):109–114
- [48] Basak S, Karaman CZ, Akdilli A, Mutlu C, Odabası O, Erpek G. Evaluation of some important anatomical variations and dangerous areas of the paranasal sinuses by CT for safer endonasal surgery. *Rhinology*. 1998;**36**:162–167
- [49] Güldner C, Pistorius SM, Diogo I, Bien S, Sesterhenn A, Werner JA. Analysis of pneumatization and neurovascular structures of the sphenoid sinus using cone-beam tomography (CBT). *Acta Radiologica*. 2012;**53**(2):214–219
- [50] Unal B, Bademci G, Bilgili YK, Batay F, Avci E. Risky anatomic variations of sphenoid sinus for surgery. *Surgical and Radiologic Anatomy*. 2006;**28**(2):195–201
- [51] Hewaidi GH, Omami GM. Anatomic variation of sphenoid sinus and related structures in Libyan population: CT scan study. *Libyan Journal of Medicine*. 2008;**3**(3):1–9
- [52] Beale TJ, Madani G, Morley SJ. Imaging of the paranasal sinuses and nasal cavity: Normal anatomy and clinically relevant anatomical variants. *Seminars in Ultrasound, CT and MRI*. 2009;**30**(1):2–16
- [53] Wang J, Bidari S, Inoue K, Yang H, Rhoton A Jr. Extensions of the sphenoid sinus: A new classification. *Neurosurgery*. 2010;**66**(4):797–816
- [54] Lu Y, Pan J, Qi S, Shi J, Zhang XA, Wu K. Pneumatization of the sphenoid sinus in Chinese: The differences from Caucasian and its application in the extended transsphenoidal approach. *Journal of Anatomy*. 2011;**219**(2):132–142

- [55] Aktas D, Kalcioğlu MT, Kutlu R, Özturan O, Oncel S. The relationship between the concha bullosa, nasal septal deviation and sinusitis. *Rhinology*. 2003;**41**(2):103–106
- [56] Meyer TK, Kocak M, Smith MM, Smith TL. Coronal computed tomography analysis of frontal cells. *American Journal of Rhinology*. 2003;**17**(3):163–168
- [57] Cho JH, Citardi MJ, Lee WT, Sautter NB, Lee HM, Yoon JH, Hong SC, Kim JK. Comparison of frontal pneumatization patterns between Koreans and Caucasians. *Otolaryngology—Head and Neck Surgery*. 2006;**135**(5):780–786
- [58] Lee WT, Kuhn FA, Citardi MJ. 3D computed tomographic analysis of frontal recess anatomy in patients without frontal sinusitis. *Otolaryngology—Head and Neck Surgery*. 2004;**131**(3):164–173
- [59] Zhang L, Han D, Ge W, Tao J, Wang X, Li Y, Zhou B. Computed tomographic and endoscopic analysis of supraorbital ethmoid cells. *Otolaryngology—Head and Neck Surgery*. 2007;**137**(4):562–568

