

# Agreement of collateral grade scoring between single phase CTA and temporal MIPs

Sin Yee Foo<sup>1</sup>, Marta Guarisco<sup>2</sup>, Amith Sitaram<sup>2</sup>, Keith Muir<sup>2</sup>

<sup>1</sup>Department of Neuroradiology, Institute of Neurological Sciences, Glasgow, UK

<sup>2</sup>Institute of Neuroscience and Psychology, University of Glasgow

## INTRODUCTION

Single phase CT Angiography (CTA) is widely available in acute ischaemic stroke (AIS) but the phase of acquisition may affect determination of collateral status. The preferred phase of CTA acquisition is the arterial phase to assess major arterial branch vessel occlusion and recanalization following thrombolytic therapy or thrombectomy. Assessment of collateral status, which has implications on prognosis and response to treatment, as recent literature suggest, is most accurately performed in the venous phase.

We aimed to compare collateral scoring between single phase CTA and multi-phase CTA created from temporal maximal intensity projections (MIPs) derived from CT perfusion scans.

## METHODS

From a database of acute stroke patients imaged <6h after onset with both single phase CT angiography (CTA) and perfusion (CTP), we selected cases with CTA-confirmed ICA or M1 occlusions and retrograde collateral flow. The phase of CTA (arterial, arteriovenous or venous) was determined for single phase CTA using a method described by Casault et. al. Temporal MIPs were derived from CTP 4D angiography, method as described by Smit et. al, again resulting in arterial, arteriovenous and venous phases (Figure 1). Collateral quality was scored independently by two readers (SYF and AS) using the method of Tan et. al. (see Table 1) were scored. Discrepancies were resolved by discussion. Collateral grades on single phase CTA and temporal MIPs using Chi squared tests.

Figure 1: CT perfusion derived temporal MIPs (Left to right: Arterial, Equilibrium, Venous)

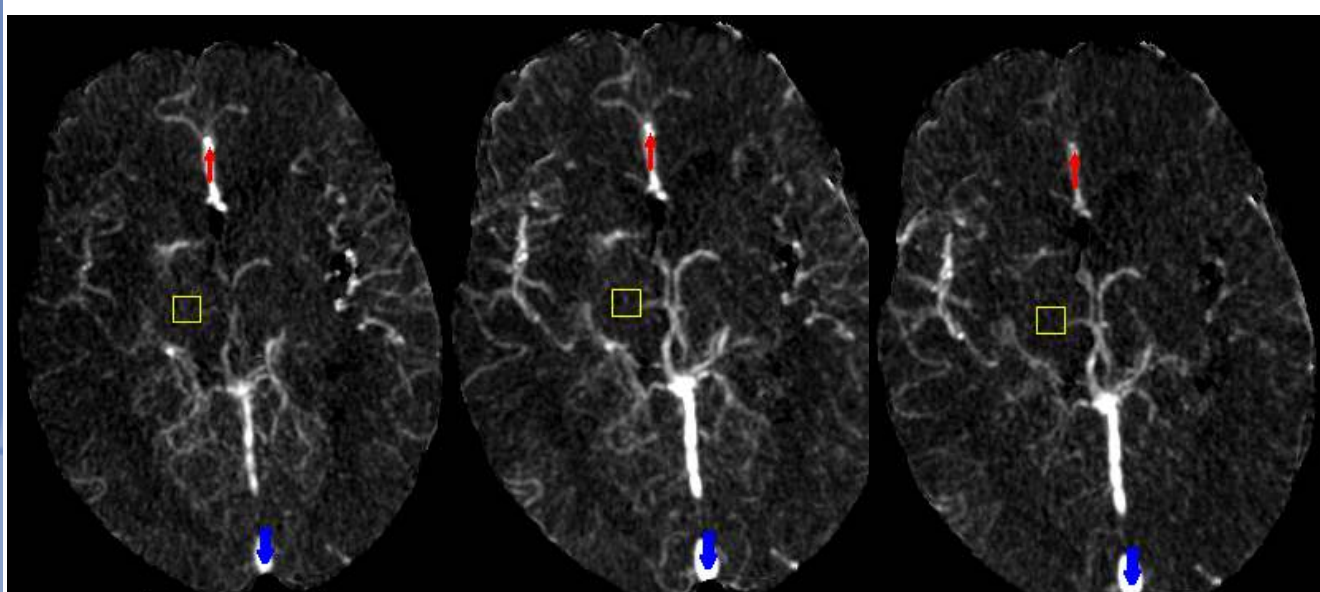


Table 1: Tan et. al scoring system

Score	Description
0	Absent filling – no vessels are visible within the occluded MCA territory
1	Arterial contrast filling of <=50% of the occluded MCA territory
2	Arterial contrast filling was present in >50% but <100% of the occluded MCA territory
3	Arterial contrast filling was present in 100% of the occluded MCA territory

## RESULTS

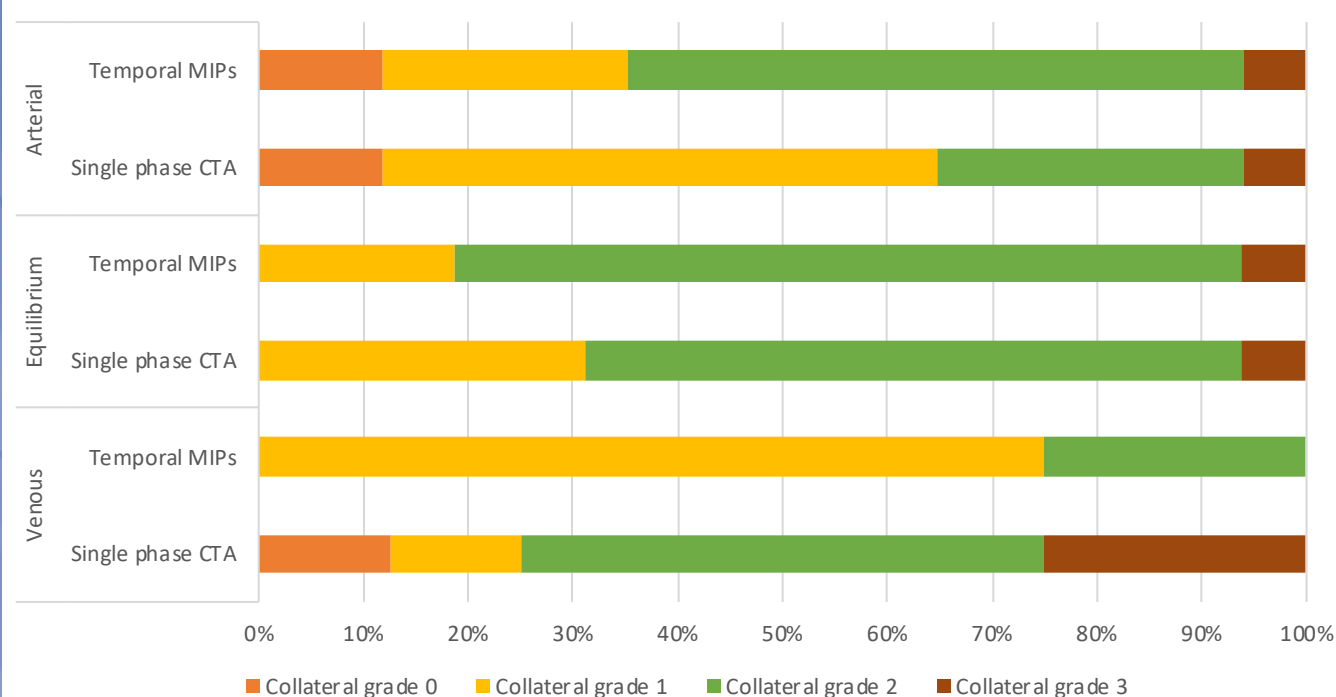
Forty-one proximal occlusions with retrograde collateral flow were included. Patients had a mean age of 73.7 years and median admission NIHSS of 16.

Table 1 shows agreement of collateral grading between single phase CTA and temporal MIPs in each of the three phases. Figure 2 demonstrates the distribution and visual relationship between these two methods of assessment.

Table 2: Agreement of collateral grading

Phase of Scan	Agreement	Disagreement	Kappa value
Arterial (n=17)	6	11	0.242
Equilibrium (n=16)	4	12	0.673
Venous (n=8)	1	7	0.2

Figure 2: Distribution of Collateral Grade according to Method of Assessment and Phase Category



Interobserver agreement for assessment of collateral grades on temporal MIPs was fair (K) = 0.218, 0.346 and 0.31 for arterial, equilibrium and venous phases respectively).

## CONCLUSION

Single phase CTA has moderate agreement with temporal MIPs in the equilibrium phase for collateral assessment, but only fair agreement for arterial or venous phase acquisitions. Observer agreement for collaterals is fair. This study suggests that in a patient who presents with AIS undergoing CT brain, single phase CTA and CTP, a more complete assessment of both arterial occlusion or recanalization and collateral status, is possible.

## REFERENCE

1. Casault C, Al Sultan AS, Trivedi A et al. *Can J Neurol Sci.* 2017 Sep;44(5):503-507
2. Smit EJ, Vonken EJ, van Seeters T, et al. Timing-invariant imaging of collateral vessels in acute ischemic stroke. *Stroke* 2013;44:2194 –99