
Endoscopic Submucosal Dissection for Early Colon Cancer

Valentin Ignatov, Anton Tonev, Nikola Kolev,
Aleksandar Zlatarov, Shteryu Shterev,
Tanya Kirilova and Krasimir Ivanov

Additional information is available at the end of the chapter

<http://dx.doi.org/10.5772/63441>

Abstract

Endoscopic submucosal dissection (ESD) was first implemented in early gastric cancer allowing for en-bloc resection of the lesions. With the experience came the expertise to introduce ESD for early colon cancer (ECC). ESD demonstrates several advantages in comparison with the endoscopic mucosa resection. It allows accurate histological assessment of the depth of invasion, minimizes the risk of local recurrence and helps in the determination of additional therapy. Indications for ESD are placed only after adequate endoscopic morphological classification of the lesions excluding higher risk of nodal metastases. This chapter provides an overview of the application of ESD techniques in ESD for ECC and provides assessment on its technical aspects and complications. In order to decrease the rate of complications a standard protocol for the ESD should be adopted. The protocol includes recommendations for patient selection, bowel and patient preparation, appropriate equipment (knives, endoscopes, and power devices). The chapter will review the current ESD techniques and oncological results. ESD could have great impact on the treatment of early colon cancer. Its role is already proven in rectal localizations and despite the challenges it should be adopted for the colon. Safe strategy for ESD is the cornerstone in decreasing complications, which includes suitable resection of specialized ESD devices.

Keywords: Early colon cancer, endoscopic submucosal dissection, minimally invasive treatment

1. Introduction

The endoscopic treatment method for gastrointestinal neoplastic lesion has developed in recent years. Another modality to the existing techniques is the endoscopic submucosal dissection which is a novel method which broadens the possibilities for endoscopic treatment of neoplastic lesion. First introduced in Japan for early gastric cancer, now the method has advanced and is also applied for early colon cancer. After gaining initial experience the ESD can be used safely on condition that the indications are strictly followed and the technical issues and associated complications are recognized. The chapter will review the current ESD techniques and oncological results. ESD could have great impact on the treatment of early colon cancer. Its role is already proven in rectal localizations and despite the challenges it should be adopted for the colon. Safe strategy for ESD is the cornerstone in decreasing complications, which includes suitable resection of specialized ESD devices.

2. Indications for colonic ESD

The indications for ESD are object of debate. The Colon ESD standardization Implementation Working Group has proposed a draft of "Criteria of Indications for Colorectal ESD). They include large-sized (more than 20 mm in diameter) lesion, which are unsuitable for snare endoscopic mucosal resection, non-granular types of laterally spreading tumours, lesion with type VI pit pattern, cancer with less than 1000 μ m submucosal infiltration, large depressed-type lesions, large elevated lesion, suspected of cancer [1]. Additional indications for ESD include sporadic tumours in IBD, local residual carcinoma after endoscopic piecemeal resection, mucosal lesion with fibrosis, adenoma with non-lifting sign.

The diagnostic process includes chromo-endoscopy, magnified endoscopy, NBI-enhanced magnified endoscopy or EUS. The histological confirmation of diagnosis is not required because the adequate chromo-endoscopic evaluation is confirmed to be sufficient. Biopsy is not always required. The occurring submucosal fibrosis may increase the difficulty of the procedure and the associated risk [2].

3. Muscle retracting sign

Other useful criteria which may help the selection of patients suitable for ESD is the muscle retracting (MR) sign. The MR sign is described as retraction of muscularis propria with submucosal fibrosis. ESD of lesions with positive MR sign is more difficult, which poses as a threat for a safe procedure [2]. Usually in such cases ESD is aborted. The sign is not universally exhibited by all larger lesions with protruding areas, despite the morphological similarities. The conclusion is that MR sign may serve as indication for difficult ESD with risk of resection failure. Therefore it may indicate patients for surgical resection to avoid adverse events and complications of the ESD.

4. CO₂ insufflation

The ESD is performed after insufflation of the colon lumen with CO₂, which has been proven to be effective [3]. It decreases the risk of pneumoperitoneum in cases of perforation and further complications, related to the ESD.

5. Treatment devices

ESD is technically dependent method and various devices have been introduced. Most of them have been developed in Japan [1, 4–21] (**Figure 1**). The devices can be divided in two more general categories: needle-knife type and grasping type.



Figure 1. Devices used for colonic endoscopic submucosal dissection: A: Flush Knife (Fujifilm Medical, Tokyo, Japan); B: Flush Knife Ball Tip (Fujifilm Medical, Tokyo, Japan); C: DualKnife (Olympus Medical Systems Co., Tokyo, Japan); D: B-Knife (Zeon Medical, Tokyo, Japan); E: Splash needle (Pentax Co., Tokyo, Japan); F: Hook Knife (Olympus Medical Systems Co., Tokyo, Japan); G: IT Knife 2 (Olympus Medical Systems Co., Tokyo, Japan); H: Clutch Cutter (Fujifilm, Tokyo, Japan); I: SB knife Jr (Sumitomo Bakelite); J: Hemostat-Y forceps (PENTAX Medical, Germany).

The needle-type knife device has two modifications – uncovered and covered type. The Flush Knife (Fujifilm Medical, Tokyo, Japan), the DualKnife (Olympus Medical Systems Co., Tokyo, Japan), the B-Knife (Zeon Medical, Tokyo, Japan), and the Splash needle (Pentax Co., Tokyo, Japan) belong to the obtuse, short tipped types [22–24]. As suggested by their name, the Flush Knife and the Splash needle also have the capability to inject substances in the submucosa.

This option is very helpful, because it obviates the need to change the injection and the cutting device during the procedure [23, 25]. Having a ball-disk at the tip, the Dual Knife is able to hook the submucosa, separate it from the muscularis propria. In contrast to the monopolar devices, the BKnife is a bipolar knife and therefore it may reduce the risk of complications. The HookKnife is usually used in cases of poor submucosal elevation [26]. Because of the special tip, the submucosa can be hooked and separated from muscularis propria and be safely cut [30]. On the other hand, the DualKnife and the Flush Knife are short tipped and may cause perforation of the thin wall of the colon in the presence of folds. The Flush Knife has two modifications – with needle tip and ball tip. Another product of Olympus Medical Systems Co. is the insulated-tipped knife 2 (IT Knife 2). Its efficacy is reported to be high when used for gastric lesion [27]. The procedure time is reported to be shortened because of the faster dissection time due to the longer blade. It also enables coagulation of small vessels. However, it is difficult to manipulate with this device and the long blade may also cause long perforations. A new device was later introduced, called IT knife nano. Its blade is smaller than of the IT Knife 2 and is targeted for submucosal dissection of the colon.

Author	Year	Country	Number of cases	Main device	Generator
Tamegai et al.	2007	Japan	71	Hook Knife	
Hurlstone et al.	2007	UK	42	Flex knife, IT knife	–
Fujishiro et al.	2007	Japan	200	Flex knife, Hook Knife, electrosurgical knife	ICC-2(X) or VI0300D
Zhou et al.	2009	China	74	Needle-knife, IT knife, Hook Knife	ICC-200
Isomoto et al.	2009	Japan	292	Flex knife, Hash knife, Hook Knife	ICC-200 or VI0300D
Saito et al.	2009	Japan	405	Bipolar needle knife (B-knife), IT knife	–
Iizuka et al.	2009	Japan	38	Flex knife	ICC-200 or VI0300D
Hotta et al.	2010	Japan	120	Flex knife, Flush Knife, Hook Knife	ICC-200 or VI0300D
Niimi et al.	2010	Japan	310	Flex knife, Hook Knife, electrosurgical knife	ICC-200 or VI0300D
Yoshida et al.	2010	Japan	250	Flush Knife	VI0300D
Toyonaga et al.	2010	Japan	512	Flex knife, Flush Knife	–
Matsumoto et al.	2010	Japan	203	Flex knife, Hook Knife, Dual Knife	–
Uraoka et al.	2011	Japan	202	B-Knife, Dual Knife, IT knife, mucosctome	–
Shono et al.	2011	Japan	137	Flush Knife, Hook Knife, precutting knife	–
Kim et al.	2011	Korea	108	Flex knife, Hook Knife	VI0300D
Lee et al.	2011	Korea	499	Flex knife, Hook Knife	VI0300D
Probst et al.	2012	Germany	76	Hook Knife, IT knife, triangle knife	VI0300D
Okamoto et al.	2013	Japan	30	Dual Knife, mucosctome-2	VI0300D
Nawata et al.	2014	Japan	150	SB knife Jr, IT knife nano	–

Table 1. List of most commonly used devices and generators.

The grasping type devices have two major representatives – Clutch Cutter device (Fujifilm, Tokyo, Japan) and SB knife Jr (Sumitomo Bakelite) [21, 28]. The cutting method involves use of grasping type scissor forceps. It avoids fixing the knife to the target, although their use is associated with higher risk of perforation and bleeding after unexpected bowel movement [28]. Another useful device is the Hemostat-Y forceps (H-S2518; Pentax Co., Tokyo, Japan), which is used in bipolar mode to control visible bleeding and minimize the risk of any burning effect on the muscle layer. Some authors describe the use of double-balloon colonoscope in cases of difficult lesion location or to avoid paradoxical movement [29]. The procedure requires electro-surgical device. On **Table 1** are presented the most commonly used generators.

6. Practical aspects of the ESD

The bowel preparation is essential for a successful ESD. Any feces and liquid should be cleared from the colon. If any still remains in the lumen, ESD should not be initiated. The feces do not only prevent adequate dissection, but also pose as a serious treat in case of perforation.

A single channel general lower gastrointestinal endoscope is used for the procedure. Some centres have adopted the use of upper gastrointestinal endoscope. It is slimmer and can be used in retroflexed position [4]. The tip of the endoscope can be fitted with a transparent cap (Olympus Medical Systems Co., Tokyo, Japan).

ESD starts with submucosal injection. It is crucial to maintain adequate elevation during the procedure. Different solutions have been used. Some centres use in their practice two solutions: Glyceol (10% glycerin and 5% fructose; Chugai Pharmaceutical Co., Ltd., Tokyo, Japan) mixed with a small amount of Indigo Carmine and epinephrine, and 0.4% sodium hyaluronate solution (MucoUp; Seikagaku Corp, Tokyo, Japan) [30]. First, small amount of Glyceol is injected in the submucosal layer to confirm the appropriate localization and then MucoUp is injected until proper elevation is achieved. The final step is to inject small amount of Glyceol to flush the residual MucoUp [31]. Repeated submucosal injections are required during the procedure to maintain adequate submucosal elevation [29].

7. Sedation

ESD is usually a long procedure and can continue for more than 2.5 hours. Additionally, the abdominal discomfort caused by gas insufflation causes restlessness. Restlessness due to abdominal fullness and pain occurs frequently in cases with an operation time exceeding 2.5 h. Several medicaments are used for sedation. Some authors report use of midazolam and pentazocine with monitoring by automatic blood pressure monitor. They observed restlessness in 15 out of these 22 cases (68.1%) despite conscious sedation when the procedure lasted more than 2.5 hours. When the procedure lasted less than 2.5 h, restlessness was observed in only 10 out of 83 cases (12.0%) [32]. Carbon dioxide insufflations have also been reported to be effective for the prevention of abdominal fullness [33]. Another option is the use of propofol

for conscious sedation which could be used for longer procedure without restlessness and discomfort [10].

8. Technique of ESD

The process of ESD is divided in several consecutive steps which are presented on **Figure 2**. After adequate elevation of the mucosa has been achieved, the process is initiated. The first step is mucosal incision and simultaneous incision to the deep submucosa layer. The lifting solution is injected at the proximal end of the lesion and mucosal incision is made. Sometimes the insertion of the endoscopic tip into the submucosal layer may become difficult and in these cases trimming of the mucosa is performed. To clear space for dissection after the trimming the submucosal layer near the mucosa is precisely cut. One of the practices for the mucosal incision is to circumvent the tumour. In cases where partial circumferential incision is performed the proximal side of the lesion is incised after the submucosal injection. Various endocut modes are recommended for the incision, which depend on the generator used. The described techniques for incision have their advantages and disadvantages. The circumferential incision may lead to undesired leakage of lifting liquid and loss of submucosal elevation. When injected at the distal side the tumour takes perpendicular to the endoscope position, which may hamper the dissection. The remaining uncut mucosa at the distal side pulls the tumour upward and also changes the position of the tumour. These situations are observed for tumours larger than 50 mm. When the incision is partially circumferential the elevation of the mucosa is easily maintained, because the uncut residual mucosa prevents liquid leakage. On the other hand after the partial resection of the tumour, the residual mucosa may become difficult for resection. Therefore each approach has its advantages and disadvantages. The specific type of incision should be chosen according to the tumour characteristics such as size,

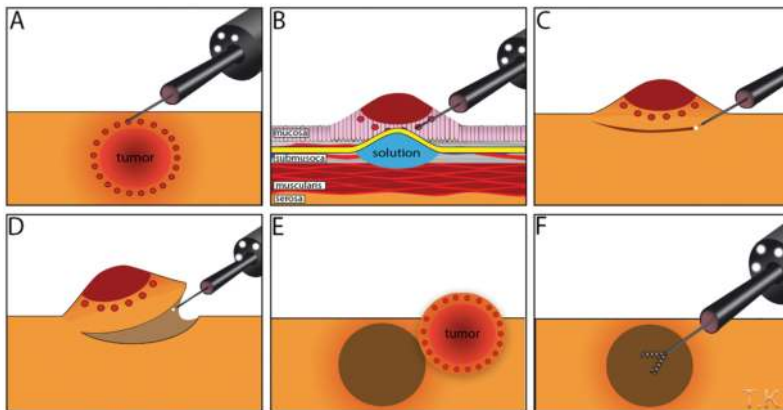


Figure 2. Steps of endoscopic submucosal dissection for early stage colon cancer: A: electrocautery marking around the lesion; B: injection of solution underneath the lesion; C: incision around the lesion; D: lifting and removal of the lesion; E: extraction of the tumor; F: meticulous hemostasis.

location, types of knives. During the submucosal dissection, the endoscopist can easily recognize the advantages of ESD. Structures such as vessels, fibrosis, etc. are clearly visible. Hemorrhage is controlled by precoagulation of the blood vessels. The thinner vessels are coagulated by cutting devices. The thicker ones can be dealt with forceps. Unlike for adenomatous lesion, in cases of early colon cancer the cutting line should be near the mucosal layer in order to achieve R0 resection. This step should be carried out with precision due to the higher perforation risk. The ESD is only finalized after careful inspection for any bleeding vessels. If any are found these are coagulated.

9. Complications

ESD in the colon is technically challenging procedure due to the anatomical characteristic of the colon. The latter is a long luminal organ with many folds, which impede the manipulation of the endoscope. The thin walls are easier to penetrate in comparison to the gastric wall. The insufflated gas during longer procedures may cause paradoxical movement of the endoscope. This situation occurs specifically in tumour, located above the sigmoid colon. It is difficult to find specific studies only on colon ESD. Therefore the presented data will cover also outcomes of colorectal ESD, bearing in mind that the rectal manipulations are easier due to the length of this segment. The rate of perforation of ESD is dramatically high when compared with that observed for endoscopic mucosal resection (EMR) [34–36] and has been reported to be 1.4–10.4%. According to several clinical studies the predicting factors for perforation are large lesions (>30 mm), fibrosis, colonic location and less experience with ESD [12, 22, 37, 38]. (**Table 2**).

The use of knife coagulation is considered the most common cause of perforation [39]. As described in the previous section, the obtuse knives such as DualKnife and the Flush Knife can easily cause perforation. In contrast the Hook Knife is able to hook up the mucosa, separate it from the submucosal layer and cut it safely. Other reasons for perforation include snare resection, coagulation by special haemostatic forceps with soft coagulation, endoscopic clipping onto coagulated submucosa [39]. The complications following ESD for colon tumour can be severe and even fatal in case of peritonitis. Alarming symptoms for perforation are abdominal tympanism, emphysema, and abdominal pain and muscle resistance. Most of the perforation cases are treated conservatively without emergency surgery. Although the closure of the mucus defect is practiced in several centres in Japan, this practice is currently considered impractical and technically challenging with the available devices, e.g. hemo-clips. Endoscopic clipping is possible for small perforation [40, 41]. The abdominal distention can be treated by decompression of the peritoneum via 20 Fr needle [10]. A new closure device which consists of clip with a loop may come in handy [42]. In some cases the perforation is not detected during endoscopy and only later on computed tomography. The possible explanation is that micro-perforations occur during ESD on deep injection by the needle. Those cases are not clinically significant and can be safely treated by conservative measures, such as stopping of oral intake. Another specific case of perforation is the delayed perforation. It accounts to 0.3% to 0.7% of the perforations [4, 5, 43] and is considered to be related to excessive coagulation in the

muscularis propria. Usually delayed perforations are large in size and therefore require emergency surgery [4, 5, 43]. Bleeding after ESD is another common complication. The usual practice is to cut any vessel below 2 mm in diameter with a knife in coagulation mode. For vessels larger than 2 mm in diameter, a special haemostatic forceps should be used in soft coagulation mode. These forceps have the ability to gently catch the vessel and lift it upwards from muscularis propria. The surrounding mucosa around the vessel is also resected with the forceps. Removal of the coagulated vessel and the surrounding submucosa ensures safer and easier submucosal dissection. In cases when bleeding cannot be stopped by the knife the haemostatic forceps can be used as well with SOFT coagulation mode. The rate of postoperative haemorrhage in ESD is reported to be 0–12.0% (**Table 1**) [4, 5, 8–10, 22, 23, 25, 26, 44]. Most cases of postoperative haemorrhage are treated only by endoscopic clipping and withholding oral intake without emergency surgery or blood transfusion.

Author	Year	Country	Number of cases	Post-ESD perforation rate	Bleeding rate
Tamegai et al.	2007	Japan	71	–	1.4%
Hurlstone et al.	2007	UK	42	2.4%	9.5%
Fujishiro et al.	2007	Japan	200	6.0%	0.5%
Zhou et al.	2009	China	74	8.1%	1.4%
Isomoto et al.	2009	Japan	292	7.9%	0.7%
Saito et al.	2009	Japan	405	3.5%	1.0%
Iizuka et al.	2009	Japan	38	7.9%	–
Hotta et al.	2010	Japan	120	7.5%	–
Niimi et al.	2010	Japan	310	4.8%	1.6%
Yoshida et al.	2010	Japan	250	6.0%	2.4%
Toyonaga et al.	2010	Japan	512	1.8%	1.6%
Matsumoto et al.	2010	Japan	203	6.9%	–
Uraoka et al.	2011	Japan	202	2.5%	0.5%
Shono et al.	2011	Japan	137	3.6%	3.6%
Kim et al.	2011	Korea	108	20.4%	–
Lee et al.	2011	Korea	499	7.4%	–
Probst et al.	2012	Germany	76	1.3%	7.9%
Okamoto et al.	2013	Japan	30	0.0%	0.0%
Nawata et al.	2014	Japan	150	0.0%	0.0%

Table 2. Rate of complications after colorectal ESD from single center studies.

Another common effect after ESD is local inflammation to a certain degree. C-reactive protein level may rise to $5,82 \pm 12.10$ mg/L 2 days after the procedure in cases with perforation and

1.27 ± 2.00 mg/L in cases without perforation [45]. Fever and abdominal pain were also reported without perforation. A rare complication was acute colon obstruction after ESD of a colonic tumour located at the cecal base [46].

10. Clinical Studies on Colorectal ESD

Several large series on colorectal ESD have been published from Asian centres. However, most of the data are retrospective, and direct prospective comparative data on ESD versus EMR or surgery are not available. The Japan Society for Cancer of the Colon and Rectum conducted a multi-centre, observational study for all patients treated by conventional endoscopic resection and ESD for colorectal neoplasms exceeding 20 mm in size from October 2007 to December 2010 [9]. A total of 816 lesions were treated by ESD and the short-term outcomes were as follows. The mean lesion size was about 40 mm in diameter. *En bloc* resection was achieved in more than 90% of the cases, regardless of lesion size, with a perforation rate of 2.0% and delayed bleeding rate of 2.2%. None of the perforation cases needed emergency surgery as most

Author	Year	Country	Number of cases	En bloc resection rate	Complete en bloc resection rate
Tamegai et al.	2007	Japan	71	98.6%	95.8%
Hurlstone et al.	2007	UK	42	78.6%	73.8%
Fujishiro et al.	2007	Japan	200	91.5%	70.5%
Zhou et al.	2009	China	74	93.2%	89.2%
Isomoto et al.	2009	Japan	292	90.1%	79.8%
Saito et al.	2009	Japan	405	86.9%	–
Iizuka et al.	2009	Japan	38	60.5%	57.9%
Hotta et al.	2010	Japan	120	93.3%	51.0%
Niimi et al.	2010	Japan	310	90.3%	74.5%
Yoshida et al.	2010	Japan	250	86.8%	81.2%
Toyonaga et al.	2010	Japan	512	98.2%	–
Matsumoto et al.	2010	Japan	203	–	85.7%
Uraoka et al.	2011	Japan	202	90.6%	–
Shono et al.	2011	Japan	137	89.1%	85.4%
Kim et al.	2011	Korea	108	–	78.7%
Lee et al.	2011	Korea	499	95.0%	–
Probst et al.	2012	Germany	76	81.6%	69.7%
Okamoto et al.	2013	Japan	30	100.0%	–
Nawata et al.	2014	Japan	150	98.7%	97.3%

Table 3. Rate of en-bloc resections and complete en-bloc resections after colorectal ESD from single center studies.

iatrogenic perforations is very small, and can be successfully closed with endoscopic clip placement alone followed by intravenous antibacterial therapy (nothing *per os*).

A recent systematic review reported resection rates of 90.5% (61–98.2%) for endoscopic en bloc resection and of 76.9% (58–95.6%) for histologically confirmed complete resection, with associated local recurrence rates of 1.9% (0–11%) (**Table 3**) [30]. In addition, there are several studies with >500 ESD procedures, including large single centre series [47, 48], multi-centre surveys [49, 50], and a prospective multi-centre study [51]. These series confirm the high “en bloc” resection rates (up to 88.8% histologically confirmed complete resections) and the reported complication rates (perforation 4.8–5.4%, delayed perforation 0.4–0.7%, bleeding 1.5–1.7%). It was also demonstrated that ESD is feasible not only for the resection of adenoma or superficial cancers, but is also curative for submucosal invasive cancer. Thus, submucosal invasion limited to the upper 1,000 inlinegraphic m of the submucosal layer (sm1) is sufficiently treated with local resection if the tumour has a G1/G2 differentiation and no lymphatic or vascular invasion (L0, V0) [52–55]. When compared to EMR, data on ESD consistently show a higher en bloc resection rate/lower recurrence rate. Thus, in an analysis of 26 studies on EMR, en bloc resection for relatively smaller target lesions was possible in only 42.6% (19.2–91.8%) and recurrence rates were 17% (4.8–31.4%) for lesions resected in a piecemeal fashion [9]. In addition, several retrospective case series [35, 56–58], a matched case control analysis [59], and a meta-analysis [60] were published on the comparative analysis of EMR versus ESD. All these reports show a higher efficacy of ESD for the resection of larger sessile or flat lesions, resulting in a lower recurrence rate. When analysing risk factors for adenoma recurrence after EMR, associations were reported with size and morphology of the lesions (higher risk of incomplete resection for serrated adenoma/flat adenoma), piecemeal resection, and number of fragments [61–65]. Data on complications after EMR/ESD show similar bleeding rates (EMR 0–11.1%; ESD 0.5–9.5%), but the perforation rate is higher for ESD (1.3–20%) than for EMR (0–5.8%). However, the vast majority of perforations occurring during ESD are small and easily treated during the procedure, and thus the actual need for emergency surgery does not differ for EMR versus ESD [14, 18, 49, 66–68]. ESD is technically demanding and does require long procedure times. Thus, a recent study comparing 1,029 cases of conventional EMR with 816 ESD procedures showed a significantly higher procedure time for ESD (96 min) than for EMR (18 min). Procedure times increased with the size of the lesion, although for very large lesions a comparison to laparoscopic surgery would be more appropriate [66, 67]. Comparative data are available for ESD versus surgery, but again without a formal head-to-head study. Two smaller retrospective studies found no significant difference for efficacy (including procedure time) and safety between ESD versus transanal endoscopic microsurgery (TEM) for the treatment of early rectal cancer [69, 70]. A recently published systematic review and meta-analysis of 11 ESD and 10 TEM studies showed higher en bloc resection rates and a reduced need for additional surgery for TEM, while recurrence rates were significantly lower after ESD and no difference in the overall complication rate was observed [71]. Finally, a comparative retrospective study from the National Cancer Centre Tokyo found that ESD is equally effective as laparoscopic surgery for the treatment of early colorectal cancer, with significantly lower complication rates and shorter procedure times [72]. Indeed, the accompanying editorial called for an initiative to disseminate ESD for optimal treatment of early colorectal cancer [73]. While

larger studies on colorectal ESD are almost exclusively from Asia, data on colorectal ESD from Western countries is mostly limited to the distal colon [9, 19, 74–77](**Table 1**). Taken together, there are considerable advantages of ESD over EMR for the resection of larger sessile or flat lesions, in particular high en bloc resection rates and low recurrence rates. The major problem of ESD is the technical challenge and the relatively long procedure time. Compared with surgery, ESD shows similar performance as TEM for rectal lesions, while a clear advantage – both for clinical outcome and procedure time – was observed in a single comparative study for ESD versus laparoscopic surgery for the treatment of T1 colorectal carcinoma. Nevertheless, there still is a need for prospective comparative trials to better define the role of ESD in comparison to EMR or surgery.

11. Conclusion

ESD is an attractive endoscopic treatment modality for larger sessile or flat adenomas/superficial or slightly submucosal invasive colorectal cancers. ESD is a reliable method for achieving en bloc resection of relatively large colorectal superficial neoplasms, with superior curability. Still, ESD is associated with technical difficulties and complications, including perforation. Therefore patients should be selected for ESD only according to strict criteria, including tumour characteristics. The prerequisite for ESD is proper diagnosis, established by magnifying endoscopy, endoscopic ultrasound, etc. While colorectal ESD has recently become a standard procedure in major Asian endoscopy centres, propagation of ESD in Western countries will critically depend on opportunities for specialized training and probably also on technical developments to facilitate ESD and reduce procedure times.

Author details

Valentin Ignatov, Anton Tonev*, Nikola Kolev, Aleksandar Zlatarov, Shteryu Shterev, Tanya Kirilova and Krasimir Ivanov

*Address all correspondence to: teraton@abv.bg

Department of General and Operative Surgery, Medical University Varna, Bulgaria

References

- [1] Shono T, Ishikawa K, Ochiai Y, Nakao M, Togawa O, Nishimura M, et al. Feasibility of endoscopic submucosal dissection: a new technique for en bloc resection of a large superficial tumor in the colon and rectum. *Int J Surg Oncol*. 2011;2011:948293.

- [2] Toyonaga T, Tanaka S, Man-I M, East J, Ono W, Nishino E, et al. Clinical significance of the muscle-retracting sign during colorectal endoscopic submucosal dissection. *EndoscInt Open*. 2015 May 5;3(03):E246–251.
- [3] Fujishiro M, Kodashima S, Ono S, Goto O, Yamamichi N, Yahagi N, et al. Submucosal injection of normal saline can prevent unexpected deep thermal injury of Argon plasma coagulation in the in vivo porcine stomach. *Gut Liver*. 2008 Sep;2(2):95–98.
- [4] Fujishiro M, Yahagi N, Kakushima N, Kodashima S, Muraki Y, Ono S, et al. Outcomes of endoscopic submucosal dissection for colorectal epithelial neoplasms in 200 consecutive cases. *ClinGastroenterolHepatol*. 2007;5(6):678–683.
- [5] Isomoto H, Nishiyama H, Yamaguchi N, Fukuda E, Ishii H, Ikeda K, et al. Clinicopathological factors associated with clinical outcomes of endoscopic submucosal dissection for colorectal epithelial neoplasms. *Endoscopy*. 2009 Aug;41(8):679–683.
- [6] Matsumoto A, Tanaka S, Oba S, Kanao H, Oka S, Yoshihara M, et al. Outcome of endoscopic submucosal dissection for colorectal tumors accompanied by fibrosis. *Scand J Gastroenterol*. 2010;45(11):1329–1337.
- [7] Matsui N, Akahoshi K, Nakamura K, Ihara E, Kita H. Endoscopic submucosal dissection for removal of superficial gastrointestinal neoplasms: A technical review. *World J GastrointestEndosc*. 2012 Apr 16;4(4):123–136.
- [8] Tamegai Y, Saito Y, Masaki N, Hinohara C, Oshima T, Kogure E, et al. Endoscopic submucosal dissection: a safe technique for colorectal tumors. *Endoscopy*. 2007 May; 39(5):418–422.
- [9] Hurlstone DP, Atkinson R, Sanders DS, Thomson M, Cross SS, Brown S. Achieving R0 resection in the colorectum using endoscopic submucosal dissection. *Br J Surg*. 2007 Dec;94(12):1536–1542.
- [10] Zhou P-H, Yao L-Q, Qin X-Y. Endoscopic submucosal dissection for colorectal epithelial neoplasm. *Surg Endosc*. 2009 Jul;23(7):1546–1551.
- [11] Saito Y, Sakamoto T, Fukunaga S, Nakajima T, Kiriya S, Kuriyama S, et al. Endoscopic submucosal dissection (ESD) for colorectal tumors. *Dig Endosc Off J JpnGastroenterolEndosc Soc*. 2009 Jul;21Suppl 1:S7–12.
- [12] Iizuka H, Okamura S, Onozato Y, Ishihara H, Kakizaki S, Mori M. Endoscopic submucosal dissection for colorectal tumors. *GastroentérologieClin Biol*. 2009;33(10–11):1004–11.
- [13] Hotta K, Oyama T, Shinohara T, Miyata Y, Takahashi A, Kitamura Y, et al. Learning curve for endoscopic submucosal dissection of large colorectal tumors. *Dig Endosc*. 2010;22(4):302–306.

- [14] Niimi K, Fujishiro M, Kodashima S, Goto O, Ono S, Hirano K, et al. Long-term outcomes of endoscopic submucosal dissection for colorectal epithelial neoplasms. *Endoscopy*. 2010 Sep;42(09):723–729.
- [15] Yoshida N, Naito Y, Kugai M, Inoue K, Wakabayashi N, Yagi N, et al. Efficient hemostatic method for endoscopic submucosal dissection of colorectal tumors. *World J Gastroenterol WJG*. 2010 Sep 7;16(33):4180–4186.
- [16] Toyonaga T, Man-i M, Chinzei R, Takada N, Iwata Y, Morita Y, et al. Endoscopic treatment for early stage colorectal tumors: the comparison between EMR with small incision, simplified ESD, and ESD using the standard flush knife and the ball tipped flush knife. *ActaChirIugosl*. 2010;57(3):41–46.
- [17] Uraoka T, Higashi R, Kato J, Kaji E, Suzuki H, Ishikawa S, et al. Colorectal endoscopic submucosal dissection for elderly patients at least 80 years of age. *SurgEndosc*. 2011 Sep;25(9):3000–3007.
- [18] Kim ES, Cho KB, Park KS, Lee KI, Jang BK, Chung WJ, et al. Factors predictive of perforation during endoscopic submucosal dissection for the treatment of colorectal tumors. *Endoscopy*. 2011 Jul;43(7):573–578.
- [19] Probst A, Golger D, Anthuber M, Märkl B, Messmann H. Endoscopic submucosal dissection in large sessile lesions of the rectosigmoid: learning curve in a European center. *Endoscopy*. 2012 Jul;44(7):660–667.
- [20] Okamoto K, Kitamura S, Muguruma N, Takaoka T, Fujino Y, Kawahara Y, et al. Mucosectom2-short blade for safe and efficient endoscopic submucosal dissection of colorectal tumors. *Endoscopy*. 2013 Nov;45(11):928–930.
- [21] Nawata Y, Homma K, Suzuki Y. Retrospective study of technical aspects and complications of endoscopic submucosal dissection for large superficial colorectal tumors. *Dig Endosc Off J JpnGastroenterolEndosc Soc*. 2014 Jul;26(4):552–555.
- [22] Saito Y, Uraoka T, Matsuda T, Emura F, Ikehara H, Mashimo Y, et al. Endoscopic treatment of large superficial colorectal tumors: a case series of 200 endoscopic submucosal dissections (with video). *GastrointestEndosc*. 2007 Nov;66(5):966–973.
- [23] Toyonaga T, Man-I M, Morita Y, Sanuki T, Yoshida M, Kutsumi H, et al. The new resources of treatment for early stage colorectal tumors: EMR with small incision and simplified endoscopic submucosal dissection. *Dig Endosc Off J JpnGastroenterolEndosc Soc*. 2009 Jul;21Suppl 1:S31–37.
- [24] Fujishiro M, Kodashima S, Goto O, Ono S, Muraki Y, Kakushima N, et al. Technical feasibility of endoscopic submucosal dissection of gastrointestinal epithelial neoplasms with a splash-needle. *SurgLaparoscEndoscPercutan Tech*. 2008 Dec;18(6):592–597.
- [25] Takeuchi Y, Uedo N, Ishihara R, Iishi H, Kizu T, Inoue T, et al. Efficacy of an endo-knife with a water-jet function (Flushknife) for endoscopic submucosal dissection of superficial colorectal neoplasms. *Am J Gastroenterol*. 2010 Feb;105(2):314–322.

- [26] Yoshida N, Naito Y, Sakai K, Sumida Y, Kanemasa K, Inoue K, et al. Outcome of endoscopic submucosal dissection for colorectal tumors in elderly people. *Int J Colorectal Dis.* 2010 Apr;25(4):455–461.
- [27] Saito Y, Kawano H, Takeuchi Y, Ohata K, Oka S, Hotta K, et al. Current status of colorectal endoscopic submucosal dissection in Japan and other Asian countries: progressing towards technical standardization. *Dig Endosc Off J JpnGastroenterolEndosc Soc.* 2012 May;24Suppl 1:67–72.
- [28] Akahoshi K, Akahane H, Murata A, Akiba H, Oya M. Endoscopic submucosal dissection using a novel grasping type scissors forceps. *Endoscopy.* 2007 Dec;39(12):1103–1105.
- [29] Jung YS, Park DI. Submucosal injection solutions for endoscopic mucosal resection and endoscopic submucosal dissection of gastrointestinal neoplasms. *GastrointestInterv.* 2013;2(2):73–77.
- [30] Matsuda T, Fujii T, Saito Y, Nakajima T, Uraoka T, Kobayashi N, et al. Efficacy of the invasive/non-invasive pattern by magnifying chromoendoscopy to estimate the depth of invasion of early colorectal neoplasms. *Am J Gastroenterol.* 2008 Nov;103(11):2700–2706.
- [31] Hayashi N, Tanaka S, Hewett DG, Kaltenbach TR, Sano Y, Ponchon T, et al. Endoscopic prediction of deep submucosal invasive carcinoma: validation of the narrow-band imaging international colorectal endoscopic (NICE) classification. *GastrointestEndosc.* 2013 Oct;78(4):625–632.
- [32] Yoshida N, Yagi N, Naito Y, Yoshikawa T. Safe procedure in endoscopic submucosal dissection for colorectal tumors focused on preventing complications. *World J Gastroenterol.* 2010 Apr 14;16(14):1688–1695.
- [33] Saito Y, Uraoka T, Matsuda T, Emura F, Ikehara H, Mashimo Y, et al. A pilot study to assess the safety and efficacy of carbon dioxide insufflation during colorectal endoscopic submucosal dissection with the patient under conscious sedation. *GastrointestEndosc.* 2007;65(3):537–542.
- [34] Tanaka S, Haruma K, Oka S, Takahashi R, Kunihiro M, Kitadai Y, et al. Clinicopathologic features and endoscopic treatment of superficially spreading colorectal neoplasms larger than 20 mm. *GastrointestEndosc.* 2001 Jul;54(1):62–66.
- [35] Saito Y, Fukuzawa M, Matsuda T, Fukunaga S, Sakamoto T, Uraoka T, et al. Clinical outcome of endoscopic submucosal dissection versus endoscopic mucosal resection of large colorectal tumors as determined by curative resection. *SurgEndosc.* 2010 Feb;24(2):343–352.
- [36] Iishi H, Tatsuta M, Iseki K, Narahara H, Uedo N, Sakai N, et al. Endoscopic piecemeal resection with submucosal saline injection of large sessile colorectal polyps. *GastrointestEndosc.* 2000 Jun;51(6):697–700.

- [37] Jeong G, Lee JH, Yu MK, Moon W, Rhee P-L, Paik SW, et al. Non-surgical management of microperforation induced by EMR of the stomach. *Dig Liver Dis Off J Ital Soc Gastroenterol Ital Assoc Study Liver*. 2006 Aug;38(8):605–608.
- [38] Seebach L, Bauerfeind P, Gubler C. “Sparing the surgeon”: clinical experience with over-the-scope clips for gastrointestinal perforation. *Endoscopy*. 2010 Dec;42(12):1108–1111.
- [39] Yoshida N, Wakabayashi N, Kanemasa K, Sumida Y, Hasegawa D, Inoue K, et al. Endoscopic submucosal dissection for colorectal tumors: technical difficulties and rate of perforation. *Endoscopy*. 2009 Sep;41(09):758–761.
- [40] Fujishiro M, Yahagi N, Kakushima N, Kodashima S, Muraki Y, Ono S, et al. Successful nonsurgical management of perforation complicating endoscopic submucosal dissection of gastrointestinal epithelial neoplasms. *Endoscopy*. 2006 Oct;38(10):1001–1006.
- [41] Uraoka T, Kawahara Y, Kato J, Saito Y, Yamamoto K. Endoscopic submucosal dissection in the colorectum: present status and future prospects. *Dig Endosc*. 2009;21:S13–16.
- [42] Sakamoto N, Beppu K, Matsumoto K, Shibuya T, Osada T, Mori H, et al. “Loop Clip”, a new closure device for large mucosal defects after EMR and ESD. *Endoscopy*. 2008 Sep;40Suppl 2:E97–98.
- [43] Toyonaga T, Man-I M, Ivanov D, Sanuki T, Morita Y, Kutsumi H, et al. The results and limitations of endoscopic submucosal dissection for colorectal tumors. *ActaChirIugosl*. 2008;55(3):17–23.
- [44] Tanaka S, Oka S, Kaneko I, Hirata M, Mouri R, Kanao H, et al. Endoscopic submucosal dissection for colorectal neoplasia: possibility of standardization. *GastrointestEndosc*. 2007;66(1):100–107.
- [45] Yoshida N, Kanemasa K, Sakai K. Experience of endoscopic submucosal dissection (ESD) to colorectal tumor-especially about clinical course of cases with perforation. 2008 [cited 2016 Jan 8]; Available from: http://inis.iaea.org/Search/search.aspx?orig_q=RN:39103526
- [46] Park SY, Jeon SW. Acute intestinal obstruction after endoscopic submucosal dissection: report of a case. *Dis Colon Rectum*. 2008 Jun 7;51(8):1295–1297.
- [47] Yoshida N, Yagi N, Inada Y, Kugai M, Yanagisawa A, Naito Y. Prevention and management of complications of and training for colorectal endoscopic submucosal dissection. *Gastroenterol Res Pract*. 2013;2013:287173.
- [48] Lee E-J, Lee JB, Lee SH, Kim DS, Lee DH, Lee DS, et al. Endoscopic submucosal dissection for colorectal tumors--1,000 colorectal ESD cases: one specialized institute’s experiences. *SurgEndosc*. 2013 Jan;27(1):31–39.

- [49] Tanaka S, Terasaki M, Kanao H, Oka S, Chayama K. Current status and future perspectives of endoscopic submucosal dissection for colorectal tumors. *Dig Endosc.* 2012;24(s1):73–79.
- [50] Tanaka S, Tamegai Y, Tsuda S, Saito Y, Yahagi N, Yamano H. Multicenter questionnaire survey on the current situation of colorectal endoscopic submucosal dissection in Japan. *Dig Endosc.* 2010;22(s1):S2–8.
- [51] Saito Y, Uraoka T, Yamaguchi Y, Hotta K, Sakamoto N, Ikematsu H, et al. A prospective, multicenter study of 1111 colorectal endoscopic submucosal dissections (with video). *GastrointestEndosc.* 2010 Dec;72(6):1217–1225.
- [52] Oka S, Tanaka S, Kanao H, Ishikawa H, Watanabe T, Igarashi M, et al. Mid-term prognosis after endoscopic resection for submucosal colorectal carcinoma: summary of a multicenter questionnaire survey conducted by the colorectal endoscopic resection standardization implementation working group in Japanese Society for Cancer of the Colon and Rectum. *Dig Endosc Off J JpnGastroenterolEndosc Soc.* 2011 Apr;23(2):190–194.
- [53] S Y, M W, H H, H B, K Y, J S, et al. The risk of lymph node metastasis in T1 colorectal carcinoma. *Hepatogastroenterology.* 2003 Dec;51(58):998–1000.
- [54] Bosch SL, Teerenstra S, de Wilt JHW, Cunningham C, Nagtegaal ID. Predicting lymph node metastasis in pT1 colorectal cancer: a systematic review of risk factors providing rationale for therapy decisions. *Endoscopy.* 2013 Oct;45(10):827–834.
- [55] Carrara A, Mangiola D, Pertile R, Ricci A, Motter M, Ghezzi G, et al. Analysis of risk factors for lymph nodal involvement in early stages of rectal cancer: When can local excision be considered an appropriate treatment? Systematic review and meta-analysis of the literature. *Int J SurgOncol.* 2012 Jun 19;2012:e438450.
- [56] Lee E-J, Lee JB, Lee SH, Youk EG. Endoscopic treatment of large colorectal tumors: comparison of endoscopic mucosal resection, endoscopic mucosal resection–precutting, and endoscopic submucosal dissection. *SurgEndosc.* 2012 Jan 26;26(8):2220–2230.
- [57] Terasaki M, Tanaka S, Oka S, Nakadoi K, Takata S, Kanao H, et al. Clinical outcomes of endoscopic submucosal dissection and endoscopic mucosal resection for laterally spreading tumors larger than 20 mm. *J GastroenterolHepatol.* 2012 Apr;27(4):734–740.
- [58] Tajika M, Niwa Y, Bhatia V, Kondo S, Tanaka T, Mizuno N, et al. Comparison of endoscopic submucosal dissection and endoscopic mucosal resection for large colorectal tumors. *Eur J GastroenterolHepatol.* 2011 Nov;23(11):1042–1049.
- [59] Kobayashi N, Yoshitake N, Hirahara Y, Konishi J, Saito Y, Matsuda T, et al. Matched case-control study comparing endoscopic submucosal dissection and endoscopic mucosal resection for colorectal tumors. *J GastroenterolHepatol.* 2012 Apr;27(4):728–733.

- [60] Cao Y, Liao C, Tan A, Gao Y, Mo Z, Gao F. Meta-analysis of endoscopic submucosal dissection versus endoscopic mucosal resection for tumors of the gastrointestinal tract. *Endoscopy*. 2009 Sep;41(09):751–757.
- [61] Pohl H, Srivastava A, Bensen SP, Anderson P, Rothstein RI, Gordon SR, et al. Incomplete polyp resection during colonoscopy—Results of the complete adenoma resection (CARE) Study. *Gastroenterology*. 2013;144(1):74–80.e1.
- [62] Woodward TA, Heckman MG, Cleveland P, De Melo S, Raimondo M, Wallace M. Predictors of Complete Endoscopic Mucosal Resection of Flat and Depressed Gastrointestinal Neoplasia of the Colon. *Am J Gastroenterol*. 2012;107(5):650–4.
- [63] Kim HH, Kim JH, Park SJ, Park MI, Moon W. Risk factors for incomplete resection and complications in endoscopic mucosal resection for lateral spreading tumors. *Dig Endosc*. 2012;24(4):259–266.
- [64] Mannath J, Subramanian V, Singh R, Telakis E, Ragunath K. Polyp recurrence after endoscopic mucosal resection of sessile and flat colonic adenomas. *Dig Dis Sci*. 2011 Feb 16;56(8):2389–2395.
- [65] Sakamoto T, Matsuda T, Otake Y, Nakajima T, Saito Y. Predictive factors of local recurrence after endoscopic piecemeal mucosal resection. *J Gastroenterol*. 2012 Jan 6;47(6):635–640.
- [66] Ohata K, Nonaka K, Minato Y, Misumi Y, Tashima T, Shozushima M, et al. Endoscopic submucosal dissection for large colorectal tumor in a Japanese general hospital. *J Oncol*. 2013;2013:218670.
- [67] Nakajima T, Saito Y, Tanaka S, Iishi H, Kudo S, Ikematsu H, et al. Current status of endoscopic resection strategy for large, early colorectal neoplasia in Japan. *SurgEndosc*. 2013 Sep;27(9):3262–3270.
- [68] Lee E-J, Lee JB, Choi YS, Lee SH, Lee DH, Kim DS, et al. Clinical risk factors for perforation during endoscopic submucosal dissection (ESD) for large-sized, nonpedunculated colorectal tumors. *SurgEndosc*. 2012 Jun;26(6):1587–1594.
- [69] Kawaguti FS, Nahas CSR, Marques CFS, Martins B da C, Retes FA, Medeiros RSS, et al. Endoscopic submucosal dissection versus transanal endoscopic microsurgery for the treatment of early rectal cancer. *SurgEndosc*. 2014 Apr;28(4):1173–1179.
- [70] Park SU, Min YW, Shin JU, Choi JH, Kim Y-H, Kim JJ, et al. Endoscopic submucosal dissection or transanal endoscopic microsurgery for nonpolypoid rectal high grade dysplasia and submucosa-invading rectal cancer. *Endoscopy*. 2012 Nov;44(11):1031–1036.
- [71] Arezzo A, Passera R, Saito Y, Sakamoto T, Kobayashi N, Sakamoto N, et al. Systematic review and meta-analysis of endoscopic submucosal dissection versus transanal endoscopic microsurgery for large noninvasive rectal lesions. *SurgEndosc*. 2014 Feb; 28(2):427–438.

- [72] Kiriya S, Saito Y, Yamamoto S, Soetikno R, Matsuda T, Nakajima T, et al. Comparison of endoscopic submucosal dissection with laparoscopic-assisted colorectal surgery for early-stage colorectal cancer: a retrospective analysis. *Endoscopy*. 2012 Nov;44(11):1024–1030.
- [73] Swanström LL. Treatment of early colorectal cancers: too many choices? *Endoscopy*. 2012 Nov;44(11):991–992.
- [74] Farhat S, Chaussade S, Ponchon T, Coumaros D, Charachon A, Barrioz T, et al. Endoscopic submucosal dissection in a European setting. A multi-institutional report of a technique in development. *Endoscopy*. 2011 Aug;43(8):664–670.
- [75] Repici A, Hassan C, Pagano N, Rando G, Romeo F, Spaggiari P, et al. High efficacy of endoscopic submucosal dissection for rectal laterally spreading tumors larger than 3 cm. *GastrointestEndosc*. 2013 Jan;77(1):96–101.
- [76] Thorlacius H, Uedo N, Toth E. Implementation of endoscopic submucosal dissection for early colorectal neoplasms in Sweden. *Gastroenterol Res Pract*. 2013;2013:758202.
- [77] Sauer M, Hildenbrand R, Bollmann R, Sido B, Dumoulin FL. Tu1426 Endoscopic Submucosal Dissection (ESD) of large sessile and flat neoplastic lesions in the colon: a single-center series with 83 procedures from Europe. *GastrointestEndosc*. 2014 May;79(5):AB536.