

---

# Introductory Chapter: Introduction to Advanced Concepts in Endocarditis

---

Michael S. Firstenberg

Additional information is available at the end of the chapter

<http://dx.doi.org/10.5772/intechopen.79883>

---

## 1. Introduction

Infective endocarditis is a broad topic that encompasses various types of infections of the heart and is typically used to describe abscess cavities, infectious or inflammatory vegetations on cardiac structures such as valves or implanted prosthetic devices, fistulae, or areas of localized infectious tissue destruction. Without a doubt, infectious problems involving the heart or cardiac structures represent a formidable diagnostic and therapeutic clinical problem. Furthermore, despite advances in medical and surgical therapies—some of which are highlighted in this text—there are concerns that there are significant increases in the number of cases reported. Even more concerning are some of the issues that have resulted in the increased incidence of endocarditis case and what impact these issues might have on how individual patients are managed and how society approaches this complex (and expensive) medical, surgical, and—now—social problem.

It is also becoming more apparent that even relatively minor procedures are associated with a risk of infecting both native and prosthetic cardiac structures [1]. Historically, it was assumed that procedures, such as dental work, had a significant role in the development of endocarditis and other procedures, such as endoscopic evaluations, had a minimal role, and therefore prophylactic antibiotics before all such “minor” procedures were not necessary. However, recent evidence suggests that there is a much greater risk for post-procedure endocarditis than initially thought—especially those with inherently abnormal cardiac structures, such as mitral valve prolapse or bicuspid aortic valves [2].

The epidemiology of infections reflects not only the dark side of the progresses in medical therapy but also some of the social problems that plague modern society. The changing microbiology also reflects how this complex disease has also paralleled the advances in medicine. Diagnostic tools continue to evolve with not only improvements in imaging technologies but also our understandings on how to appropriately use them to better understand the overall clinical picture. In addition, the role of therapies—especially early surgical intervention—has

been demonstrated to have a significant impact on the management and outcomes of infected patients. The goal of this text is to highlight some of the current concepts in the clinical characteristics, the presentation, the diagnosis, and the management options.

## 2. Epidemiology

There has been a significant increase in the overall incidence of infectious endocarditis—and there are many reasons for this. The two, probably, most important fundamental reasons are the growing number of patients with substantial comorbidities who are receiving therapies involving prosthetic material implanted into their hearts. Many of these patients have comorbidities that historically might have contraindicated advanced cardiac therapies (including heart valve surgery) years ago. Such comorbidities included not only frailty and advanced age but end-stage renal disease, history of solid or bone marrow transplantation, chronic high-intensity immunosuppression, and multiple previous cardiac procedures. In addition, the fact that medical advances have resulted in these “sick” patients living longer, even if the absolute rate (i.e., cases/year) did not change, the total number of cases would increase as the overall population at risk over time has increased.

The second growing population of patients at risk for developing endocarditis are patients with a history of intravenous substance abuse—and even more so, those who continue to abuse IV drugs having already undergone a surgical procedure to repair/replace an infected cardiac valve [3, 4]. The global burden of substance abuse and the impact of infectious endocarditis are only recently been the sources of focused investigation with a growing appreciation of the magnitude of the problem [5]. Many of these patients tend to be younger—and as a function of their greater physiologic reserve, difficulties in getting appropriate access to healthcare and the means in which they become infected can result in this population presenting much later in the course of an infection with advanced cardiac structural destruction and are more likely to have polymicrobial or fungal infections. As many of these patients have received suboptimal therapy for their nonspecific presentations and symptoms, late presentations after weeks, or even months, of therapies for “viral syndromes,” “community acquired pneumonias,” or even “cellulitis” from local infections at the site of infection are not uncommon. Noncompliance with medical therapy, combined with mistrust in the healthcare system, in this population might also predispose them to presenting late in their disease. Nevertheless, as more patients receive advanced cardiac therapies—such as catheter-based valve replacements, implantable cardioverter defibrillators, pacemakers, intravascular remote pressure monitors, and ventricular assist devices—the risks for developing device-related infections are substantial and growing [6, 7]. Unfortunately, the growth in the overall utilization of these devices in sicker patients has exceeded our overall understanding of how to reduce, prevent, or provide prophylaxis against potential infections [8–10]. Furthermore, with the growing understanding of the natural history of endocarditis, risk factors for developing infections, the management of specific types of infections and their presenting complication, long-term outcomes of both medical and surgical therapies, and the overall heterogeneous

spectrum of clinical presentation, medical and surgical teams are becoming better at individualizing care plans.

### 3. Microbiology

A growing challenge has also been the “war” between evolving resistant bacteria, multidrug-resistant organisms, polymicrobial infections, and opportunistic fungi and the drug therapies that are available to safely and appropriately treat these infections. Such infections clearly have been shown to be predictors of poor outcomes and are often primary indications for urgent surgical intervention [11]. While advances in techniques used for testing of genetic techniques and cellular markers have improved the ability to define a causative agent, this does not inherently imply that such infectious are any easier to treat [12]. In addition, the growing recognition of “sepsis” and aggressiveness toward early treatment and diagnostic evaluations might have a secondary effect on the earlier recognition and overall incidence of diagnosing endocarditis. Nevertheless, without a doubt, the growing and routine use of immune modulating medications for common diseases such as rheumatoid arthritis, inflammatory bowel disease, and psoriasis (just to name a few) has also increased the incidence of unusual bacterial and fungal infections—of which progressing to endocarditis is common [13]. Another growing population is those adults with congenital heart disease. Many of these patients have had multiple previous surgical procedures involving prosthetic material and are, in general, living longer—both are risk factors for developing endocarditis [14, 15]. In addition, while the overall focus tends to be on infectious causes, there is clearly much to learn about noninfectious causes of endocarditis such as marantic or Libman-Sacks endocarditis [16].

### 4. Diagnosis

While it is often believed that positive blood cultures are the sine qua non in the diagnosis of endocarditis, it must be recognized that patients can often present with extensive destruction, and involvement of their cardiac structures has negative cultures. The original Duke Criteria has for many years provided the foundation for the diagnostic criteria of endocarditis [17]. However, advances in imaging technology and broader application of such technology have also proven to be extremely useful in the management of infected patients and guiding therapy [18]. Historically, transthoracic and transesophageal imaging were considered and still are first-line diagnostic tests to evaluate patients with suspected endocarditis—and current guidelines and appropriateness criteria continue to support their liberal use [2, 12]. The role of other imaging modalities, such as 3D echocardiography, computed tomography (CT), magnetic resonance imaging, and positron-emission tomography (PET) is expanding [19, 20]. Furthermore, not only is early use of advanced imaging well established in the diagnosis and management of endocarditis; it is clear that there should be a low threshold for repeat imaging to follow the response to medical therapies or, more specifically, help identify those patients who are failing medical therapy and might benefit from surgical intervention.

## 5. Therapy

Early involvement of a multidisciplinary team, as discussed below, is critical to the successful management of these complex patients. As many of these patients will require prolonged course of targeted antibiotics, compliance can be an issue even in the most motivated patients. These patients often require close follow-up to ensure that recommended treatment plans are not only adhered to but, more importantly, successful in eradicating the infection resulting in symptomatic valvular destruction. While it might be easy for the provider to “prescribe” a prolonged course of antibiotic therapy, successful completion often involves a recognition of the multiple socioeconomic issues that are keys to success. Many patients do not have the ability or resources to comply with daily (or more frequent) outpatient therapies—and clearly, prolonged hospital stays to complete a course of antibiotics is no longer reasonable nor practical. As such, care teams are often forced to become “creative” in discharge and treatment planning to individualize therapy within the framework of social support, financial resources, and patient factors. Such care plans might not follow established guidelines strictly, but as long as all involved—especially the patient through shared decision-making—understand the risks, benefits, goals, and options, then unconventional plans might be more likely to clinically succeed in the long run than guideline-based therapies that are, at an individual level, unreasonable and unlikely to succeed.

Probably one of the most important aspects in the management of endocarditis is identifying those patients who might benefit from surgical management. While current guidelines, as discussed below and in several chapters in this text, can help provide indications for surgery, the decision to operate is not always so simple. Patients often present critically ill, neurologic complications such as embolic strokes are common, and often there are complex comorbidities and surgical technical issues (i.e., previous cardiac surgery) that must be considered in the decision-making process of when to operate—and, just as importantly, what operation to perform.

Case by case surgical judgment (and experience) is often required to determine which structures can and should be preserved as opposed to which structures might require aggressive debridement and replacement. Surgeons must caution against the concept of “exercises in technique over judgement.” While repairing an infected valve might limit the risk of reinfected prosthetic material or the need for re-intervention for a failing (or infected) artificial heart valve, it must be also recognized that failed repairs are not without short- and long-term risks and complications either both in terms of reinfection from inadequate debridement of infected tissue and from the development of heart failure or structure complications from valvular dysfunction. A significant challenge is also the timing of surgery in the setting of systemic infections and complications—especially neurologic complication [21]. As discussed, each case requires a delicate balance when evaluating the potential risks and benefits of early versus delayed surgical therapy. However, without a doubt, early and aggressive intervention has been shown to improve overall outcomes at both the individual and population level. Such changes in the paradigm from delayed surgical management to earlier intervention are well established in current European and American Society guidelines, based upon randomized trials and extensive clinical experience, and discussed in further detail throughout this text [22–24].

Even though there is some variability in the specific indications, and level of evidence to support for surgical therapy, in general early surgery should be considered in those patients who present with the following signs and symptoms [25]:

1. Early surgery is recommended for those patients with fungal infections or highly resistant organisms.
2. Valvular dysfunction resulting in signs or symptoms of acute heart failure.
3. Those patients who present with cardiovascular complications directly associated with their infections including new heart block, aortic or root, or annular abscess cavities or penetrating infectious complications such as fistula might benefit from early surgery.
4. Surgery is indicated in the setting of persistent bacteremia or fever greater than 5–7 days in the absence of another identifiable primary source in the setting of appropriate targeted antibiotic therapy.
5. Enlarging vegetations despite appropriate antibiotic therapy or evidence of recurrent embolic complications.
6. Vegetations that are mobile and greater than 1 cm and/or with evidence of severe valve regurgitation.
7. Mobile vegetations that are greater than 1 cm especially in the setting of other relative indications for surgery and when involving the anterior leaflet of the mitral valve.

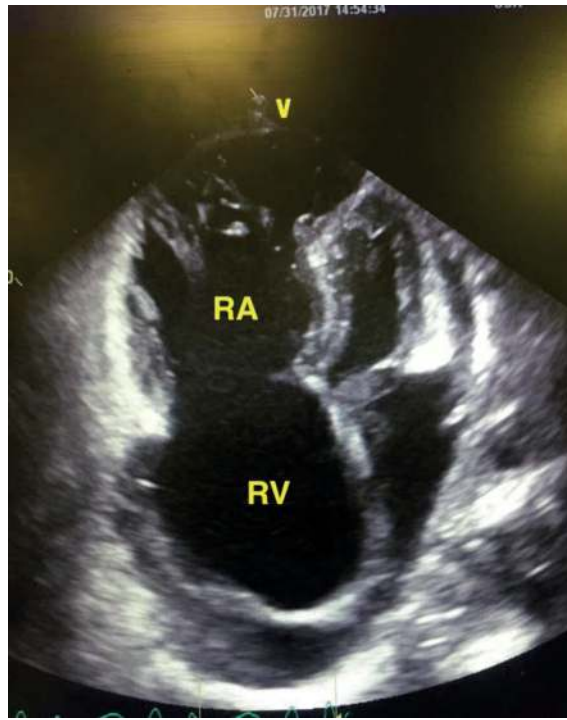
Similar recommendations are used to guide therapy in patients with prosthetic valve endocarditis [26]. As discussed at length in the chapter on prosthetic valve infectious, it must be recognized that medical management is rarely successful, and despite what might be considered prohibitive surgical risks, the best chance at a long-term durable cure of infected prosthetic material often requires removal and replacement.

As previously mentioned, the worldwide substance abuse epidemic has resulted in a significant increase in patients presenting with right-sided endocarditis (i.e., involvement of the tricuspid valve). Because of historical concerns of relapse, noncompliance, and unclear indications for surgical intervention, many of these patients were treated medically—with treatment failures often blamed on the patient's social issues. However, as more and more patients present with right-sided disease, there is a growing body of the literature focusing on how to best treat this difficult patient population. Contemporary guidelines and indications for right-sided interventions follow those for left-sided disease [27]. Nevertheless, the specific surgical procedures considered for these patients, despite decades of experience, remain unclear [28, 29]. Options included “vegetomy,” “valvectomy,” valve repair, and valve replacement [30]. The historical literature on simply removing the infected tricuspid valve and leaving the patient with “wide-open” tricuspid regurgitation is still frequently utilized despite concerns for the development of severe right-heart failure and its devastating pathophysiologic consequences [31]. Even though there are a small subset of patients who not only survived this surgical approach AND complete a course of drug rehabilitation AND are deemed to be reasonable surgical candidates for eventual valve replacement AND have an uncomplicated surgical course, some advocate

(including this author) that this approach is completely against surgical and medical wisdom, inappropriate ethically, and predisposes patients to unreasonable postoperative complications and that operative intervention must involve appropriate debridement of all infected tissues but, as importantly, not predispose the patient to the catastrophic sequelae of “wide-open” tricuspid regurgitation. The technical and ethical aspects of right-sided disease and the management of patients with substance abuse are discussed in this text. Rarely is right-side infections managed with procedures that result in severe regurgitation—a pathophysiology that is often the initial indication for intervention.

## 6. Social implications

The growing population of patients who abuse intravenous drugs, as discussed, has resulted in a significant increase in those patients presenting with endocarditis. There has been a reported twofold increase in the number of active heroin users between 2006 and 2013 [32]. The implications of this cannot be ignored. While it is unclear if it is infected needles, skin contamination, or infected drugs being injected—or a combination of events—the consequences are the same. In addition, as a function of their substance abuse, often these patients present with underlying, and often untreated, hepatitis B, hepatitis C, and the human immunodeficiency virus (HIV) [33]. These patients often have chronic pain syndromes and high levels of tolerance to narcotics associated with their drug addictions, not to mention associated personality and psychological disorders, all of which challenge the short- and long-term care and management options for this population. Long-term compliance with medical therapies, such as anticoagulation for mechanical valves, might predispose these patients to early tissue valve failure and the need for reintervention. Such decision-making must also consider existing comorbidities, such as liver dysfunction from untreated hepatitis or recent embolic strokes. As such, it is easy to appreciate that even a single episode of endocarditis can have tremendous lifelong ramifications [34]. As such, having a good understanding of the long-term outcomes of these patients is important in decision-making at the time of their index event. For example, one study reported that between 2002 and 2014, there was a two times increase in the number of patients requiring surgery for infected endocarditis at their institution space (14.8% in 2002 to 26% in 2012). Of the 436 patients studied over a mean follow-up of 29 months, adverse events occurred in 20%, including 10% developing reinfections—often as a function of continued substance abuse. Even though there was a lower operative mortality in patients with drug abuse mainly due to their age, a propensity score analysis demonstrated that IV drug abuse was associated with an almost fourfold increase in valve-related complications and a 6.2-fold increase in the risk for reinfection. Unfortunately, because of the biased beliefs (some of which might be valid) of relapse of drug abuse, noncompliance, limited access to chronic healthcare, and poor socioeconomic status of many of these patients, surgery in the setting of long-standing drug abuse is often viewed as intervening on an end-stage disease that is often imminently fatal. Some clinicians view attempts at curing these patients of their infections and substance abuse as being futile. The consequence of this, as discussed in the chapter on the ethics of surgery, is the issue of what to do with patients who reinfected their prosthetic heart



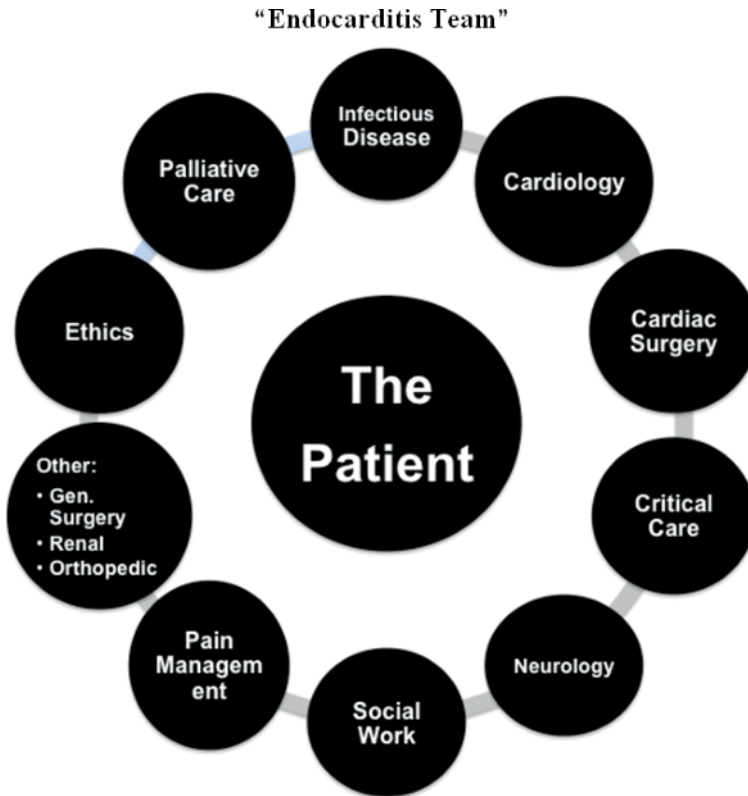
**Figure 1.** Echocardiogram of a 28-year-old mother of two with a long-standing history of substance abuse and multiple admissions over several years for tricuspid valve endocarditis. Surgery was not offered on multiple occasions due to concerns of recurrence and noncompliance and her substance abuse. She presented with severe right ventricular (RV) failure, severe right atrial (RA) enlargement, and a non-existent tricuspid valve, ascites, and hepatic congestion, and was deemed to be inoperable by a multidisciplinary team. A palliative care consult was obtained, and she was referred to hospice. She died of right-sided heart failure several months later.

valves in the setting of ongoing substance abuse. Until more objective data and experiences are available to guide such decision-making, clearly prior to withholding potentially high-risk, lifesaving, re-operative surgery, a referral to palliative care and ethics team is indicated—not to mention an open and honest (and well-documented) discussion with the patient and family regarding the severity of the issue at hand. Many surgical teams will force the patient to sign a plan of care contract prior to surgery acknowledging that noncompliance and valve reinfection might result in withholding further or future therapies (**Figure 1**).

## 7. Conclusions

Improvements in technology and a greater awareness of the problem have resulted in a substantial increase in the diagnosis of infectious endocarditis. Furthermore, as patients present with





**Figure 2.** Structure of an “Endocarditis Heart Team” (adopted from Firstenberg [25]).

more complex and high-risk comorbidities, difficult social problems—such as intravenous substance abuse—and a wider utilization of invasive cardiac therapies, the risk for developing infectious complications has also increased. Without a doubt, the management of endocarditis—regardless of the presentation—continues to be an evolving and difficult problem. As such, much like many other complex medical and surgical problems, there is growing evidence that a team approach to both short- and long-term management is a foundation to success (**Figure 2**) [35, 36].

The goal of this text is to provide some valuable insights into some of the ever-evolving topics and controversies and by no means is it intended to be the definitive reference—the area is too complex and the science is moving too quickly. Nevertheless, hopefully with a greater awareness and understanding, there can be ongoing improvements in the prevention, diagnosis, and treatment of this devastating problem.



## Author details

Michael S. Firstenberg<sup>1,2\*</sup>

\*Address all correspondence to: [msfirst@gmail.com](mailto:msfirst@gmail.com)

1 Cardiothoracic Surgery, The Medical Center of Aurora and Rose Hospital, Aurora, Colorado, USA

2 Surgery and Integrative Medicine–College of Medicine, Adjunct Faculty–College of Graduate Studies, Northeast Ohio Medical Universities, Ohio, USA

## References

- [1] Janszky I, Gémes K, Ahnve S, Asgeirsson H, Möller J. Invasive procedures associated with the development of infective endocarditis. *Journal of the American College of Cardiology*. 2018;**71**(24):2744-2752
- [2] Zegri-Reiriz I, de Alarcón A, Muñoz P, Sellés MM, González-Ramallo V, Miro JM, Falces C, Rico CG, Urkola XK, Lepe JA, Alvarez RR. Infective endocarditis in patients with bicuspid aortic valve or mitral valve prolapse. *Journal of the American College of Cardiology*. 2018; **71**(24):2731-2740
- [3] Sousa C, Botelho C, Rodrigues D, Azeredo J, Oliveira R. Infective endocarditis in intravenous drug abusers: An update. *European Journal of Clinical Microbiology and Infectious Diseases*. 2012;**31**(11):2905-2910
- [4] Habib G, Lancellotti P, Antunes MJ, Bongiorni MG, Casalta JP, Del Zotti F, Dulgheru R, El Khoury G, Erba PA, Iung B, Miro JM. ESC Guidelines for the management of infective endocarditis. *European Heart Journal*. 2015;**2015**:ehv319
- [5] Njoroge LW, Al-Kindi SG, Koromia GA, ElAmm CA, Oliveira GH. Changes in the Association of Rising Infective Endocarditis with Mortality in People Who Inject Drugs. *JAMA Cardiology*. Published online June 20, 2018. DOI: 10.1001/jamacardio.2018.1602
- [6] Latib A, Naim C, De Bonis M, Sinning JM, Maisano F, Barbanti M, Parolari A, Lorusso R, Testa L, Dato GMA, Miceli A. TAVR-associated prosthetic valve infective endocarditis: Results of a large, multicenter registry. *Journal of the American College of Cardiology*. 2014;**64**(20):2176-2178
- [7] Salaun E, Sportouch L, Barral PA, Hubert S, Lavoute C, Casalta AC, Pradier J, Ouk D, Casalta JP, Lambert M, Gouriet F. Diagnosis of infective endocarditis after TAVR: Value of a multimodality imaging approach. *JACC Cardiovascular Imaging*. 2018;**11**(1):143-146

- [8] Thornhill MH, Dayer MJ, Jones S, Prendergast B, Baddour LM, Lockhart PB. The effect of antibiotic prophylaxis guidelines on incidence of infective endocarditis. *Canadian Journal of Cardiology*. 2016;**32**(12)
- [9] Patanè S. Is there a need for bacterial endocarditis prophylaxis in patients undergoing gastrointestinal endoscopy? *Journal of Cardiovascular Translational Research*. 2014;**7**(3): 372-374
- [10] Dayer MJ, Jones S, Prendergast B, Baddour LM, Lockhart PB, Thornhill MH. Incidence of infective endocarditis in England, 2000–13: A secular trend, interrupted time-series analysis. *The Lancet*. 2015;**385**(9974):1219-1228
- [11] Slipczuk L, Codolosa NJ, Carlos D, Romero-Corral A, Pressman GS, Figueredo VM. Systematic review and meta-analysis of infective endocarditis microbiology over 5 decades. *Circulation*. 2012;**126**(Suppl 21):A15138
- [12] Dellinger RP, Levy MM, Rhodes A, Annane D, Gerlach H, Opal SM, Sevransky JE, Sprung CL, Douglas IS, Jaeschke R, Osborn TM. Surviving sepsis campaign: International guidelines for management of severe sepsis and septic shock, 2012. *Intensive Care Medicine*. 2013;**39**(2):165-228
- [13] Tacke D, Koehler P, Cornely OA. Fungal endocarditis. *Current Opinion in Infectious Diseases*. 2013;**26**(6):501-507
- [14] Abandeh FI, Bazan JA, Davis JA, Zaidi AN, Daniels CJ, Firstenberg MS. Bartonella henselae prosthetic valve endocarditis in an adult patient with congenital heart disease: Favorable outcome after combined medical and surgical management. *Journal of Cardiac Surgery*. 2012;**27**(4):449-452
- [15] Pfahl KW, Orsinelli DA, Raman S, Firstenberg M. The diagnosis and treatment of a mycotic coronary artery aneurysm: A case report. *Echocardiography*. 2013;**30**(10):E304-E306
- [16] Liu J, Frishman WH. Nonbacterial Thrombotic Endocarditis. *Cardiology in Review*. 2016 Sep 1;**24**(5):244-247
- [17] Baddour LM, Wilson WR, Bayer AS, Fowler VG, Tleyjeh IM, Rybak MJ, Barsic B, Lockhart PB, Gewitz MH, Levison ME, Bolger AF. Infective endocarditis in adults: Diagnosis, antimicrobial therapy, and management of complications: A scientific statement for healthcare professionals from the American Heart Association. *Circulation*. 2015;**132**(15):1435-1486
- [18] Bruun NE, Habib G, Thuny F, Sogaard P. Cardiac imaging in infectious endocarditis. *European Heart Journal*. 2014;**35**(10):624-632
- [19] Habets J, Tanis W, Reitsma JB, van den Brink RB, Willem PTM, Chamuleau SA, Budde RP. Are novel non-invasive imaging techniques needed in patients with suspected prosthetic heart valve endocarditis? A systematic review and meta-analysis. *European Radiology*. 2015;**25**(7):2125-2133
- [20] Mahmood M, Kendi AT, Ajmal S, Farid S, O'Horo JC, Chareonthaitawee P, Baddour LM, Sohail MR. Meta-analysis of 18F-FDG PET/CT in the diagnosis of infective endocarditis. *Journal of Nuclear Cardiology*. 2017;**30**:1-4

- [21] Yanagawa B, Petterson GB, Habib G, Ruel M, Saposnik G, Latter DA, Verma S. Surgical management of infective endocarditis complicated by embolic stroke: Practical recommendations for clinicians. *Circulation*. 2016;**134**(17):1280-1292
- [22] Aranki SF, Santini F, Adams DH, Rizzo RJ, Couper GS, Kinchla NM, Gildea JS, Collins JJ Jr, Cohn LH. Aortic valve endocarditis. Determinants of early survival and late morbidity. *Circulation*. 1994;**90**(5 Pt 2):II175-II182
- [23] Kang DH, Kim YJ, Kim SH, Sun BJ, Kim DH, Yun SC, Song JM, Choo SJ, Chung CH, Song JK, Lee JW. Early surgery versus conventional treatment for infective endocarditis. *New England Journal of Medicine*. 2012;**366**(26):2466-2473
- [24] Erbel RA. The New Strategy in Infective Endocarditis: Early Surgery Based on Early Diagnosis: Are We Too Late, When early Surgery is Best? *Circulation*. 2014 Dec 5, pp. CIRCULATIONAHA-114
- [25] Firstenberg MS. Introductory Chapter: Endocarditis—A Diagnostic and Therapeutic Challenge, *Contemporary Challenges in Endocarditis*. Michael S. Firstenberg, IntechOpen. DOI: 10.5772/66406. Available from: <https://www.intechopen.com/books/contemporary-challenges-in-endocarditis/introductory-chapter-endocarditis-a-diagnostic-and-therapeutic-challenge>
- [26] Perrotta S, Jeppsson A, Fröjd V, Svensson G. Surgical treatment of aortic prosthetic valve endocarditis: A 20-year single-center experience. *The Annals of Thoracic Surgery*. 2016; **101**(4):1426-1432
- [27] Yong MS, Coffey S, Prendergast BD, Marasco SF, Zimmet AD, McGiffin DC, Saxena P. Surgical management of tricuspid valve endocarditis in the current era: A review. *International Journal of Cardiology*. 2016;**202**:44-48
- [28] Protos AN, Trivedi JR, Whited WM, Rogers MP, Owolabi U, Grubb KJ, Sell-Dottin K, Slaughter MS. Valvectomy versus Replacement for the Surgical Treatment of Tricuspid Endocarditis. *The Annals of Thoracic Surgery*. 2018 May 16. pp. S0003-4975(18)30680-5. DOI: 10.1016/j.athoracsur.2018.04.051. [Epub ahead of print]
- [29] Alqahtani F, Ad N, Badhwar V, Holmes S, Alkhouli M. Trends in tricuspid valve surgery secondary to bacterial endocarditis: National inpatient sample (NIS) results. *Journal of the American College of Cardiology*. 2018;**71**(11 Suppl):A2017
- [30] Hughes CF, Noble N. Vegetectomy: An alternative surgical treatment for infective endocarditis of the atrioventricular valves in drug addicts. *Journal of Thoracic and Cardiovascular Surgery*. 1988;**95**:857-861
- [31] Dawood MY, Cheema FH, Ghoreishi M, Foster NW, Villanueva RM, Salenger R, Griffith BP, Gammie JS. Contemporary outcomes of operations for tricuspid valve infective endocarditis. *The Annals of Thoracic Surgery*. 2015;**99**(2):539-546
- [32] Wurcel AG, Anderson JE, Chui KK, Skinner S, Knox TA, Snyderman DR, Stopka TJ. Increasing infectious endocarditis admissions among young people who inject drugs. *Open Forum Infectious Diseases*, Oxford University Press. 2016;**3**(3):ofw157

- [33] Gundedly P, Burgess DS, Boulay J, Caldwell G, Thornton A. 921 prevalence of hepatitis C infection and epidemiology of infective endocarditis in intravenous drug users in central Kentucky. *Open Forum Infectious Diseases*, Oxford University Press. 2014, 2014;**1**(Suppl 1): S266-S266
- [34] Magsino K, Sanjanwala R, Hiebert B, Rothney J, Manji R, Arora R, Shah P. Treatment Outcomes for Right-Sided Endocarditis in Intravenous Drug Users: A Systematic Review and Analysis of Outcomes in a Tertiary Centre. *The Thoracic and Cardiovascular Surgeon*. 2018 Jan 19. DOI: 10.1055/s-0037-1618578. [Epub ahead of print]
- [35] Chambers J, Sandoe J, Ray S, Prendergast B, Taggart D, Westaby S, Arden C, Grothier L, Wilson J, Campbell B, Gohlke-Bärwolf C. The infective endocarditis team: Recommendations from an international working group. *Heart*. 2014;**100**(7):524-527
- [36] Chirillo F, Scotton P, Rocco F, Rigoli R, Polesel E, Olivari Z. Management of patients with infective endocarditis by a multidisciplinary team approach: An operative protocol. *Journal of Cardiovascular Medicine*. 2013;**14**(9):659-668