

Chapter

Saddle Nose: A Systematic Approach

Marianetti Tito Matteo

Abstract

The saddle nose deformity is always associated to cartilaginous or bone defects. It could have congenital, traumatic, infectious or iatrogenic origin. Its correction consists not only in a camouflage, but also it is important to reconstruct the missing structure. In this chapter, we will discuss about all aspect of the saddle nose and we will propose a different therapeutical approach (septum, concha or costal grafts) in relation to the severity of the defects (with a personal classification). The classification is also based on the presence or absence of the nasal septum, which is a fundamental aspect that we must take into account when approaching nasal reconstruction. We will discuss the technical aspect of the rib graft harvesting and its use to reconstruct the nasal structure.

Keywords: saddle nose, rib graft, nasal reconstruction

1. Introduction

Saddle nose is a pathological deformity characterized by loss of nasal dorsal height due to osseocartilaginous collapse.

While the cause can be congenital, for example, syphilis or intrauterine trauma, most cases are due to trauma of the nasal septum and pyramid, Wegener granulomatosis, relapsing polychondritis, cocaine abuse, and previous rhinoplasty. The removal of an excessive amount of the bone and/or cartilage during a prior operation is the most frequent cause.

Saddle nose is one of the most difficult morpho-functional deformities of the nose to correct, as it entails not only masking with a graft but also planned anatomical reconstruction of all the structures involved. Grafts obtained from septal or conchal cartilage, sutured in overlapping layers so as to increase the thickness where necessary, can be sufficient in cases of low to medium severity. The presence of septal remnants can be exploited to combine septal grafts with grafts of auricular concha in order to increase the thickness of the final graft. There is instead less agreement on the choice of material for use in reconstruction in cases of greater severity, where the absence of cartilage is often combined with the absence of the bony support of the nasal pyramid. The ideal graft material must be nontoxic, non-carcinogenic, non-allergenic, nondestructive with respect to adjacent tissues, non-resorbable, readily available, and sterilizable as well as easy to shape and to remove if necessary.

The variety of autogenous (bony and cartilaginous), homologous (irradiated cartilage), and alloplastic grafts put forward in the literature attests to the

nonexistence of one “ideal” material. Alloplastic grafts have a tendency toward extrusion and infection, and homologous grafts are characterized by the highest rate of resorption. The bone is difficult to shape, requires solid stabilization, and can be reabsorbed. In the end, despite its tendency toward distortion, costal cartilage remains at present the material of choice for the correction of severe cases of saddle nose.

It should also be pointed out, on the basis of the majority of cases presented in the literature, that cartilaginous grafts give rise to the fewest problems as regards shaping, attachment, and infection. The only negative data regarding resorption is, however, limited in the case of autologous cartilage and generally ceases in the first few months after the operation.

1.1 Autologous grafts

1.1.1 Bone

The bone is the material most commonly employed to remedy saddle nose over the last century. The first to use the autologous bone for nasal reconstruction was Ollier in 1861, who inserted a piece of the frontal bone in an Indian flap. The material is mostly taken from the cranium and the iliac crest [1, 2]. The bone cannot be regarded as a material of choice, however, because it tends to be reabsorbed when inserted into the nasal dorsum. Complications at the donor site and the fact that grafts of this nature create a dorsum of excessive rigidity are further reasons why the use of autologous bone in cases of saddle nose has been practically abandoned today [3].

1.1.2 Cartilage

Currently regarded as the graft material closest to the ideal, autologous cartilage presents the following characteristics: (1) it causes little reaction in the tissues of the recipient site; (2) it possesses the combination of rigidity, elasticity, and flexibility required to reconstruct the contours of the nose; (3) it can resist the traction forces of wound healing; (4) it can survive without functional use (unlike the bone); (5) it is available in large amounts; and (6) it is easy to reshape and survives over time without the perichondrium. Tardy reports no cases of infection or rejection in 6000 cartilaginous grafts. It has also been shown that resorption is short-lived and limited to the initial postoperative period [2, 4].

In cases of low or moderate severity, cartilage from the nasal septum or auricular concha can be used. In more severe cases, a graft of costal cartilage constitutes the preferred therapeutic option. This cartilage is hyaline and proves to be rigid and fragile (**Figure 1**). Always available in large amounts and thicknesses, it is sufficiently rigid for use in cases where it is necessary to counter the retraction of thick, inelastic, cicatricial tissues. While the material is usually harvested from the ninth and tenth ribs, the sixth, seventh, and eighth are preferable in the case of female patients, as the incision is thus made in the inframammary fold and the postoperative scar is not visible. Gunter et al. [5] suggest that a CT scan of the sternal-costal region should be carried out in the case of adult patients to ascertain the degree of calcification of the cartilaginous portion of the ribs.

The incision (about 5 cm) must be performed horizontally in the medial (cartilaginous) portion of the rib. In harvesting material from the sixth, seventh, and eighth ribs, it must be borne in mind that their medial portion is covered by the rectus abdominis muscle of the abdomen (**Figure 2**). The fascia of this muscle must be cut and the fibers opened out in the same direction as the fascicle. The ninth and

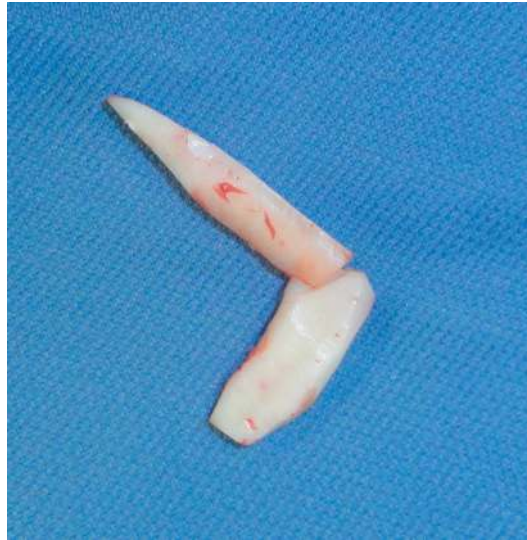

Figure 1.
Costal cartilage used to reconstruct the “L-structure” of the septum.

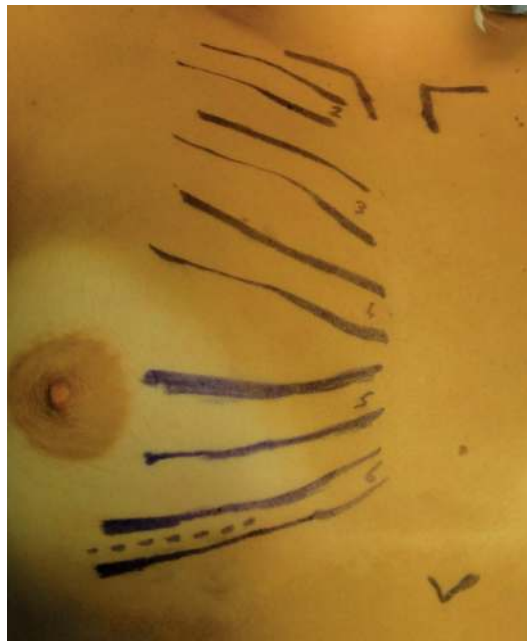

Figure 2.
Preoperative drawing of the second to sixth rib of a patient.

tenth ribs are instead located at the side of the rectus abdominis muscle. Once the outer surface of the rib has been exposed, it must be separated from the intercostal muscles, which can be facilitated on the inner side by the use of a specific curved rib elevator (**Figure 3**).

The perichondrium can be separated from the rib for subsequent use to cover any residual irregularities of the nasal dorsum.

Particular care must be taken in detaching the inferior portion of the rib, as this is where the anterior intercostal branches of the internal thoracic (or mammary) artery, the venae comitantes, and the intercostal nerves are all situated. It is important to identify the joint of the bony and cartilaginous portions so as to harvest the largest possible amount of cartilage. Once the portion of the rib required has been

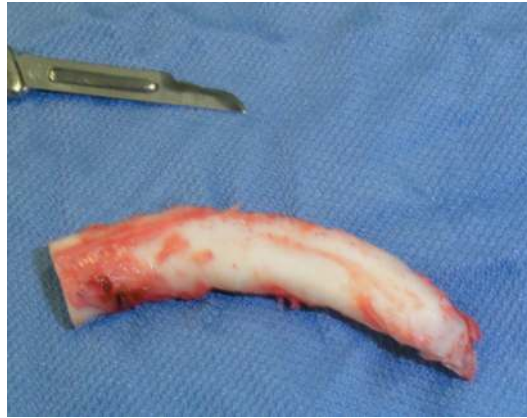

Figure 3.
Harvesting of the cartilaginous segment of the sixth rib.

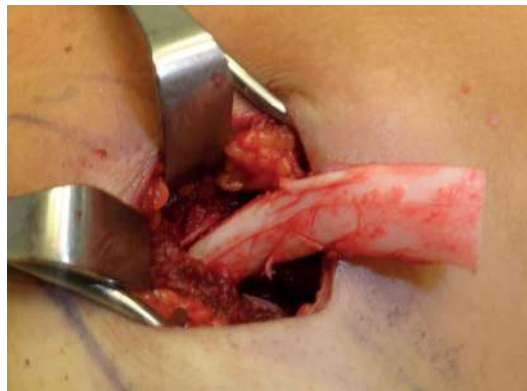

Figure 4.
Intraoperative view of the costal harvesting.

exposed and detached, it can be removed by excision, using a scalpel with sturdy blade; after which it is necessary to make sure that the pleura below is undamaged. The cavity thus left is filled with a saline solution, and the anesthetist is asked to increase the pressure in the airways, making sure that no bubbles appear in the cavity.

A considerable amount of cartilage can be obtained from the rib, and more than one can be harvested with no postoperative functional deficit (**Figure 4**).

It is very important to suture the remaining perichondrium tightly so as to seal off the empty space left after harvesting the rib.

The major problem of costal cartilage is its tendency to become distorted [6]. Various methods have been put forward for the prevention of this complication. Gibson and Davis [7] demonstrated that “balanced cross-sectional carving” (removal of the perichondrium and a strip of cartilage from the outer and inner sides with respect to the thorax and the use of the cartilage in the middle) reduced the tendency toward distortion considerably. Gibson then stated, however, in a later publication that distortion of the cartilage could only be prevented by not harvesting it. Some authors investigated the molecular basis of the tendency toward distortion of the cartilage and showed that certain protein-polysaccharide complexes inhibits the intracartilaginous stress causing distortion, an interesting discovery that has, however, had no clinical application [8]. Gunter et al. [9] have demonstrated that distortion of the harvested costal cartilage is significantly reduced by the insertion of a Kirschner thread. While the different authors all agree

that the distortion peaks 15–30 minutes after harvesting, some claim that it exists only in the first half of an hour and others claim that it can take place even months after the operation. The most superficial and deepest layers of the costal cartilage harvested are those that undergo the greatest distortion according to the rule of cross-sectional carving. Common experience suggests that this is accelerated if the cartilage is immersed in a saline solution immediately after removal.

Complications in the area of the donor site are very infrequent. They can include pneumothorax, localized postoperative atelectasis, and unsightly scarring. Postoperative pain is instead common and can be prevented or reduced by injecting local anesthetic into the subperichondrial space before the final suturing [10–11].

1.2 Alloplastic grafts

While alloplastic grafts present a high risk of infection and extrusion, many surgeons make use of them at first because they are readily available and, above all, avoid any complications at the donor site. Prostheses of silicone (Silastic) are still widely used by many authors to reconstruct the dorsum in cases of saddle nose, probably because they prove to be easy to handle and to remove in the event of infection [12–15]. Milward reports extrusion rates of up to 55%, however, and Deva et al. complications in 9.7% of cases [12, 13]. Other materials used include polytetrafluoroethylene and hydroxyapatite. Complications have been reported in 2.6–5% of cases for Gore-Tex and 5% for hydroxyapatite [16, 17].

Another synthetic material frequently used at present with an apparently lower percentage of complications is porous high-density polyethylene (PHDPE: MEDPOR surgical implants, Porex Surgical), which has been employed in cranio-maxillofacial surgery for 20 years now and is of proven tolerability. This porous alloplastic material (pores of about 150 microns in diameter) is not degradable *in vivo* and permits the fibrointegration of soft tissues. Once this has taken place, it proves to be stable, and the risk of extrusion and infection diminishes over the years. Romo et al. suggest covering the MEDPOR graft with a homologous graft of purified acellular human derma in order to taper the edges and make the dorsum less rigid and more natural in appearance. Even though this is one of the alloplastic materials most frequently used at present, Romo reports complications in 3–4% of cases [17].

1.3 Classification and therapeutic algorithm

Tardy's classification of saddle nose has three increasing degrees of severity: minimum, moderate, and major [2]. The first degree involves slight accentuation of the depression of the supratip, 1–2 millimeters above the ideal. The presence can be observed in such cases of a dorsal “pseudo-hump” in the upper third of the nasal pyramid caused by collapse of the other two thirds. If saddle nose deformity is due to the absence of the caudal septum, there will also be a certain degree of columellar retraction. Saddle nose of moderate and major severity presents greater depression of the dorsum due to the loss of osseocartilaginous support.

The classification of Daniel and Brenner [18] instead distinguishes six types of saddle nose:

(1) Type 0 (pseudo-saddle nose) comprises patients who present depression of the cartilaginous dorsum due to prior rhinoplasty. (2) Type I (minor) includes cases with excessive depression of the supratip and columellar retraction caused by weakening of the cartilaginous septum. (3) Type II (moderate) is characterized by collapse of the cartilaginous ridge, columellar retraction, and loss of support for the tip. (4) Type III (major) comprises more severe cases with the total absence of support for the cartilaginous ridge, the columella, and the nasal tip. (5) Type IV

(severe) involves the total absence of osseocartilaginous support, often combined with septal perforation, depression of the osseocartilaginous dorsum, columellar retraction, and the loss of tip projection. (6) Type V (catastrophic) comprises cases that require local or free flaps for reconstruction and are often combined with deformity of other neighboring regions of the face. The authors correlate each of the different types with a therapeutic approach, increasing in complexity in relation to the tissue deficit involved, and a specific etiology.

It is, however, often difficult in practical terms to identify a particular case of saddle nose as belonging to one category or another of an overly specific classification characterized by common etiologies, clinical characteristics, and therapeutic approaches. As Murakami says, “variability exists to large extent, because the saddle nose deformity is not a single entity but rather a spectrum of abnormalities.”

On the other hand, the practical need is felt for quick classification of saddle nose as a prerequisite for deciding how to correct it.

The original classification put forward here as a more practical tool involves three degrees of severity and takes the presence or absence of the nasal septum as the primary factor in determining the surgical treatment required.

Degree I (slight): depression <2 mm with respect to the ideal height of the dorsum: septum present (**Figure 5a**).

Degree II (moderate): depression of 2–5 mm with respect to the ideal height of the dorsum:

- (a) cartilaginous septum present or partially present (**Figure 6a**) and
- (b) septum absent (**Figure 7a**)

Degree III (severe): depression >5 mm with respect to the ideal height of the dorsum: septum absent (**Figure 8a**).

The resulting therapeutic algorithm is as follows:

- I: Onlay grafts from the nasal septum (**Figure 5b**).
- Ia: Onlay grafts from the nasal septum and/or auricular concha (**Figure 6b**).
- Iib: Reconstruction of the septum and dorsum with auricular concha (**Figure 7b**).
- III: Reconstruction of the septum and dorsum with costal cartilage (**Figure 8b**).

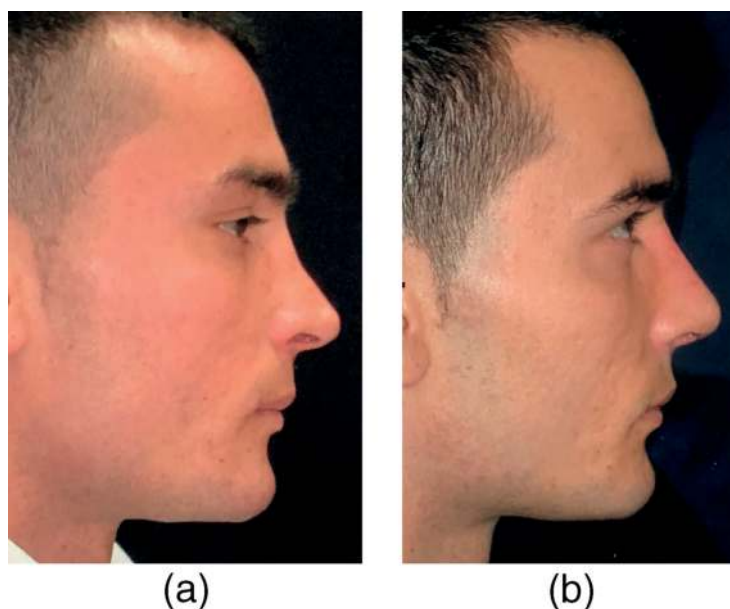


Figure 5.
(a) Preoperative view of a patient affected by saddle nose deformity degree I (slight). (b) Postoperative profile view of the same patient of (a).

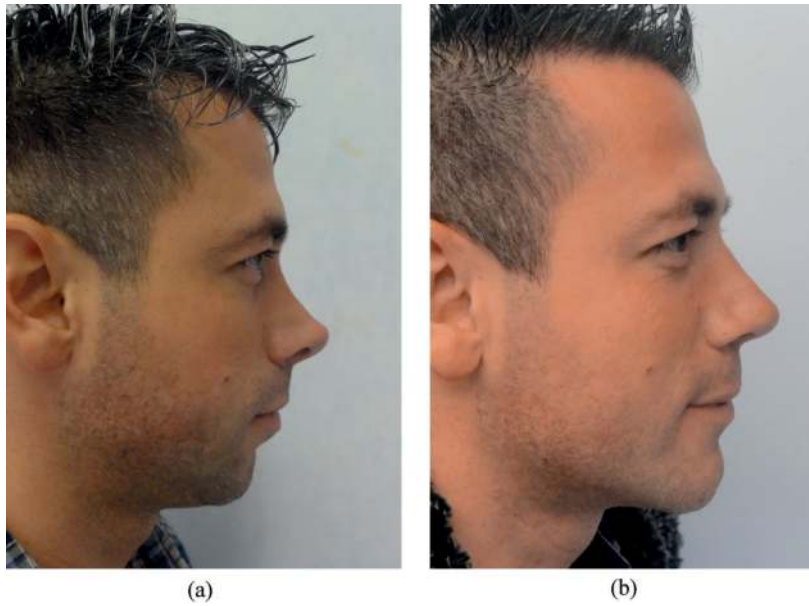


Figure 6.
(a) Preoperative view of a patient affected by saddle nose deformity degree IIa (moderate with cartilaginous septum present). (b) Postoperative profile view of the same patient of (a).

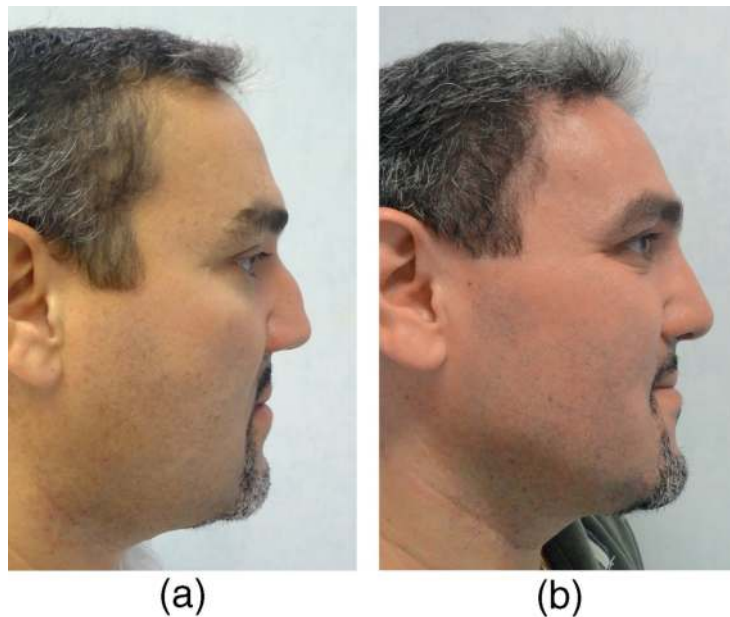


Figure 7.
(a) Preoperative view of a patient affected by saddle nose deformity degree IIb (moderate with cartilaginous septum absent). (b) Postoperative profile view of the same patient of (a).

The ideal height of the dorsum differs for men and women, coinciding in the first case with the line from the nasion to the tip-defining points (with suitable projection of the tip) and positioned about 2 mm caudally from the same in the second.

The presence or absence of the nasal septum, as ascertained clinically not only by palpation and anterior rhinoscopy but also by radiological means like RMN for greater accuracy, is of crucial importance in deciding how to correct the deformity (**Figure 9**).

The primary objective must be to restore support for the nose and then to obtain the desired appearance. The reconstruction can be thus described as composite with a bottom layer of support and an upper layer of esthetic importance. In cases I and

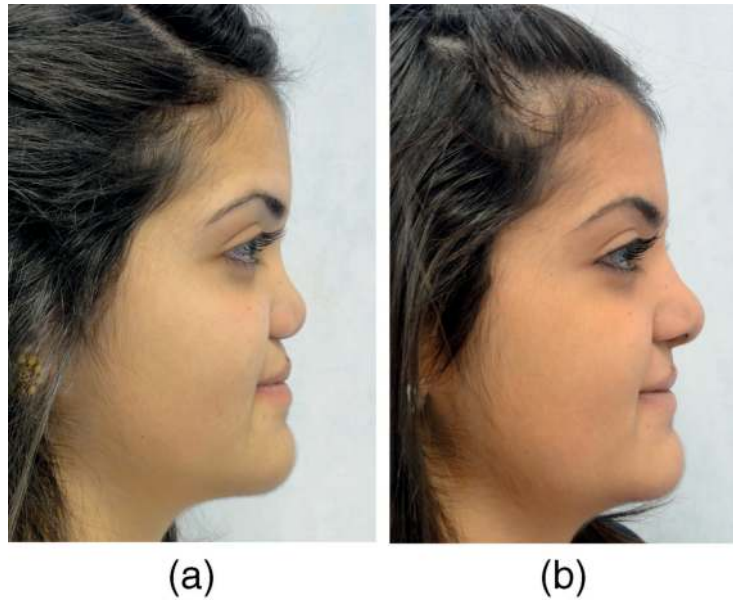


Figure 8.
(a) Preoperative view of a patient affected by saddle nose deformity degree III (severe). (b). Postoperative profile view of the same patient of (a).



Figure 9.
Clinical sign of absent septal support.

IIa, where the septum is present and support exists, onlay grafts can be used to correct the deformity. The material can be taken from the present or residual septum and from the cartilage of the auricular concha if this proves insufficient.

The onlay graft must be carefully shaped to make sure that it is not perceptible to sight or touch after the operation. To this end, incisions can be made halfway

through the thickness of the cartilage in order to obtain a more or less curved shape as required. The cartilage can be given as inverted V, inverted U, or A shape by means of greenwood fractures.

It must also be oval, wider in the middle, and narrower at the top and bottom, in order to follow the natural shape of the dorsum.

An inverted V graft offers superior adaptation and stability than a flat one. As it consists of a single layer, it can only be used for patients requiring a minimal increase in the dorsum. If more is needed, a pillar of cartilage can be sutured beneath the inverted V so as to create a solid A-shaped structure. This stabilizing pillar can be secured closer to or farther from the top of the inverted V in order to vary the degree of gap between the arms of the V and increase or decrease the height of the graft. Both the inverted V and the A shape present, however, a very acute angle at the top, which can make the dorsum look too narrow in patients with very thin skin. In such cases, it proves useful to make further incisions halfway through the thickness on either side of the median incision so as to obtain an inverted U shape, which is closer to the natural curvature of the nasal dorsum and proves more stable on insertion into the same. Even in cases when only a localized dorsal defect is present, it is usually preferable, where possible, to use a graft covering the area from the nasion to the septal angle in order to reduce the irregularities, obtain the best esthetic result, and reduce the possibility of the graft being moved out of position. In order to secure the onlay graft, a very precise pouch must be created cephalically so as to prevent movement out of position. Caudally, it is instead possible to secure the graft to the septum or the alar cartilages, suturing in this case being obviously facilitated by the open approach. In order to obtain greater stability, a median incision of about 5 mm can be made in the caudal edge of the graft so as to obtain two small strips of cartilage for suturing to the lateral crura.

Some authors advise securing the graft also cephalically by means of transcutaneous sutures to be removed after 7–10 days. One further tip when using onlay grafts is to taper the edges carefully in order to prevent the creation of “steps” perceptible to sight or touch after the operation.

Degree IIb involves moderate depression of the nasal dorsum and the absence of septal support. In such cases, while costal cartilage is a possibility, reconstruction of the L-shaped structure of caudal dorsal support with auricular cartilage is unquestionably preferable given the almost total absence of undesirable esthetic-functional consequences. It is in any case generally preferable, whenever possible, to harvest material from the auricular concha rather than the rib, not least in terms of acceptability to the patient. Even though its elasticity and natural curvature do not make conchal cartilage an ideal material for reconstruction of the nasal septum, it is possible to obtain a straight and solid L-shaped supporting structure (**Figure 10**).

The esthetic and functional results can be excellent, and damage at the donor site is normally minimal [19].

The auricular concha is instead insufficient, even when harvested bilaterally, for the correction of type III saddle nose, where marked dorsal depression and the absence of septal support are often combined with the lack of support from the nasal bones. All this is almost invariably accompanied by contraction of the skin and mucus membrane of a cicatricial nature or as a result of cocaine abuse or previous rhinoplasty.

The therapeutic approach to type III saddle nose is therefore aimed at the reconstruction of a sturdy L-shaped supporting structure capable of adequately withstanding the wound healing traction of the skin and mucus. The material of choice for the graft is unquestionably costal cartilage, shaped primarily with a view to reconstructing the caudal and dorsal support of the septum. To this end, it is possible

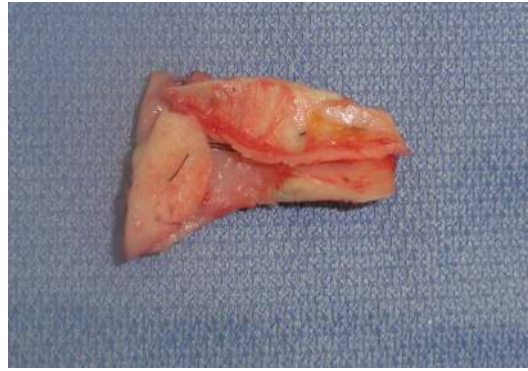


Figure 10.
Neoseptum totally reconstructed by conchal cartilage.

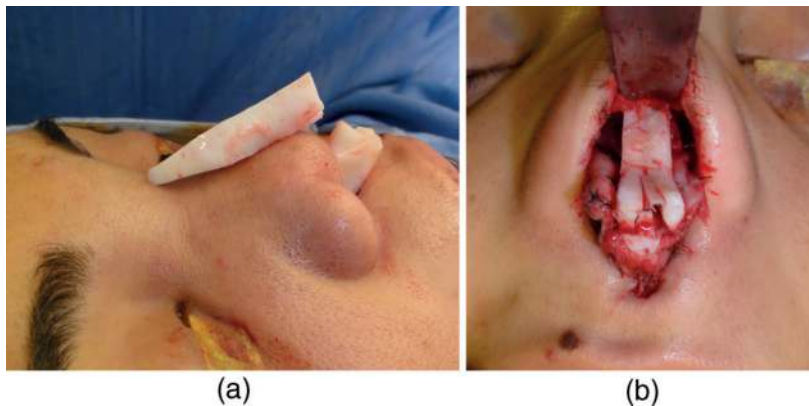


Figure 11.
(a) and (b) Antero-caudal septal structure reconstructed by costal cartilage.

to connect two pieces of a single rib (or two ribs), one to serve as the dorsal pillar with a socket to secure the other serving as the caudal pillar (**Figure 11a and b**).

It is not easy to secure the graft in place, above all in the cephalic portion. While some authors suggest that the creation of a pouch large enough for insertion of the graft is sufficient, others maintain that greater stability is required. According to Gunter et al., Kirschner thread can be used both to prevent distortion of the costal cartilage and to secure the graft cephalically [9]. Meyer suggests securing the graft with wire to the glabellar region after drilling a hole in the bone by means of open access [20]. Other authors maintain that it is sufficient to suture the graft to the skin above transcutaneously for 7–10 days. In the caudal portion, the graft should be secured with non-resorbable thread to the inferior nasal spine or its periosteum.

2. Summary

The saddle nose deformity is a big challenge for the surgeon. Its correction should be structural because the camouflage does not permit to correct the functional problems related to this pathology. In this chapter, we reviewed the different aspects of the saddle nose including its etiology, classification, and surgical treatment. The classification is very important because it can guide the surgical approach we should use for the correction. A fundamental diagnostic finding is the presence of the nasal septum which represents the gold material for the reconstruction. If this is missing, our reconstruction choice should be focused on auricular cartilage or costal cartilage in more severe cases.

Personal considerations of the author


The saddle nose represents one of the most challenging nasal deformities for the surgeon. The patient affected by saddle nose has almost always psychological problems, including concerns related to their own identity. The surgeon should evaluate the patient from different points of view, including diagnostic, therapeutical, and psychological. The choice of the correct surgical approach should be rational and based on the severity of the deformity. Different techniques of surgical correction of the saddle nose have to be present in our armamentarium, because only if we choose the right one, we can obtain optimal results.

Author details

Marianetti Tito Matteo
Marianetti Med Clinic, Rome, Italy

*Address all correspondence to: titomatteo.marianetti@tin.it

IntechOpen

© 2018 The Author(s). Licensee IntechOpen. This chapter is distributed under the terms of the Creative Commons Attribution License (<http://creativecommons.org/licenses/by/3.0>), which permits unrestricted use, distribution, and reproduction in any medium, provided the original work is properly cited. 

References

- [1] Converse J. *Reconstructive Plastic Surgery*. 2nd ed. Vol. 2. Philadelphia PA: WB Saunders; 1977. p. 1141
- [2] Tardy EM, Schwartz M, Parras G. Saddle nose deformity: Autogenous graft repair. *Facial Plastic Surgery*. 1989;**6**:2-21
- [3] Mowlen R. Bone grafting. *British Journal of Plastic Surgery*. 1963;**16**:293-299
- [4] Rozner L. Augmentation rhinoplasty. *British Journal of Plastic Surgery*. 1980;**33**:377-382
- [5] Gunter JP, Rohrich RJ, Hackney FL. Dorsal augmentation: Onlay grafting using shave autologous septal cartilage. In: *Dallas Rhinoplasty. Nasal Surgery by the Masters*. 2nd ed. St Louis, MO: Quality Medical Publishing; 2007
- [6] Fry H. Cartilage and cartilage grafts: The basic properties of the tissue and the components responsible for them. *Plastic and Reconstructive Surgery*. 1967;**40**:426-435
- [7] Gibson T, Davis WB. The distortion of autogenous cartilage grafts: Its cause and prevention. *British Journal of Plastic Surgery*. 1958;**10**:257-268
- [8] De Jong JH. Rib Graft in the Treatment of Saddle Deformity. Presented at the European Academy of Facial Surgery, London; 1983
- [9] Gunter JP, Clark CP III, Friedmann RM, Hackney FL. Internal stabilization of large autologous rib cartilage grafts to avoid warping in rhinoplasty. In: *Dallas Rhinoplasty. Nasal Surgery by the Masters*. 2nd ed. St Louis, MO: Quality Medical Publishing; 2007
- [10] Marin VP, Landecker A, Gunter JP. Harvesting rib cartilage grafts for secondary rhinoplasty. In: *Dallas Rhinoplasty. Nasal Surgery by the Masters*. 2nd ed. St Louis, MO: Quality Medical Publishing; 2007
- [11] Gibson T. Cartilage grafts. *British Medical Bulletin*. 1965;**21**:153-165
- [12] Milward TM. The fate of silastic and vitrathene nasal implants. *British Journal of Plastic Surgery*. 1972;**25**:1276-1278
- [13] Deva AK, Merten S, Chang L. Silicone in nasal augmentation rhinoplasty: A decade of clinical experience. *Plastic and Reconstructive Surgery*. 1998 Sep;**102**(4):1230-1237
- [14] Marvin JA. The application of cantilever bridge principle to silastic nasal support. *British Journal of Plastic Surgery*. 1980;**33**:404-406
- [15] Mackay IS, Bull TR. The fate of silastic in the management of saddle deformity of the nose. *The Journal of Laryngology and Otology*. 1983;**97**:43-47
- [16] Trenité N, Rhinoplasty GJ. *A Practical Guide to Functional and Aesthetic Surgery of the Nose*. The Netherlands: Kugler Publications; 2005
- [17] Romo T, Slafani AB, Sabini P. Reconstruction of the major saddle nose deformity using composite allo-implants. *Facial Plastic Surgery*. 1998;**14**(2):151-157
- [18] Daniel RK, Brenner KA. Saddle nose deformity: A new classification and treatment. *Facial Plastic Surgery Clinics of North America*. 2006;**14**(8):301-312
- [19] Bocchieri A. Subtotal reconstruction of the nasal septum using a conchal reshaped graft. *Annals of Plastic Surgery*. 2004;**53**(2):118-125
- [20] Meyer R, Kesselring UK. Reconstructive surgery of the nose. *Clinics in Plastic Surgery*. 1981;**8**:435-446